

Thoracic imaging with ^{67}Ga gallium

Heinrich Klech¹, Horst Köhn², Martin Huppmann¹, and Wolfgang Pohl¹

¹ II. Medical Department, Division of Pulmonary Diseases and

² Institute of Nuclear Medicine and L. Boltzmann Institute of Nuclear Medicine, Wilhelminenspital, A-1171 Vienna, Austria

Abstract. In the past, gallium-67 imaging has undergone several ups and downs related to its clinical importance. After a period of initial enthusiasm, its role and indications are now established. At present, there are two fields of clinical interest for ^{67}Ga -imaging: (1) mediastinal staging in bronchogenic carcinoma and the staging of malignant lymphoma; (2) assessment of activity in interstitial lung diseases, especially sarcoidosis and inflammatory lung disorders. The advantage of ^{67}Ga -imaging is that it is highly sensitive for the detection of neoplastic and inflammatory processes, independent of anatomical barriers. Particularly with the challenge of AIDS, ^{67}Ga -imaging will gain increasing importance in the future. The low specificity of gallium for detecting underlying disorders precludes its use as a primary diagnostic tool. Therefore, and because of the cost and radiation load, the indications for application will have to be selected very carefully.

Key words: ^{67}Ga Gallium imaging – Lung cancer – Mediastinal staging – Sarcoidosis – Inflammatory lung disorders – Indications

Since its introduction by Edwards and Hayes in 1969, the clinical value of gallium-67 scanning has remained controversial, despite the fact that numerous reports and reviews (Siemsen 1978; Bekerman 1980; Neumann 1984; Niden 1984; Yeh 1984; Waxman 1986) are available. However, ^{67}Ga scanning of the thorax is used worldwide as well as in our institution as an adjunct to radiography for a number of specific indications:

1. To assess hilar and mediastinal involvement in pulmonary malignancies
2. To assess extent, location and inflammatory activity of diffuse lung diseases such as sarcoidosis and other granulomatous lung disorders, extrinsic allergic alveolitis, interstitial lung fibrosis of various etiology, pneumoconioses, etc.
3. To follow up progression or response to treatment in these inflammatory disorders
4. To detect disseminated interstitial disease that escapes visualization by chest radiography in selected cases.

Controversy focuses mostly on the issues of reliability of ^{67}Ga scanning in assessment of malignant disorders (McKenna 1985) and of interpretation of the result clinically

in inflammatory lung disorders. Furthermore, the issues of restricted availability, costs and radiation load have been heavily disputed in the past (Whitcomb 1984).

This article describes the authors' experience with thoracic ^{67}Ga scanning, summarizes the present literature, and critically reviews the current clinical use of ^{67}Ga scanning as well as its limitations.

Mechanism of localisation

The uptake mechanism is probably the most fascinating aspect of ^{67}Ga scanning. Since here we have an "imaging of cells," in contrast to other means of imaging, the uptake of ^{67}Ga is not restricted by anatomical barriers. However, the exact uptake mechanism in tumors or inflammatory lesions is unknown. ^{67}Ga is bound to transferrin in the blood and accumulates in the lysosomal fraction of leukocytes, macrophages, reticuloendothelial cells and tumor cells (Hoffer 1980). Interference with transferrin receptors on the tumor cells is suggested as the primary reason for ^{67}Ga accumulation (Hoffer 1978; Larson 1978; Vallabhajosula 1983). Increased capillary leakage on inflammation sites and a direct bacterial uptake may be other contributing factors.

^{67}Ga Gallium scanning in thoracic malignancies

Table 1 lists the patients with various malignant thoracic disorders that have been investigated at our institution since 1979.

Table 1. Own series of patients with malignant intrathoracic disorders

Lung cancer	146
Mesothelioma	9
Pulmonary metastases	17
Hodgkin's lymphoma	23
Non-Hodgkin's lymphoma	33
Total	228

Materials and methods

Gallium imaging was done 72 h after intravenous administration of 3 mCi ^{67}Ga citrate. Large bowel clearing by use of laxatives preceded the administration. A whole-body hy-

Table 2. Assessment of mediastinal lymph node involvement (N2) in 55 patients with lung cancer

	Excluded	Confirmed
Mediastinoscopy	10	5
Transbronchial needle biopsy	3	11
Thoracotomy	21	3
Necropsy	0	2
Total	34	21

brid scanner (Scannicamera, CGR, spectrometer setting 150–400 keV) or a multipeak large-field gamma camera using the three major photon peaks of gallium and equipped with a high-energy collimator was used.

For evaluation of mediastinal involvement, a ^{67}Ga scan was considered as positive if the hilar and/or mediastinal region showed an abnormal uptake.

In a prospective clinical study of 55 patients with lung cancer, sensitivity and specificity of ^{67}Ga scanning in detecting mediastinal lymph node metastases were evaluated and compared to conventional chest radiography, including chest tomography as well as computed tomography (CT). Sixteen patients had squamous cell carcinoma, 12 had adenocarcinoma, 12 had small cell carcinoma, and 15 had other types of bronchogenic carcinoma.

Chest radiographs, conventional chest tomographs, computed tomographs, and ^{67}Ga scans were examined by two independent investigators. Interobserver variance was checked prior to evaluation and accordance was obtained in 95% of the selected cases.

A third-generation tomograph [Somatom DR3, 8 mm sections, matrix 512×512 , 100 ml contrast medium, 0.5 ml/s, Angiografin (Schering)] was used for CT. Evaluation of mediastinal lymph nodes by CT considered size, extent, and location with regard to primary tumor location as previously described (Hajek 1985). Mediastinal metastatic spread was confirmed in 21 patients and excluded in 34 patients by means of mediastinoscopy, transbronchial needle aspiration, thoracotomy, or necropsy (see Table 2).

Results

Primary lung cancer

In our series of 146 patients with lung cancer, 119 cases revealed positive uptake on the tumor site (82%). Lesions

Table 3. Uptake of ^{67}Ga in primary lung tumors

	Positive ^{67}Ga uptake <i>n</i>	%
Primary lesion > 3 cm	83/ 87	95
Primary lesion < 3 cm	36/ 59	61
Total	119/146	82

smaller than 3 cm were more difficult to detect than those larger than 3 cm (Table 3). Uptake of ^{67}Ga exceeded the size of the lesion in those cases where pneumonia due to bronchial obstruction was observed ($n=3$). We did not find essential differences of ^{67}Ga uptake among the various histological types of tumors. In patients with alveolar cell carcinoma, the ^{67}Ga uptake sometimes did not match all the lesions demonstrated on chest radiography.

Detection of mediastinal metastases

The results of our series of 55 patients are shown in Tables 4 and 5. In patients with confirmed metastatic spread, conventional chest radiography had a true-positive rate (sensitivity) of only 66%. Conventional chest tomography increased the sensitivity to only 71%. In contrast to this, both CT and ^{67}Ga scanning had a sensitivity of 90%. When used in combination (CT plus ^{67}Ga), the sensitivity reached nearly 100%. An example is given in Fig. 1.

In patients where mediastinal involvement could be excluded, both chest radiography and conventional tomography of the mediastinum were negative in 32 of 34 cases (specificity=94%). In three cases (13%), CT yielded false-positive results (specificity=87%). In these cases mediastinal CT revealed enlarged lymph nodes (>1.5 cm) within the usual lymphatic drainage area of the tumor but malignancy could not be confirmed by mediastinoscopy or necropsy. In most cases with centrally located primary tumors, CT was better than ^{67}Ga scanning in discriminating between metastases and primary tumors. Thus, differentiation of centrally located primary tumors from mediastinal metastases was more difficult with ^{67}Ga scanning. False-positive results with ^{67}Ga , the lesions mimicking mediastinal tumor involvement, were observed in six cases (16%), yielding a specificity of 84%. In five of these cases no reason for the mediastinal ^{67}Ga uptake was identified. In one case

Table 4. Proven mediastinal spread ($n=21$)

Histologic type	<i>n</i>	True positive			
		Chest X-ray	Conventional tomography	CT	^{67}Ga
Squamous cell	5	3/ 5	3/ 5	3/ 3	4/ 5
Adeno cell	2	2/ 2	2/ 2		2/ 2
Small cell	9	6/ 9	6/ 9	5/ 6	9/ 9
Others	5	3/ 5	4/ 5	2/ 2	3/ 3
Total	21	14/21	15/21	10/11	18/20
Sensitivity		66%	71%	90%	90%

Table 5. No mediastinal spread ($n = 34$)

Histologic type	<i>n</i>	True negative			
		Chest X-ray	Conventional tomography	CT	⁶⁷ Ga
Squamous cell	11	10/11	10/11	7/ 7	8/11
Adeno cell	10	10/10	10/10	7/ 9	8/10
Small cell	3	3/ 3	3/ 3	1/ 1	1/ 2
Others	10	9/10	9/10	5/ 6	8/10
Total	34	32/34	32/34	20/23	25/33
Specificity		94%	94%	87%	75%

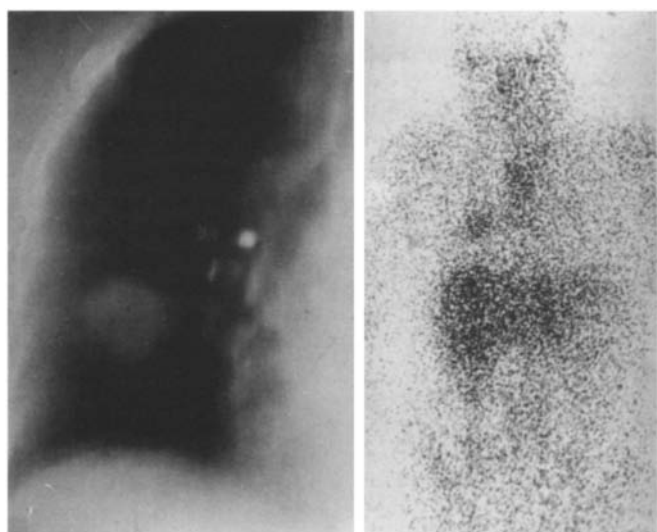


Fig. 1. Computed tomography and whole-body ⁶⁷Ga scan of a 46-year-old patient with primary non-small cell carcinoma of the middle lobe. Neither conventional chest X-ray nor radiographic chest tomography showed any signs of hilar or mediastinal metastases. ⁶⁷Ga scanning documented pathological uptake in the right hilum and in the mediastinum. Hilar (N1) and mediastinal (N2) metastases were confirmed by thoracotomy

mediastinal ⁶⁷Ga uptake due to nonspecific inflammatory reactions was observed after mediastinoscopy, performed 2 days prior to ⁶⁷Ga injection (see Fig. 2).

Discussion

Uptake in primary lung cancer

Gallium-67 uptake in the primary lesion is reported to occur in 64%–100% of patients (Edwards 1969; Vaidya 1970; Grebe 1971; Ito 1971; Higashi 1972; Van der Shoot 1972; Deland 1974; Hjelm 1975; Waxman 1986). Earlier reports suggest differences among various tumor types regarding ⁶⁷Ga uptake (Higashi 1972; Van der Shoot 1972; Deland 1974). Recent reports demonstrate that most histologic types of pulmonary carcinoma are associated with positive uptake of ⁶⁷Ga into primary lesions, provided the lesion is larger than 2–3 cm in diameter (Beckerman 1980; Waxman 1984, 1986).

Our series demonstrate that detectability depends on tumor size rather than on histology. Almost all lesions larger than 3 cm in diameter were gallium-avid. Lesions

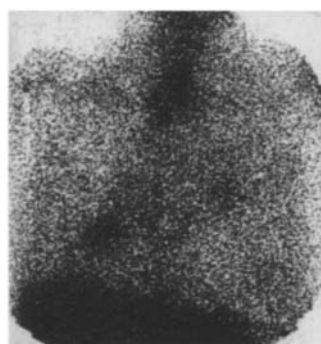

Fig. 2. ⁶⁷Ga camera scan of a patient with primary non-small cell carcinoma of the right medial lower lobe with hilar (N1) metastases. False-positive mediastinal ⁶⁷Ga uptake was due to recent mediastinoscopy (2 days prior to injection of ⁶⁷Ga). Mediastinal (N2) metastases were excluded by thoracotomy

that are larger than 3 cm on radiography and show no ⁶⁷Ga uptake have been reported to be suspicious of metastatic origin (De Meester 1978).

Many reports suggest that radiation therapy may drastically decrease gallium uptake in lung cancer (Edwards 1970; Vaidya 1970; Higashi 1972; Kinoshita 1974; Hjelm 1975; Bitran 1978).

In conclusion, there is little clinical value in investigating ⁶⁷Ga uptake in primary lung cancer. Uptake depends on size. Lesions smaller than 3 cm are hardly detectable. Previous radiotherapy alters the ⁶⁷Ga uptake of the tumor. Therefore, a therapeutic effect cannot reliably be monitored by ⁶⁷Ga scanning.

Mediastinal staging

Evaluation of mediastinum and hilum is essential for prediction of operability and prognosis in patients with lung cancer. Detection of involved mediastinal lymph nodes precludes curative resection. Mediastinoscopy, a conventional invasive technique, fails to document malignant mediastinal lymph nodes in 10%–30% of cases, despite its high specificity (Goldberg 1974; McKenna 1985).

In the past decade, most emphasis was therefore put on using gallium scans for detecting hilar and mediastinal metastases in patients with lung cancer (Deland 1976; Alazraki 1978; De Meester 1979; Fosburg 1979; Waxman 1982; Neumann 1981; Lunia 1981; Lesk 1982; McKenna 1985; Klech 1986a). However, there is considerable variation in the figures reported so far. The study by Alazraki et al.

Table 6. Mediastinal staging with ^{67}Ga scanning

	<i>n</i>	Sensitivity (%)	Specificity (%)
Alazraki et al. (1978)	25	100	71
Lesk et al. (1978)	34	89	67
Fosburg et al. (1979)	70	88	86
De Meester et al. (1979)	66	56	94
Neumann et al. (1981)	38	55	63
Lunia et al. (1981)	75	92	70
Waxman et al. (1984)	51	91	58
McKenna et al. (1985)	75	23	82
Klech et al. (1986)	55	90	75
Mean		76	74

(1978) compared ^{67}Ga scan results with mediastinoscopy findings in 25 patients with non-small cell carcinoma. The authors report 100% sensitivity and 71% specificity for detection of mediastinal involvement with ^{67}Ga , and conclude that a negative gallium scan precludes the need for mediastinoscopy and such patients may be directly referred to thoracotomy. This clear-cut result is not confirmed by other studies. Reported sensitivity ranges from 23% to 100%, while the range of specificity is 58%–94% (De Meester 1978; Alazraki 1978; Lesk 1978; Curto 1980; Neumann 1981; Lunia 1981; Waxman 1984; McKenna 1985) (see Table 6).

In contrast, De Meester et al. (1978) reported 56% sensitivity and 94% specificity. These results were subsequently confirmed by Richardson et al. (1980), who demonstrated sensitivity of 56% and specificity of 97% in the detection of lymph node metastases in the mediastinum.

These discrepant results reported by different investigators can be explained by the fact that basically different criteria were used to determine the sensitivity and specificity of the gallium scan. Alazraki et al. (1978) considered the scan positive if the hilar and/or mediastinal region showed increased gallium uptake. With this approach, the authors observed high sensitivity but relatively low specificity. We used the same criteria as Alazraki et al. in our study. The result is relatively high sensitivity of 90% and comparatively low specificity of 75%. De Meester et al. (1978) and Richardson et al. (1980) used a different set of criteria. Only an increase of ^{67}Ga uptake in the mediastinal region was considered positive. Hilar increase alone was considered negative for mediastinal involvement. Thus, patients with mere ipsilateral hilar or perihilar increase were considered negative, as were patients in whom no activity was demonstrated within the hilus. With this approach it is evident that when the mediastinum is evaluated selectively, the sensitivity of detection is low, while the specificity is high. Waxman et al. (1984) nicely demonstrated the divergent results with regard to sensitivity and specificity by applying these two different approaches to the same set of patients.

Therefore, the criteria used to define whether the gallium scan is positive or negative are the most important considerations when determining sensitivity and specificity of the test. It is probable that the results reported in the literature are in agreement; however, due to differences in the criteria for sensitivity and specificity they appear to be divergent. In 1985, McKenna et al. presented their study of 35 patients. The sensitivity was only 23% and the specificity was 82%. In contrast to previous studies, each pa-

tient underwent thoracotomy with total mediastinal node sampling. By these means, malignant mediastinal lymph node involvement was observed in five of 19 patients with negative mediastinoscopy prior to thoracotomy. In contrast to previous reports, McKenna et al. (1985) concluded that because of the low sensitivity, ^{67}Ga scanning cannot be recommended for preoperative staging. Although the authors' attempt to obtain the most exact diagnosis by complete mediastinal lymph node sampling is appreciated, the methods they applied, as well as their conclusion, may be subject to criticism:

1. Only some of the patients were scanned with a multiplex gamma camera, which is known to yield optimum resolution.
2. The authors evaluated only mediastinal ^{67}Ga uptake, which is known to result in comparatively low sensitivity. Since the route of metastases from the primary tumor to the mediastinal nodes is almost always via the hilar nodes, most patients will demonstrate hilar abnormalities before or coincident with detection of mediastinal disease (Nohe 1956). If the authors had defined hilar ^{67}Ga uptake as positive, the number of false negatives would perhaps have been smaller.
3. False-negative mediastinal ^{67}Ga scans were observed predominantly in patients in whom the mediastinal lymph nodes were not enlarged or not larger than 1 cm. Today many surgeons consider these patients as operable, and improvement of survival has been reported when surgery is combined with adjuvant therapy (Daly 1986).

CT scanning reportedly yields highly satisfactory results in staging the mediastinum in lung cancer (Daly 1984; Breyer 1984; Glazer 1984; Heelan 1985; Hajek 1985). Experience in our series of patients matches the published results. In centrally located tumors, CT scanning may discriminate better than gallium scanning between primary tumor and hilar or mediastinal lymph node metastasis. CT scanning provides valuable information when extent and size of lymph node metastasis is investigated with regard to localization of the lymphatic drainage of a tumor (Hajek 1985). In our series combined use of ^{67}Ga and CT yielded nearly 100% sensitivity.

In conclusion, mediastinal ^{67}Ga scanning should not be regarded as a routine investigation and should be used only in selected cases. Due to its high sensitivity, it is of clinical value in the management of lung cancer, provided the primary tumor shows uptake and both hilum and mediastinum are evaluated together.

In case of negative mediastinal uptake together with negative radiography and negative CT, the patient can be referred to thoracic surgery without explorative mediastinoscopy. A positive hilar or mediastinal uptake suggests mediastinoscopy prior to thoracotomy. CT scanning and ^{67}Ga scanning supplement each other very effectively: their combined use increases sensitivity to almost 100%.

Clinical management of malignant lymphoma

In the report of the cooperative study group (Johnston 1977), 88% of untreated Hodgkin patients had positive ^{67}Ga uptake at the site of the lesions. There is no marked difference in ^{67}Ga uptake with regard to the histologic type of Hodgkin lesions. Lesions smaller than 1 cm are difficult to assess, and once a patient has been treated the sensitivity decreases. Given these limitations to prove the involvement,

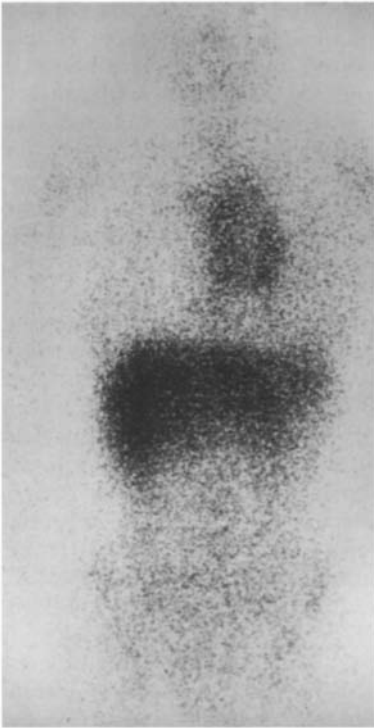


Fig. 3. ^{67}Ga scan of a 28-year-old patient with immunoblastic non-Hodgkin's lymphoma. Pathological ^{67}Ga uptake is seen in the mediastinum (matching a huge lymph tumor) and in the spleen

the ^{67}Ga scan is at least as sensitive and probably more sensitive than radiography in detecting mediastinal disease (Turner 1978). The sensitivity reported for Non-Hodgkin lymphoma is apparently lower, ranging from 50% in lymphocytic type Non-Hodgkin lymphoma to nearly 100% in Burkitt lymphoma (Turner 1978).

Gallium-67 scanning as a simple noninvasive procedure is helpful in follow-up studies of the course of a lymphoma-

tous disease after therapy (Henkin 1974; Turner 1978; Yang 1979; Yehn 1979). A positive gallium scan may be the first or only objective evidence of persistence or recurrence of treated diseases. Based on our experience and that of other authors, ^{67}Ga scanning can be of great value to detect recurrent disease in the mediastinum and lung, since postirradiation fibrosis can diminish the reliability of other imaging techniques as compared to gallium scintigraphy (see Figs. 3, 4a, b).

Detection of metastases of primary extrapulmonary tumor

The ^{67}Ga scan is less sensitive than chest radiography in detecting lung metastases of tumors that have a tendency toward pulmonary dissemination, such as breast cancer (Richman 1975) and soft tissue sarcoma. A sensitivity of 84% is reported for metastatic melanoma. Kirkwood et al. (1982) suggested ^{67}Ga scanning as a routine procedure in diagnostic staging and follow-up of patients receiving therapy for metastatic melanoma.

^{67}Ga Gallium scanning in "inflammatory disorders" of the lung

Since 1979 we have studied more than 500 patients with various inflammatory thoracic disorders by means of ^{67}Ga -imaging. In our series, special emphasis was placed on patients with interstitial lung diseases in order to examine the clinical usefulness of ^{67}Ga in these disorders (Table 7).

Sarcoidosis

Sarcoidosis is defined as a multisystem granuloma-forming disorder that nearly always involves the lung.

Various authors have proposed ^{67}Ga -imaging as an aid in the diagnosis, evaluation of disease activity, and the assessment of therapy (Heshiki 1974; Niden 1976; Siemsen

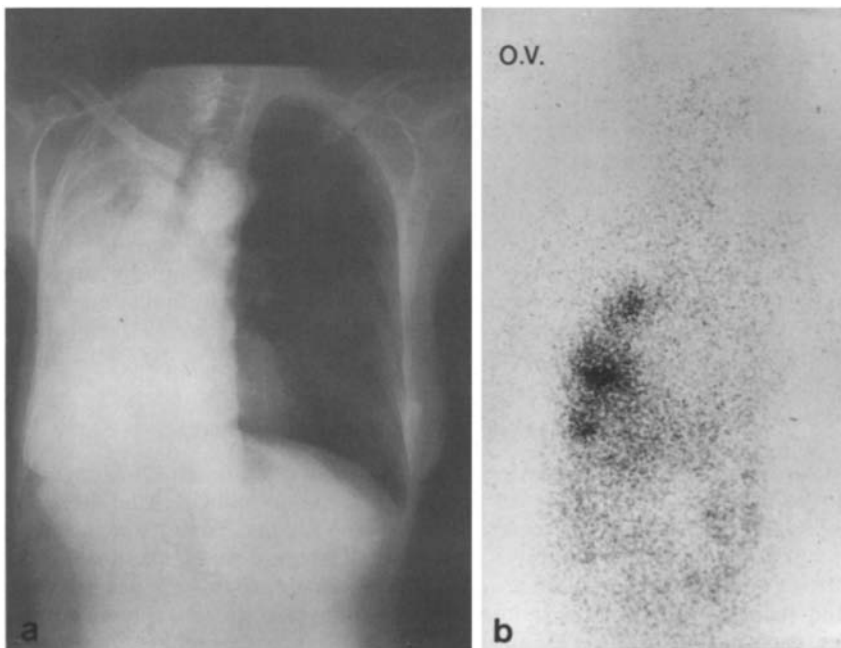


Fig. 4a, b. Chest radiograph (a) and ^{67}Ga scan (b) of a primary lymphocytic plasmacytoid Non-Hodgkin's lymphoma of the right lung which obstructs the right middle lobe and lower lobe bronchus, resulting in partial atelectasis of the lung

Table 7. Own patient series (1979–1986)

	<i>n</i>
Interstitial lung disorders	
Sarcoidosis	298
Idiopathic pulmonary fibrosis	32
Extrinsic allergic alveolitis	24
Pneumoconioses	16
Collagen vascular disorders	11
ARDS	6
Others	9
Infections	
Tuberculosis	
exudative	16
miliary	6
lymph nodes	14
<i>Pneumocystis carinii</i>	3
Bacterial pneumonia	27
Miscellaneous	
Pulmonary infarction, bronchitis, Emphysema, etc.	42
Total	504

1978; Nosal 1979; Line 1981, Schoenberger 1982; Beaumont 1982; Gupta 1982; Köhn 1982, Klech 1982, 1983a, b, c; Keogh 1983; Baughman 1984; Klech 1984, 1985b; Hollinger 1985; Mishkin 1985; Niden 1986; Israel 1986; Rizzato 1986).

⁶⁷Ga-Imaging as a diagnostic adjunct

⁶⁷Ga-Uptake depends on the extent and severity of the granulomatous inflammation in involved organs. Patients with active sarcoidosis usually accumulate ⁶⁷Ga in the hili and/or lung parenchyma. This may be accompanied by in-

creased ⁶⁷Ga-uptake in the salivary glands in up to 75% of patients (Mishkin 1978; Klech 1982). Although this finding is nonspecific, the combination of pulmonary and salivary gland uptake strongly suggests sarcoidosis (Klech 1986a).

Interestingly, most cutaneous sarcoid lesions will not take up ⁶⁷Ga, obviously due to insufficient granuloma mass (Lopez-Majano 1982). Only with extensive cutaneous involvement can significant ⁶⁷Ga-uptake be observed (Fig. 5a, b). Some authors consider ⁶⁷Ga a useful guide to optimal transbronchial tissue biopsy (Niden 1976), whereas others are not convinced of this strategy (Ackart 1982).

In summary, due to its low specificity, gallium imaging should not be used as a single diagnostic test for sarcoidosis. Diagnosis must be based primarily on histologic, laboratory, and clinical findings.

⁶⁷Gallium to assess disease activity

In established sarcoidosis, ⁶⁷Ga-imaging is today widely used as a supplement to evaluate the extent and activity of the granulomatous process. The clinical activity of pulmonary sarcoidosis was assessed by different means in 60 patients with sarcoidosis. In 94% of cases, ⁶⁷Ga demonstrated pathological uptake, whereas conventional chest radiography indicated active disease only in 80% (Köhn 1982; Klech 1982).

In a small series of seven patients who deteriorated from type I (bihilar sarcoidosis) to type II disease, as verified by transbronchial biopsy, ⁶⁷Ga was positive in all seven patients while chest radiography failed in four (Klech 1983a). Experienced clinicians and radiologists are well aware that chest radiography is problematic for the assessment of interstitial lung involvement (Epler 1978; DeRemee 1983). It is not possible to distinguish between active inflammation and irreversible fibrosis by means of chest radiography. To

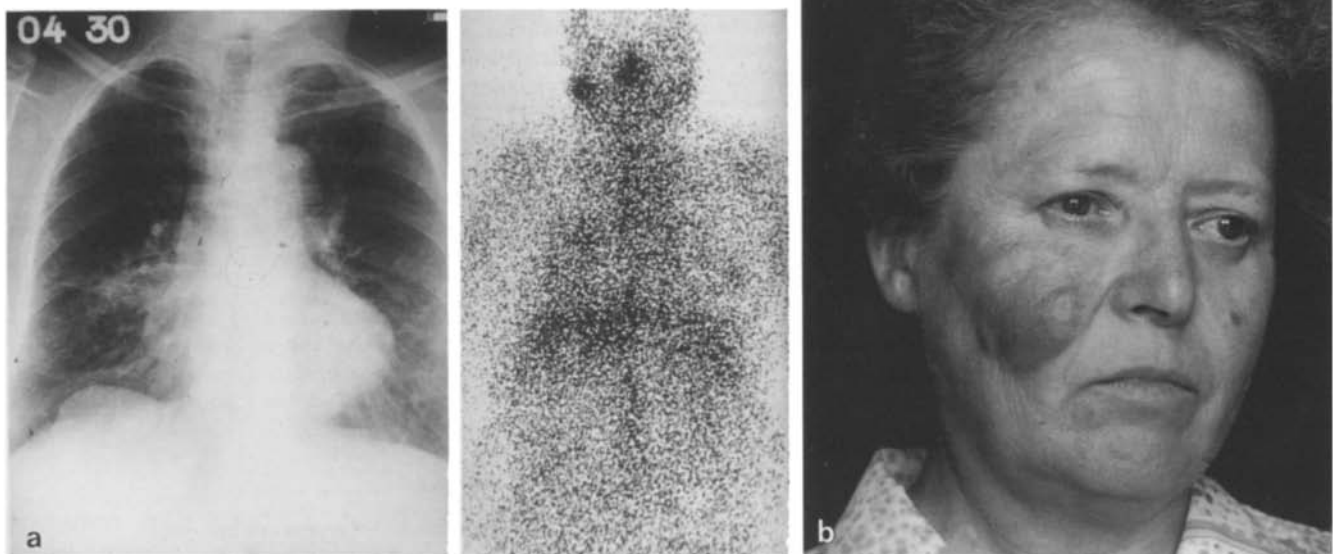



Fig. 5a, b. A 55-year-old female patient with chronic sarcoidosis, type-III, and a large cutaneous lesion on the right side of the face. ⁶⁷Ga-Scan reveals abnormal uptake in the lung, spleen, and at the site of the cutaneous lesion

Table 8. Pattern of thoracic ^{67}Ga -uptake in relation to disease activity in sarcoidosis

Thoracic ^{67}Ga -uptake	N	Sarcoid disease activity	
		Persisting or progressive	Inactive or regressive
No uptake	85	6%	94%
Hilar uptake	152	71%	29%
Lung uptake	61	64%	36%

 Steroid treatment

the clinician, the detection of pulmonary inflammation by ^{67}Ga can be of great importance.

Some authors emphasize the value of computer-based quantitation to improve the evaluation of diffuse pulmonary uptake, as well as to make therapeutic decisions (Line 1981; Rohatgi 1983; Unnik 1983; Bisson 1983; Wesselius 1983; Duffy 1986). This approach might be valuable in patients with diffuse homogeneous pulmonary granulomas, but the majority of pulmonary sarcoid lesions are not distributed homogeneously. We feel that if a semiquantitative score takes into account the regional distribution and intensity of gallium, sufficient information is provided for clinical routine care.

In patients with biopsy-proven sarcoidosis, we found a close correlation between a positive ^{67}Ga scan and the disease activity (Table 8). The ^{67}Ga -scan was negative in 94% of patients with inactive or regressive disease.

In recent years, other investigational means, such as serum angiotensin-converting enzyme (S-ACE) and bronchoalveolar lavage (BAL), have been widely used to assess disease activity. S-ACE has been found to be elevated in about 60% of patients with sarcoidosis (Studdy 1981). Comparing S-ACE to ^{67}Ga in terms of sensitivity and specificity, we found ^{67}Ga to be more sensitive than S-ACE (Köhn 1982; Klech 1982, 1983a, 1984). Both tests correlated significantly. Although other authors have reported similar findings, not all of them were able to demonstrate this correlation (Nosal 1979; Line 1981; Beaumont 1982; Gupta 1982; Schoenberger 1982; Rizzato 1986).

Other biochemical activity markers such as lysozyme, endopeptidase, procollagen-III-peptide, etc. are currently under investigation. We recently demonstrated a significant correlation between a ^{67}Ga -score and serum levels of gamma-interferon and neopterin (Köhn 1986). Activated T-lymphocytes, predominantly found in the alveoli of sarcoid patients, secrete gamma-interferon which, in turn, stimulates macrophages to release neopterin.

In recent years, considerable attention has been focused on BAL to determine whether it is possible to evaluate alveolar cellular changes earlier and more accurately with




feature	Alveolitis	Granuloma	Lung fibrosis
substrate	 T-Lymphocyte	 Epitheloid-Cells	
assessments	BAL	^{67}Ga -Gallium chest X-ray ACE BAL (lung function tests)	chest X-ray lung function tests

Fig. 6. Markers of disease activity corresponding to different features of granulomatous lung disorders

this method than with chest radiography. Line et al. (1981) have suggested that an activity index combining BAL (% lymphocytes) and ^{67}Ga -uptake be used to define low- and high-intensity alveolitis. This concept has been confirmed by other authors who also found a correlation between the percentage of BAL lymphocytes and ^{67}Ga -uptake (Huchon 1981; Fayman 1984). However neither we nor other authors have been able to confirm this finding (Beaumont 1982; Costabel 1983; Havranek 1983; Klech 1984; Baughman 1984).

The majority of centers contributing to a recent international survey on BAL in patients with sarcoidosis have reported a relationship between ^{67}Ga and the percentage of BAL lymphocytes rather than S-ACE (Klech 1986b), which reflects how difficult it is to compare data subject to variable modes of evaluation. The results of various activity markers probably correspond to different stages of the granulomatous reaction and are thus complementary rather than concordant. Each marker should be interpreted in light of its advantages and limitations regarding the assessment of pathophysiological processes in the course of the disease (Fig. 6).

^{67}Ga -Imaging to monitor the course of sarcoidosis and predict prognosis

Although the efficacy of corticosteroid therapy in altering the ultimate course of sarcoidosis and preventing progressive pulmonary fibrosis remains controversial, it is generally accepted that corticosteroids improve symptoms and induce remissions.

In the past, chest radiography and lung function tests were used as standard criteria for the long-term follow-up of patients on corticosteroid therapy. However, for short-time monitoring lung function tests in particular have proven to be too insensitive (Winterbauer 1980; Klech 1983b, c, d, 1984, 1985).

In a prospective clinical trial, we investigated the impact of different activity markers such as S-ACE and ^{67}Ga for monitoring therapeutic effects and assessing prognosis, in comparison with lung function tests and the information they may provide for the clinician.

Materials and methods

Twenty-seven patients (20–62 years of age, mean 38.8 years) were included who had histologically proven sarcoidosis. Of those, 16 were female and 11 male. Upon entering the study, the patients were evaluated by clinical findings, chest

radiography, lung function tests (total lung capacity, forced vital capacity), blood gas analysis at rest and during exercise S-ACE, and ^{67}Ga -imaging.

Each patient underwent serial follow-up assessments (mean 3, range 2–7) when significant disease activity changes were observed clinically; 69 follow-up assessments were classified as either deterioration, improvement, or as stable. All patients gave their informed consent.

The clinical symptoms were recorded by the attending physician. At the same time, laboratory data were assessed. Chest radiographs were scored according to standard criteria: type 0 = normal; type I = bilateral hilar adenopathy; type II = bilateral hilar adenopathy with pulmonary involvement; type III = pulmonary infiltration without hilar adenopathy. Deterioration was defined by the following criteria: marked deterioration of the chest X-ray, with or without clinical symptoms such as dyspnea, cough, fever, chest pain, arthralgia, etc. These criteria were met in 15 follow-up assessments.

Improvement was only defined when there was marked amelioration of the chest X-ray, together with improvement in or lack of clinical symptoms. Criteria for improvement were met in 29 follow-up assessments. In all other instances, the disease was regarded as stable. The majority of patients did not receive corticosteroid therapy during the study. If steroids had to be prescribed, treatment was stopped 1 week prior to follow-up assessment. Lung function was measured by means of a body-plethysmograph (Jaeger, FRG) in terms of vital capacity (VC) and total lung capacity (TLC). Blood gas analysis was measured by arterial puncture (radial artery) at rest and after exercise (75 W/5 min bicycle or treadmill exercise) and expressed as the alveolar-capillary oxygen difference (AaDO_2) using the formula:

$$\text{AaDO}_2 = \left[P_{i\text{O}_2} - \left(\frac{P_{\text{aCO}_2}}{RQ} \right) \right] - P_{\text{aO}_2}$$

^{67}Ga -Scans were scored independently by two experienced observers and graded 0–3, comparing the lung activity with that in the liver and shoulders (Köhn 1982; Klech 1982). S-ACE was measured photometrically according to the method of Cushman and Cheung as modified by Lieberman (1976) (normal range ≤ 24 U/ml).

For statistical analysis, Spearman's rank correlation coefficient was used as well as Wilcoxon's nonparametric test to compare follow-up assessments.

Results

Instances of deterioration ($n=15$)

AaDO_2 at rest and exercise showed the most significant changes. AaDO_2 at rest increased by more than 10% in 87% and during exercise in 60%. S-ACE increased in 85% and showed no change or even decreased in 15%. The ^{67}Ga -score increased in 66% and remained unchanged in 34%. In no case was ^{67}Ga -uptake diminished compared with previous scans (Fig. 7). We could demonstrate no significant correlation between changes of ^{67}Ga and ACE or lung function and AaDO_2 .

Instances of improvement ($n=29$)

The ^{67}Ga -score decreased significantly with clinical improvement ($P < 0.001$). Improvement in the ^{67}Ga -scan was

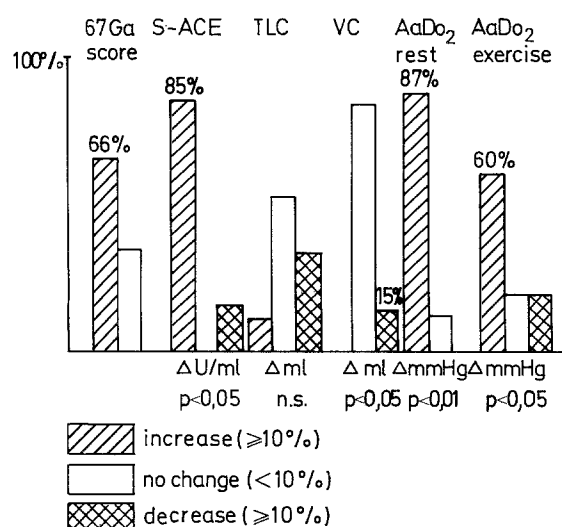


Fig. 7. Changes of parameters after recent deteriorations ($n=15$)

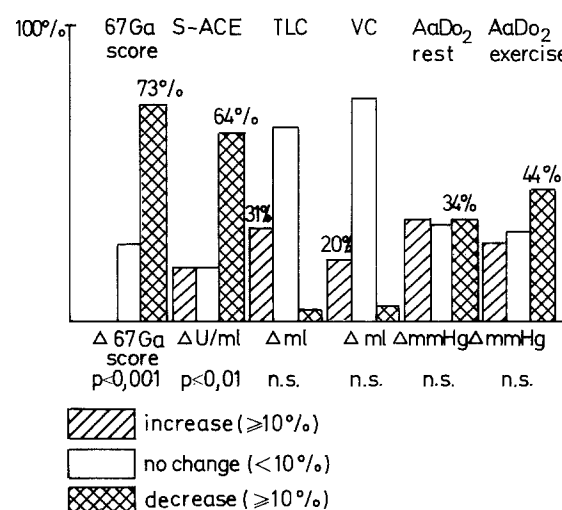


Fig. 8. Changes of parameters after improvement of pulmonary sarcoidosis ($n=29$)

observed in 73%. In 27%, the gallium score remained unchanged. ACE decreased markedly in 64% of instances, but remained unchanged in 18% and increased in 16%. Changes in lung function were insignificant, VC improved in only 31%, and TLC only improved in 20% of cases. Changes in blood gases were also insignificant for the documentation of improvement (Fig. 8). Loose, but significant correlations were found between the decrease of S-ACE and increase of VC ($r_s = 0.59$, $P < 0.01$) or decrease of AaDO_2 during exercise ($r_s = 0.54$, $P < 0.05$).

Discussion

The results of this study confirm the limited clinical value of lung function studies (Winterbauer 1980), particularly for follow-up assessments of patients with pulmonary sarcoidosis (Klech 1983b, c, d, 1984, 1985).

Obviously, in the majority of sarcoidosis patients deterioration of blood gas analysis is due to reversible air-flow limitation and an inequality in the distribution of ventilation caused by mucosal swelling and endobronchial granu-

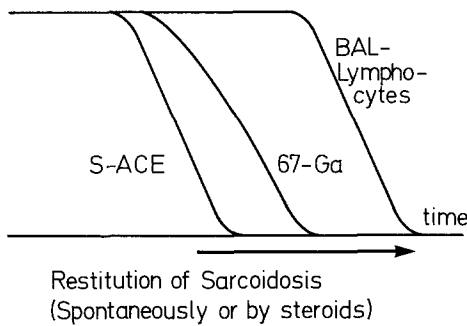


Fig. 9. Decrease of activity markers according to improvement of sarcoidosis

loma formation, rather than by irreversible fibrotic changes in the pulmonary interstitium. Therefore, blood gas analysis at rest and during exercise is a sensitive indicator of actual clinical deterioration, but has no prognostic significance for the long-term course of the disease. Lung function tests, particularly VC, reliably document irreversible impairments, but have no value for making short-term therapeutic decisions. Diffusing capacity (DLCO) has been proposed to monitor lung function in sarcoidosis. However, concomitant airflow limitation restricts reliable interpretation and reversible airflow limitation is a common feature in patients with pulmonary sarcoidosis.

We used chest radiography as the standard criterion for assessment since it is widely used in clinical practice. Only those instances that clearly showed deterioration or improvement in the chest X-ray were selected for further assessments.

At present, based on experience with new activity markers, the clinician's opinion on the value of chest radiography has been modified (Kleeh 1982; DeRemee 1983; Rizzato 1986). However, the clinical value of S-ACE, ^{67}Ga -imaging and BAL for follow-up assessments is controversial (Keogh 1983; Lawrence 1983; Baughman 1984; Hollinger 1985). This may be due to the variable modes of evaluation or to the fact that these markers measure different sarcoidosis features. Therefore, changes in disease activity are not reflected in the same manner by different markers. If there is improvement, the S-ACE values decrease first, followed by an improvement in ^{67}Ga ; however, lymphocyte counts in BAL remain elevated for a longer period of time (Fig. 9).

At our institution, the following strategy is used for clinical follow-up and therapeutic decisions (Fig. 10). Chest radiography and S-ACE levels are still the standard criteria. ^{67}Ga Imaging is initially commonly performed in patients with pulmonary involvement (type II or III), but later on is limited to selected cases. In the past there has been much concern about the costs, availability and radiation load of ^{67}Ga (Whitcomb 1984). Using 3 mCi ^{67}Ga -citrate, the radiation load does not exceed that of a chest tomography or a CT study. However, in young patients there should be a strong indication. The successful use of low dosage gallium imaging (1.5 mCi) was reported by Rizzato et al. (1986).

In conclusion, ^{67}Ga -imaging provides information about the spread and extent of the disease and permits the progression to be followed at each site of involvement. ^{67}Ga is more sensitive than chest radiography and when used selectively, is of reasonable value for follow-up and making therapeutical decisions in pulmonary sarcoidosis within the framework of other activity markers.

Interstitial lung disorders

Idiopathic pulmonary fibrosis (IPF)

Line et al. (1978) have used ^{67}Ga , together with BAL, to stage IPF and have reported a close correlation between a ^{67}Ga index and the inflammatory cell reaction in the lung, particularly the neutrophil counts in BAL. However, the clinical features correlated poorly with the ^{67}Ga indices. The results were essentially corroborated by Niden et al. (1984).

In our group of patients ($n=32$), only a minority had an abnormal ^{67}Ga uptake that was unrelated to BAL cell counts. In IPF, ^{67}Ga probably accumulates only when there is acute neutrophil alveolitis at a stage where therapeutic improvement can be expected.

Extrinsic allergic alveolitis

In our series of patients ($n=24$), ^{67}Ga -uptake was only observed after recent exposure to the causative antigen (Fig. 11). Acute exogenous allergic alveolitis is characterized by T-helper cell alveolitis, often associated with interstitial granuloma formation, which can be very similar to

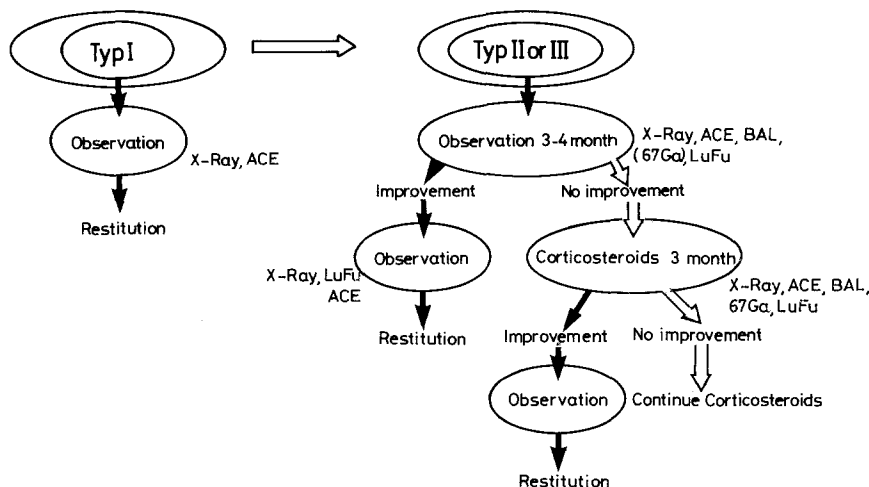


Fig. 10. Diagram of rational strategy for follow-up and therapeutical decisions in patients with sarcoidosis

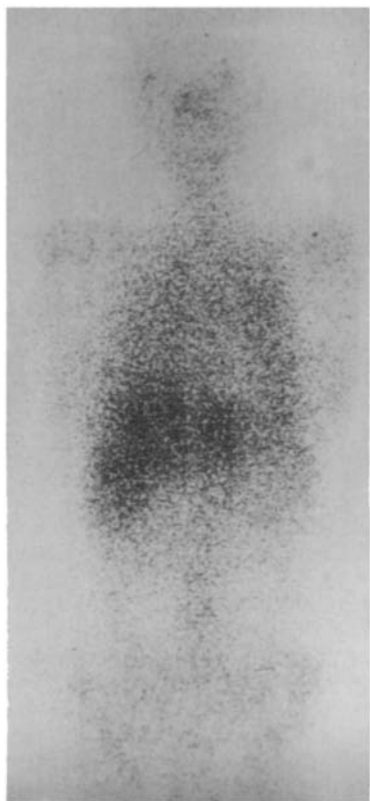


Fig. 11. A 28-year-old farmer with proven exogenous allergic alveolitis (farmer's lung). ^{67}Ga -Scan shows abnormal lung uptake. Imaging was performed immediately after extensive exposure to moldy hay dust

that seen in sarcoidosis (Kleeh 1986a). Absence of antigen exposure for 4–6 weeks will normalize the gallium scan.

Pneumoconiosis and collagen vascular disorders

Siemsen et al. (1974) first described diffuse pulmonary ^{67}Ga -uptake in 110 patients with pneumoconiosis and reported the ^{67}Ga scan to be more sensitive than chest radiography to document lung involvement. In a small group of patients ($n=16$), we found abnormal ^{67}Ga uptake only in patients who had been exposed to the antigen the 3 months before imaging. Talc and beryllium pneumoconiosis shows a ^{67}Ga uptake that is similar to that of sarcoidosis (Brown 1984; Niden 1984). We studied 11 patients with collagen vascular disorders. Four of 6 patients with lung involvement due to rheumatoid arthritis had an abnormal ^{67}Ga -uptake. Only 1 patient out of 3 with pulmonary lupus erythematoses (LE) showed lung uptake. However, pulmonary manifestations of LE are generally mild.

^{67}Ga has been used to assess pulmonary damage caused by pharmaceuticals such as nitrofurantoin (Crook 1982) or bleomycin (Richman 1975) and other antitumor drugs (McMahon 1978). Lung damage could be localized better by ^{67}Ga than by chest radiography in most cases.

Pulmonary lesions associated with adult respiratory distress syndrome (ARDS) accumulate gallium in the acute stage due to interstitial neutrophilic inflammation rather than to a nonspecific increase in the alveocapillary permeability of gallium (Passamonte 1984). As soon the neutrophilic inflammation subsides – mostly with the development

of interstitial lung fibrosis – abnormal ^{67}Ga -uptake is rarely seen. Therefore, four of six patients with ARDS who were scanned later than 8 weeks after the lung injury no longer had abnormal ^{67}Ga uptake.

Infectious diseases of the lung

Siemsen et al. (1978) and Bekerman et al. (1980) have reported ^{67}Ga to be useful for the diagnosis of virtually all pulmonary inflammations, including pneumonia, lung abscess, tuberculosis, and *Pneumocystis carinii* infection. Thadepalli et al. (1978) have found a close correlation between bacteriologically confirmed pulmonary infections and abnormal pulmonary ^{67}Ga -uptake. However, Walsh et al. (1985) have recently raised the question of whether ^{67}Ga -imaging can be recommended for the assessment of tuberculosis activity due to its low specificity (only 27%). They concluded that ^{67}Ga cannot be used reliably to distinguish between active or inactive tuberculosis. Our results are in agreement with these findings. Serial chest radiographs, together with sputum smears or bronchoscopy, provide sufficient information. ^{67}Ga may be useful in patients with lymph node tuberculosis. In patients with miliary tuberculosis, ^{67}Ga was positive in only four of six cases.

Nonspecific lung disorders such as pulmonary infarction, bronchitis, etc. inconsistently accumulate ^{67}Ga , depending on the size and nature of the underlying inflammation. ^{67}Ga -imaging has been reported to be helpful in the differential diagnosis of pneumonias or pulmonary infarctions (Niden 1977). However, specific diagnosis seems not to be possible (Brown 1983).

Acquired immune deficiency syndrome (AIDS)

Opportunistic lung infections caused by *Pneumocystis carinii*, cytomegalovirus, and mycobacterium avium-intracellulare are common in patients with AIDS. Since these infections are known to accumulate ^{67}Ga , even without evidence of lesions in the chest X-ray (Levenson 1976; Turbner 1978; Hamed 1979), at present ^{67}Ga imaging is of particular value in the clinical management of AIDS. We saw an increase in diffuse ^{67}Ga -uptake in both lungs in two cases of opportunistic infection due to *P. carinii* and in one with cytomegalovirus infection in spite of negative chest X-ray findings. ^{67}Ga -Imaging has been recommended as a sensitive initial diagnostic test in AIDS patients suspected of having an opportunistic infection. It helps to localize the involved lung areas as a guide for diagnostic bronchoalveolar lavage and transbronchial tissue biopsy (Levin 1983; Coleman 1984).

References

- Ackart RS, Munzel TL, Rodriguez JJ, Donlan CJ, Klayton RJ, Foreman DR (1982) Efficacy of ^{67}Ga -scintigraphy in predicting the diagnostic yield of transbronchial lung biopsy in pulmonary sarcoidosis. *Chest* 82:7–9
- Alazraki NP, Ramsdell JW, Taylor A, Friedman PJ, Peters RM, Tisi GM (1978) Reliability of gallium scan, chest radiography compared with mediastinoscopy for evaluating mediastinal spread in lung cancer. *Am Rev Respir Dis* 117:415–420
- Baughman RP, Fernandez M, Bosken CH (1984) Comparison of gallium-67 scanning, bronchoalveolar lavage and serum angiotensin converting enzyme levels in pulmonary sarcoidosis. *Am Rev Respir Dis* 129:676–681

- Beaumont D, Herry SY, Sapene M, Bourget P, Larzul JJ, DeLa-berthe B (1982) Gallium 67 in the evaluation of sarcoidosis: correlation with serum angiotensin converting enzyme and bronchoalveolar lavage. *Thorax* 37:11-18
- Bekerman C, Hoffer PB, Bitran JD, Gupta RG (1980) Gallium-67 citrate imaging studies of the lung. *Semin Nucl Med* 10:286-301
- Bisson G, Drapeau G, Lamoureux G, Cantin A, Rola-Pleszczynski M, Begin R (1983) Computer based quantitative analysis of gallium-67 uptake in normal and diseased lungs. *Chest* 84:513-517
- Bitran JD, DeMeester TR, Rezai-Zadeh K, Toledo-Pereya LH, Churg A, Columb HM (1978) Clinicopathologic correlation demonstrating the failure of 67 gallium scanning in determining response to radiotherapy. *Chest* 73:356-359
- Breyer RH, Karstaedt N, Mills SA, Johnston FR, Choplin RH, Wolfman NT (1984) Computed tomography for evaluation of mediastinal lymph nodes in lung cancer: correlation with surgical staging. *Ann Thorac Surg* 38:215-220
- Brown DG, Aguirre A, Weaver A (1980) 67 Gallium scanning in talc-induced pulmonary granulomatosis. *Chest* 77:561-565
- Brown JM, Moreno AJ, Weisman I, Baker FJ, Lundy MN, Brown TJ (1983) Positive gallium 67 scintigraphy associated with pulmonary embolism. *Chest* 84:233-235
- Coleman DL, Hettner RS, Luce JM, Dadek PM, Golden JA, Murray JF (1984) Correlation between gallium lung scans and fiberoptic bronchoscopy in patients with suspected *Pneumocystis carinii* pneumonia and the acquired immune deficiency syndrome. *Am Rev Respir Dis* 130:1166-1169
- Costabel U, Bross KJ, Fischer J, Guzman J, Matthys H (1983) Die Bedeutung der Helfer-T-Lymphozyten in der bronchoalveolären Lavage für die Aktivitätsbeurteilung der pulmonalen Sarkoidose. *Prax Klin Pneumol* 37:574-577
- Crook MJ, Kaplan PD, Adatepe MH (1982) Gallium 67 scanning in nitrofurantoin-induced pulmonary reaction. *J Nucl Med* 23:690-692
- Curto LM, Castro OM, Rull G, Cueto A, Alenia JG, Caballero C (1980) Value of mediastinic scintigraphy with Ga-67 in the study of lung cancer extension (abstract). *Eur J Nucl Med* 5:27
- Daly BDT, Faling LJ, Pugatch RD, Jung-Legg Y, Gale ME, Bite G (1984) Computed tomography. An effective technique for mediastinal staging in lung cancer. *J Thorac Cardiovasc Surg* 88:486-494
- Daly BDT, Faling LJ, Gale ME, Jung-Legg Y, Snider GL, Korp DD, Chang H (1986) Staging with CT. *Chest* 90:926-927
- Deland FH, Sauerbrunn BJ, Boyd C, Wilkinson RH, Friedman BI, Moinuddin M, Preston DF, Knisely RM (1974) 67 Ga citrate imaging in untreated primary lung cancer. Preliminary report of the cooperative group. *J Nucl Med* 15:408-411
- DeMeester DR, Golomb HM, Kirchner P, Rezai-Zadeh K, Bitran JD, Streeter DL, Hoffman PC, Cooper M (1979) The role of Ga-67 scanning in the clinical staging and preoperative evaluation of patients with carcinoma of the lung. *Ann Thorac Surg* 28:451-464
- DeRemee RA (1983) The roentgenographic staging of sarcoidosis: historical and contemporary perspective. *Chest* 83:128-133
- Duffy GJ, Thirumurthi K, Casey M, Barker F, Odlum C, Fitzgerald MX (1986) Semi-quantitative gallium-67 lung scanning as a measure of the intensity of alveolitis in pulmonary sarcoidosis. *Eur J Nucl Med* 12:187-191
- Edwards CL, Hayes RL (1969) Tumor scanning with 67 gallium citrate. *J Nucl Med* 10:103-105
- Edwards CL, Hayes RL (1970) Scanning malignant neoplasms with gallium-67. *JAMA* 212:1182-1190
- Epler GR, McLond TC, Gaensler EA (1978) Normal chest roentgenograms in chronic diffuse infiltrative lung disease. *N Engl J Med* 298:934-939
- Fayman WA, Greenwald LV, Staton G (1984) Quantitative 67 gallium citrate lung imaging in sarcoidosis: comparison of three methods and correlation with bronchoalveolar lavage. *AJR* 142:683-688
- Fosburg RG, Hopkins G, Kan MK (1979) Evaluation of the mediastinum by gallium-67 scintigraphy in lung cancer. *J Thorac Cardiovasc Surg* 77:76-82
- Glazer GM, Orringer MB, Gross BH, Quint LE (1984) The mediastinum in non-small cell lung cancer: CT surgical correlation. *AJR* 142:1101-1105
- Goldberg EM, Shapiro CM, Glickman HS (1974) Mediastinoscopy for assessing mediastinal spread in clinical staging of lung cancer. *Semin Oncol* 1:205-212
- Gupta RG, Bekerman C, Sicilian L, Oparil S, Pinsky SM, Szidon JP (1982) Gallium 67 citrate scanning and serum angiotensin converting enzyme levels in sarcoidosis. *Radiology* 144:895-899
- Hamed IA, Wenzl JE, Leonard JC, Altshuler GP, Pederson JA (1979) Pulmonary cytomegalovirus infection. Detection by gallium 67 imaging in the transplant patient. *Arch Intern Med* 139:286-288
- Hajek P, Imhof H, Kumpan W, Schratler M, Klech H, Moritz E (1985) Mediastinales Staging von Bronchuskarzinomen. *Fortschr Roentgenstr* 142:74-79
- Havranek V, Klech H, Rona G, Hubner M (1983) Die bronchoalveoläre Lavage (BAL) bei pulmonaleer Sarkoidose. *Wien Med Wochenschr [Suppl 133]* 75:42
- Heelan RT, Martini N, Westcott JW, Bains MS, Watson RC, Caravelli JF (1985) Carcinomatous involvement of the hilum and mediastinum: computed tomographic and magnetic resonance evaluation. *Radiology* 156:111-115
- Henkin RE, Polcyn RE, Quinn JL (1974) Scanning treated Hodgkin's disease with 67 Ga citrate. *Radiology* 110:151-154
- Heshiki A, Schatz SL, McKusick KA (1974) Gallium-67 citrate scanning in patients with pulmonary sarcoidosis. *Am J Roentgenol Radium Ther Nucl Med* 122:744-749
- Hjelms E, Dyrbye M (1975) Uptake of 67 Ga in malignant lesions of the lung and lymphatic tissue. *Scand J Respir Dis* 56:251-258
- Hoffer PB (1978) Mechanism of localisation: In: Hoffer PB, Bekerman C, Henkin RE (eds) Gallium-67 imaging. John Wiley and Sons, New York, pp 3-11
- Hoffer PB (1980) Gallium: mechanisms. *J Nucl Med* 21:282-285
- Hollinger WM, Staton GW, Fajman WA, Gilman MJ, Pine JR, Check IJ (1985) Prediction of therapeutic response in steroid-treated pulmonary sarcoidosis. *Am Rev Respir Dis* 132:65-69
- Huchon GJ, Berrisouk F, Barritoult LG, Venot A, Marsac J, Ronceayrol JC, Chretien J (1983) Comparison of bronchoalveolar lavage and gallium-67 lung scanning to assess the activity of pulmonary sarcoidosis. In: Chretien J, Marsac J, Saltiel JC (eds) Sarcoidosis and other granulomatous disorders. Pergamon Press, Paris, pp 440-445
- Israel HL, Gushne GF, Park CH (1986) Assessment of gallium 67 scanning in pulmonary and extrapulmonary sarcoidosis. *Ann NY Acad Sci* 465:455-462
- Ito Y, Okuyama S, Awano T (1971) Diagnostic evaluation of 67 Ga scanning in lung cancer and other diseases. *Radiology* 101:355-362
- Johnston GS, Go MF, Benua RS, Larson SM, Andrews GA, Hubner KF (1977) Gallium-67 citrate imaging in Hodgkin's disease: final report of the cooperative group. *J Nucl Med* 18:692-698
- Keogh BA, Hunninghake GW, Line BR, Crystal RG (1983) The alveolitis of pulmonary sarcoidosis: evaluation of natural history and alveolitis dependent changes in lung function. *Am Rev Respir Dis* 128:256-265
- Kinoshita F, Ushio T, Maekawa A, Ariwa R, Kubo A (1974) Scintiscanning of pulmonary diseases with 67 Ga citrate. *J Nucl Med* 15:227-233
- Kirkwood JM, Myers JE, Vlock DR, Neumann RD, Hoffer PB, Gottschalk A (1982) Tomographic gallium-67 citrate scanning: useful new surveillance for metastatic melanoma. *Ann Intern Med* 97:694-696
- Klech H (1986) Sarcoidosis: differential diagnosis. *Semin Respir Med* 8:72-94

- Kleeh H, Köhn H, Kummer F, Mostbeck A (1982) Assessment of activity in sarcoidosis. *Chest* 82:732-738
- Kleeh H, Köhn H, Pohl W, Kummer F, Mostbeck A (1983a) Aktivitätsdiagnostik der Sarkoidose. *Wien Med Wochenschr* 133:425-431
- Kleeh H, Witek F, Koehn H, Pohl W (1983b) Pulmonary function tests (PTF) compared to 67 gallium scintigraphy and S-ACE for monitoring recurrent pulmonary sarcoidosis. *Am Rev Respir Dis* 127:4 (abstract)
- Kleeh H, Pohl W, Hubner M, Koehn H, Kummer F (1983c) How to monitor recurrent pulmonary sarcoidosis. Value of serial lung function tests, S-ACE and 67 Ga scanning. *Eur J Respir Dis [Suppl 126]* 64:580 (abstract)
- Kleeh W, Witek F, Hubner M, Pohl W (1983d) Verlauf der Lungenfunktion bei pulmonaler Sarkoidose. *Wien Med Wochenschr [Suppl 133]* 74:23-24
- Kleeh H, Koehn H, Pohl W, Kummer F (1984) Sensitivity and specificity of 67 Ga scanning, bronchoalveolar lavage (BAL) chest radiography and lung function tests (LFT) for assessment of activity in patients with pulmonary sarcoidosis. *Respiration* 46:1 (abstract)
- Kleeh H, Huppmann M, Hajek P, Imhof H, Köhn H (1986a) Value of 67 gallium scanning, computed tomography and chest radiography for non invasive mediastinal staging of bronchogenic carcinoma. *Eur J Respir Dis [Suppl 146]* 6P:A83
- Kleeh H, Haslam P, Turner-Warwick M (1986b) World wide clinical survey on bronchoalveolar lavage (BAL) in sarcoidosis. Experience in 62 centers in 19 countries. *Sarcoidosis* 3:113-122
- Kleeh H, Koehn H, Witek F, Mostbeck A, Kummer F (1985) Serial S-ACE and 67 Ga scanning supplement best routine chest radiography for monitoring recurrent pulmonary sarcoidosis. *Sarcoidosis* 2:72-73
- Köhn H, Kleeh H, Mostbeck A, Kummer F (1982) 67 Ga scanning for assessment of disease activity and therapy decisions in pulmonary sarcoidosis in comparison to chest radiography, serum ACE and blood T-lymphocytes. *Eur J Nucl Med* 7:413-416
- Köhn H, Pohl W, Woloszczuk W, Kleeh H (1986) Gamma interferon and neopterin for assessment of activity in sarcoidosis. *Sarcoidosis* 3:156 (abstract)
- Larson SM (1978) Mechanisms of localisation of gallium-67 in tumors. *Semin Nucl Med* 8:193-204
- Lawrence EC, Teague RB, Gottlieb MS, Shingran SG (1983) Serial changes in markers of disease activity with corticosteroid treatment in sarcoidosis. *Am J Med* 74:747-756
- Lesk DM, Wood TE, Carrol SE, Reese L (1978) The application of 67 Ga scanning in determining the operability of bronchogenic carcinoma. *Radiology* 128:707-711
- Levenson SM, Warren RD, Richman SD, Johnston GS, Chabner BA (1976) Abnormal pulmonary 67 gallium accumulation in *P. carinii* pneumonia. *Radiology* 119:395-398
- Levin M, McLead R, Young Q, Abrahams C, Chambliss C, Walzer P, Katin SA (1983) Pneumocystis pneumonia: Importance of gallium scan for early diagnosis and description of a new immunoperoxidase technique to demonstrate *Pneumocystis carinii*. *Am Rev Respir Dis* 128:182-185
- Lieberman J (1975) Elevation of serum angiotensin converting enzyme (S-ACE) level in sarcoidosis. *Am J Med* 59:365-372
- Line BR, Fulmer JD, Reynolds HY, Roberts WC, Jones AE, Harris EK, Crystal RG (1978) Gallium 67 citrate scanning in the staging of idiopathic pulmonary fibrosis: correlation with physiologic and morphologic feature and bronchoalveolar lavage. *Am Rev Respir Dis* 118:355-365
- Line BR, Hunninghake GW, Keogh BA, Jones AE, Johnston GS, Crystal RG (1981) Gallium-67 scanning to stage the alveolitis of sarcoidosis: correlation with clinical studies, pulmonary function studies and bronchoalveolar lavage. *Am Rev Respir Dis* 123:440-446
- Lopez-Majano V, Sansi P (1982) Gallium uptake in cutaneous sarcoidosis. *Eur J Nucl Med* 7:95-96
- Lunia MD, Ruckdeschel JC, McKneally MF, Killam D, Baxter D (1981) Noninvasive evaluation of mediastinal metastases in bronchogenic carcinoma. *Cancer* 47:672-676
- McKenna RJ, Haynie TP, Libshitz HI, Mountain CF, McMurtrey MJ (1985) Critical evaluation of the gallium 67 scan for surgical patients with lung cancer. *Chest* 87:428-431
- McMahon MB, Bekerman C (1978) The diagnostic significance of gallium lung uptake in patients with normal chest radiographs. *Radiology* 127:189-193
- Mishkin FS, Niden AH (1985) Clinical application of 67 gallium citrate lung imaging in sarcoidosis. In: Lieberman J (ed) *Sarcoidosis*. Grune & Stratton, Orlando, Florida, pp 161-178
- Mishkin FS, Tanaka TT, Niden AH (1978) Abnormal gallium scan patterns of the salivary gland in pulmonary sarcoidosis. *Ann Intern Med* 89:933-934
- Neumann RD, Sostman HD (1984) 67 Ga scintigraphy of the thorax. *Chest* 86:253-256
- Neumann RD, Hoffer PB, Merino MJ, Kirkwood JM, Gottschalk A (1981) Clinical value of gallium 67 in imaging patients with lung carcinoma and melanoma. *Med Radionucl Imaging* 2:475-486
- Niden AH, Mishkin FS (1984) Diffuse infiltrative lung disease. In: Atkins HE (ed) *Pulmonary nuclear medicine*. Marcel Dekker, New York Basel, pp 167-200
- Niden AH, Mishkin FS, Khurana MM (1976) Gallium-67 citrate lung scans in interstitial lung disease. *Chest* 69:266-268
- Niden AH, Mishkin FS, Khurama MML, Rick R (1977) 67 gallium lung scan. An aid in the differential diagnosis of pulmonary embolism and pneumonitis. *JAMA* 237:1206-1211
- Niden AH, Mishkin FS, Salem F, Thomas Jr AV, Kandor V (1986) Prognostic significance of gallium lung scans in sarcoidosis. *Ann NY Acad Sci* 465:435-443
- Nohe HC (1956) An investigation into the lymphatic and vascular spread of carcinoma of the bronchus. *Thorax* 2:171-185
- Nosal A, Schleissner LA, Mishkin FS (1979) Angiotensin-I-converting enzyme and gallium scan in non-invasive evaluation of sarcoidosis. *Ann Intern Med* 90:328-331
- Passamonte PM, Martinez AJ, Singh A (1984) Pulmonary gallium concentration in the adult respiratory distress syndrome. *Chest* 85:828-830
- Richardson JV, Zenk BA, Rossi NP (1980) Preoperative noninvasive mediastinal staging in bronchogenic carcinoma. *Surgery* 88:382-385
- Richman SD, Ingle JN, Levenson SM (1975a) Usefulness of gallium scintigraphy in primary and metastatic breast cancer. *J Nucl Med* 16:996-1001
- Richman SD, Levenson SM, Bisun PA (1975b) Gallium accumulation in pulmonary lesion associated with bleomycin toxicity. *Cancer* 36:1966-1972
- Rizzato G, Blasi A (1986) An European survey on the usefulness of 67 Ga lung scans in assessing sarcoidosis. Experience in 14 research centers in seven different countries. *Ann NY Acad Sci* 465:463-478
- Rohatgi PK, Baier H (1983) Quantitative gallium scanning in pulmonary sarcoidosis. *Respiration* 44:304-313
- Schoenberger CI, Line BR, Keogh BA, Hunninghake GW, Crystal RG (1982) Lung inflammation in sarcoidosis: comparison of serum angiotensin converting enzyme levels with bronchoalveolar lavage and gallium-67 scanning assessment of the T-lymphocyte alveolitis. *Thorax* 37:19-25
- Siemsen JK, Sargent EN, Grebe SF, Winsor DW, Wentz D, Jacobsen G (1974) Pulmonary concentration of 67 Ga in pneumoconiosis. *Am J Roentgenol Radium Ther Nucl Med* 120:815-820
- Siemsen JK, Grebe SF, Waxman AD (1978) The use of gallium 67 in pulmonary disorders. *Semin Nucl Med* 8:235-249
- Thadepalli H, Rambhatla K, Mishkin FS (1978) Correlation of microbiologic findings and gallium 67 scans in patients with pulmonary infections. *Chest* 72:442-448
- Turbiner EH, Yeh SDJ, Rosen PP, Banis MS, Benna RJ (1978) Abnormal gallium scintigraphy in *Pneumocystis carinii* pneumonia with a normal chest radiograph. *Radiology* 127:437-438
- Turner DA, Fordham EW, Slayton RE (1978) Malignant lym-

- phoma. In: Hoffer PB, Bekerman C, Henkin RE (eds) Gallium-67 imaging. John Wiley and Sons, New York, pp 95-112
- Unnik JG van, Royen EA van, Alberts C, Schoot JB van der (1983) A method of quantitative ^{67}Ga scintigraphy in the evaluation of pulmonary sarcoidosis. *Eur J Nucl Med* 8:351-353
- Vallabhajosula S, Goldsmith SJ, Lipszyc H, Chahinian AP, Ohnuma T (1983) ^{67}Ga -transferrin and ^{67}Ga -lactoferrin binding to tumor cells. Specific versus non-specific glycoprotein-cell interaction. *Eur J Nucl Med* 8:354-357
- Van der Schoot JB, Groen AS, De Jong J (1972) Gallium 67 scintigraphy in lung diseases. *Thorax* 27:543-546
- Walsh TJ, Bekerman C, Chansow A, Szidon P (1985) The value of gallium 67 scanning in pulmonary tuberculosis. *Am Rev Respir Dis* 132:746-747
- Waxman AD, Julien PJ, Brachman MB, Tanasescu DE, Ramanna L, Birnbaum F, Berman DS, Koerner SK (1984) Gallium scintigraphy in bronchogenic carcinoma: the effect of tumor location on sensitivity and specificity. *Chest* 86:178-183
- Waxman AD (1986) The role of nuclear medicine in pulmonary neoplastic processes. *Semin Nucl Med* 16:285-295
- Wesselius LJ, Witztum KF, Taylor AT, Hartman MT, Moser KM (1983) Computer-assisted versus visual lung gallium-67 index in normal subjects and in patients with interstitial lung disorders. *Am Rev Respir Dis* 128:1084-1089
- Whitcomb ME, Dixon GF (1984) Gallium scanning, bronchoalveolar lavage and the national debt. *Chest* 85:719-721
- Winterbauer RH, Hutchinson JF (1980) Clinical significance of pulmonary function tests on the management of sarcoidosis. *Chest* 78:640-647
- Yang SL, Alderson PO, Kaizer HA (1979) Serial Ga-67 citrate imaging in children with neoplastic disease: concise communication. *J Nucl Med* 20:210-214
- Yeh SD (1984) Tumor localization scans in primary lung tumors. In: Atkins HE (ed) *Pulmonary nuclear medicine*. Marcel Dekker, New York Basel, pp 217-263
- Yehn SDJ, Benua RS, Tan CTC (1979) Gallium scan in recurrent Hodgkin's disease in children. *Clin Nucl Med* 4:359-367

Discussion

^{67}Ga -Imaging

An interesting comment about the future of gallium scanning was made. As a result of the AIDS problem, Ga-scanning has become very popular in the US. It has proven very useful not only in the assessment of lung disease (pneu-

mocystis carinii pneumonia the most common AIDS-related opportunistic infection), but also of lymphoma-type lesions or abdominal disease. A dramatic uptake of ^{67}Ga in the abdomen caused by different types of infections within the gastrointestinal tract can be seen despite the fact that the colon normally excretes ^{67}Ga . Therefore, it has been recommended to perform a whole-body scan as opposed to limited lung imaging in these patients.