





# Stanford Type A Aortic Dissection in A Patient with Primary Antiphospholipid Syndrome and Coronavirus Disease 2019

Sarah A. Ahmad, MD<sup>1</sup> Nauman Khalid, MD<sup>2</sup>  Lovely Chhabra, MD<sup>3</sup>  Waleed T. Kayani, MD<sup>4</sup>  
Tarek Helmy, MD<sup>5</sup>

<sup>1</sup> Section of Cardiothoracic Surgery, Saint Francis Medical Center, Monroe, Louisiana

<sup>2</sup> Section of Interventional Cardiology, Saint Francis Medical Center, Monroe, Louisiana

<sup>3</sup> Section of Cardiology, Westchester Medical Center Network Advanced Physician Services, New York, New York

<sup>4</sup> Section of Interventional Cardiology, Baylor College of Medicine, Houston, Texas

<sup>5</sup> Section of Interventional Cardiology, Louisiana State University Health Shreveport, Louisiana

**Address for correspondence** Nauman Khalid, MD, Section of Interventional Cardiology, St. Francis Medical Center, 309 Jackson Street, Monroe, LA 71201 (e-mail: naumankhalid84@gmail.com).

*Aorta* (Stamford) 2023;11:47–49.

## Abstract

Acute aortic dissection is one of the most lethal diseases, affecting the lining of the aortic wall. We describe a case of Stanford Type A aortic dissection in a patient with underlying primary antiphospholipid syndrome (APS) complicated by coronavirus disease 2019 (COVID-19). APS is characterized by recurrent venous and/or arterial thrombosis, thrombocytopenia, and rarely vascular aneurysms. The hypercoagulable milieu attributable to APS and the prothrombotic state from COVID-19 posed a challenge in achieving optimal postoperative anticoagulation in our patient.

## Keywords

- ▶ aortic dissection
- ▶ Stanford Type A
- ▶ primary antiphospholipid syndrome
- ▶ COVID-19

## Introduction

Aortic dissection is a tear in the lining of the aortic wall and carries high mortality. Antiphospholipid syndrome (APS) is an autoimmune disorder with multisystem involvement, and its hallmarks include vascular thromboses, presence of antiphospholipid antibodies, and pregnancy loss. Coronavirus disease 2019 (COVID-19) is a multiorgan infection caused by severe acute respiratory syndrome coronavirus 2 (SARS-CoV-2) that started in 2019 and since then has rapidly progressed into a pandemic. We present a patient with history of APS who developed Stanford Type A aortic dissection requiring operative repair and developed COVID-19 in the postoperative course.

## Case Presentation

A 54-year-old woman with a history of primary APS and stroke (in 1993 and 2005) on chronic oral anticoagulation with warfarin presented to the emergency department complaining of tearing chest and upper back pain. She denied any family history of aortic aneurysm, aortic dissection, or sudden cardiac death. Initial vital signs demonstrated a blood pressure of 86/41 mm Hg in both arms, and a pulse rate of 74 beats/min. A 12-lead electrocardiogram was unremarkable. Computed tomography of the chest showed the Stanford Type A aortic dissection extending from the aortic root through the aortic bifurcation into the left

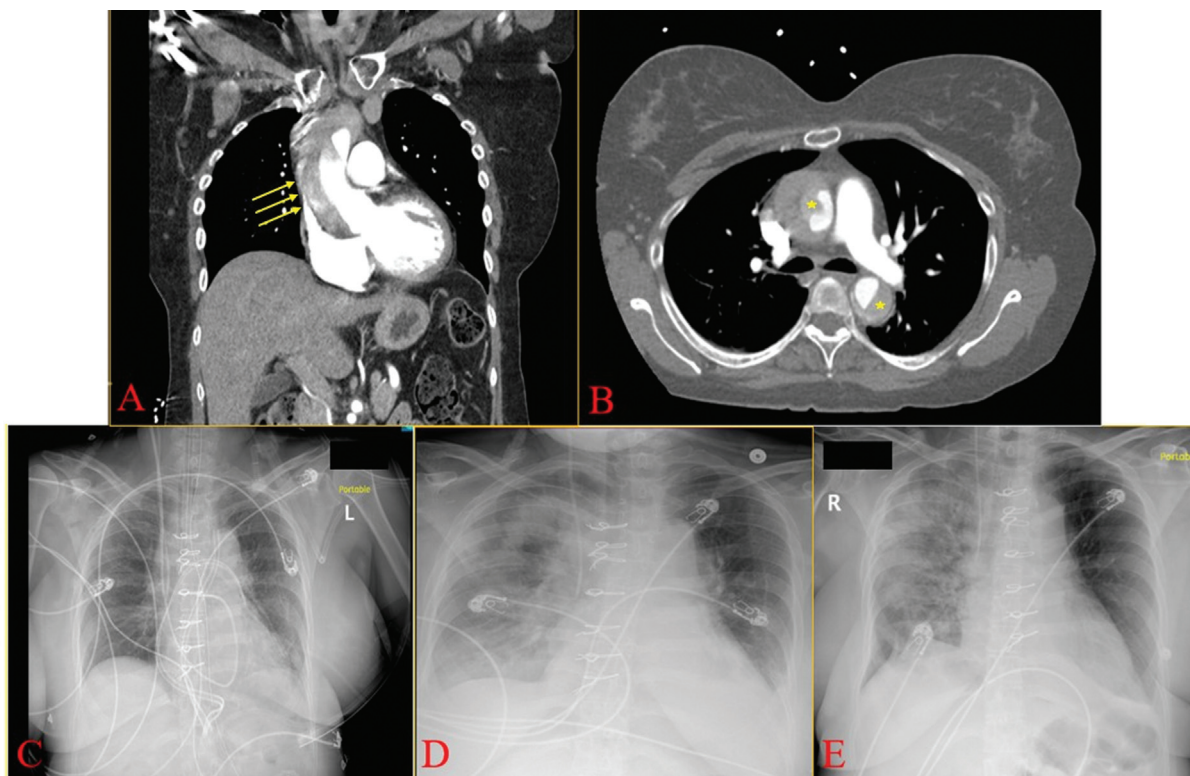
received  
January 20, 2021  
accepted after revision  
July 11, 2022

DOI <https://doi.org/10.1055/s-0042-1757952>.  
ISSN 2325-4637.

© 2023. The Author(s).

This is an open access article published by Thieme under the terms of the Creative Commons Attribution-NonDerivative-NonCommercial-License, permitting copying and reproduction so long as the original work is given appropriate credit. Contents may not be used for commercial purposes, or adapted, remixed, transformed or built upon. (<https://creativecommons.org/licenses/by-nc-nd/4.0/>)

Thieme Medical Publishers, Inc., 333 Seventh Avenue, 18th Floor, New York, NY 10001, USA



**Fig. 1** Stanford Type A aortic dissection in a patient with primary antiphospholipid syndrome and coronavirus disease 2019. (A) Coronal plane showing dissection in the ascending aorta (yellow arrows). (B) Transverse plane showing ascending aortic dissection extending into the descending aorta (yellow asterisks). (C) Chest X-ray (CXR) on postoperative day (POD) 1 with normal findings. (D) CXR on POD 4 showing diffuse bilateral consolidative opacities. (E) CXR on POD 13 showing improved pulmonary findings.

common iliac artery, also involving the innominate and bilateral common carotid arteries (►Fig. 1A and B). A nasopharyngeal swab for COVID-19 using real-time reverse transcriptase-polymerase chain reaction assay gave a positive result. Preoperative transesophageal echocardiogram revealed mild aortic insufficiency.

Under appropriate isolation precautions and hypothermic circulatory arrest with antegrade cerebral perfusion, emergent aortic repair with aortic valve resuspension was performed. Intraoperatively, there was no evidence of aortic wall thickening (i.e., inflammatory aortopathy) and no aneurysm at the proximal or distal anastomotic site. Pathologic assessment of the ascending aortic specimen showed fragments of large caliber vascular tissue showing focal hemorrhage within the adventitia, no histological assessment was performed. Furthermore, no genetic analysis was performed on this patient.

On postoperative day (POD) 4, she developed acute hypoxia requiring oxygen supplementation with the chest X-ray (CXR) demonstrating diffuse bilateral consolidative opacities (►Fig. 1D) compared with normal findings on POD 1 (►Fig. 1C). Empiric therapy with remdesivir, zinc, and vitamin C for COVID-19 was initiated. Anticoagulation with intravenous unfractionated heparin and warfarin was administered for underlying primary APS. Over the next 48 to 72 hours, her oxygen requirements progressively increased to 90% FiO<sub>2</sub>. Initially, systemic steroids were withheld because of concern for delayed wound healing and mediastinitis; however, with worsening hypoxia, steroids were

initiated. On POD 8, she received convalescent plasma therapy. The patient demonstrated gradual improvement over the next several days with improved findings on the CXR on POD 13 (►Fig. 1E). She was eventually weaned to ambient air and discharged on POD 17.

## Discussion

We describe the first unique case of Stanford Type A aortic dissection in a patient with underlying primary APS complicated by COVID-19. Two rare associations are highlighted in our case: first of Type A aortic dissection and APS, and second of Type A aortic dissection and COVID-19. The lack of aortic wall thickening intraoperatively suggests that in our case, COVID-19 was likely not the causative factor for aortopathy (and resultant aortic dissection) and that aortic dissection was likely may possibly have developed due to the underlying APS although without histological assessment no definitive diagnosis can be made. Nonetheless, the postoperative course was complicated by pulmonary involvement of COVID-19 manifested by resistant hypoxemia. Furthermore, the hypercoagulable milieu attributable to APS and the prothrombotic state from COVID-19 posed a challenge in achieving optimal postoperative anticoagulation.

APS is an autoimmune hypercoagulable disease characterized by antiphospholipid antibodies (APL), recurrent venous, and/or arterial thrombosis, thrombocytopenia, and rarely vascular aneurysms.<sup>1</sup> The association of APS with

vascular wall abnormalities is multifactorial and mechanisms may include the following<sup>1</sup>: (1) The APL may be directly linked to arterial wall abnormalities, (2) APL may cause activation of endothelial cells, monocytes, and platelets, (3) APL may be associated with upregulation of mediators responsible for modulation of the vascular tone, and (4) APL may also cause an increase in the metalloproteinase 9 which degrades elastin and has been implicated in vascular aneurysm induction.<sup>1</sup> Given the requirement of lifelong oral anticoagulation for patients with APS, this propensity for aneurysm development creates a management dilemma.<sup>1</sup> A case of APS, systemic lupus erythematosus, and Type A aortic dissection has been previously reported in a 42-year-old woman who underwent surgical ascending aorta replacement.<sup>2</sup>

COVID-19 is an infectious disease caused by SARS-CoV-2 that was identified in Wuhan, China, in December 2019, and since then has rapidly spread worldwide to cause a pandemic and a public health crisis.<sup>3</sup> Few cases of acute Type A aortic dissection have been reported in patients with COVID-19.<sup>4-6</sup> Key surgical challenge for inflammatory aortopathy is the suture line, which may be prone to bleeding in the acute infectious phase and with proclivity for aneurysm formation in the long-term. With respect to the protection of the patients and health care providers, liberal preoperative COVID-19 rapid testing is being performed at various institutions for emergent procedures. Patients with positive tests can then be placed in appropriate isolation precautions, providers can wear appropriate personal protective equipment and procedure rooms can be disinfected accordingly. Furthermore, special attention to the pulmonary status in

the postoperative period can be paid for such patients who can provide unanticipated challenges, as depicted in our case.

#### Funding

None.

#### Conflict of Interest

The authors declare no conflict of interest related to this article.

#### Acknowledgments

None.

#### References

- 1 Szyper-Kravitz M, Altman A, de Carvalho JF, et al. Coexistence of the antiphospholipid syndrome and abdominal aortic aneurysm. *Isr Med Assoc J* 2008;10(01):48-51
- 2 Ulutaş F, Çobankara V, Bozdemir A, Karasu U. Rare association of antiphospholipid antibody syndrome, systemic lupus erythematosus and aortic dissection: a striking presentation with multi-organ failure? *Eur J Case Rep Intern Med* 2020;7(11):001887
- 3 Khalid N, Chen Y, Case BC, et al. COVID-19 (SARS-CoV-2) and the heart—an ominous association. *Cardiovasc Revasc Med* 2020;21(08):946-949
- 4 Akgul A, Turkyilmaz S, Turkyilmaz G, Toz H. Acute aortic dissection surgery in patient with Covid-19. *Ann Thorac Surg* 2021;111(01):e1-e3
- 5 Fukuhara S, Rosati CM, El-Dalati S. Acute type a aortic dissection during the COVID-19 outbreak. *Ann Thorac Surg* 2020;110(05):e405-e407
- 6 Tabaghi S, Akbarzadeh MA. Acute type A aortic dissection in a patient with COVID-19. *Future Cardiol* 2021;17(04):625-629