

Topical Interferon Alpha-2b for Treatment of Noninvasive Ocular Surface Squamous Neoplasia with 360° Limbal Involvement

Siamak Zarei-Ghanavati¹, MD, FICO; Reza Alizadeh¹, MD; Sophie X. Deng², MD, PhD

¹Eye Research Center, Mashhad University of Medical Sciences, Mashhad, Iran

²Jules Stein Eye Institute, UCLA, Los Angeles, California, USA

Abstract

Purpose: To report the results of topical interferon alpha-2b (IFN α 2b) for the treatment of ocular surface squamous neoplasia (OSSN) with 360° limbal involvement.

Methods: In a prospective observational study, five patients with biopsy proven primary or recurrent OSSN with 360° limbal involvement received topical IFN α 2b (3 million IU/ml, 4 times daily) and were followed from 8 to 12 months. Outcome measures included resolution of the lesion, relief of symptoms, systemic and ocular side effects, and recurrence rate.

Results: Five patients including 4 primary OSSNs and one recurrent OSSN received topical interferon alpha-2b. The mean age was 60.2 (range: 52–73) years and mean follow up duration was 10.2 months. Clinical resolution of the tumor occurred in all cases 2 months after initiation of treatment and no patient developed ocular or systemic complications. No recurrence of OSSN developed during the follow up period.

Conclusion: Topical recombinant IFN α 2b appears to be an effective alternative treatment for OSSN with 360° limbal involvement. This approach precludes the high risk of limbal stem cell deficiency which results from surgical excision or topical chemotherapeutic agents.

Keywords: Conjunctival Intraepithelial Neoplasia; Interferon Alpha-2b; Ocular Surface Squamous Neoplasia; Ocular Surface Squamous Neoplasia

J Ophthalmic Vis Res 2014; 9 (4): 423-426.

INTRODUCTION

Ocular surface squamous neoplasia (OSSN) is the most common neoplasm of the ocular surface. It is a slowly progressive tumor with low potential for metastasis which commonly arises from the limbus.^[1] A variety of treatment options has been shown to be successful. Surgical excision combined with cryotherapy has been the standard treatment for OSSN. By complete excision, with or without adjunctive cryotherapy, the recurrence rate is 9% and 33%, respectively.^[2,3] Excision margins are the most important factor in predicting recurrence. If the surgical margin is positive, the recurrence rate can be as high as 53%.^[2]

In cases of OSSN that involved 360° of the limbus, surgical excision with clear margins is a destructive procedure and might result in severe complications including persistent epithelial defects, corneal haziness and neovascularization, symblepharon formation and limbal stem cell deficiency. In this situation, alternative topical treatments including immune modulators such as interferon alpha-2b (IFN α 2b) or chemotherapeutic agents such as mitomycin-C (MMC) and 5-fluorouracil (5-FU) may be used. However, it has been shown that topical MMC and 5-FU are toxic to the ocular surface and might cause limbal stem cell deficiency.^[4-7]

Correspondence to:

Siamak Zarei-Ghanavati, MD, FICO. Eye Research Center, Mashhad University of Medical Sciences, Khatam-al-Anbia Eye Hospital, Abootaleb Blvd., Mashhad, Iran.
E-mail: zareis@mums.ac.ir

Received: 20-05-2013

Accepted: 12-11-2013

Access this article online

Quick Response Code:



Website:
www.jovr.org

DOI:
10.4103/2008-322X.150811

Topical IFN α 2b has been shown to be effective as a single-agent therapy or as an adjunct after surgery. As it is not associated with limbal stem cell damage, it could be an excellent alternative treatment for 360° involvement of the limbus.^[8,9] In this study we evaluate the efficacy of topical IFN α 2b for treatment of 360° limbal OSSN.

METHODS

This prospective study was conducted at Khatam-al-Anbia Eye Institute, Mashhad University of Medical Sciences, Iran. Institutional review board approval was obtained and the study followed the tenets of the declaration of Helsinki. A comprehensive ophthalmic examination was performed in all patients including measurement of uncorrected and best corrected visual acuity, tonometry, slit lamp biomicroscopy, and dilated fundus examination.

The extension of OSSN was determined by slit lamp biomicroscopy with and without Rose Bengal staining. OSSN was classified based on the seventh edition of the American Joint Committee on Cancer (AJCC) classification.^[10] All patients who underwent topical IFN α 2b medication had primary or recurrent OSSN which had involved 360° of the limbus. The diagnosis was confirmed by small incisional biopsy.

We used IFN α 2b at 3 million IU/ml (Interferon alpha-2b 3 Mega Unit Vial, Hejrat Distribution Co, Tehran, Iran) and the volume of three vials of IFN α 2b was injected into an empty drop container without dilution. All patients instilled the drop 4 times daily and stored the container in the refrigerator for 2 weeks. After 2 weeks, the patients received another container with IFN α 2b.

All patients were examined prior to initiation of IFN α 2b and were seen after 1-day, 1-week, 1-month, and then every month thereafter. The medication was continued for 1-month after complete clinical resolution. All systemic and ocular adverse effects were recorded during follow-up.

RESULTS

Five eyes of five patients including four male and one female subject with mean age of 55 (range, 52–73;

median, 60) years and 360° limbal OSSN were included in the study. Table 1 shows demographic data, clinical findings and the outcomes of treatment. In terms of lesion morphology, three eyes presented as sessile papilliform [Figure 1a], one as gelatinous [Figure 1b] and the other one as leukoplakic. All patients complained of low visual acuity, itching, foreign body sensation and photophobia.

Mean follow-up duration was 10.2 (range, 8–12, median, 10) months. Complete clinical resolution was achieved in all eyes after a course of topical IFN α -2b therapy for 8 weeks. Before treatment all patients had cornea epithelial irregularity and punctate epithelial erosions on slit lamp biomicroscopy [Figure 1b]. After 1-month, corneal epithelial abnormality improved and all patients reported symptomatic improvement. In the 2nd month visit, the corneal involvement resolved completely. The neoplastic mass disappeared and limbal vascularity was also reduced significantly [Figure 1]. Mean best corrected visual acuity increased from 20/200 before treatment to 20/40 at last follow-up.

No patient developed persistent epithelial defect, symblepharon, or any signs indicative of limbal stem cell deficiency. No recurrence was seen based on the slit lamp biomicroscopy at final follow up. None of the patients experienced systemic adverse effects related to IFN α 2b therapy including malaise, flu like symptoms, bone pain and fatigue. Patients' information was summarized in Table 1.

DISCUSSION

OSSN is a slowly progressing lesion that arises due to mutations in limbal stem cells. In cases of OSSN with 360° limbal involvement, stem cell dysfunction might change the clinical presentation (case #4 was referred to us with a diagnosis of limbal stem cell deficiency) [Figure 1]. In this situation, signs of limbal stem cell deficiency including corneal epithelial irregularity, epithelial erosion and peripheral corneal neovascularization, may be present before treatment. Eradication of neoplastic cell by surgical excision, cryotherapy or antimetabolites or chemotherapeutic agents (MMC and 5-FU) can damage the remaining limbal stem cells and aggravate limbal stem cell deficiency.^[3,5-7]

Table 1. Patient's data

Case	Gender	Age	VA (before treatment)	Primary/recurrent	Previous treatment	Clinical morphology	VA (after treatment)	Recurrence after treatment	Follow-up (M)
1	Male	62	20/400	Primary	-	Sessile papilliform	20/60	No	10
2	Male	60	20/200	Recurrent	Excision+ cryotherapy	Sessile papilliform	20/40	No	11
3	Male	55	20/100	Primary	-	Leukoplakic	20/40	No	8
4	Female	51	20/100	Primary	-	Gelatinous	20/30	No	12
5	Male	73	20/400	Primary	-	Sessile papilliform	20/40	No	10

VA, visual acuity; M, month

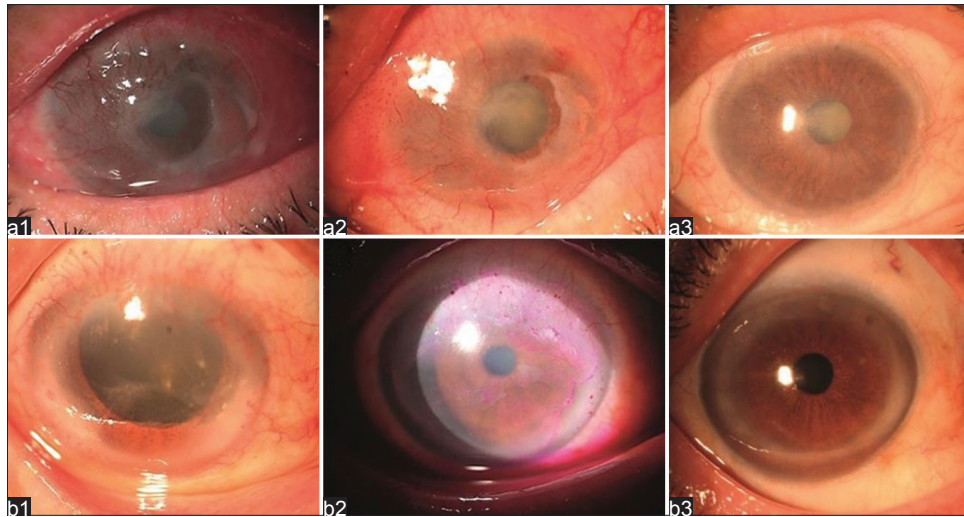


Figure 1. (a) Slit lamp photograph of case one with 360° sessile papiliform OSSN. a1: Before treatment (note signs of limbal stem cell deficiency). a2: One month after treatment (note the reduction in neoplastic mass and ocular surface inflammation). a3: Two months after treatment (note complete resolution). (b) Slit lamp photograph in case 4 with 360° gelatinous OSSN. b1: Before treatment (note signs of limbal stem cell deficiency). b2: One month after treatment [note reduction in neoplastic mass and migration of neoplastic cell to corneal center (Rose Bengal staining)]. b3: Twelve months after treatment and 2 weeks after cataract surgery.

Topical chemotherapy using immune modulator agents have gained great attention. Interferons are glycoprotein molecules which have an important role in human natural defense responses. The Food and Drug Administration (FDA) has approved interferon therapy for a variety of diseases including hairy cell leukemia, type-C viral hepatitis and Kaposi's sarcoma.^[11,12] Several studies have shown that topical IFN α 2b as a single therapeutic agent is an effective treatment for both primary and recurrent OSSN.^[13-15] Recently, a study used IFN α 2b for large OSSNs (tumor diameter ≥ 15 mm or $\geq 180^\circ$ limbal involvement) and achieved 72% success.^[16]

To the best of our knowledge, there is no study reporting the treatment of OSSN with 360° limbal involvement. Treatment of this subtype of OSSN differs from others as limbal stem cell deficiency and extensive ocular surface damage may occur before or after treatment. However, in our study, all patients achieved favorable results with no significant systemic or ocular side effect. Extended follow up is needed to determine recurrence after 1-year.

In the current study topical IFN α 2b was well tolerated by all patients. The corneal epithelial irregularity and punctate epithelial erosions were a result of partial limbal cell deficiency or dysfunction before treatment. During treatment, all cases showed improved visual acuity and ocular symptoms. We believe such improvements increased their compliance as compared to other OSSN cases with less severe ocular surface problems. We employed a higher dose of topical IFN α 2b: 3 million IU/ml instead of 1 million IU/ml. In a recent study, Galor et al^[17] compared the effectiveness of these two concentrations of IFN α 2b for treatment of

OSSN. Although, not statistically significant, their results showed a trend toward increased success rates and faster resolution of the lesion in the 3 million IU/ml group. Our unpublished data showed similar findings and we chose the 3 million IU/ml concentration for extensive OSSN. In addition, continuous follow up of these patients would be necessary to evaluate long term outcomes of treatment. We excluded the patients with invasive OSSN based on clinical examination and histopathology. However, a small incisional biopsy cannot confirm the lack of invasion in other parts of the tumor. In general, in cases of invasive OSSN, topical monotherapy is contraindicated and the ophthalmologist must consider surgical excision and cryotherapy.^[18]

In summary, topical IFN α 2b appears to be a safe and effective treatment for OSSN with 360° limbal involvement. This noninvasive treatment reduces the risk of limbal stem cell deficiency associated with surgical excision or topical antimetabolite chemotherapeutic agents.

ACKNOWLEDGEMENT

SXD receives grant support from the National Eye Institute (R01EY021797) and the California Institute of Regenerative Medicine (TR2-01768)

REFERENCES

1. Kiire CA, Srinivasan S, Karp CL. Ocular surface squamous neoplasia. *Int Ophthalmol Clin* 2010;50:35-46.
2. Tabin G, Levin S, Snibson G, Loughnan M, Taylor H. Late recurrences and the necessity for long-term follow-up in corneal and conjunctival intraepithelial neoplasia. *Ophthalmology* 1997;104:485-492.

3. Peksayar G, Soytürk MK, Demiryont M. Long-term results of cryotherapy on malignant epithelial tumors of the conjunctiva. *Am J Ophthalmol* 1989;107:337-340.
4. Russell HC, Chadha V, Lockington D, Kemp EG. Topical mitomycin C chemotherapy in the management of ocular surface neoplasia: A 10-year review of treatment outcomes and complications. *Br J Ophthalmol* 2010;94:1316-1321.
5. Dudley BW, Malecha MA. Limbal stem cell deficiency following topical mitomycin C treatment of conjunctival-corneal intraepithelial neoplasia. *Am J Ophthalmol* 2004;137:950-951.
6. Poothullil AM, Colby KA. Topical medical therapies for ocular surface tumors. *Semin Ophthalmol* 2006;21:161-169.
7. Yeatts RP, Engelbrecht NE, Curry CD, Ford JG, Walter KA. 5-Fluorouracil for the treatment of intraepithelial neoplasia of the conjunctiva and cornea. *Ophthalmology* 2000;107:2190-2195.
8. Karp CL, Moore JK, Rosa RH Jr. Treatment of conjunctival and corneal intraepithelial neoplasia with topical interferon alpha-2b. *Ophthalmology* 2001;108:1093-1098.
9. Vann RR, Karp CL. Perilesional and topical interferon alpha-2b for conjunctival and corneal neoplasia. *Ophthalmology* 1999;106:91-97.
10. Edge S, Byrd DR, Compton CC, Fritz AG, Greene FL, Trotti A, et al. Carcinoma of the Conjunctiva. *AJCC Cancer Staging Manual*. 7th ed. New York, NY: Springer; 2010.
11. Billiau A. The clinical value of interferons as antitumor agents. *Eur J Cancer Clin Oncol* 1981;17:949-967.
12. Davis GL. Interferon treatment of chronic hepatitis C. *Am J Med* 1994;96:41S-46S.
13. Giaconci JA, Karp CL. Current treatment options for conjunctival and corneal intraepithelial neoplasia. *Ocul Surf* 2003;1:66-73.
14. Schechter BA, Koreishi AF, Karp CL, Feuer W. Long-term follow-up of conjunctival and corneal intraepithelial neoplasia treated with topical interferon alfa-2b. *Ophthalmology* 2008;115:1291-1296.e1.
15. Shah SU, Kaliki S, Kim HJ, Lally SE, Shields JA, Shields CL. Topical interferon alfa-2b for management of ocular surface squamous neoplasia in 23 cases: Outcomes based on American Joint Committee on Cancer classification. *Arch Ophthalmol* 2012;130:159-164.
16. Kim HJ, Shields CL, Shah SU, Kaliki S, Lally SE. Giant ocular surface squamous neoplasia managed with interferon alpha-2b as immunotherapy or immunoreduction. *Ophthalmology* 2012;119:938-944.
17. Galor A, Karp CL, Chhabra S, Barnes S, Alfonso EC. Topical interferon alpha 2b eye-drops for treatment of ocular surface squamous neoplasia: A dose comparison study. *Br J Ophthalmol* 2010;94:551-554.
18. Holcombe DJ, Lee GA. Topical interferon alfa-2b for the treatment of recalcitrant ocular surface squamous neoplasia. *Am J Ophthalmol* 2006;142:568-571.

How to cite this article: Zarei-Ghanavati S, Alizadeh R, Deng SX. Topical interferon alpha-2b for treatment of noninvasive ocular surface squamous neoplasia with 360° limbal involvement. *J Ophthalmic Vis Res* 2014;9:423-6.

Source of Support: Nil. **Conflict of Interest:** None declared.