

[CASE REPORT]

Reimplantation of a Pacemaker into a Subpectoral Pocket Via the Lateral Approach in Collaboration with Plastic Surgeons

Takahiro Takeuchi¹, Hisanori Yui¹, Chie Yui¹, Tadashi Itagaki¹, Keisuke Machida¹,
Yusuke Tsujinaka¹, Anna Fujimori¹, Kaori Takahashi¹, Kyuhachi Otagiri¹, Yuta Nakajima²,
Wataru Kasuga², Shoji Kondoh² and Hiroshi Kitabayashi¹

Abstract:

An 86-year-old woman had a pacemaker implanted into a subfascial pocket. After four months, the generator became exposed, and the pacemaker was removed. She exhibited a lack of prepectoral tissue. We therefore performed reimplantation in collaboration with plastic surgeons. We placed the leads via the extrathoracic subclavian venous approach, and plastic surgeons created a subpectoral pocket from the low lateral side of the pectoralis major muscle. General cardiologists rarely create subpectoral pockets and they are unable to implant leadless pacemakers at their hospital due to lack of sufficient skill. Our case showed that creating a subpectoral pocket in collaboration with plastic surgeons is quick and safe.

Key words: pacemaker, infection, reimplantation, pectoralis major, plastic surgery

(Intern Med 59: 967-970, 2020)

(DOI: 10.2169/internalmedicine.3979-19)

Introduction

Recently, a steady increase in the number of implantations of cardiac implantable electronic devices (CIEDs) has been noted. In particular, implantable cardioverter defibrillators (ICDs) and cardiac resynchronization therapy defibrillators have become common therapy. Cardiologists typically implant CIEDs into a subcutaneous pocket because it is generally safe, and the procedure time is shorter than that required for a subpectoral pocket (1). As society ages, however, we may need to implant CIEDs in thin elderly patients. In such cases, making a subfascial pocket is effective (2).

Furthermore, the incidence of infection of CIEDs implanted in elderly patients is increasing, and these patients subsequently require CIED reimplantation. In cases of the reimplantation of pacemaker, a leadless pacemaker may be selected, given its advantages against infection. However, the safe operation of a leadless pacemaker requires substantial

experience, and many general cardiologists are thus unable to implant it at their hospital. Therefore, cardiologists need to consider other approaches for the implantation or reimplantation of CIEDs.

In the present case, we decided to perform the subpectoral implantation of a pacemaker. Implantation of CIEDs into a subpectoral pocket is relatively rare, and cardiologists generally do not have much experience in this regard. One drawback to deep dissection in the pocket is the narrow field of view. Furthermore, creating the subpectoral pocket using the same method as that for creating a subcutaneous or subfascial pocket might result in complications such as bleeding and hematoma (3). We believe that the lateral approach to creating the subpectoral pocket solves this issue, and creating it in collaboration with plastic surgeons does not require special skill for general cardiologists.

Plastic surgeons often perform implantations under the pectoralis major muscle for the reconstruction of breast tissue. Compared with cardiologists, they have more experience and knowledge concerning the creation of a subpec-

¹Department of Cardiovascular Medicine, Ina Central Hospital, Japan and ²Department of Plastic Surgery, Ina Central Hospital, Japan
Received: September 30, 2019; Accepted: October 29, 2019; Advance Publication by J-STAGE: December 13, 2019
Correspondence to Dr. Takahiro Takeuchi, takeuchi@inahp.jp

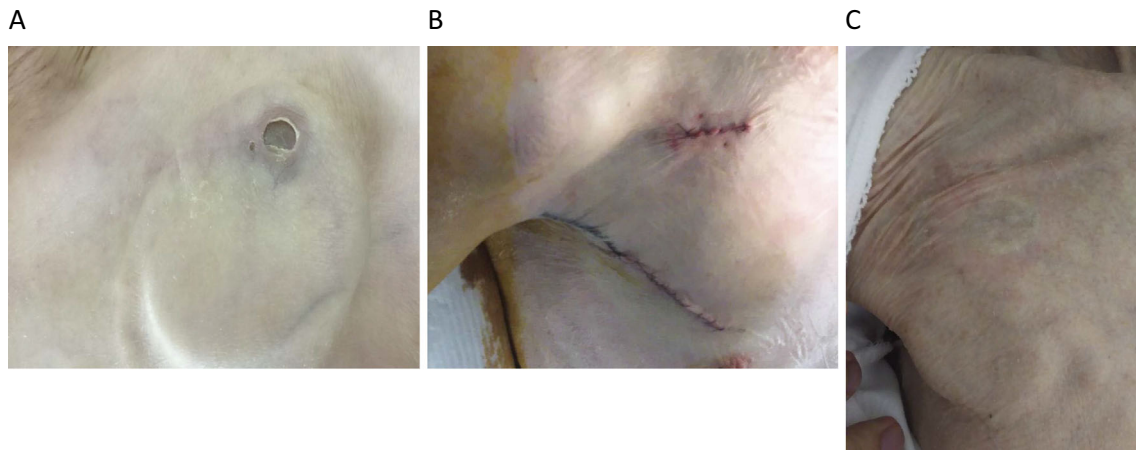


Figure 1. Images of the surgical scar. A: Exposure of the generator at the left surgical scar. B: The right surgical scar after reimplantation in the subpectoral pocket. C: The right surgical scar after one year.

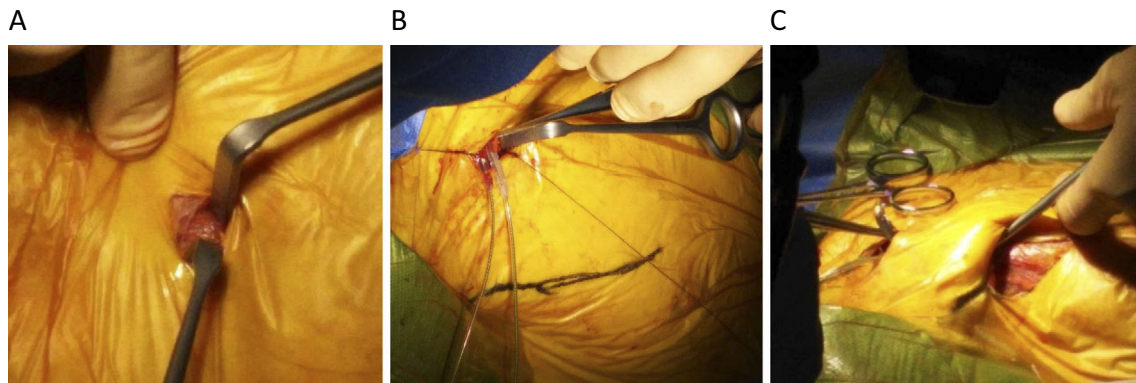


Figure 2. A: We made an incision line of approximately 1 cm on the subclavian skin and divided the subcutaneous tissue and muscle. B: We punctured the subclavian vein from the incision line via the extrathoracic subclavian approach. C: Plastic surgeons created the subpectoral pocket from the lower lateral side of the pectoralis major muscle.

toral pocket while avoiding complications.

Case Report

An 86-year-old woman was hospitalized due to advanced atrioventricular block. She was petite (height: 137 cm, weight: 31.0 kg), lacked fatty tissue on both pectoralis major muscles, and took steroids for polymyalgia rheumatica (prednisolone, 5 mg per day). We carefully implanted a permanent pacemaker into her left subfascial pocket. Unfortunately, we were unable to suture only one subcutaneous layer. While no pacemaker pocket erosion was observed for three months after surgery, at four months, the pacemaker generator became exposed through the left subclavian incision (Fig. 1A). Although the pacemaker generator was infected, her white blood cells and C-reactive protein levels did not increase, and blood culture was negative.

We removed the entire pacemaker system. Slight adhesion of the leads was observed, and we extracted the leads manually under local anesthesia. We asked plastic surgeons to assist in the debridement of the necrotic tissue. The patient re-

quired early reimplantation of the new pacemaker. In addition, there was little fatty tissue on her right pectoralis major muscle.

We performed the implantation in collaboration with plastic surgeons two weeks after removing the pacemaker system. Under local anesthesia, we made an incision line on her right subclavian skin of approximately 1 cm and divided the subcutaneous tissue and pectoralis major muscle (Fig. 2A). We punctured her right subclavian vein from the incision line via the extrathoracic subclavian approach. The leads were placed at the right ventricular apex and right atrial appendage. The leads were fixed to the pectoralis major muscle using a silk thread (Fig. 2B). Next, under local anesthesia, plastic surgeons created a subpectoral pocket from the low lateral side of the pectoralis major muscle (Fig. 2C) in about 10-15 minutes without bleeding. The generator and leads were connected under the muscle and placed in the subpectoral pocket. Finally, we sutured the two scars (Fig. 1B). She left our hospital after one week without any complications such as bleeding, hematoma, or infection (Fig. 3). She returned to our hospital after one year for a

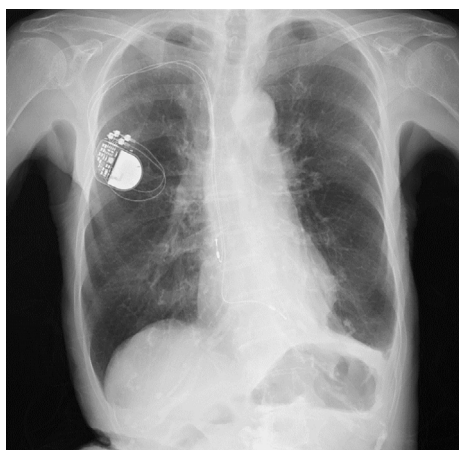


Figure 3. Chest X-ray obtained one week after reimplantation.

follow-up visit, and the scar was clear without skin erosion (Fig. 1C).

Discussion

Subpectoral implantation is a well-recognized technique that has been available since the 1960s. The merits of subpectoral implantation were highlighted anew in commentary published approximately two decades ago (4). However, many general cardiologists lack sufficient knowledge and experience to create a subpectoral pocket.

As the lateral approach for creating the subpectoral pocket is rarely reported (5, 6), this approach to implantation is unfortunately not recognized by many general cardiologists; however some arrhythmia cardiologists are aware of it. When creating a subpectoral pocket, cardiologists may create a subpectoral pocket from the usual incisional line of the subclavian skin toward the inferior direction. However, with this approach, bleeding can occur due to damage to the pectoris major muscle, and the narrow field of view makes it difficult to stop this bleeding. The layer of the low lateral side of the pectoralis major muscle is sparser than the anterior side of this muscle. Therefore, dividing the layer from the low lateral side of the pectoris major muscle is relatively easy and yields a wider field of view, while minimizing bleeding and hematoma. In the present case, bleeding and hematoma did not occur. Plastic surgeons often perform implantations under the pectoralis major muscle using this lateral approach during breast reconstruction. We believe that collaborating with plastic surgeons to create a pocket for CIEDs under the pectoralis major muscle is safe and quick for patients.

General anesthesia is typically used in reports of the lateral approach (5, 6). Furthermore, patients typically require a large subpectoral pocket for implantable cardioverter defibrillator implantation. Our patient was an elderly woman, and the pacemaker generator required a small subpectoral pocket. Pneumonia and delirium often develop when general anesthesia is administered to elderly patients. We explained

the risks and benefits of each anesthesia approach to the patient, and she ultimately selected local anesthesia.

Recently, the number of implantations of leadless pacemakers has markedly increased, given its many advantages against infection. Successful lead extraction and leadless pacemaker implantation reportedly remained free from reinfection in patients who had suffered from traditional pacemaker infection (7). The implantation of a leadless pacemaker is reportedly safe (8), even in Japanese patients (9). In general, the leadless pacemaker is the first choice for reimplantation in patients with pacemaker infection who are suitable for a VVI pacemaker. However, an advanced age (>75 years old), female gender, low body mass index (<20 kg/m²), and history of chronic obstructive pulmonary disease are risk factors of cardiac effusion or perforation events with the implantation of a leadless pacemaker (10). The present patient had multiple risk factors, including an advanced age, female gender and low body mass index (16.5 kg/m²). She was therefore not suitable for the implantation of a leadless pacemaker.

However, there are some disadvantages associated with this approach. For one, this approach takes more time and requires more local anesthesia than the conventional method. It is also difficult to detect generator infection in the subpectoral pocket. In addition, the generator exchange via this approach of implantation should be performed in collaboration with plastic surgeons. While complications are rare when creating a subpectoral pocket using the lateral approach, injury to the perforating branches of the internal thoracic artery or lateral thoracic nerve might occur if the subpectoral pocket is created extremely lateral or inside of the chest. Thin elderly patients deemed too risky for leadless pacemaker implantation may benefit from this approach.

Performing implantation in the subpectoral pocket in collaboration with plastic surgeons is a safe and easy approach for general cardiologists. We believe that cardiologists should consider the lateral approach with the subpectoral pocket for the implantation or reimplantation of CIEDs in small-frame elderly patients.

The authors state that they have no Conflict of Interest (COI).

References

1. Michael R, Robert W, James W, Stephen R. Complications associated with pectoral Cardioverter-Defibrillator implantation: comparison of subcutaneous and submuscular approaches. Worldwide Jewel Investigators. *J Am Coll Cardiol* **28**: 1287-1282, 1996.
2. Imai K. Pocket creation in the prepectoral subfascial position for the implantation of a cardiac implantable electrical device. *J Arrhythmia* **30**: 92-94, 2014.
3. Rafaele P, Richard K, Kenneth A. How to make a submuscular pocket. *J Cardiovasc Electrophysiol* **17**: 1381-1383, 2006.
4. Parsonnet V, Roelke M, Bernstein AD. The subpectoral pulse generator site revisited. *Pacing Clin Electrophysiol* **23**: 1-3, 2000.
5. Costeas XF, Strembelas PG, Markou DX, Stefanadis CI, Toutouzas PK. Subpectral cardioverter-defibrillator implantation using a lateral approach. *J Interv Card Electrophysiol* **4**: 611-619,

- 2000.
6. Morishima I, Sone T, Tsuboi H, et al. Restoring the recurrent extrusion of the subcutaneously implanted defibrillator by means of subpectoral replacement: the benefits of subpectoral implantation in the current ICD era. *J Arrhythmia* **21**: 418-421, 2005.
 7. Kypka A, Blessberger H, Kammler J, et al. Leadless cardiac pacemaker implantation after lead extraction in patients with severe device infection. *J Cardiovasc Electrophysiol* **27**: 1067-1071, 2016.
 8. Duray GZ, Ritter P, El-Chami M, et al. Long-term performance of a transcatheter pacing system: 12-month results from the Micra Transcatheter Pacing study. *Heart Rhythm* **14**: 702-709, 2017.
 9. Soejima K, Asano T, Ishikawa T, et al. Performance of leadless pacemaker in Japanese patients vs. rest of the world. *Circ J* **81**: 1589-1595, 2017.
 10. Roberts PR, Clementy N, Al Samadi F, et al. A leadless pacemaker in the real-world setting: The Micra Transcatheter Pacing System Post-Approval Registry. *Heart Rhythm* **14**: 1375-1379, 2017.

The Internal Medicine is an Open Access journal distributed under the Creative Commons Attribution-NonCommercial-NoDerivatives 4.0 International License. To view the details of this license, please visit (<https://creativecommons.org/licenses/by-nc-nd/4.0/>).