

Treatment of Anti-NMDA Receptor Encephalitis with Ovarian Teratoma Removal: A Literature Review and Two Case Reports

Nguyen Phuong Tu^{1,2}, Pham Ba Nha^{1,2}, Nguyen Duy Hung^{1,2}, Nguyen Hoang Minh^{3*}, Hoang Ngoc Anh², Thien Chu Dinh^{4,5}

¹Obstetrics and Gynecology Department of Hanoi Medical University, Hanoi, Vietnam; ²Obstetrics and Gynecology Department in Bach Mai Hospital, Hanoi, Vietnam; ³Hanoi National Hospital of Odontostomatology, Hanoi, Vietnam; ⁴School of Odonto Stomatology, Hanoi Medical University, Hanoi, Vietnam; ⁵Institute for Research and Development, Duy Tan University, Danang, Vietnam

Abstract

Citation: Tu NP, Nha PB, Hung ND, Minh NH, Anh HN, Chu Dinh T. Treatment of Anti-NMDA Receptor Encephalitis with Ovarian Teratoma Removal: A Literature Review and Two Case Reports. Open Access Maced J Med Sci. 2019 Dec 30; 7(24):4378-4382. <https://doi.org/10.3889/oamjms.2019.839>

Keywords: NMDA encephalitis; Immunoglobulin; Ovarian teratoma

***Correspondence:** Nguyen Hoang Minh, Hanoi National Hospital of Odontostomatology, Hanoi, Vietnam. E-mail: dnguyenhoangminh@gmail.com

Received: 23-Sep-2019; **Revised:** 20-Nov-2019; **Accepted:** 21-Nov-2019; **Online first:** 20-Dec-2019

Copyright: © 2019 Nguyen Phuong Tu, Pham Ba Nha, Nguyen Duy Hung, Nguyen Hoang Minh, Hoang Ngoc Anh, Thien Chu Dinh. This is an open-access article distributed under the terms of the Creative Commons Attribution-NonCommercial 4.0 International License (CC BY-NC 4.0)

Funding: This research did not receive any financial support

Competing Interests: The authors have declared that no competing interests exist

BACKGROUND: N-methyl-d-aspartate receptor (NMDAR) antibody encephalitis appears common in the world, but the number of clinical cases in Vietnam which were recorded is rare.

CASE REPORT: We describe two new cases of disease in recent years with the aim of contributing to diagnosis and treatment experiences. These cases were noted over the past 3 years with the patients who have been treated at lower levels but have no results. They came to us when symptoms became worse and therefore required prolonged treatment with special intensive care facilities. The atypical and easily confused symptoms are the reasons that make the disease be detected late; leading to a much higher cost of treatment and the complication may appear in the patient. In the past, patients with these manifestations were diagnosed with unexplained encephalitis and severe sequelae or death. Autoimmune encephalitis has many types; NMDA encephalitis associated with ovarian teratoma is the most common autoimmune encephalitis in young women.

CONCLUSION: In conclusion, based on the case report, we hope to contribute some experiences on the diagnosis and the strategy in early treatment. With most female patients at very young age, early treatment to avoid complications will help patients have a quality life and maintain reproductive function.

Introduction

Anti-N-methyl-D-aspartate-receptor (anti – NMDAR) encephalitis is defined as an autoimmune disorder connected with ovarian teratomas [1]. Patients regularly show noticeable psychiatric signs and unintentional movements and rapidly progress to unresponsiveness with central hypoventilation and dysautonomia [2]. In spite of the fact that the occurrence of anti – NMDAR encephalitis linked with ovarian teratomas is different across studies, it could lead to severe consequences and the health of a person might be under threat. Although the symptoms are very serious but when the tumor is removed, those symptoms improve quickly [2]. The reason why this syndrome was not depicted until 2007 is related to the lack of radiologic discovery and precise laboratory.

This explains why the majority of earlier cases likely diagnosed as viral encephalitis [1]. Accordingly, the prognosis is very important, and in many cases, disease can be fatal with irreversible damage to cortical areas in those who suffer delay in diagnosis and medical care. As a result, patients could end up with weakening neuropsychiatric dysfunction or even being death. However, if the antibodies are pathogenic, doctors can determine that their effects on NMDA receptors would be reversible because most of the patients did recover [2]. When studying this antibody based on pharmacological and genetic properties, these antibodies show a relationship between the ability to decline receptor function and the clinical presentation of the disease [3].

The exact diagnosis of the disease is still difficult because the symptoms of the disease are not typical and easily confused with neurological diseases

[4]. Grassroots hospitals will face difficulties to diagnose due to the lack of specific clinical cases and treatment experience. The type of immunotherapy that is often claimed as most effective in controlling the symptoms of the disease still remains a matter of debate. Hence, there is a vital lack of data concerning the optimum treatment of the disease and the cases may show some confounding factors that leading to a delay in diagnosis [3].

Therefore, with the aim of contributing part of the experience in diagnosis anti- NMDAR encephalitis and early treatment, we report cases of two young women with teratoma removal and treatment therapy after surgery, a patient with plasmapheresis and a patient without plasmapheresis.

Case Reports

Case 1

The first patient was an 18-year-old female who had not yet been found any abnormal in medical history. She presented with vomiting, headache, high fever (always over 39,5°C) and acute disorientation for one week, then high fever accompanied with urine incontinence, confusion and dull response. She was admitted with the identification of meningitis-encephalitis since January 7th, 2017 after one day at Thanh Hoa Province General hospital. She was treated by high dose and a combination of intravenous (IV) antibiotic which were Meronem 500 mg and Pamecillin 1 g, antiviral drugs, antimicrobial treatment, solumedrol (Methylprednisolone 1 g), sedative drugs to against brain edema. However, her disease progressed more serve despite having drug treatment. As her Glasgow Coma score was 10, her prognosis had become worsen, therefore, we must open the trachea, support with mechanical breathing. As a result, the patient then fell into unconscious condition.

MRI brain showed a condition of mild posterior hemisphere edema. Her abdominal CT (Computed Tomography) and ultrasound (Figure 1) revealed a 90 x 60 mm ovarian teratoma in the right ovary.

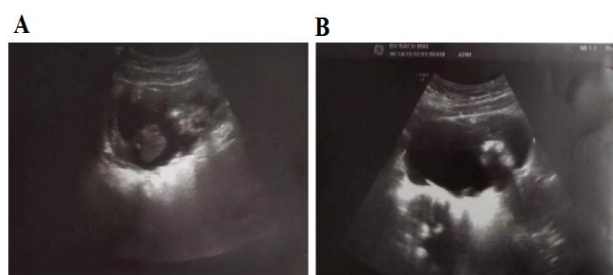

Figure 1: Imaging of the ovarian teratoma on the ultrasound; A) Ovarian teratoma on the vaginal ultrasound imaging; B) Ovarian teratoma on the abdominal ultrasound imaging

After a consultation within the most important departments of the hospital (including neurologists, internists, psychiatrists, intensivists, infectious disease specialists, radiologists, gynecologists and pathologists), we decided to used immunoglobulin therapy and the gynecologist removed the ovarian teratoma by using laparoscopic method at the Obstetrics Department in Bach Mai Hospital. She was treated with intravenous immunoglobulin to against anti-NMDA receptor encephalitis and went through minimal changes in neurologic symptoms. We used Intratect (Immunoglobulin G2,5g) for her with the dose of 20 gr per day on 5 consecutive days. Besides, she also received corticosteroid therapy by IV 5 days after surgery with Methylprednisolone 1 g per day. She experienced a successful surgery (Figure 2). Within 24 hours after surgery, she achieved a remarkable improvement in her cognitive function (the patient could recognize herself, her parents' names, and in few days later she could remember previous events). The result of histopathology showed the present of mature teratoma and nerve tissue. Several days later, she had recovery with good condition and could be discharged.

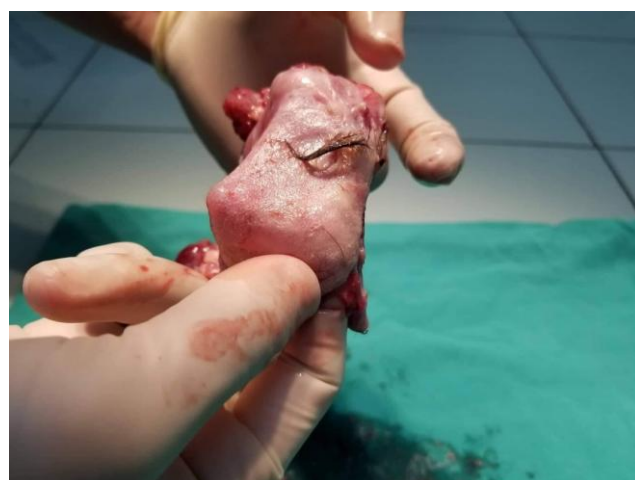

Figure 2: Imaging of the ovarian teratoma after surgery

In conclusion, after 3 months of treatment, the patient was able to resume normal activities, recognize and exercise completely normally, return to school and memory recovers well.

Case 2

The second female patient was 17 years old who has no history of medical or psychiatric problems. She began with headache, memory loss, and intermittent fever (38°C) for 6 days. The patient had high continuous fever during days, the average temperature was over 38.2 Celsius degrees continuously and her mental was affected, such as she spoke all day without determined topics, laughed for whole day then lost appetite. Also, her mother reported to doctor that she had been enduring increasingly memory loss over the past few weeks.

Later, she developed disjointed and unintelligible speech and an irregularly aggressive behavior including shouting at everyone. She was brought to the Hanoi Mental Hospital but the doctors were not sure about the diagnosis and treatment there. Afterwards, she was admitted to the National Hospital of Tropical Diseases and was treated for 4 days before hospitalized in the National Institute of mental health on June 4th with the present of sporadically incoherent language and altered manner. The results of basic tests and initial investigations were normal. Brain CT and MRI (Magnetic resonance imaging) (Figure 3) were checked without findings, Ultrasound and abdominal CT revealed a 61 x 116 mm mass likely an ovarian teratoma.

After 1 week, the mental of the patient got worse, acute confusion and a subjective fever with infectious respiratory organs and two weeks into admission, the patient developed many complications, including severe pneumonia.

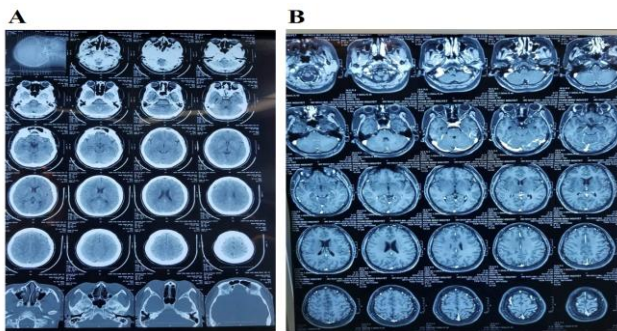


Figure 3: Imaging of the patient on MRI result; A) Imaging of a normal condition; B) Imaging did not show a condition of brain edema

More thorough methods were carried out to analysis and found out the reason. The Electroencephalograms (EEG) were accomplished and they showed general slower with unspecific characteristics and there was no evidence of abnormal paroxysmal activity. She was given a course of IV solumedrol and antibiotics (high dose and combined three types of antibiotics). We considered to find out the anti – NMDA glutamate receptor antibodies and it was positive. And surgeons removed ovarian mass by laparoscopic cystectomy after one month from the moment she had her first symptoms (Figure 4). In the following days, the patient’s condition was fast improving under ongoing corticosteroid therapy with intravenous Methylprednisolone 1 g per day for seven days and followed the routine supportive care. Hence, the histopathology was consistent with mature cystic teratoma. The results verified the appearance of nervous system tissue. The microscopic examination showed the tumor of ovary tissue and the tumor included different embryonal component. The well – differentiated element was cutaneous tissue. The mesodermal comprised of bone and cartilage tissue. In addition, there was a presence of poor differentiated element that contained immature

neuroepithelium (amount of immature neuroectoderm occupies ≤ 3 low-power magnification fields).

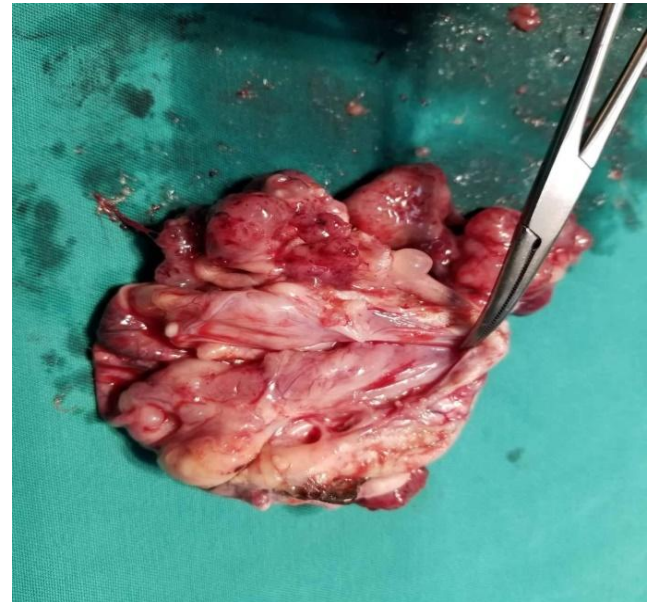


Figure 4: Imaging of the ovarian teratoma after laparoscopic cystectomy. After surgery, the patient had recovered significantly

According to the information above, we created a comparison between two patients (Table 1). The table shows the same symptoms and some basic tests to find out the cause to the disease, it also gives the differences in the treatment of two patients. Thus, it is possible to draw experience in diagnosis and treatment.

Table 1: Comparison between two cases

	Case 1: The 1 st Patient	Case 2: The 2 nd Patient
Gender	Female	Female
Age	18	17
Medical history	Normal	Normal
First symptoms	Vomiting, headache High fever (> 39 degree) Acute disorientation	Headache Intermittent fever (38 degree) Memory loss Speak and laugh whole day
Late symptoms	Urine incontinence Confusion Dull response	Incoherent speech Abnormally aggressive behavior.
Complication	Hypoxic respiratory failure	Infectious respiratory organ by Pseudomonas bacteremia.
First diagnosis	Meningitis encephalitis	Psychosis
Blood test	Normal	White blood cells increase
Biochemical test	Normal	Normal
Coagulation	Normal	Normal
Urine sediment	Positive for leukocytes	Negative Fever test: negative Dengue test: negative Tuberculosis: Negative
PCR	HSV: negative Tuberculosis: negative	
MRI brain	Mild posterior hemisphere edema	Normal
EEG	Normal	Generalized slowing characteristics Protein 0,21 g/L Glucose 3,4 mmol/L Pandy: negative
Lumbar puncture	Protein 0,81 g/L Glucose 3,9 mmol/L Pandy: positive	
Abdominal CT	90x60 mm teratoma in the right ovary	61x116 mm ovarian teratoma
Anti-NMDA glutamate receptor	Positive	Positive
Treatment	-Immunoglobulin therapy -Laparoscopic cystectomy -Corticosteroid therapy	Laparoscopic cystectomy Corticosteroid therapy
Histopathology	The present of nerve tissue and mature teratoma	The present of nervous system tissue and ovary tissue
Recovery	Recharged after several days	Recharged after two weeks

Discussion

Base on a previous study, Anti-NMDA encephalitis often happens in young women and it is usually combined with ovarian tumors, particularly teratomas [2]. The presence of a tumor in men and children is unusual [3], while in young women, encephalitis is regularly attached with ovarian teratomas [4]. Eventually, the average age of the patients in two cases are very young. The disorder causes a mental condition that appeared with noticeable psychiatric syndrome or, less often, memory decline, accompanied by the level of consciousness, abnormally behavior and unintentional movements. Two patients in this report are very young, one is 17 years old and another is 18 years old, and the first symptoms are the same (high temperature and headache). The derangement is usually beginning with headache, or malaise, then followed by a series of mental symptoms and behavior changes that lead to loss of consciousness around. The patients came in condition the psychiatric symptoms were often the most prominent but they did not respond to anti-psychotics. The patient after suffering psychiatric symptoms may have some complications related to respiratory tract and severe pneumonia appears most often. Hence, we can see that the symptoms of two cases often effected on the particular organs which were responsible for ability to remember, character, movement, autonomic control, which accounts for the unique assemblage of changes related to personality, impairments in perception and motor disorder. With cases of patients who had acute onset of psychiatric symptoms but had no unresponsive to anti-psychotic medication, we should consider that it is due to autoimmune encephalitis and should find out the cause. The progression of these manifestations in a young woman should raise a question in the dysfunction and motivate the search of an ovarian teratoma [5].

When comparing the above two cases, we found that surgical removal of ovarian tumors combined with immunotherapy would bring better results and patients would also recover faster. The first patient, although the symptoms were worse, the time for diagnosis and surgery was later, but thanks to the combination of immunoglobulin, the recovery process was faster than the second patient. The analysis suggests that the use of more immunoglobulin is helpful in the postoperative treatment of patients and addition to surgery to remove ovarian tumors. Eliminate of an abnormal ovarian mass accompanied by plasma exchange and using corticosteroids led to a brisk neurological reaction and final full recuperation. In the first case, we required more time to diagnose, and then the patient was operated and was treated with immunotherapy. And in the second case, the fact that we had previous experience so we could diagnose earlier. Therefore, the patient had teratoma ovary was

cured sooner. Due to some reasons, the second patient did not have enough condition to be used immunoglobulin but when she had surgery immediately right after diagnosis and was treated with intravenous corticosteroids for post-operative days, she could be eventual full recovered without immunotherapy. Thus, we determine that immunotherapy is frequently efficient, and it has been recommended that brisk excision of the teratoma accelerate recovery [2].

From many researches in the world, the scientists had proved that immune balancing methods eliminating causes and risk factors are the main options and chief supports of treatment plan [3]. Immune methods such as with steroids, plasmapheresis and IV Immuno globulin supports decrease antibody titers. Ovarian teratoma removal results in shorten clinical improvement. Besides, we specify that early tumor excision is the most essential way enabling brisk and full recuperation from anti-NMDAR encephalitis. If we do the operation as soon as possible, we can shorten the duration of the treatment. When comparing the results of treatment between two cases, it is clear that immunotherapy offers much better results. Indeed, the lesson is that we should try to combine both surgical and immunotherapy, not just remove ovarian tumors. In addition, early diagnosis will help patients to avoid severe neurological complications and restore memory faster. In the previous study, scientists indicated that ovarian teratomas accounted for 94% of all neoplasms which are responsible for the creation of anti-NMDAR encephalitis, with clinical improvement after tumor resection [6]. There are several methods of immunosuppressive treatments such as immunoglobulin therapy, intravenous steroids, plasmapheresis therapy or cyclophosphamide but if we just use only immunosuppressant drugs, the disease cannot be cured [7]. In contrast, the removal of ovarian tumor may be curative, so we can notice that all the immunosuppressive methods give the further support for treatment. Moreover, these drugs cost high prices so if the patients do not have the insurance, their hospital fee will be very expensive. When we compare with the results of other patients who have been reported before we see that about 80% of patients have improvement in neurological symptoms after tumor removal and immunosuppressive treatment [3]. However, there has not been any specific study to evaluate the possibility of recurrence, the disease relapses less likely in patients who do not have microscopic germ cell tumors undetectable by imaging [8]. There are even patients who are discovered with ovarian tumor after many years since they have had neurological manifestations. Therefore, after being discharged from the hospital, the patients should be examined at follow up visits to prevent recurrence. In addition, these patients should be checked for their fertility in the future.

In conclusion, Anti-NMDA-R encephalitis can be defined as a diverse syndrome with a broad differential diagnosis, disease manifestations often change but the disease responds quickly if it is treated in the right direction. Definitive diagnosis is confirmed when anti – NMDA-R antibodies are determined in the blood or cerebrospinal fluid [7]. In order to have prompt diagnosis and management, the awareness and communication between medical professionals from the various specialties are necessary, the gynecologists have an important role to make the patients have positive outcome, not only treat the disease by removing the ovarian tumors but also preserve the reproductive function for patients.

Ethical Approval

All procedures performed in studies involving human participants were in accordance with the ethical standards of the institutional and / or national research committee and with the 1964 Helsinki declaration and its later amendments or comparable ethical standards. The reports were approved by the Ethics Committee of Bach Mai hospital.

Informed Consent

The patients and their families agreed to provide the information, the images in writing/publishing this article.

References

1. Day GS, et al. Anti-NMDA-receptor encephalitis: case report and literature review of an under-recognized condition. *Journal of general internal medicine*. 2011; 26(7):811-816. <https://doi.org/10.1007/s11606-011-1641-9> PMID:21318640 PMCID:PMC3138579
2. Dalmau J, et al. Anti-NMDA-receptor encephalitis: case series and analysis of the effects of antibodies. *The Lancet. Neurology*. 2008; 7(12):1091-1098. [https://doi.org/10.1016/S1474-4422\(08\)70224-2](https://doi.org/10.1016/S1474-4422(08)70224-2)
3. Dalmau J, et al. Clinical experience and laboratory investigations in patients with anti-NMDAR encephalitis. *The Lancet. Neurology*. 2011; 10(1):63-74. [https://doi.org/10.1016/S1474-4422\(10\)70253-2](https://doi.org/10.1016/S1474-4422(10)70253-2)
4. Uchino A, et al. Pseudo-piano playing motions and nocturnal hypoventilation in anti-NMDA receptor encephalitis: response to prompt tumor removal and immunotherapy. *Internal medicine*. 2011; 50(6):627-630. <https://doi.org/10.2169/internalmedicine.50.4764> PMID:21422691 PMCID:PMC3740121
5. Shimazaki H, et al. Reversible limbic encephalitis with antibodies against the membranes of neurones of the hippocampus. *Journal of neurology, neurosurgery, and psychiatry*. 2007; 78(3):324-325. <https://doi.org/10.1136/jnnp.2006.104513> PMID:17308294 PMCID:PMC2117656
6. Wong D, Fries B. Anti-NMDAR encephalitis, a mimicker of acute infectious encephalitis and a review of the literature. *IDCases*. 2014; 1(4):66-67. <https://doi.org/10.1016/j.idcr.2014.08.003> PMID:26839775 PMCID:PMC4735025
7. Titulaer M. Treatment and prognostic factors for long-term outcome in patients with anti-NMDA receptor encephalitis: an observational cohort study. *Lancet Neurol*. 2013; 12(2):157-165. [https://doi.org/10.1016/S1474-4422\(12\)70310-1](https://doi.org/10.1016/S1474-4422(12)70310-1)
8. Mann A, Grebenciuova E, Lukas R. Anti- N-methyl-D-aspartate receptor encephalitis: diagnosis, optimal management, and challenges. *Ther. Clin. Risk Manag*. 2014; 10:517-525. <https://doi.org/10.2147/TCRM.S61967> PMID:25061311 PMCID:PMC4085332