

Wallenberg's Syndrome: An Unusual Case of Dysphagia

Aurora Loeza-del Castillo^a Josué Barahona-Garrido^b
Sergio Criales^c Sergio Chang-Menéndez^d Aldo Torre^b

Departments of ^aMedicine, ^bGastroenterology, ^cRadiology and ^dNeurology,
Instituto Nacional de Ciencias Médicas y Nutrición 'Salvador Zubirán', Mexico
City, Mexico

Key Words

Wallenberg's syndrome · Acute dysphagia · Lateral medullary infarct

Abstract

A 56-year-old man presented with sudden-onset oropharyngeal dysphagia and vomiting of central etiology. Neurological evaluation showed uvula deviation to the left, paresis of the mid-right portion of the soft palate, lateralization of gaze to the right side, and dysphonia. Magnetic resonance imaging (MRI) showed an infarction in the left lateral medullary region, therefore the diagnosis of Wallenberg's syndrome was established. The neurological issues along with the dysphagia gradually improved and the patient was discharged.

Introduction

Central control of swallowing is regulated by a central pattern generator positioned in the solitary tract nucleus and neighboring medullary reticular formation. The central pattern generator activates the cranial nerve motor neurons, including the nucleus ambiguus and vagal dorsal motor nucleus, and then innervates the muscles of deglutition [1].

Dysphagia is caused by mechanical obstruction, neurological disorders or muscular disorders among others. In the case of oropharyngeal dysphagia, it is usually either a secondary manifestation of neuromuscular diseases or a primary abnormality related to structural aberrations of the oropharynx [2].

A focused history is essential in defining the level of dysfunction and distinguishing oropharyngeal dysphagia from globus hystericus, xerostomia, or esophageal dysphagia. Also, a careful evaluation of diseases associated with swallowing dysfunction, such as

lateral medullary infarct, should be considered that may be heralded by acute dysphagia [3].

We present a case of a 56-year-old healthy patient with a minor neck trauma and sudden-onset oropharyngeal dysphagia that worsened due to grade IV esophagitis caused by vomiting of central etiology. Evaluation showed uvula deviation to the left, paresis of the mid-right portion of the soft palate, lateralization of gaze to the right side and dysphonia. Magnetic resonance imaging (MRI) showed an infarction in the left lateral medullary region. Atypical Wallenberg's syndrome diagnosis was established.

Case Presentation

A 56-year-old man was referred to our hospital due to sudden-onset dysphagia. The patient had been in good health until he experienced sudden-onset vertigo, oropharyngeal dysphagia, rightward deviation of gaze, vomiting and hoarseness. At the time of admission to hospital, he was unable to swallow solids or liquids and he complained of heartburn. Clinical examination revealed uvula deviation to the left, paresis of the mid-right side of soft palate, lateralization of gaze to the right side, and dysphonia. Blood pressure and heart rate were normal. Metabolic, renal, hematological, cardiac, lipid, or coagulation disorders were ruled out.

We performed a video fluoroscopy that showed a lack of passage of contrast medium beyond the piriform sinuses towards the distal esophagus ([fig. 1](#)); in the lateral projection, signs of aspiration were present ([fig. 2](#)). A manometric study was not performed because we did not have the equipment for upper esophageal sphincter evaluation. An upper tract endoscopy revealed grade IV esophagitis. A nasogastric tube was placed for feeding. Treatment with intravenous double dose of omeprazole was started with improvement of the heartburn symptom.

Because of the sudden onset of symptoms and neurological features, MRI was obtained showing an area of hypointensity in T1 ([fig. 3](#)) and hyperintensity in T2 and FLAIR sequences in the right lateral medullary region compatible with an infarction ([fig. 4](#) and [fig. 5](#)). In this way, the diagnosis of atypical Wallenberg's syndrome was established.

The patient had no risk factors for an ischemic, thrombotic or cardiac disease; however, an intentional search for a prothrombotic state was carried out (platelet count, prothrombin and partial thromboplastin times, lipids, C and S proteins, antithrombin III, antiphospholipid and antinuclear antibodies, chest X-ray, all being normal). As an isolated risk factor the patient had a minor trauma to the neck involving hyperextension. Immediately after the trauma the patient complained of mild neck pain, and three days later dysphagia, vertigo and the other described manifestations suddenly appeared; however, atlanto-axial subluxation and vascular lesions were ruled out. All manifestations showed at the same time, and no other abnormal signs appeared during follow-up.

A deglutition rehabilitation program was started based on oral stimulation techniques including tactile and thermal stimulation and head raising exercises to improve opening of the upper esophageal sphincter [4]. Oral feeding was progressed gradually until almost complete tolerance was achieved. The patient was discharged when swallowing reflex improved and was able to eat a diet of at least 1,800 kcal/day. One month after the onset of symptoms, vertigo, vomiting and dysphonia had disappeared. Treatment with clopidogrel 75 mg/day was started and the patient continued with omeprazole 40 mg/day p.o. for four more weeks.

Discussion

Dysphagia as the main manifestation of brain stem disorder is strongly associated with a lesion to the nucleus ambiguus in the rostral part of the medulla [5]. The clinical picture resulting from a dorsolateral medullary infarction is known as Wallenberg's syndrome and results from the occlusion of the posterior inferior cerebellar artery or of its parent vertebral artery [6, 7]. In a series of 123 consecutive patients with lateral medullary infarction documented by angiography, vertebral artery disease was present on 67% and

disease of the posterior inferior cerebellar artery in 10%. The presumed pathogenic mechanisms included large vessel infarction in 50%, arterial dissection in 15%, small vessel infarction in 13% and cardiac embolism in 5%. Unknown causes allowed 15% of cases. Hospital mortality rate was 0.8% [8].

Wallenberg's syndrome was originally described in 1895 and consists in Horner's syndrome, absent corneal reflex, lateropulsion of saccadic eye movements, nystagmus, ataxia, dysphagia, hoarseness, sensory loss over the facial region, contralateral hemiparesis, etc. [9]. A combination of signs and symptoms can manifest depending on the site of the lesion, whether rostral, caudal or medial [10]. Symptoms including ataxia, dizziness, Horner's sign, numbness of either the ipsilateral or contralateral body, vertigo, dysphagia, and hoarseness are the most frequent at onset [8, 11]. In this case the main symptom was dysphagia, accompanied by vertigo, ataxia, dysphonia, and vomiting. Dysphagia is not the most common or main symptom at onset of Wallenberg's syndrome, so this case corresponds to an atypical presentation of this disease.

The neurogenic origin of acute dysphagia should be suspected in the practice of gastroenterology, even if it represents an uncommon pathology. It may perhaps indicate a graver diagnosis such as the heterogeneous clinical pictures of lateral medullary infarction syndrome. In this case we ruled out the most common causes of prothrombotic disorders. The only risk factor that could explain a brain stem infarction was a minor neck trauma. It has been reported that minor neck trauma could be associated with lesions of the vertebral artery and also with high levels of beta-thromboglobulin and platelet factor 4 suggesting activated platelet aggregation [12]. Based on this information we suspected that neck trauma could have caused vessel damage, platelet activation and then medullary infarction, and this was the reason for treating our patient with clopidogrel. As mentioned before, an important proportion, 15% of cases, are due to unknown causes [8].

To improve our knowledge, it is important to mention that there is only one report of a case of Wallenberg's syndrome following a minor neck trauma with atlanto-axial subluxation and platelet activation [12].

Fig. 1. Esophagogram showing a lack of passage of contrast medium beyond the piriform sinuses towards the distal esophagus (arrow).

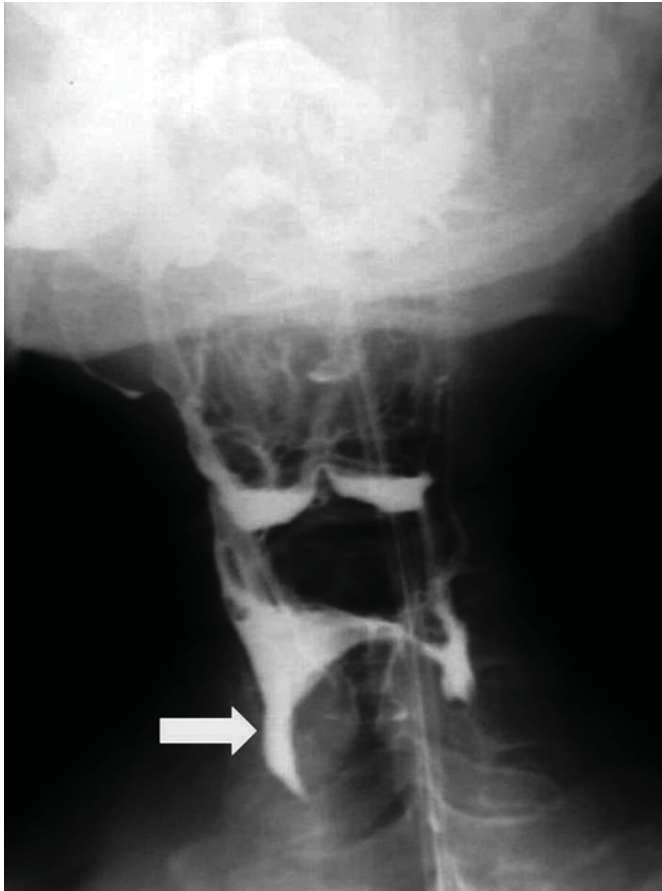


Fig. 2. Esophagogram lateral projection showing contrast medium inside of the trachea (arrow).

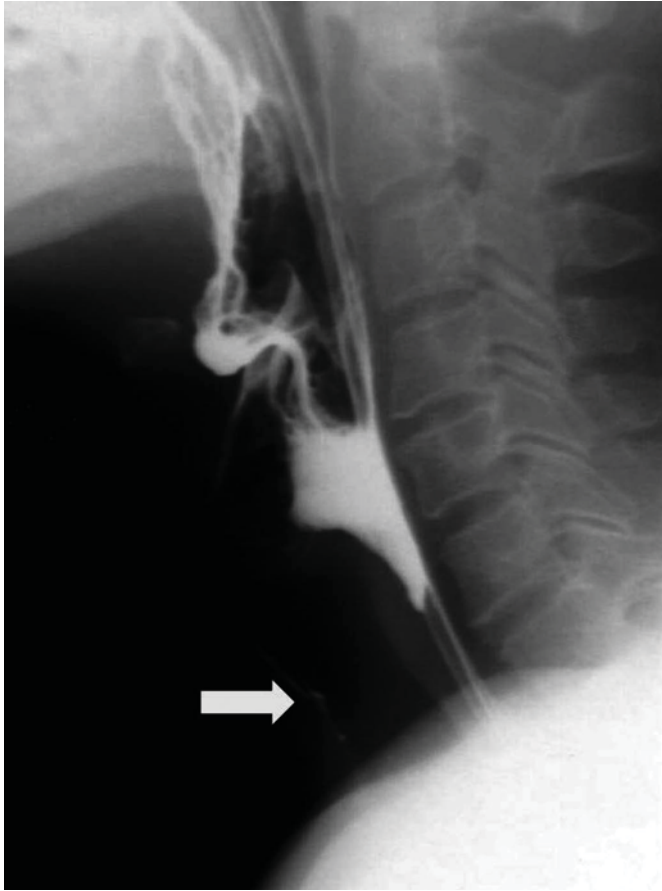


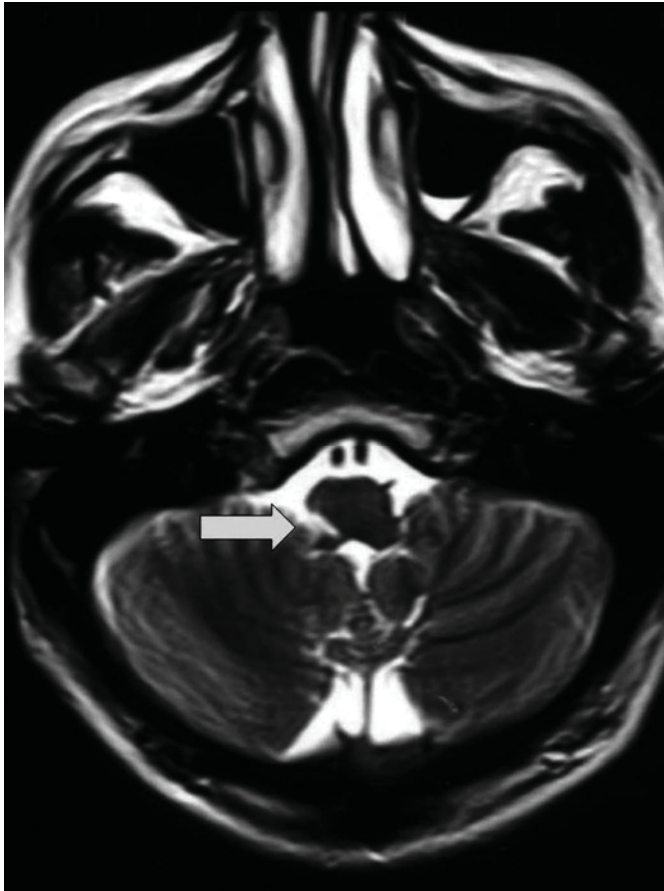
Fig. 3. MRI T1 sequence showing a hypointense lesion (arrow) in the right lateral medullary region.

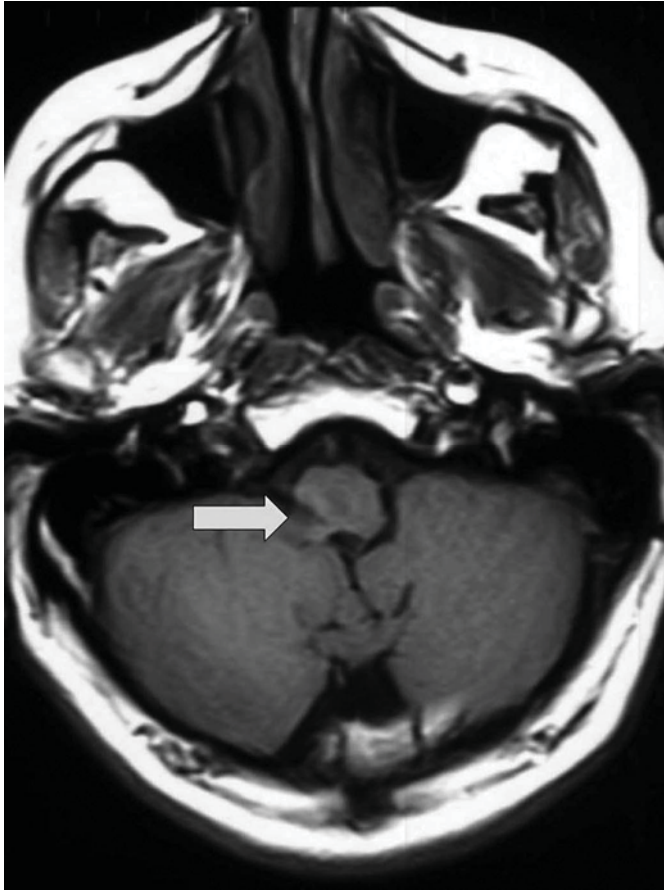

Fig. 4. MRI T2 sequence showing a hyperintense lesion (arrow) in the right lateral medullary region.

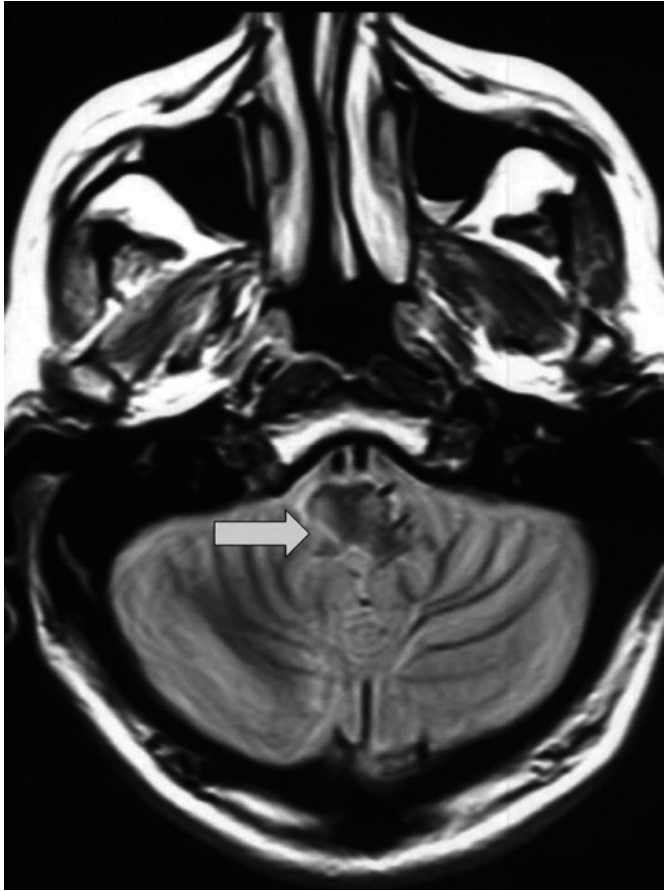

Fig. 5. FLAIR MRI sequence showing a hyperintense lesion (arrow) in the right lateral medullary region.



References

- 1 Martino R, Terrault N, Ezerzer F, Mikulis D, Diamant NE: Dysphagia in a patient with lateral medullary syndrome: insight into the central control of swallowing. *Gastroenterology* 2001;121:420–426.
- 2 Oh TH, Brumfield KA, Hoskin TL, Stolp KA, Murray JA, Bassford JR: Dysphagia in inflammatory myopathy: clinical characteristics, treatment strategies, and outcome in 62 patients. *Mayo Clin Proc* 2007;82:441–447.
- 3 Chiti-Batelli S, Delap T: Lateral medullary infarct presenting as acute dysphagia. *Acta Otolaryngol* 2001;121:419–420.
- 4 Singh S, Hamdy S: Dysphagia in stroke patients. *Postgrad Med J* 2006;82:383–391.
- 5 Kurono H, Uesaka Y, Kunimoto M, Imafuku I: The correlation between dysphagia and involvement of the ambiguous nucleus on MRI in acute-phase lateral medullary syndrome. *Rinsho Shinkeigaku* 2006;46:421–426.
- 6 Shioya H, Kikuchi K, Suda Y, Shindo K: Atypical Wallenberg's syndrome due to spontaneous vertebral arterial dissection: case report. *No To Shinkei* 2004;65:519–524.
- 7 Prosiegel M, Höling R, Heintze M, Wagner-Sonntag E, Wiseman K: The localization of central pattern generators for swallowing in humans – a clinical-anatomical study on patients with unilateral paresis of the vagal nerve, Avellis' syndrome, Wallenberg's syndrome, posterior fossa tumors and cerebellar hemorrhage. *Acta Neurochir Suppl* 2005;93:85–88.
- 8 Kim JS: Pure lateral medullary infarction: clinical-radiological correlation of 130 acute, consecutive patients. *Brain* 2003;126:1864–1872.
- 9 Schmidt D: Classical brain stem syndrome: definitions and history. *Ophthalmologie* 2000;97:411–417.
- 10 Rigueiro-Veloso MT, Pego-Reigosa R, Brañas-Fernández F, Martínez-Vázquez F, Cortés-Laiño JA: Wallenberg's syndrome: a review of 25 cases. *Rev Neurol* 1997;146:1561–1564.
- 11 Sacco RL, Freddo L, Bello JA, Odel JG, Onesti ST, Mohr JP: Wallenberg's lateral medullary syndrome: clinical-magnetic resonance imaging correlations. *Arch Neurol* 1993;50:609–614.
- 12 Arai M: Wallenberg's syndrome following minor neck trauma: a case associated with atlanto-axial subluxation, an anomaly of the axis, and platelet activation. *Rinsho Shinkeigaku* 1995;35:670–672.