



Lateral Horizontal Head Position Approach for the Lateral and Anterior Third Ventricles: A Subependymoma Clinical Case and Literature Review

Hüseyin Doğu¹ Hidayet Akdemir¹ Sırma Çetin²

¹Department of Neurosurgery, Medicine Hospital, Atlas University, Istanbul, Turkey

²Department of Pathology, Istanbul Faculty of Medicine, Istanbul University, Istanbul, Turkey

Address for correspondence Hüseyin Doğu, MD, Medicine Hospital, Hoca Ahmet Yesevi Cad. No 149, 34460, Bağcılar, Istanbul, Turkey (e-mail: huseyindogu@gmail.com).

AJNS 2022;17:642–646.

Abstract

Subependymomas are benign, slow-growing, noninvasive solitary lesions of World Health Organization Grade I cerebral ependymal origin that are rare compared with other types of ependymomas. Anterior third ventricle subependymomas are usually detected during autopsies in cases of sudden death due to acute or intermittent obstruction of the cerebrospinal fluid passage. Different surgical approaches are used for these cerebral lateral and third ventricular lesions. Serious complications can occur, either because of brain edema and acute intracranial pressure due to the lesion itself or the chosen head position and continuous use of brain retractors during the surgical procedure.

Keywords

- ▶ third ventricle
- ▶ transcallosal interhemispheric
- ▶ subependymoma

In this case report, we trust that the surgical principles we applied with the aid of two cotton pads, gravity assist, and lateral horizontal head position, and without continuous use of brain retractors in the third ventricular lesion in the transcallosal interhemispheric approach are safe and secure in preventing perioperative brain edema or early postoperative neurological complications.

Introduction

Subependymomas are rare noninvasive benign lesions of ependymal origin and were first described by Scheinker and Scheinker 1945.¹ Previous studies reported that of all World Health Organization (WHO) grade I subependymomas, 50 to 60% occur in the fourth ventricle and 30 to 40% occur in the lateral ventricles, but those in the third ventricle are rare.^{2–5} In addition, grade I subependymomas are extremely rare in adults, whereas ependymomas in the fourth ventricle are more common in children.⁶ In the literature,

serious complications have been reported in the early postoperative period because of the characteristics of the tumor or continuous use of brain retractors for the transcallosal interhemispheric approach used to reach the lateral ventricle.⁷

In the present study, we discuss the advantages of the lateral horizontal head position and transcallosal interhemispheric approach using two cotton pads in a case of acute hydrocephalus anterior third ventricle subependymoma with clinical and surgical findings consistent with those reported in the relevant literature.

article published online
October 18, 2022

DOI <https://doi.org/10.1055/s-0042-1757724>.
ISSN 2248-9614.

© 2022. Asian Congress of Neurological Surgeons. All rights reserved.

This is an open access article published by Thieme under the terms of the Creative Commons Attribution-NonDerivative-NonCommercial-License, permitting copying and reproduction so long as the original work is given appropriate credit. Contents may not be used for commercial purposes, or adapted, remixed, transformed or built upon. (<https://creativecommons.org/licenses/by-nc-nd/4.0/>)

Thieme Medical and Scientific Publishers Pvt. Ltd., A-12, 2nd Floor, Sector 2, Noida-201301 UP, India

Case Report

On March 15, 2021, a 40-year-old male patient was brought to the emergency department of our hospital. Physical examination revealed stable vital signs, but the patient was highly confused, had meaningless speech, and convulsions, with a Glasgow Coma Scale (GCS) score of 7. Non-contrast-enhanced brain computed tomography in the emergency department revealed unilateral asymmetric acute hydrocephalus and a suspicious lesion at the level of the foramen of Monro in the left lateral ventricle (►Fig. 1). Emergent ventriculostomy was performed. In the 18th hour of cerebrospinal fluid (CSF) drainage, the patient's GCS score increased to 13 to 14 on neurological examination (NE). Brain magnetic resonance imaging (MRI) revealed a contrast-enhancing lesion extending from the third ventricle to the left lateral ventricle, with a diameter of 22 × 28 mm, and acute hydrocephalus (►Fig. 2). Surgery was performed on March 17, 2021, via the transcallosal interhemispheric approach.

Surgical Position and Technique

The patient was anesthetized and placed in the supine position. Then, the patient was turned to the left lateral decubitus position at a ratio of 2:3 from the supine position. Next, the head was lifted 45 degrees, turned 20 to 30 degrees to the left, and the neck was brought to 0 to 5 degrees flexion. The patient was then fixed with a skull-pin head holder (►Fig. 3). Free craniotomy was performed in the left frontoparietal region, with two-thirds of the 3 × 3 cm free craniotomy flap on the left side encompassing

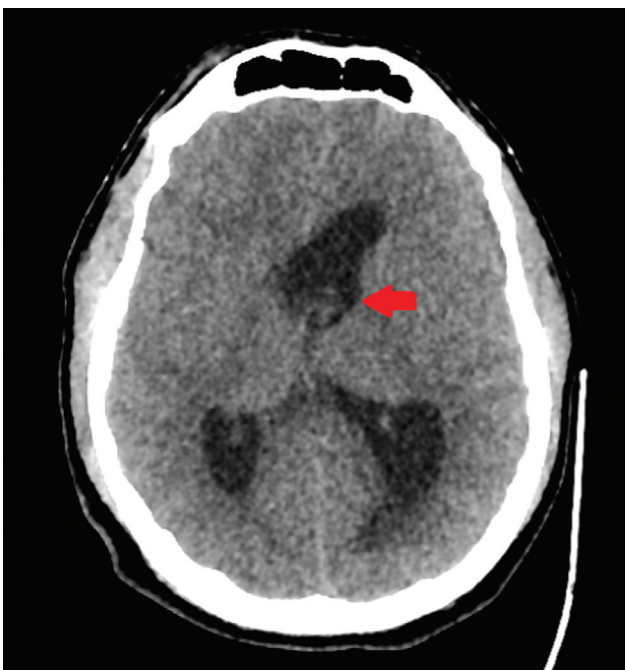


Fig. 1 Preoperative head computed tomography in the axial plane showing acute hydrocephalus and a suspicious lesion at the level of the foramen of Monro in the left lateral ventricle (red arrow).

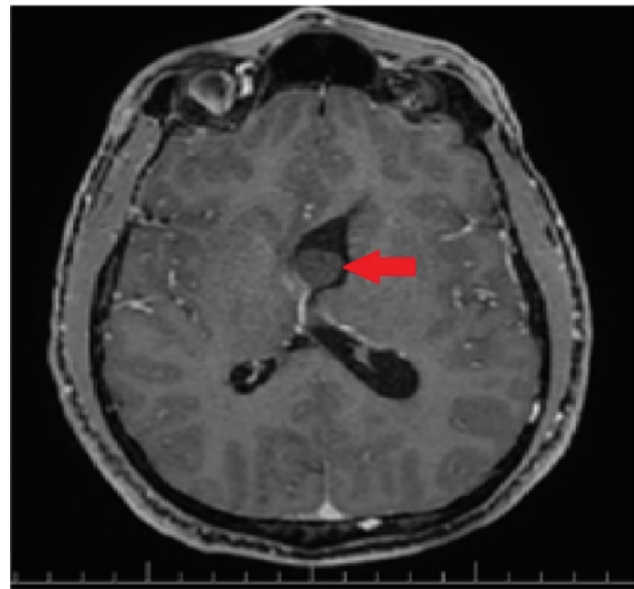


Fig. 2 Preoperative contrast-enhanced T1-weighted axial brain magnetic resonance imaging scan showing a mild, contrast-enhancing, well-demarcated solid lesion extending from the third ventricle to the left lateral ventricle, with a diameter of 22 × 28 mm, and unilateral acute hydrocephalus (red arrow).

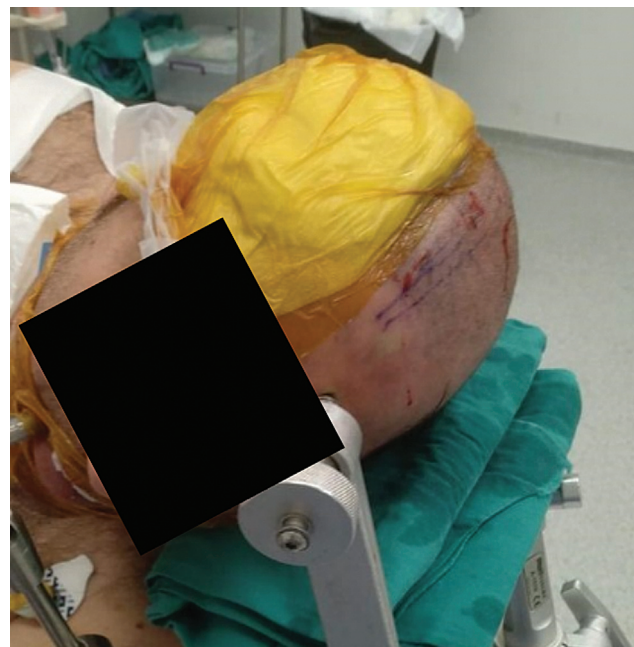

Fig. 3 Surgical position: The head is raised 45 degrees, turned 20 to 30 degrees to the left, and the neck is brought to 0 to 5 degrees flexion. The patient is fixed with a head holder.

the superior sagittal sinus (SSS). The dura mater base was opened in a C shape with the same length of the SSS. Upon entering the interhemispheric corridor with the falx, two 2 × 2 cm round cotton pads, which would replace intermittent brain retractors, were placed in front of and behind the craniotomy flap. With the help of the two cotton pads placed in the surgical area, the corpus callosum was reached easily by dissecting the cingulate gyrus at the free edge of

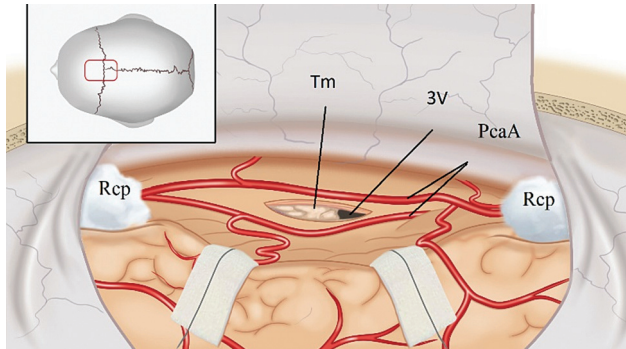


Fig. 4 Schematic illustration of the positioning and surgical corridor provided by the interhemispheric transcalsal approach with the help of two round cotton pads placed in the surgical area. Abbreviations: 3V, third ventricle; Tm, tumor; Rcp, round cotton pad; PcaA, pericallosal artery.

the falx. A 1.5 cm callosotomy was performed in the foramen of Monro by using an intraoperative neuronavigation control. After the left lateral ventricle was opened, the following tumor surgery procedures were continued with the surgical view provided by the cotton pads that were placed on the field (**Fig. 4**). Thereby, we minimized any additional trauma caused by continuous use of brain retractors. The lesion in the left lateral ventricle was clear and dirt-white in color and was at the level of the foramen of Monro, extending into the third ventricle with prominent capillaries and a cream-white-colored surface (**Fig. 5**). After confirming that it was solitary and pedunculated, the small connection was cut, and en bloc resection was performed (**Fig. 6**). After the lesion was removed, the CSF passage was found to be provided by the third ventricle, and the ventriculostomy catheter was removed. Histopathological examination revealed that the lesion was a WHO grade I subependymoma (**Fig. 7A, B**). The patient's control postoperative contrast-enhanced brain MRI scan showed that the left lateral ventricle was asymmetrically larger than the right lateral ventricle (**Fig. 8**). The patient did not have neurological deficits in the early postoperative period and was discharged on the 10th postoperative day. No neurological deficits were observed in the NE performed in the third and sixth month.

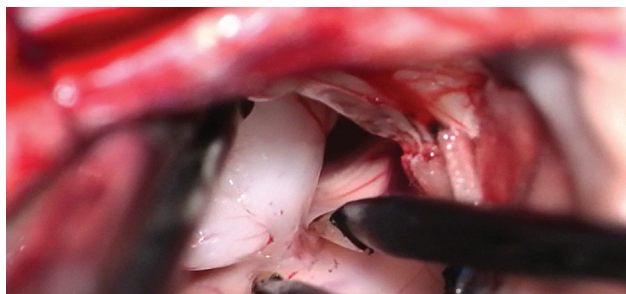

Fig. 5 The lesion in the left lateral ventricle is clear and dirt-white in color. It is at the level of the foramen of Monro, extending into the third ventricle, with prominent capillaries, and a cream-white-colored surface.

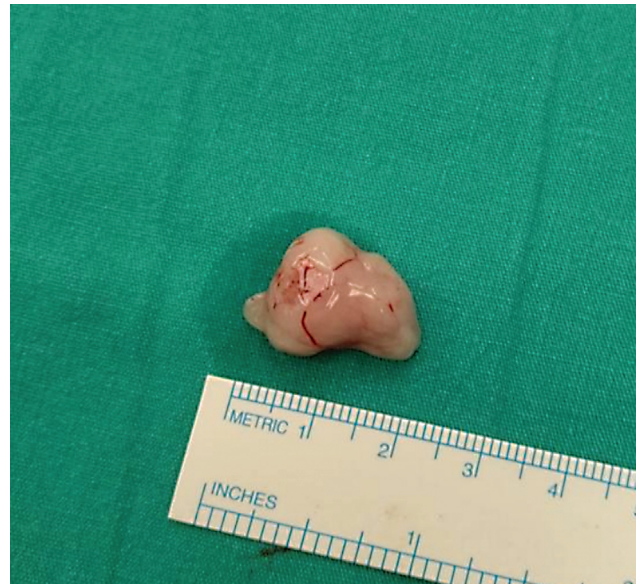

Fig. 6 Macroscopic appearance of the tumor.

Discussion

The WHO grade I anterior third ventricle subependymomas are usually detected during autopsies in cases of sudden death due to acute or intermittent obstruction of the CSF passage, sometimes when neuroimaging is performed during NE for complaints of headache, amnesia, behavioral

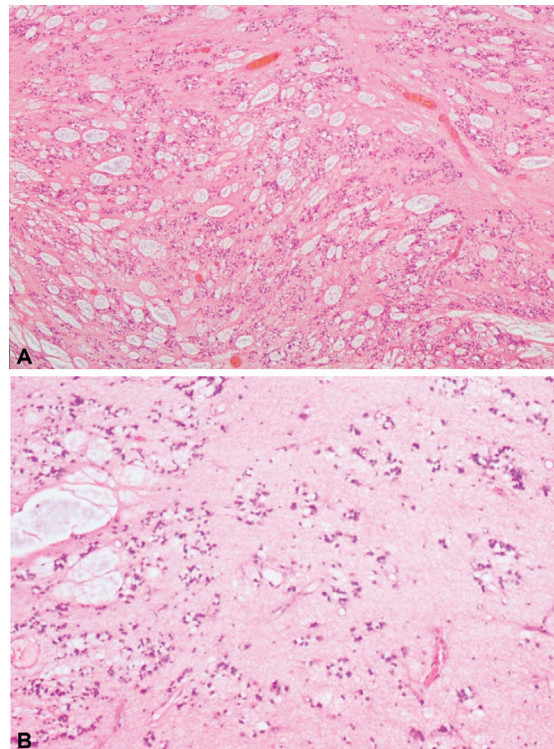


Fig. 7 (A, B) Histopathologic examination result showing a subependymoma with microcysts filled with myxoid substance and clusters of small uniform cells embedded in the fibrillary background (hematoxylin-eosin staining, original magnifications: A $\times 40$, and B $\times 100$).

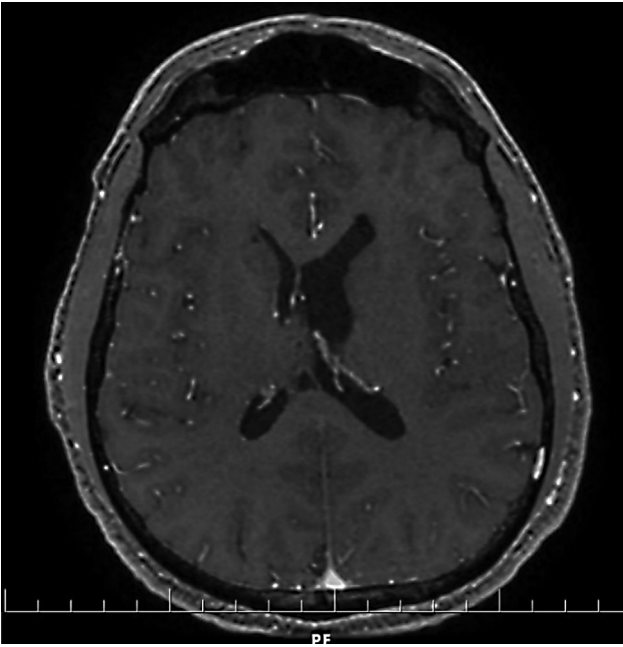


Fig. 8 Control of early postoperative contrast-enhanced T1-weighted brain magnetic resonance imaging in the axial plane. The tumor is totally resected, and the right lateral ventricle is moderately dilated.

disorders, and sometimes as part of routine screening tests for those admitted to the emergency services due to trauma or injury.^{6,8} When pure third ventricle subependymomas reach approximately 2 cm in size, they can become symptomatic by causing CSF flow blockage in the foramen of Monro.⁹ Hydrocephalus has been reported in 94% of intraventricular symptomatic subependymomas.¹⁰ Subependymomas have been mostly found in the ventricular lumen and rarely found in the brain parenchyma.¹¹ In addition, subependymomas cause central herniation or sudden death due to unilateral acute hydrocephalus with obstruction of the CSF passage from the third ventricle.^{12,13}

In our case, the patient presented with complaints of acute hydrocephalus, with a 22 × 28 mm diameter lesion, which almost became compatible with the anatomy of the anterior third ventricle. In a 20-year period, Fujisawa et al reported only five subependymoma cases among 1,500 brain tumors, three of which were in the foramen of Monro, one was in the right foramen of Monro, and the other was in the septum pellucidum.⁹ Of the cases, one was diagnosed after a traffic accident; one because of semicomatose; one because of sleepiness; and one on evaluation of headaches. Patients usually die of acute hydrocephalus before surgical treatment, and the lesions are detected in autopsies.

The gravity effect of the surgical approach chosen during surgical planning for deeply located lesions such as the lateral or anterior third ventricle, the chosen head position, or the protection of the cortical veins during interhemispheric dissection is crucial in preventing postoperative neurological deficits or complications. In addition, continuous brain retractor application in the surgical approach chosen for these lesions is also among the important risk factors for the emergence of possible neurological deficits.

The transcallosal interhemispheric approach was first used in 1922 by Dandy to expose the posterior transcallosal interhemispheric corridor to further expose the third ventricle, and this approach was developed by Stein.^{14,15} Transcallosal interhemispheric intervention is more frequently preferred than the transcortical approach to reach the anterior and middle parts of the third and lateral ventricles because of the low risks of complications such as hemiparesis and epilepsy.¹⁶ Previous studies reported that even if the transcallosal interhemispheric approach is well tolerated as compared with the transcortical approach, serious complications such as hemiparesis, amnesia, mutism, aphasia, cranial nerve VI and VII pareses, and tactile transfer deficits can be observed.^{7,17} The first study to prevent these serious fatal complications was conducted by Clark in 1988, who described the lateral horizontal head position and gravity-assisted technique.¹⁸ By modifying this technique, Shevach et al applied the horizontal head position and gravity assist by lifting the head 45 degrees in 15 patients with lateral ventricle or midline lesions.¹⁹ The authors emphasized the importance of turning the head laterally and upward for the gravity-assisted lateral horizontal head position in planning surgery to preserve venous blood flow from the brain in the transcallosal interhemispheric approach. In our preferred approach, gravity support, lateral horizontal head position, use of two cotton pads, adequate anesthetic support, adequate brain laxity, and especially gentle microdissection of the cingulate gyrus and additional CSF drainage after the incision of the corpus callosum increase the surgical field of vision and eliminate the need for the continuous use of brain retractors during intraventricular tumor surgery. The tumor surgical procedure is continued safely and securely with the view provided by the two cotton pads placed in front of and behind the craniotomy flap. With the aid of the two cotton pads, the possible surgical complications of these deeply located lesions are minimized by preventing contusions; lacerations of the brain tissue, especially during dissection of the cingulate gyrus; or edema related to vasospasm of the pericallosal arteries from the vascular structures. In addition, through our approach, a wide viewing angle is provided by the two cotton pads used inside the brain, allowing a wide microscopic area and panoramic view from the lateral ventricle, genu anteriorly, and atrium posteriorly.

Conclusion

Subependymomas are rare benign, slow-growing, solitary, and pedunculated intraventricular lesions. With correct diagnosis and urgent surgical treatments, as in our patient, the prognosis is excellent. We believe that by applying the principles of our preferred surgical approach (use of two cotton pads, gravity assist, lateral horizontal head position, and nonuse of continuous brain retractors), an alternative method can be created for reducing the risks of perioperative brain edema, additional postoperative neurological deficits, and complications, which are more common in standard approaches for third ventricle lesions.

Authors' Contributions

Hüseyin Doğu was involved in conceptualization, designing, definition of intellectual content, literature search, clinical studies, data analysis, manuscript preparation and editing. Hidayet Akdemir was involved in conceptualization, definition of intellectual content, clinical studies, data analysis, and manuscript preparation. Sırma Çetin contributed to clinical studies and data acquisition. Hüseyin Doğu and Hidayet Akdemir provided guarantee.

Funding

None.

Conflict of Interest

None declared.

References

- Scheinker IM, Scheinker IM. Subependymoma: a newly recognized tumor of subependymal derivation. *J Neurosurg* 1945; 2:232–240
- Louis DN, Ohgaki H, Wiestler OD, et al. WHO Classification of Tumours of the Central Nervous System. Lyon: International Agency for Research in Cancer (IARC Press); 2016
- Scheithauer BW. Symptomatic subependymoma. Report of 21 cases with review of the literature. *J Neurosurg* 1978;49(05): 689–696
- Lombardi D, Scheithauer BW, Meyer FB, et al. Symptomatic subependymoma: a clinicopathological and flow cytometric study. *J Neurosurg* 1991;75(04):583–588
- Rushing EJ, Cooper PB, Quezado M, et al. Subependymoma revisited: clinicopathological evaluation of 83 cases. *J Neurooncol* 2007;85(03):297–305
- Nowak A, Marchel A. Surgical treatment of intraventricular ependymomas and subependymomas. *Neurol Neurochir Pol* 2012;46(04):333–343
- Apuzzo MJ, Litofsky NS. Surgery in and around the anterior third ventricle. In Apuzzo MJ, ed. *Brain Surgery Complication Avoidance and Management*. New York, NY: Churchill Livingstone Inc.; 1993:541–577
- Kurukumbi M, Muley A, Ramidi G, Wynn Z, Trouth AJ. A rare case of subependymoma with an atypical presentation: a case report. *Case Rep Neurol* 2011;3(03):227–232
- Fujisawa H, Hasegawa M, Ueno M. Clinical features and management of five patients with supratentorial subependymoma. *J Clin Neurosci* 2010;17(02):201–204
- Chiechi MV, Smirniotopoulos JG, Jones RV. Intracranial subependymomas: CT and MR imaging features in 24 cases. *AJR Am J Roentgenol* 1995;165(05):1245–1250
- Ragel BT, Osborn AG, Whang K, Townsend JJ, Jensen RL, Couldwell WT. Subependymomas: an analysis of clinical and imaging features. *Neurosurgery* 2006;58(05):881–890, discussion 881–890
- Mørk SJ, Morild I, Giertsen JC. Subependymoma and unexpected death. *Forensic Sci Int* 1986;30(04):275–280
- Ortiz-Reyes R, Dragovic L, Eriksson A. Sudden unexpected death resulting from previously nonsymptomatic subependymoma. *Am J Forensic Med Pathol* 2002;23(01):63–67
- Dandy WE. Diagnosis, localization and removal of tumors of the third ventricle. *Bull Johns Hopkins Hosp* 1922;33:188–189
- Stein BM. Transcallosal approach to third ventricular tumors. In Schmidek HH, Sweet WH, eds. *Current Techniques in Operative Neurosurgery*. New York: Grune & Stratton; 1977:247–255
- Winston KR, Cavazzuti V, Arkins T. Absence of Neurological and behavioral abnormalities after anterior transcallosal operation for third ventricular lesions. *Neurosurgery* 1979;4(05):386–393
- Ehni G. Interhemispheric and percallosal (transcallosal) approach to the cingulate gyri, intraventricular shunt tubes, and certain deeply placed brain lesions. *Neurosurgery* 1984;14(01):99–110
- Clark K. The occipital transtentorial approach to the pineal region. In: Schmidek HH, Sweet WH, eds. *Operative Neurosurgical Techniques*. Orlando: Grune & Statton, Inc; 1988:11–418
- Shevach I, Cohen M, Rappaport ZH. Patient positioning for the operative approach to midline intracerebral lesions: technical note. *Neurosurgery* 1992;31(01):154–155