



CLINICAL INVESTIGATIVE STUDY

Metabolic changes in the cingulate gyrus, precuneus, and white matter in anorexia nervosa using multivoxel MR spectroscopy

Alice Regnaud¹ | José Boto¹ | Antoine Klauser^{2,3} | Karl-Olof Lövblad¹ |
Maria Isabel Vargas¹ | François Lazeyras^{2,3}

¹ Division of Neuroradiology, Faculty of Medicine of Geneva, Geneva University Hospital, Geneva, Switzerland

² Department of Radiology and Medical Informatics, University of Geneva, Geneva, Switzerland

³ Center for Biomedical Imaging (CIBM), University of Geneva, Geneva, Switzerland

Correspondence

Alice Regnaud, Division of Neuroradiology, Faculty of Medicine of Geneva, Geneva University Hospital, Rue Gabrielle-Perret-Gentil 4, 1205 Genève, Switzerland.

Email: alice.regnaud@affidea.ch

Funding information

This study was supported in part by the startup funds of the Department of Radiology of the Geneva University Hospital and by the Center for Biomedical Imaging (CIBM).

Abstract

Background and Purpose: This study aimed to highlight anorexia nervosa-related metabolic changes in different brain regions with different gray and white matter contents.

Methods: In a prospective study, 25 anorexic patients with mean body mass index (BMI) of 14.79 kg/m² (range 10.04–20.58) were compared with 15 healthy controls with mean BMI of 21.08 kg/m² (range 18.36–27.34). Two-dimensional magnetic resonance spectroscopic imaging was acquired in the axial plane above the corpus callosum, including frontal, precentral, postcentral, cingular, and parietal regions, as well as the precuneus, each voxel containing gray and white matter.

Results: In the anorexic group, a significant increase of choline/creatinine was observed in all brain regions except the precuneus: frontal ($p = 0.009$), cingulate ($p = 0.001$), precentral ($p = 0.001$), postcentral ($p = 0.001$), and parietal ($p = 0.002$); and in white and gray matter ($p < 0.001$). Macromolecules09/creatinine was decreased in the following regions: frontal ($p = 0.003$), cingulate ($p < 0.001$), precentral ($p = 0.004$), and precuneus ($p = 0.007$), and in white and gray matter ($p < 0.05$). We observed significantly lower values of N-acetyl aspartate/creatinine in the frontal ($p < 0.001$) and precentral ($p < 0.001$) regions and in voxels containing more than 50% white matter ($p = 0.001$); and significantly lower values of myo-inositol/creatinine in the precentral ($p = 0.006$), postcentral ($p < 0.001$), and precuneus ($p = 0.006$) regions.

Conclusions: We observed an increase in choline/creatinine in anorexics, possibly reflecting increased cell turnover; a decrease in macromolecules, which was particularly low in the cingulate and precuneus the former being known to be altered in eating disorders; and a decrease in N-acetyl aspartate/creatinine considered as a marker of neuronal density and function.

KEYWORDS

anorexia nervosa, brain metabolites, magnetic resonance spectroscopy, multivoxel

This is an open access article under the terms of the [Creative Commons Attribution-NonCommercial-NoDerivs](https://creativecommons.org/licenses/by-nc-nd/4.0/) License, which permits use and distribution in any medium, provided the original work is properly cited, the use is non-commercial and no modifications or adaptations are made.

© 2021 The Authors. *Journal of Neuroimaging* published by Wiley Periodicals LLC on behalf of American Society of Neuroimaging

INTRODUCTION

Anorexia nervosa is essentially a female eating behavior disorder, which leads to a strict and voluntary food deprivation for several months or even years. This disorder has a relatively low prevalence in the general population according to the DSM-IV-TR (Diagnostic and Statistical Manual of Mental Disorders-IV-Text Revision) criteria, approximately 0.9–2% in women and 0.1–0.3% in men.¹ However, these numbers are expected to increase with the new DSM-V criteria.² Anorexia nervosa carries a risk of somatic and psychological complications, such as heart failure, osteoporosis, infertility, depression, a risk of chronicity, relapse, and social disinsertion, and may lead to death in 10% of cases.

Reduced volumes of both white matter (WM) and gray matter (GM) have been shown in anorexics,³ as well as persistent GM volume deficits in weight-recovered patients.⁴ Gaudio et al. have also described a significant decrease in global GM in these patients as well as a significant region-specific decrease in GM volume bilaterally in the middle cingulate cortex, the precuneus, and the parietal lobule. This suggests that there might be a region-specific GM vulnerability that could play a role in the pathophysiology of the disease given that these regions are involved in the manipulation of mental images and the mental representation of the self.⁵

Anorexia nervosa is also responsible for metabolic changes, which has been a topic of interest for several authors since the 1990s, occasionally with contradictory results. The aim of our work was, therefore, to characterize cerebral metabolic changes in anorexics, while highlighting regional variations as well as variations depending on the relative content in WM and GM; with special attention to the cingulate which seems to play a key role in eating disorders, through its involvement in the image of the body, which is disturbed in anorexia nervosa and anxiety mechanisms.^{6,7}

METHODS

In a prospective study carried out in the Department of Neuroradiology of Geneva University Hospitals, from December 29, 2014 to February 19, 2018, 25 patients suffering from anorexia nervosa aged 16–48 years (mean, 25.88 years) with mean body mass index (BMI) of 14.79 kg/m² (range 10.04–20.58 kg/m²) were compared with 15 healthy female volunteers aged 22–32 years (mean, 26.53 years) with

mean BMI of 21.08 kg/m² (range 18.36–27.34 kg/m²), who gave written consent to participate in the study (Table 1). The institutional ethics committee approved the study.

The inclusion criteria were anorexia nervosa diagnosed according to DSM-IV criteria by a psychiatrist, and the absence of concomitant somatic disease. MRIs were performed at the start of the patient's medical management, and patients did not benefit from any oral or parenteral medical supplementation at this stage of management, which could have potentially influenced our results.

All patients and controls underwent brain MRI in the Department of Neuroradiology of Geneva University Hospitals, on a 3T Siemens Prisma scanner (Siemens Healthcare, Erlangen, Germany) with the following imaging protocol: T1 MPRAGE (Magnetization Prepared Rapid Acquisition Gradient Echo), 3D fluid attenuated inversion recovery, T2 axial, and 2D Semi-LASER (Localized by Adiabatic Selective Refocusing) magnetic resonance spectroscopic imaging (MRSI) with 40 ms echo time and 1500 ms repetition time. MRSI was acquired with a slice thickness of 15 mm, a 160×180 mm field-of-view (FOV), and a 16×16 encoding matrix yielding a voxel size of 1.69 cc and an acquisition time of 6.4 min. A semi-LASER sequence that minimizes chemical shift artifacts⁸ was planned with a 80×90 mm volume-of-interest (VOI) at the center of the FOV in the axial plane just above the corpus callosum (Figure 1A). Each voxel in the VOI (8×8 voxels) was classified into six different brain regions, according to the anatomical location of the sulci in the three spatial planes: superior and middle frontal, cingulate, precentral, postcentral, parietal, and precuneus (Figure 1B). The voxels were subsequently classified according to their content in WM and GM according to visual analysis of the MPRAGE sequence in the three planes of space (matrix = 288×288; voxel size = 0.9×0.9×0.9 mm³; FOV = 250 mm):

- GM content: GM > 75% - WM/GM content: 75% > WM > 50%
- GM/WM content: 75% > GM > 50% - WM content: WM > 75%

We analyzed different ratios of metabolites, including myoinositol/creatine (ml/Cr), choline/creatine (Cho/Cr), N-acetyl aspartate/creatine (NAA/Cr), and macromolecules/creatine (MM09/Cr). We excluded lactate and lipids at 1.3 ppm due to an overlap of their peaks on the spectrum, which did not allow reliable discrimination between the two peaks. The values recorded corresponded to the areas under the peaks, assessed with the Siemens Syngo software

TABLE 1 Demographic characteristics of patients and controls

	Patients	Controls	<i>p</i>
<i>n</i>	25	15	–
Age (years)	25.88 ± 9.51 (16–48)	26.53 ± 3.18 (22–32)	0.755
Height (m)	1.63 ± 0.06 (1.48–1.76)	1.65 ± 0.06 (1.52–1.75)	0.273
Weight (kg)	39.38 ± 8.48 (22–56)	57.5 ± 9.57 (43–75)	< 0.001
BMI (kg/m ²)	14.79 ± 2.61 (10.04–20.58)	21.08 ± 2.83 (18.36–27.34)	< 0.001

Abbreviations: BMI, body mass index; *n*, number of subjects.

Note: Height and weight expressed as mean ± standard deviation (range).

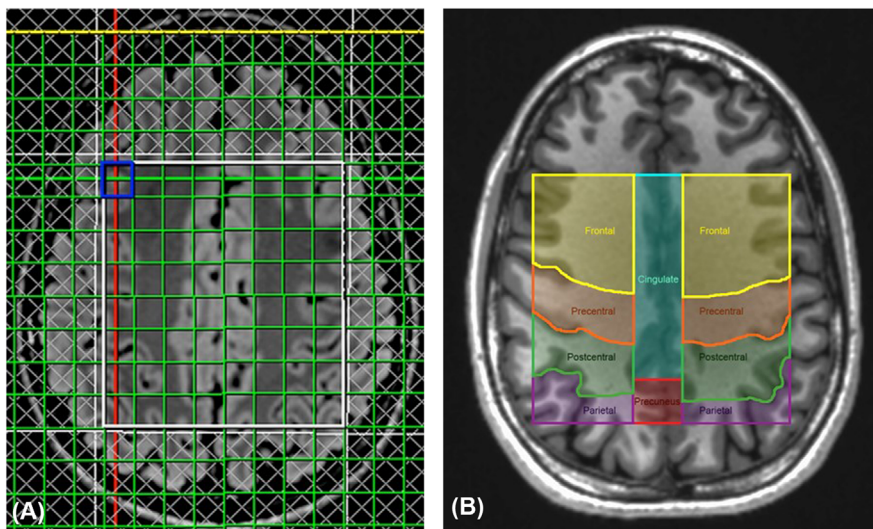


FIGURE 1 Semi-LASER volume of interest consisting of 64 voxels in the axial plane positioned above the corpus callosum (A). Volume segmentation into six regions: frontal, precentral, postcentral, cingulate, parietal, and precuneus (B) [Color figure can be viewed at wileyonlinelibrary.com]

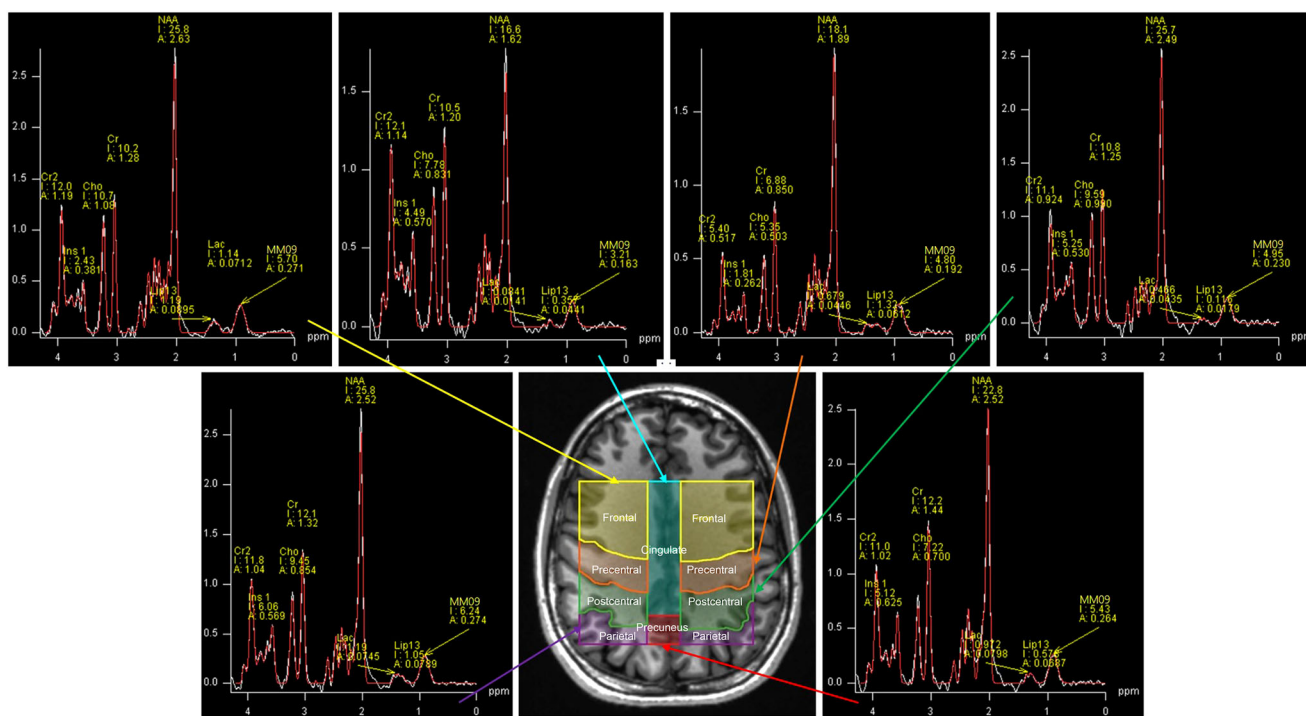


FIGURE 2 Example of spectra obtained by MRSI in the six different brain regions explored, in healthy volunteers [Color figure can be viewed at wileyonlinelibrary.com]

(Siemens Healthcare) (Figures 2 and 3).^{9,10} Processing was performed without user interaction and consisted of the following steps: Gaussian apodization (400 ms), spectral shift correction, sixth-order polynomial baseline correction, and zero-order phase correction. Curve fitting with Gaussian lineshape included NAA (main peak at 2.01 ppm and five other resonances between 2.46 and 2.84 ppm), Cr (3.02 ppm),

Cho (3.21 ppm), ml (3.56 ppm), Cr2 (3.91 ppm), Lac (1.33 ppm), lip13 (1.23 ppm), and MM09 (0.9 ppm). In addition, glutamine/glutamate was fitted with six resonances between 2.10 and 3.80 ppm, but not reported due to the overlap and J-coupled effects of these resonances. Cr (3.02 ppm) was used as an internal reference. Macromolecules level refers to the MM09 area. One patient was excluded because the

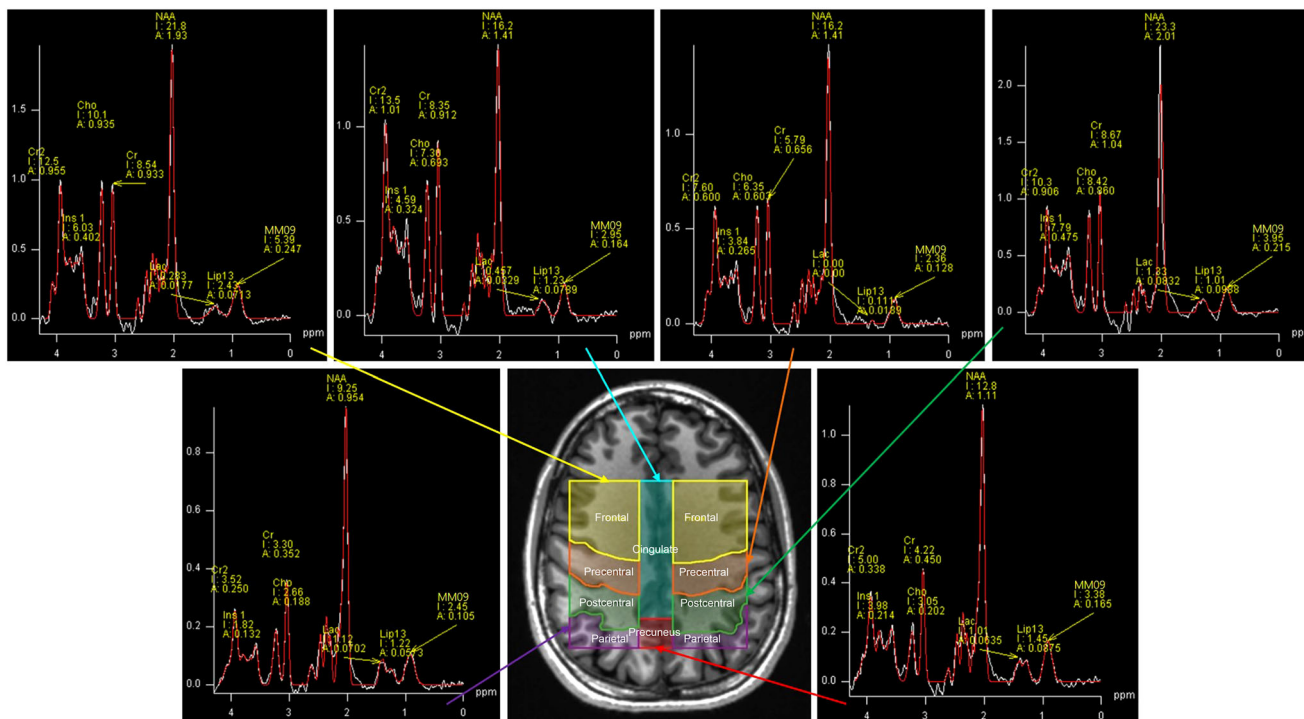


FIGURE 3 Example of spectra obtained by MRSI in the six different brain regions explored, in anorexics [Color figure can be viewed at wileyonlinelibrary.com]

morphometric sequences and the spectra were altered by artifacts due to the presence of orthodontic material. In addition, 12 voxels were excluded in six anorexic patients because of their proximity to lipids of the cranial vault causing alterations in the spectral data ($n = 7$), or their excessive content in cerebrospinal fluid ($n = 5$).

Comparison of demographic data between anorexics and controls was performed by independent samples *T* test. Homogeneity of variances between groups was evaluated by Levene's test. If this test was significant, equal variances were not assumed.

Descriptive statistics were obtained for all metabolites in the different brain regions, white and gray matter contents, and anorexics versus controls. Means of metabolites between levels were compared by a linear mixed model using a restricted maximum likelihood function, type III sum of squares assuming a diagonal covariance matrix. This model takes into account lack of independence between observations in the same subject. Fixed effects were level of the independent variable and age as a covariate. No random effects were used. If significant differences between means were identified, pairwise comparisons were performed by *T* test using a Bonferroni correction for multiple comparisons.

The association of the metabolite ratios with BMI and disease duration was investigated by Pearson correlation.

SPSS (version 22) was used to perform all statistical analyses and a 0.05 two-tailed significance level was used for all statistical tests.

RESULTS

Differences in the distribution of metabolites in anorexics and controls separately

Brain regions

There were significant differences between the ratios of metabolites in the six regions considered, both in the anorexia ($p < 0.001$) and in the control ($p < 0.001$) groups (Table 2).

The ml/Cr was the lowest in the frontal region in the anorexia group ($p < 0.001$, compared to the parietal region) and control group ($p < 0.05$ compared to the postcentral and parietal regions and the precuneus).

In both groups, Cho/Cr varied significantly between all regions ($p < 0.001$), except between the frontal and precentral regions; with the lowest values recorded in the parietal lobe and the precuneus, and the highest values in the frontal and precentral regions. In the anorexia group, NAA/Cr varied significantly between all regions, except between the cingulate and precuneus, which showed the lowest values, and between the precentral and parietal regions, which showed the highest values. Differences between regions were less striking in controls, similarly with the lowest values of NAA/Cr observed in the cingulate, and the highest values in the precentral and parietal regions. In both groups, MM09/Cr was lower in the cingulate (significantly

**TABLE 2** Comparisons of metabolite ratios in different brain regions within the anorexic and control groups

	Group	Frontal	Cingulate	Precentral	Postcentral	Parietal	Precuneus	<i>p</i>
ml/Cr	Anorexic	0.49 (0.47, 0.51)	0.54 (0.51, 0.56)	0.50 (0.47, 0.53)	0.54 (0.51, 0.57)	0.58 (0.55, 0.62)	0.53 (0.47, 0.60)	< 0.001
	Control	0.50 (0.48, 0.53)	0.54 (0.52, 0.57)	0.57 (0.53, 0.60)	0.61 (0.57, 0.64)	0.58 (0.55, 0.62)	0.61 (0.55, 0.67)	< 0.001
Cho/Cr	Anorexic	1.07 (1.06, 1.09)	0.93 (0.91, 0.94)	1.11 (1.08, 1.14)	0.98 (0.96, 1.00)	0.85 (0.83, 0.87)	0.71 (0.68, 0.74)	< 0.001
	Control	1.06 (1.05, 1.08)	0.92 (0.90, 0.93)	1.06 (1.04, 1.09)	0.97 (0.94, 0.99)	0.81 (0.79, 0.82)	0.63 (0.66, 0.71)	< 0.001
NAA/Cr	Anorexic	2.46 (2.44, 2.48)	2.11 (2.08, 2.13)	2.52 (2.49, 2.55)	2.33 (2.29, 2.37)	2.54 (2.50, 2.59)	2.08 (2.02, 2.14)	< 0.001
	Control	2.52 (2.49, 2.55)	2.09 (2.06, 2.11)	2.61 (2.57, 2.65)	2.41 (2.36, 2.45)	2.61 (2.56, 2.65)	2.55 (2.49, 2.60)	< 0.001
MM09/Cr	Anorexic	0.52 (0.51, 0.53)	0.50 (0.49, 0.50)	0.54 (0.53, 0.55)	0.51 (0.50, 0.52)	0.58 (0.56, 0.61)	0.52 (0.49, 0.55)	< 0.001
	Control	0.54 (0.53, 0.56)	0.54 (0.53, 0.55)	0.57 (0.55, 0.58)	0.51 (0.49, 0.52)	0.57 (0.55, 0.60)	0.60 (0.57, 0.64)	< 0.001

Note: Values are estimated marginal mean (95% confidence interval); *p* values result of parametric tests.

Abbreviations: Cho, choline; Cr, creatine; ml, myo-inositol; MM09, macromolecules; NAA, N-acetyl aspartate.

TABLE 3 Comparisons of metabolite ratios between different relative contents of GM and WM within the anorexic and control groups

	Group	GM	GM/WM	WM/GM	WM	<i>p</i>
ml/Cr	Anorexic	0.52 (0.50, 0.54)	0.50 (0.48, 0.53)	0.52 (0.49, 0.54)	0.54 (0.52, 0.56)	0.223
	Control	0.52 (0.49, 0.54)	0.56 (0.54, 0.58)	0.54 (0.51, 0.56)	0.60 (0.57, 0.63)	< 0.001
Cho/Cr	Anorexic	0.86 (0.84, 0.87)	0.90 (0.89, 0.92)	1.00 (0.98, 1.02)	1.19 (1.17, 1.21)	< 0.001
	Control	0.80 (0.78, 0.81)	0.85 (0.84, 0.86)	0.94 (0.92, 0.95)	1.11 (1.09, 1.13)	< 0.001
NAA/Cr	Anorexic	2.14 (2.12, 2.17)	2.22 (2.19, 2.24)	2.38 (2.35, 2.40)	2.48 (2.47, 2.50)	< 0.001
	Control	2.15 (2.11, 2.19)	2.23 (2.20, 2.26)	2.42 (2.39, 2.46)	2.56 (2.53, 2.59)	< 0.001
MM09/Cr	Anorexic	0.50 (0.49, 0.51)	0.50 (0.49, 0.51)	0.52 (0.51, 0.53)	0.54 (0.54, 0.55)	< 0.001
	Control	0.52 (0.50, 0.53)	0.55 (0.54, 0.56)	0.54 (0.52, 0.55)	0.55 (0.54, 0.56)	< 0.001

Note: Values are estimated marginal mean (95% confidence interval); *p* values result of parametric tests.

Abbreviations: Cho, choline; Cr, creatine; GM, gray matter; ml, myo-inositol; MM09, macromolecules; NAA, N-acetyl aspartate; WM, white matter.

lower than in all other regions except the postcentral region and the precuneus in anorexics with $p < 0.001$, and the frontal, postcentral, and parietal regions in controls with $p < 0.05$. MM09/Cr was also lower in the postcentral region (significantly lower than the precentral and parietal regions in anorexics, and all regions except the cingulate in controls, with $p < 0.05$). In both groups, the highest values of MM09/Cr were observed in the precentral ($p < 0.05$, with no significant difference with the frontal region) and parietal ($p < 0.05$ in anorexics) regions, as well as in the precuneus in controls ($p < 0.05$, except with the parietal and precentral regions).

Relative content in white and gray matter

There were significant differences between the four levels of relative WM and GM content for all metabolites in both the anorexia and control groups ($p < 0.001$) with the exception of ml/Cr in the anorexia group ($p = 0.223$) (Table 3). In both groups, Cho/Cr and NAA/Cr progressively increased as the relative proportion of WM increased ($p < 0.001$). There was a significant difference in MM09/Cr between GM and WM ($p < 0.001$). In the control group, the ml/Cr ratio was also significantly

higher in the WM content than both in the GM ($p < 0.001$) and WM/GM ($p = 0.007$) contents.

Comparisons between the anorexia and control groups

The ml/Cr ratio was significantly lower in the anorexia group compared to the control group, including all brain regions and relative contents in white and gray matter ($p < 0.001$). A region by region analysis showed significantly lower values of ml/Cr in anorexics in the precentral ($p = 0.006$), postcentral ($p < 0.001$), and precuneus ($p = 0.006$) regions, but not in the frontal ($p = 0.457$), cingulate ($p = 0.495$), or parietal regions ($p = 0.798$) (Figure 4A). There were significantly lower values of the ml/Cr ratio in voxels with GM/WM content (GM/WM) ($p < 0.001$) and WM content (WM) ($p = 0.003$), but no significant differences were seen in the GM content (GM) ($p = 0.985$) or in the WM/GM content (WM/GM) ($p = 0.166$) (Figure 4B).

The Cho/Cr ratio was significantly higher in the anorexia group compared to the control group, including all brain regions and relative contents in white and gray matter ($p < 0.001$). This ratio was significantly higher in the anorexia group in all regions: frontal ($p = 0.009$), cingulate

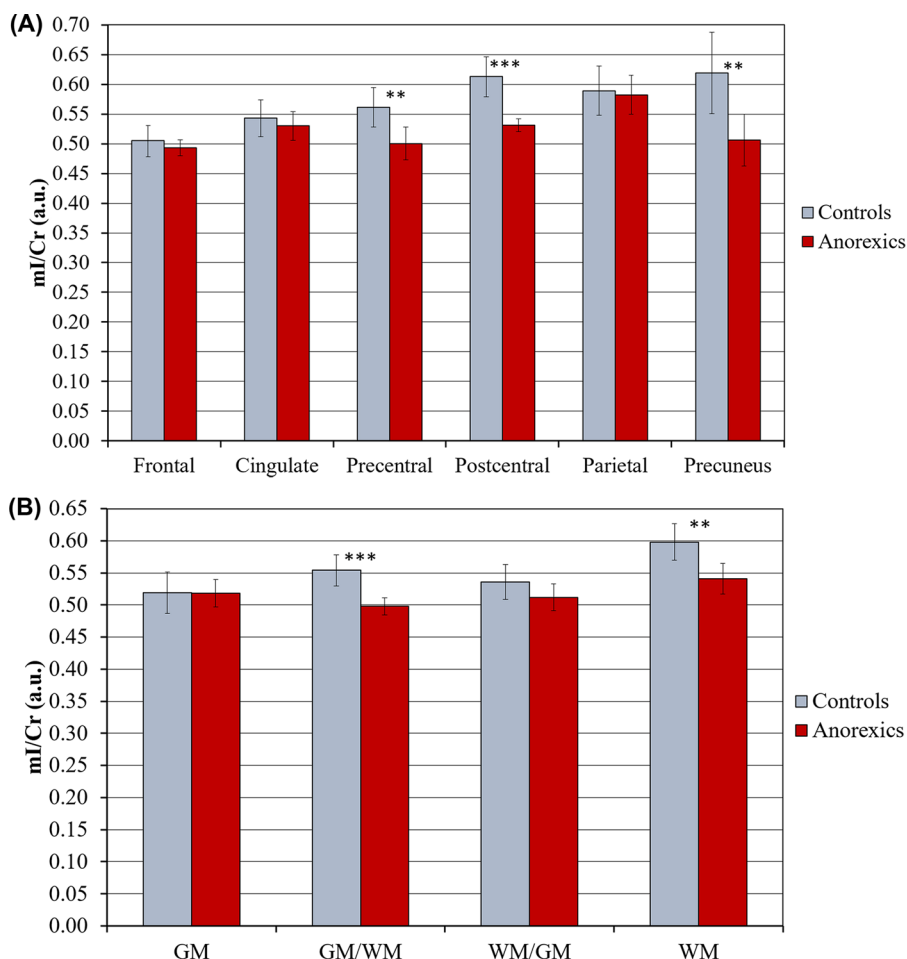


FIGURE 4 Comparisons of estimated marginal means of ml/Cr between anorexics and controls: in the six different brain regions (A) and in the four different relative contents of GM and WM (B) (** $p < 0.01$; *** $p < 0.001$). Abbreviations: GM, gray matter; ml/Cr, myo-inositol/creatine; WM, white matter [Color figure can be viewed at wileyonlinelibrary.com]

($p = 0.001$), precentral ($p = 0.001$), postcentral ($p = 0.001$), and parietal ($p = 0.002$) regions, except the precuneus ($p = 0.944$) (Figure 5A). The Cho/Cr ratio was significantly higher in the anorexia group in the four different relative contents of white and gray matter ($p < 0.001$) (Figure 5B).

The NAA/Cr ratio was significantly lower in the anorexia group compared to controls, including all brain regions and relative contents in white and gray matter ($p < 0.001$). This ratio was significantly lower in anorexics only in the frontal ($p < 0.001$) and precentral ($p < 0.001$) regions, without significant differences in the cingulate ($p = 0.336$), postcentral ($p = 0.200$), parietal ($p = 0.487$), or precuneus ($p = 0.122$) regions (Figure 6A). Anorexics had significantly lower NAA/Cr in voxels containing more than 50% white matter: WM/GM content ($p = 0.001$) and WM content ($p < 0.001$), with no significant differences observed in voxels with a greater proportion of gray matter: GM content ($p = 0.676$) and GM/WM content ($p = 0.376$) (Figure 6B).

The MM09/Cr ratio decreased significantly in the anorexia group, including all brain regions and relative contents in white and gray matter ($p < 0.001$). This was seen in four regions: frontal ($p = 0.003$), cingu-

late ($p < 0.001$), precentral ($p = 0.004$), and precuneus ($p = 0.007$). The MM09/Cr ratio did not show significant differences between anorexics and controls in the parietal ($p = 0.714$) and postcentral ($p = 0.899$) regions (Figure 7A). This difference was more pronounced in the cingulate and precuneus. Anorexics had a significantly lower MM09/Cr ratio in the four relative contents of white and gray matter: GM content ($p = 0.012$), GM/WM content ($p < 0.001$), WM/GM content ($p = 0.018$), and WM content ($p = 0.002$) (Figure 7B).

Correlation between metabolite ratios, BMI, and duration of anorexia

The correlation coefficients between metabolite ratios, BMI, and duration of anorexia, including all brain regions and relative contents in WM/GM, were low with no significant values. However, significant correlations were found between BMI and MM09/Cr in the cingulate ($r = 0.338$, $p = 0.033$), duration of anorexia and MM09/Cr in GM content ($r = -0.428$, $p = 0.033$), and between disease duration and NAA/Cr in the parietal region ($r = -0.542$, $p = 0.005$).

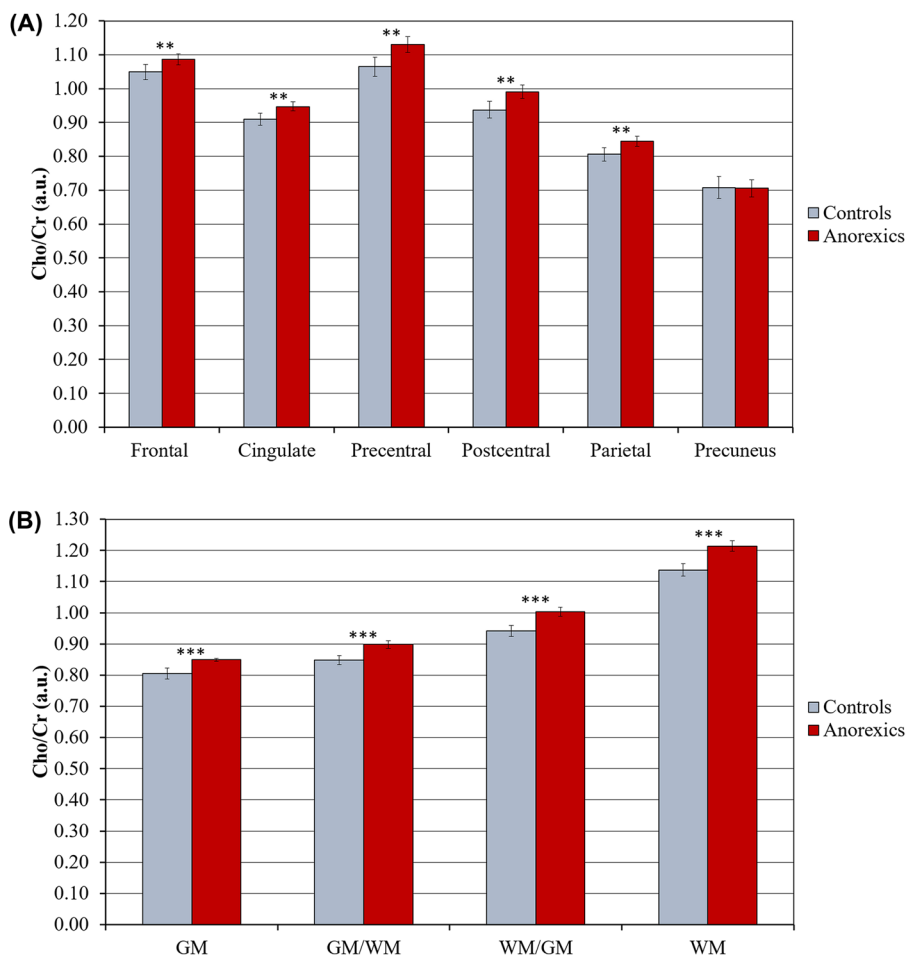


FIGURE 5 Comparisons of estimated marginal means of Cho/Cr between anorexics and controls: in the six different brain regions (A) and in the four different relative contents of GM and WM (B) (** $p < 0.01$; *** $p < 0.001$). Abbreviations: Cho/Cr, choline/creatine; GM, gray matter; WM, white matter [Color figure can be viewed at wileyonlinelibrary.com]

DISCUSSION

Our study has shown that metabolites are distributed differently throughout the brain and has uncovered important differences in the concentrations of these metabolites between anorexic patients and controls. This confirms that anorexia nervosa affects different brain regions differently and highlights the importance of using MRSI to identify these regional variations.

We found a higher Cho/Cr ratio in all brain regions of anorexics, except the precuneus, affecting both white and gray matter, which is in agreement with previous studies.^{11–14} This possibly reflects increased cell turnover, and catabolism of lipid membranes with release of fatty acids from phospholipids. In reality, the peak of choline mainly represents glycerophosphocholine.¹⁴ However, the cause is probably more complex, possibly with a component of increased membrane fluidity due to a hypocaloric standard diet or a hypocaloric choline-reduced diet, as shown by Woeckel.¹⁵

We found a significantly lower NAA/Cr ratio in the WM of the frontal and precentral regions, similarly to the studies by Castro-Fornieles et al. in frontal GM,¹⁶ and Schlemmer et al. in the parieto-

occipital WM,¹¹ but contrary to other studies.^{13,17,18} NAA is considered a marker of neuronal density and functioning, and several studies have shown a decrease in the volume of white and gray matter in anorexia, at least partly reversible after weight recovery.^{19,20} However, this decrease in volume does not seem to be due to neuronal loss but partly to trophic changes, such as smaller neurons, short dendrites, and fewer synapses.²¹ Kazlouski et al. found significantly reduced fractional anisotropy in the bilateral fimbria-fornix, fronto-occipital fasciculus, as well as the WM of the posterior cingulate in anorexia nervosa, thought not to be due to WM volume loss.²² Finally, it has been shown that NAA synthesis lowers when oxygen consumption and ATP production decrease. This means that reduced NAA could primarily reflect impaired mitochondrial energy production rather than neuronal cell loss.²³ Moreover, NAA is transported from neurons to the cytoplasm of oligodendrocytes, where aspartoacylase cleaves the acetate moiety for use in fatty acid and steroid synthesis.²⁴ The fatty acids and steroids produced are then used as building blocks for myelin lipid synthesis. This points to a possible causal link between the decrease of NAA in the brain of anorexics and the reduction of myelin lipids.

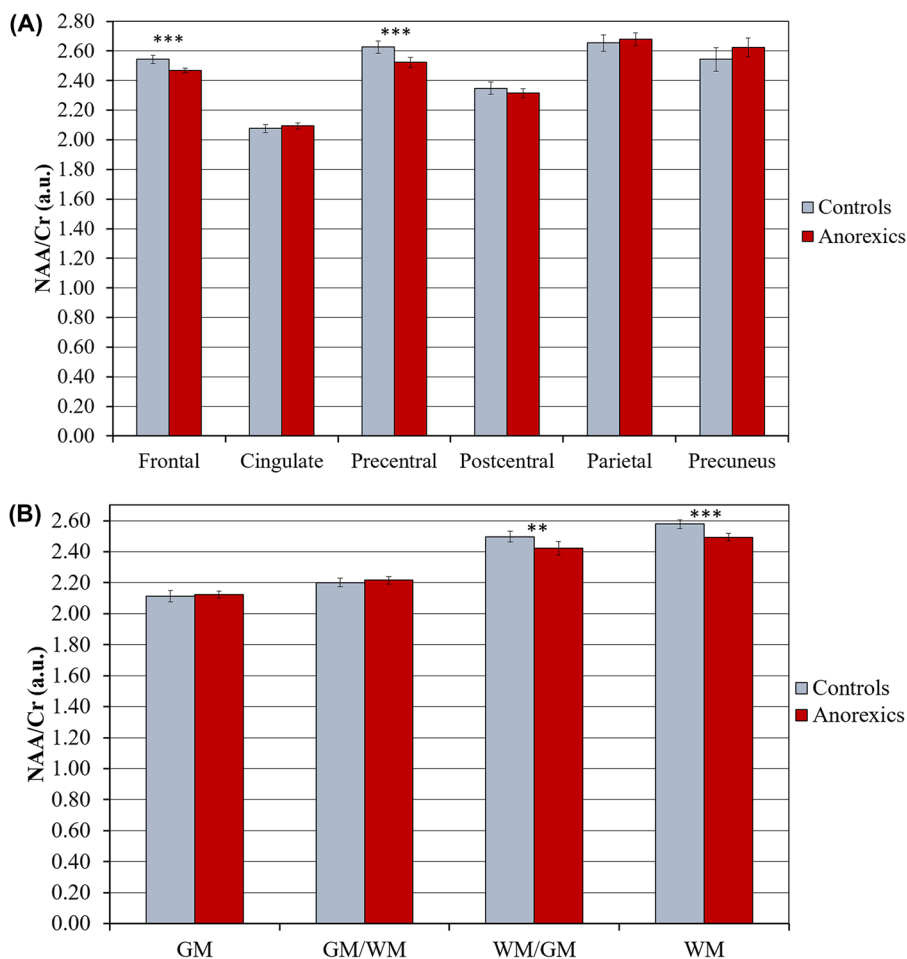


FIGURE 6 Comparisons of estimated marginal means of NAA/Cr between anorexics and controls: in the six different brain regions (A) and in the four different relative contents of GM and WM (B) (** $p < 0.01$; *** $p < 0.001$). Abbreviations: GM, gray matter; NAA/Cr, N-acetyl-aspartate/creatine; WM, white matter [Color figure can be viewed at wileyonlinelibrary.com]

Myo-inositol is considered a glial marker, since it is primarily located in astrocytes and microglial cells,²⁵ but it has also been detected in neuronal cells.²⁶ Myo-inositol intervenes in osmotic regulation phenomena, it is required for the synthesis of cell membrane phospholipids, and it acts as a precursor in the phosphatidylinositol second messenger system. We observed a decrease of the ml/Cr ratio in anorexics, similarly to other studies in frontal WM,¹⁷ and GM,^{16,27} with the most striking difference in our study concerning the precuneus. A decrease in ml has been shown in hyponatraemic states,^{28,29} which can be the case in the context of anorexia nervosa due to diuretics or laxative abuse, potomania, or inappropriate secretion of antidiuretic hormone.^{30,31} However, results concerning changes in the ml/Cr ratio lacked consistency. The biggest differences were seen in the GM/WM and WM contents but the difference collapsed in GM and WM/GM. It is a fact that the ml/Cr ratio showed the greatest variability in standard deviations which may have affected the statistical power of the tests. In view of the neurometabolic role of ml, our hypotheses to explain variations in this metabolite were changes according to the level of hydration, and also according to behavioral aspects, such as possible sleep disorders or mood disorders in both anorexics and controls.^{32–37} The

decrease in myo-inositol in anorexia nervosa seems to be due to a complex mechanism associating osmotic disorders, such as hyponatremia, an imbalance in the second messenger signaling system and partly to trophic changes, such as smaller dendrites and fewer synapses.²¹

Interpretation of macromolecule variations is more difficult. According to the study by Mader concerning multiple sclerosis, the spectroscopic peaks of “lipids at 0.9” (and 1.3) ppm might have been due to proteins or polypeptides containing the amino-acids alanine, threonine, valine, leucine, and isoleucine, which account for approximately 40% of the amino-acids of the myelin proteolipid protein and for approximately 20% of myelin basic proteins.³⁸ Additionally, the increased macromolecular resonances at 0.9 ppm may be interpreted as biochemical markers of myelin fragments. Anorexics had lower concentrations of MM09/Cr in most brain regions (with no significant difference in the postcentral and parietal regions), affecting both WM and GM. This pattern was also found by Grzelak et al. in parietal GM and WM and by Roser et al. in frontal WM and occipital GM.^{17,39} Moreover, a significant positive correlation was found between MM09/Cr in the cingulate and BMI, and a significant negative correlation was found between MM09/Cr in GM and the duration of anorexia.

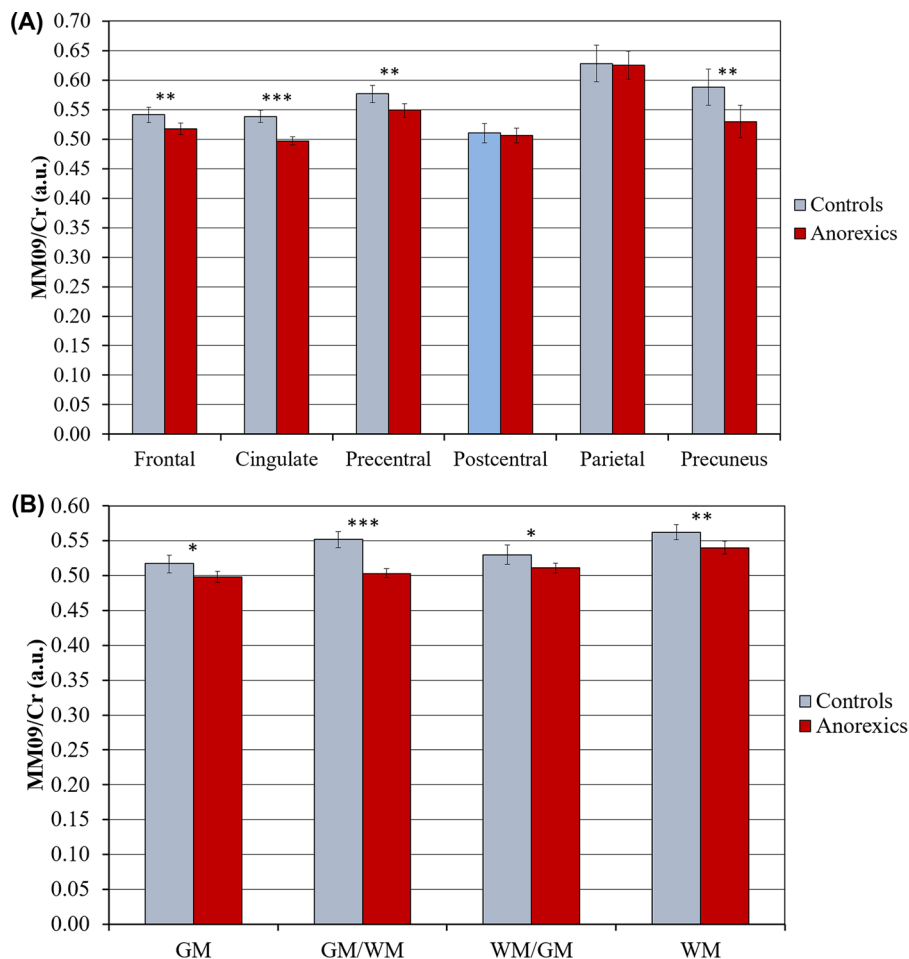


FIGURE 7 Comparisons of estimated marginal means of MM09/Cr between anorexics and controls in the six different brain regions (A) and in the four different relative contents of GM and WM (B) (* $p < 0.05$; ** $p < 0.01$; *** $p < 0.001$). Abbreviations: GM, gray matter; MM09/Cr, macromolecules/creatine; WM, white matter [Color figure can be viewed at wileyonlinelibrary.com]

The contribution of proteins to basal energy expenditure is increased in anorexia nervosa in order to maintain a normal level of glucose oxidation.⁴⁰ Our results suggest that this was particularly pronounced in the cingulate gyrus and precuneus, which sheds some light on the pathophysiology of anorexia nervosa by identifying changes in the cingulate cortex which is known to be dysfunctional in eating disorders.

The slightly more marked variations in the MM09/Cr ratio in the cingulate gyrus and the precuneus, as well as the variations in the mI/Cr ratio in the precuneus, were particularly interesting. In anorexia nervosa, the cingulate was shown to be hypoperfused.⁴¹ Furthermore, it has been shown that in healthy volunteers, the simple act of thinking about one's own physical features activates the anterior cingulate cortex.⁴² In addition to the perception of body image, the anterior cingulate cortex is involved in processing the hedonic properties of food intake.^{43,44} In a study by Gaudio et al. about distortion of body image, which is a key symptom of anorexia nervosa, a multidimensional model is assumed. This allows the perceptual, affective, and cognitive components of body distortion images to be distinguished. It also demonstrated the role of the precuneus in the perceptual component, a structure that is mainly involved when the tasks were based on

visualization of the body, self, and other images.⁴⁵⁻⁴⁷ Another interesting study is that of Mohr et al., in which estimation of body size was achieved using a specific task: subjects had to choose the image, from the thinnest to the largest, which most closely resembled their own body image.⁴⁸ The study found an absence of modulation of precuneus activity when estimating body size in anorexic patients compared to controls, leading to an overestimation of one's own weight/height. Stronger synchronous activity between the dorsal anterior cingulate and the precuneus was shown in anorexia nervosa and bulimia nervosa.⁶ The dorsal anterior cingulate-precuneus resting-state synchrony was presumed to be associated with the disorder-specific rumination on eating, weight, and body shape in patients with eating disorders. Monzon et al. also described changes in a range of WM structures of the limbic system in anorexics, mainly the fornix and cingulate as well as the fronto-occipital fiber tracts, which are regions known to be associated with anxiety, body image, and cognitive function.⁷ Finally, some morphometric studies have shown specific decreases in GM of the precuneus and lower parietal lobe in patients suffering from anorexia nervosa compared to control subjects.^{5,49-51} In addition, Mühlau et al. have shown a correlation between cortical atrophy of the cingulate

gyrus and low BMI.⁵² In our study, a significant positive correlation was observed between the MM09/Cr ratio in the cingulate gyrus and BMI, and a significant negative correlation was found between the MM09/Cr ratio in GM and the duration of anorexia. These metabolic variations in the cingulate gyrus and the precuneus in anorexic patients compared to other regions point to the fact that injury to these structures probably plays an important role in anorexia nervosa, even though a possible effect of causality cannot be clearly identified.

It is unclear what role these changes play in the pathological psychic mechanisms of anorexia nervosa, especially with the pronounced involvement of the cingulate on the metabolism of lipids, which might be associated with body image and disorder-specific rumination on eating. It is also unclear to what extent these metabolic changes are reversible after weight gain. In a positive note, Möckel et al. showed metabolic changes in the brain of patients with anorexia nervosa in ¹H-MR spectroscopy, which were reversible under successful therapy.¹² It is uncertain what impact these data will have on the therapeutic management of anorexia nervosa, but a suggestion by Woeckel et al. is that choline-enriched nutrition after starvation improves the stabilization of cerebral membranes and the metabolic situation in anorexia nervosa.¹⁵

It is, therefore, open to debate to what extent variations in creatine may have influenced variations in the different ratios of metabolites. It should be noted first that several studies have shown higher creatine values in GM in healthy subjects.^{53–56} Concerning patients suffering from anorexia nervosa, Blasel et al. observed a significant increase in creatine in GM compared to healthy subjects, without significant changes in WM.¹⁴ In our study, the increase in the Cho/Cr ratio was observed in WM and GM, which was, nevertheless, slightly greater in WM than GM, perhaps due to a selective increase in creatine in GM, as Blasel et al. suggest. Likewise, our study showed an increase in NAA/Cr, which was not significant in GM, possibly due to increased creatine in GM in the anorexia group. Finally, the exact role of creatine in the reduction of the MM09/Cr ratio, in particular in GM, could be considered.¹⁴ Different hypotheses on the variations of creatine in pathological situations have been formulated; one of these being that creatine increases energy bioavailability, promotes neuronal survival, and reduces oxidative stress and proapoptotic and pronecrotic processes.

One limitation of our study relates to the fact that our segmentation of WM and GM was performed manually based on visual inspection of the images, in the three planes of space, by a board-certificated neuroradiologist. There are several automatic segmentation software packages that are freely available and that are widely validated for this purpose⁵⁷ and we acknowledge that using one of these could have potentially provided more precise tissue classification.

Finally, a spectra analysis, using more accurate processing software packages, such as LCmodel, could have increased the precision of the findings and enhanced the scope of the study by allowing the inclusion of other metabolites, such as glutamine/glutamate and lactate.

These limitations should be addressed in the future in order to allow validation of the anorexia-related brain metabolic changes uncovered in our study, as well as to deepen our understanding of the pathophysiology of this condition.

In conclusion, we found that metabolites are distributed differently throughout the brain and that the concentrations of those metabolites showed significant differences between anorexic patients and controls. The cingulate and precuneus seemed to be particularly involved, the former being known to be dysfunctional in eating disorders. Finally, it could be interesting in the future to study these metabolites in recovered anorexics.

ACKNOWLEDGMENTS AND DISCLOSURE

Open Access Funding provided by Universite de Geneve.

ORCID

Alice Regnaud  <https://orcid.org/0000-0001-6323-9340>

José Boto  <https://orcid.org/0000-0003-1448-861X>

Antoine Klauer  <https://orcid.org/0000-0003-3019-9914>

Karl-Olof Lövblad  <https://orcid.org/0000-0003-2768-9779>

Maria Isabel Vargas  <https://orcid.org/0000-0002-6571-5336>

François Lazeyras  <https://orcid.org/0000-0002-9364-0634>

REFERENCES

1. Stice E, Bohon C. Eating disorders. In *Child and Adolescent Psychopathology*. 2nd ed. T Beauchaine, S Linshaw, editors, 719. New York: Wiley; 2012.
2. CG, Cooper Z. Eating disorders, DSM-5 and clinical reality. *Br J Psychiatry* 2011;198:8.
3. Katzman DK, Lambe EK, Mikulis DJ, Ridgley JN, Goldbloom DS, Zipursky RB. Cerebral gray matter and white matter volume deficits in adolescent girls with anorexia nervosa. *J Pediatr* 1996;129:794-803.
4. Lambe EK. Cerebral gray matter volume deficits after weight recovery from anorexia nervosa. *Arch Gen Psychiatry* 1997;54:537-42.
5. Gaudio S, Nocchi F, Franchin T, Genovese E, Cannatà V, Longo D, et al. Gray matter decrease distribution in the early stages of anorexia nervosa restrictive type in adolescents. *Psychiatry Res* 2011;191:24-30.
6. Lee S, Ran Kim K, Ku J, Lee J-H, Namkoong K, Jung Y-C. Resting-state synchrony between anterior cingulate cortex and precuneus relates to body shape concern in anorexia nervosa and bulimia nervosa. *Psychiatry Res* 2014;221:43-8.
7. Monzon BM, Hay P, Foroughi N, Touyz S. White matter alterations in anorexia nervosa: a systematic review of diffusion tensor imaging studies. *World J Psychiatry* 2016;6:177-86.
8. Scheenen TWJ, Klomp DWJ, Wijnen JP, Heerschap A. Short echo time 1H-MRSI of the human brain at 3T with minimal chemical shift displacement errors using adiabatic refocusing pulses. *Magn Reson Med* 2008;59:1-6.
9. Stovell MG, Yan J-L, Sleigh A, Mada MO, Carpenter TA, Hutchinson PJA, et al. Assessing metabolism and injury in acute human traumatic brain injury with magnetic resonance spectroscopy: current and future applications. *Front Neurol* 2017;8:426.
10. Peeters TH, van Uden MJ, Rijpmma A, Scheenen TWJ, Heerschap A. 3D ³¹P MR spectroscopic imaging of the human brain at 3 T with a 31 P receive array: an assessment of ¹H decoupling, T₁ relaxation times, ¹H-³¹P nuclear Overhauser effects and NAD. *NMR Biomed* 2019;34:e4169.



11. Schlemmer H-P, Möckel R, Marcus A, Hentschel F Göpel C, Becker G, et al. Proton magnetic resonance spectroscopy in acute, juvenile anorexia nervosa. *Psychiatry Res* 1998;82:171-9.
12. Möckel R, Schlemmer H-P, Gückel F, Göpel C, Becker G, Köpke J, et al. 1H-MR spectroscopy in anorexia nervosa. Reversible cerebral metabolic changes. *RoFo* 1999;170:371-7.
13. Hentschel F, Möckel R, Schlemmer H, Markus A, Göpel C, Gückel F, et al. 1H-MR-spectroscopy in anorexia nervosa; characteristic differences between patients and normal controls. *RoFo* 1999;170:284-9.
14. Blasel S, Pilatus U, Magerkurth J, Von Stauffenberg M, Vronski D, Mueller M, et al. Metabolic gray matter changes of adolescents with anorexia nervosa in combined MR proton and phosphorus spectroscopy. *Neuroradiology* 2012;54:753-64.
15. Woeckel L, Bertsch T, Koch S, Achtnichts L, Holtmann M, Gretz N, et al. The importance of choline and different serum parameters for the course of the anorexia nervosa. *Fortschr Neurol Psychiatr* 2007;75:402-12.
16. Castro-Fornieles J, Bargalló N, Lázaro L, Andrés S, Falcon C, Plana MT, et al. Adolescent anorexia nervosa: cross-sectional and follow-up frontal gray matter disturbances detected with proton magnetic resonance spectroscopy. *J Psychiatr Res* 2007;41:952-8.
17. Roser W, Bubl R, Buergerin D, Seelig J, Radue EW, Rost B. Metabolic changes in the brain of patients with anorexia and bulimia nervosa as detected by proton magnetic resonance spectroscopy. *Int J Eat Disord* 1999;26:119-36.
18. Joos AAB, Perlov E, Büchert M, Hartmann A, Saum B, Glauche V, et al. Magnetic resonance spectroscopy of the anterior cingulate cortex in eating disorders. *Psychiatry Res* 2011;191:196-200.
19. Boto J, Gkinis G, Roche A, Kober T, Maréchal B, Ortiz N, et al. Evaluating anorexia-related brain atrophy using MP2RAGE-based morphometry. *Eur Radiol* 2017;27:5064-72.
20. Seitz J, Herpertz-Dahlmann B, Konrad K. Brain morphological changes in adolescent and adult patients with anorexia nervosa. *J Neural Transm* 2016;123:949-59.
21. Neumärker K-J, Dudeck U, Meyer U, Neumärker U, Schulz E, Schönheit B. Anorexia nervosa and sudden death in childhood: clinical data and results obtained from quantitative neurohistological investigations of cortical neurons. *Eur Arch Psychiatry Clin Neurosci* 1997;247:16-22.
22. Kazlouski D, Rollin MDH, Tregellas J, Shott ME, Jappe LM, Hagman JO, et al. Altered fimbria-fornix white matter integrity in anorexia nervosa predicts harm avoidance. *Psychiatry Res* 2011;192:109-16.
23. Bates TE, Strangward M, Keelan J, Davey GP, Munro PMG, Clark JB. Inhibition of N-acetylaspartate production: implications for 1H MRS studies in vivo. *Neuroreport* 1996;7:1397-400.
24. Moffett J, Ross B, Arun P, Madhavarao C, Namboodiri A. N-Acetylaspartate in the CNS: from neurodiagnostics to neurobiology. *Prog Neurobiol* 2007;81:89-131.
25. Brand A, Richter-Landsberg C, Leibfritz D. Multinuclear NMR studies on the energy metabolism of glial and neuronal cells. *Dev Neurosci* 1993;15:289-98.
26. Novak JE, Turner RS, Agranoff BW, Fisher SK. Differentiated human NT2-N neurons possess a high intracellular content of myo-inositol. *J Neurochem* 1999;72:1431-40.
27. Ohrmann P, Kersting A, Suslow T, Lalee-Mentzel J, Dinges U-S, Fiebich M, et al. Proton magnetic resonance spectroscopy in anorexia nervosa: correlations with cognition. *Neuroreport* 2004;15:549-53.
28. Verbalis JG, Gullans SR. Hyponatremia causes large sustained reductions in brain content of multiple organic osmolytes in rats. *Brain Res* 1991;567:274-82.
29. Videen JS, Michaelis T, Pinto P, Ross BD. Human cerebral osmolytes during chronic hyponatremia. A proton magnetic resonance spectroscopy study. *J Clin Invest* 1995;95:788-93.
30. Bahia A, Chu ES, Mehler PS. Polydipsia and hyponatremia in a woman with anorexia nervosa. *Int J Eat Disord* 2011;44:186-8.
31. Challier P, Cabrol S. Severe hyponatremia associated with anorexia nervosa: role of inappropriate antidiuretic hormone secretion? *Arch Pediatr* 1995;2:977-9.
32. Biller A, Reuter M, Patenaude B, Homola GA, Breuer F, Bendszus M, et al. Responses of the human brain to mild dehydration and rehydration explored in vivo by 1H-MR imaging and spectroscopy. *AJNR Am J Neuroradiol* 2015;36:2277-84.
33. Urrila AS, Hakkarainen A, Castaneda A, Paunio T, Marttunen M, Lundbom N. Frontal cortex myo-inositol is associated with sleep and depression in adolescents: a proton magnetic resonance spectroscopy study. *Neuropsychobiology* 2017;75:21-31.
34. Cross NE, Lagopoulos J, Duffy SL, Cockayne NL, Hickie IB, Lewis SJG, et al. Sleep quality in healthy older people: relationship with ¹H magnetic resonance spectroscopy markers of glial and neuronal integrity. *Behav Neurosci* 2013;127:803-10.
35. Sarchielli P, Presciutti O, Alberti A, Tarducci R, Gobbi G, Galletti F, et al. A 1H magnetic resonance spectroscopy study in patients with obstructive sleep apnea. *Eur J Neurol* 2008;15:1058-64.
36. Gruber S, Frey R, Mlynárik V, Stadlbauer A, Heiden A, Kasper S, et al. Quantification of metabolic differences in the frontal brain of depressive patients and controls obtained by 1H-MRS at 3 Tesla. *Invest Radiol* 2003;38:403-8.
37. Ortiz AE, Ortiz AG, Falcon C, Morer A, Plana MT, Bargalló N, et al. 1H-MRS of the anterior cingulate cortex in childhood and adolescent obsessive-compulsive disorder: a case-control study. *Eur Neuropsychopharmacol* 2015;25:60-8.
38. Mader I. Proton MR spectroscopy with metabolite-nulling reveals elevated macromolecules in acute multiple sclerosis. *Brain* 2001;124:953-61.
39. Grzelak P, Gajewicz W, Wyszogrodzka-Kucharska A, Rotkiewicz A, Stefańczyk L, Góraj B, et al. Brain metabolism alterations in patients with anorexia nervosa observed in 1H-MRS. *Psychiatr Pol* 2005;39:761-71.
40. Franssila-Kallunki A, Rissanen A, Ekstrand A, Eriksson J, Saloranta C, Widén E, et al. Fuel metabolism in anorexia nervosa and simple obesity. *Metabolism* 1991;40:689-94.
41. Takano A, Shiga T, Kitagawa N, Koyama T, Katoh C, Tsukamoto E, et al. Abnormal neuronal network in anorexia nervosa studied with I-123-IMP SPECT. *Psychiatry Res* 2001;107:45-50.
42. Kjaer TW, Nowak M, Lou HC. Reflective self-awareness and conscious states: PET evidence for a common midline parietofrontal core. *Neuroimage* 2002;17:1080-6.
43. De Araujo IET, Kringelbach ML, Rolls ET, Mcglone F. Human cortical responses to water in the mouth, and the effects of thirst. *J Neurophysiol* 2003;90:1865-76.
44. De Araujo IE. Representation in the human brain of food texture and oral fat. *J Neurosci* 2004;24:3086-93.
45. Gaudio S, Quattrocchi CC. Neural basis of a multidimensional model of body image distortion in anorexia nervosa. *Neurosci Biobehav Rev* 2012;36:1839-47.
46. Hodzic A, Muckli L, Singer W, Stirn A. Cortical responses to self and others. *Hum Brain Mapp* 2009;30:951-62.
47. Hodzic A, Kaas A, Muckli L, Stirn A, Singer W. Distinct cortical networks for the detection and identification of human body. *Neuroimage* 2009;45:1264-71.
48. Mohr HM, Zimmermann J, Röder C, Lenz C, Overbeck G, Grabhorn R. Separating two components of body image in anorexia nervosa using fMRI. *Psychol Med* 2010;40:1519-29.
49. Castro-Fornieles J, Bargalló N, Lázaro L, Andrés S, Falcon C, Plana MT, et al. A cross-sectional and follow-up voxel-based morphometric MRI study in adolescent anorexia nervosa. *J Psychiatr Res* 2009;43:331-40.
50. Joos A, Klöppel S, Hartmann A, Glauche V, Tüscher O, Perlov E, et al. Voxel-based morphometry in eating disorders: correlation of



- psychopathology with grey matter volume. *Psychiatry Res* 2010;182:146-51.
51. Joos A, Hartmann A, Glauche V, Perlov E, Unterbrink T, Saum B, et al. Grey matter deficit in long-term recovered anorexia nervosa patients. *Eur Eat Disord Rev* 2011;19:59-63.
 52. Mühlau M, Gaser C, Ilg R, Conrad B, Leibl C, Cebulla MH, et al. Gray matter decrease of the anterior cingulate cortex in anorexia nervosa. *Am J Psychiatry* 2007;164:1850-7.
 53. Schuff N, Ezekiel F, Gamst AC, Amend DL, Capizzano AA, Maudsley AA, et al. Region and tissue differences of metabolites in normally aged brain using multislice 1H magnetic resonance spectroscopic imaging. *Magn Reson Med* 2001;45:899-907.
 54. Hetherington HP, Pan JW, Mason GF, Adams D, Vaughn MJ, Twieg DB, et al. Quantitative 1H spectroscopic imaging of human brain at 4.1 T using image segmentation. *Magn Reson Med* 1996;36:21-9.
 55. Lundbom N, Barnett A, Bonavita S, Patronas N, Rajapakse J, Tedeschi G, et al. MR image segmentation and tissue metabolite contrast in 1H spectroscopic imaging of normal and aging brain. *Magn Reson Med* 1999;41:841-5.
 56. Pfefferbaum A, Adalsteinsson E, Spielman D, Sullivan EV, Lim KO. In vivo spectroscopic quantification of the N-acetyl moiety, creatine, and choline from large volumes of brain gray and white matter: effects of normal aging. *Magn Reson Med* 1999;41:276-84.
 57. Ashburner J, Friston KJ. Unified segmentation. *Neuroimage* 2005; 26:839-51.

How to cite this article: Regnaud Alice, Boto José, Antoine Klauser, Lövblad Karl-Olof, Vargas Marialsabel, Lazeyras François. Metabolic changes in the cingulate gyrus, precuneus, and white matter in anorexia nervosa using multivoxel MR spectroscopy. *J Neuroimaging*. 2021;31:1099–1110.
<https://doi.org/10.1111/jon.12922>