

CASE REPORT

Rehabilitation after severe maxillectomy using a magnetic obturator (a case report)

Mahnaz Arshad^{1,2}  | Gholamreza Shirani^{1,3} | Xaniar Mahmoudi⁴

¹Dental Research Center, Dentistry Research Institute, Tehran University of Medical Sciences, Tehran, Iran

²Department of Prosthodontics, School of Dentistry, International Campus, Tehran University of Medical Sciences, Tehran, Iran

³Department of Oral and Maxillofacial Surgery, School of Dentistry, Tehran University of Medical Sciences, Tehran, Iran

⁴School of Dentistry, International Campus, Tehran University of Medical Sciences, Tehran, Iran

Correspondence

Xaniar Mahmoudi, School of Dentistry, International Campus, Tehran University of Medical Sciences, Tehran, Iran.
Email: Xaniarmahmoudi@yahoo.com

Key Clinical Message

This report presents oral rehabilitation of a maxillectomy patient after cancer surgery by fabricating a prosthesis comprising of a denture and a custom-made magnetic retainer. Herein, we present a case of hemimaxillectomy due to squamous cell carcinoma, which was efficiently rehabilitated with implants. Patient's condition and his profile acceptably improved following rehabilitation.

KEYWORDS

clinical report, dental implants, hemimaxillectomy, maxillofacial prosthesis

1 | INTRODUCTION

A patient with a deep maxillary defect and ill-fitted framework and obturator was referred to the Department of Prosthodontics, Tehran University of Medical Sciences. The patient had misaligned dental implants in the left side of his maxilla. Clinical and radiographic examinations revealed that the implants had good stability and the bone volume was sufficient. After routine impression and final cast making, the record base and wax rims were fabricated. Then, the vertical dimension was recorded. After tooth selection, mounting, and set-up try-in, the patient had a satisfactory lip support and smile line. The abutments were selected and the framework was designed and tried in. Use of magnets was a good option to retain the prosthesis; thus, a closed-field magnet was embedded in the obturator and abutments.

Maxillary defects can be the result of congenital malformations, developmental defects, or acquired conditions such as defects caused by cancer surgery. Surgical resection is the

most commonly used approach for patients with malignant tumors in the maxilla. Maxillary tumors often require partial maxillectomy to prevent them from recurring.¹ Following surgery, most patients have problems in chewing, swallowing, and speech articulation and suffer from respiratory tract infections or upper airway inflammation due to the created connection between the nasal cavity, oral cavity, and the maxillary sinus.^{1,2} Anxiety and decreased self-confidence are more common in patients with maxillofacial deficiencies compared to patients with other disabilities.³

Both prosthetic and surgical rehabilitation can be proposed as a solution to improve the function and esthetics in maxillectomy patients.⁴ Depending on the extent and morphology of the defect, there are various therapeutic approaches for rehabilitation of maxillectomy defects including microvascular reconstruction for large defects and use of maxillary obturator for smaller defects.⁵ For successful prosthetic rehabilitation, the obturator must have adequate support, stability, and retention. Lack of any of

these parameters can lead to treatment failure and patient dissatisfaction.⁶

Radiotherapy is often prescribed for cancer patients, which has complications and side effects such as decreased saliva, taste acuity, xerostomia, poor tolerance of prosthetic restoration, compromised bone remodeling, and muscle trismus.⁷

The fabrication of a maxillary obturator for edentulous patients can be challenging for all clinicians owing to the lack of retention and support since the available undercuts may not be enough to achieve appropriate retention and support. In such cases, zygomatic implants can provide considerable retention and support for dentition, and reconstruction of maxillary defects.⁸⁻¹⁰ Many patients have expressed their satisfaction with magnetic overdentures.¹¹ Magnets can help improve the retention and stability of implant-supported overdentures.¹² Javid introduced the use of magnetic prosthesis aiming to improve retention in reconstruction of maxillofacial defects.¹³ The connection between the magnets provides adequate retention for the prosthetic components and relieves the skin-supported areas. In routine clinical practice, we can use magnetic abutments in cases with non-angular implants, but the magnetic abutments introduced by the implant systems do not have a wide variation in angles.

This paper reports reconstruction of a very large maxillary defect with multiple surgical scars as the result of hemimaxillectomy due to squamous cell carcinoma (SCC) in a 73-year-old man using a custom-designed magnetic prosthesis.

2 | CASE REPORT

A 73-year-old male patient presented to the Department of Prosthodontics, Tehran University of Medical Sciences complaining of difficult mastication and speech articulation and water flowing into the nose during eating/drinking. The patient had severe hypernasality and reflux during swallowing. He had undergone left maxillectomy from the right maxillary canine to the left maxillary canine (type 3a Santamaria and Cordeiro classification¹⁴) due to SCC 10 years earlier. He had been diagnosed with stage 2, T2, NO, MO SCC and had undergone 31 sessions of radiotherapy (total dose of 4500 cGy, daily fraction of 145 cGy, two fields of radiation sources and the field was laterally and 18 × 9 cm). After completion of radiotherapy, he had received five dental implants in the maxilla (three in the right and two in the left pterygoid process of the maxilla) and three implants in the mandible with an inappropriate prosthesis. His denture was ill-fitted and had inappropriate structure and framework design; the patient was not satisfied with it either (Figures 1 and 2). His complaints included unaesthetic appearance of denture, an incorrect hollow wall, short border at the defect side, incorrect occlusion, cheeping of teeth, insufficient retention, and no superstructure or housing for attachment.

Extra-oral clinical examination revealed that the patient had class III malocclusion, concave profile, overclosure, and loss of lip support. The smile line was asymmetric and canted to the right with a thin vermilion and surgical scar on the

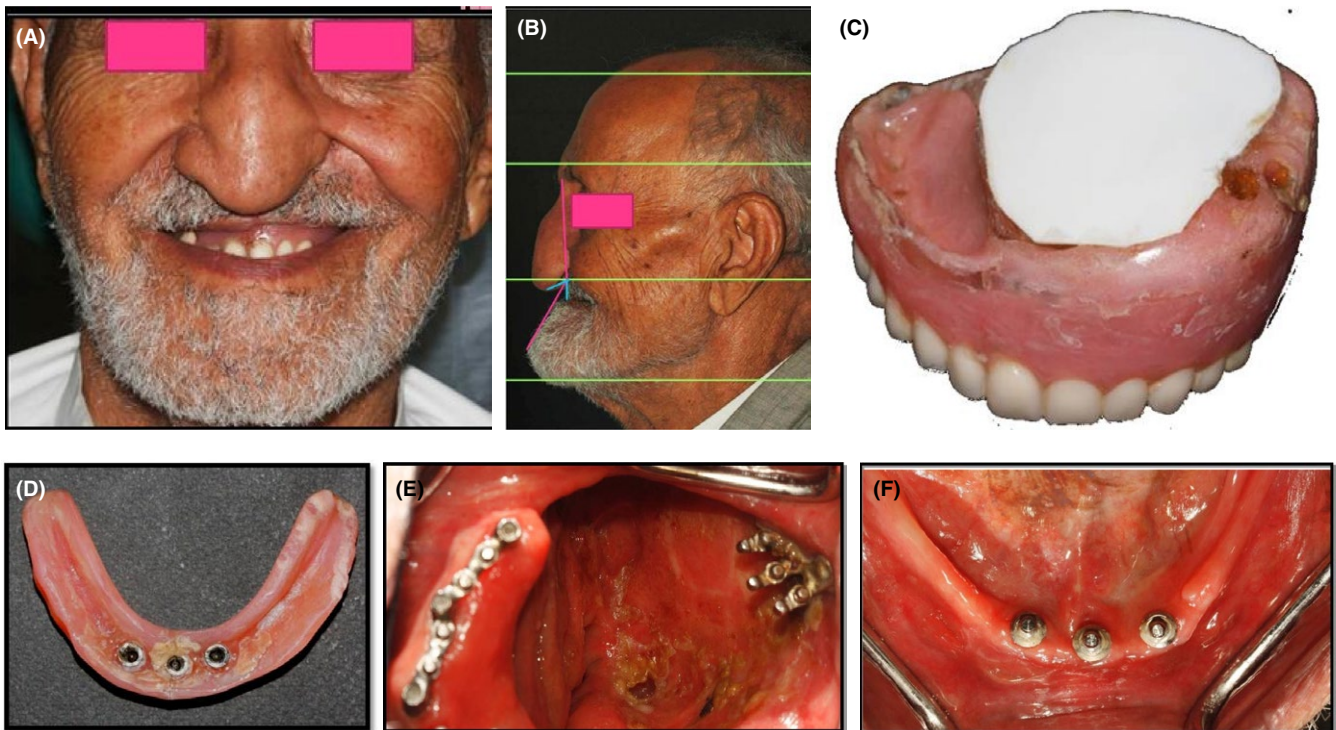


FIGURE 1 A, Profile view. B, Left lateral view. C, Maxillary obturator. D, Mandibular overdenture. E, Maxillary intraoral occlusal view. F, Mandibular intraoral occlusal view

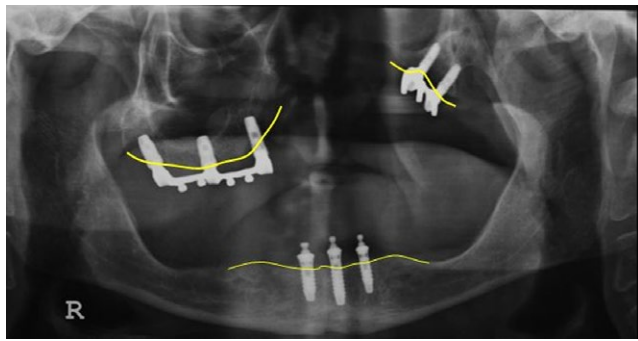


FIGURE 2 Panoramic view

upper lip. Because of his age, several surgeries, radiotherapy, multiple scars, and tissue tension, the patient was not cooperative. Intraoral clinical examination of the maxilla showed a large maxillary defect, multiple surgical scars especially in the left side, edematous oral mucosa and gingiva, xerostomia, malpositioned, and misaligned implants in the left maxilla, bony lateral wall with fibrous mucosa, suprastructure screw loosening, no scar band, no skin graft, multiple traces of bur contact on the framework and ball attachments, and inappropriate framework design. Intraoral clinical examination of the mandible showed inappropriate framework and prosthesis design, ball attachment without splinting of implants and superstructure, screw loosening in ball attachment, poor oral hygiene, and keratinized tissue of alveolar ridge. Cone beam computed tomography evaluation showed that the maxillary left implants inserted in the zygoma and pterygoid bone had good stability and the patient had sufficient bone (Figure 3A); thus, it was decided to preserve the implants, and a prosthetic treatment plan was suggested. The maxillary implants were Dentium (Implantium, Korea, Seoul) and the mandibular implants were Dio (Seoul, Korea). Skin graft was not performed considering the risk of osteoradionecrosis. Salivary glands were damaged due to radiation therapy; thus, the patient had increased saliva viscosity, poor tolerance of prosthesis, taste acuity, and xerostomia. Decreased vertical dimension and mouth opening limitation due to muscle trismus were also present. The main problem in management of this patient was very short and deep implants in the left maxilla, which had a 90° angle relative to the occlusal plane (Figure 3B,C). The ISQ value determination showed that the ISQ was 5-70.

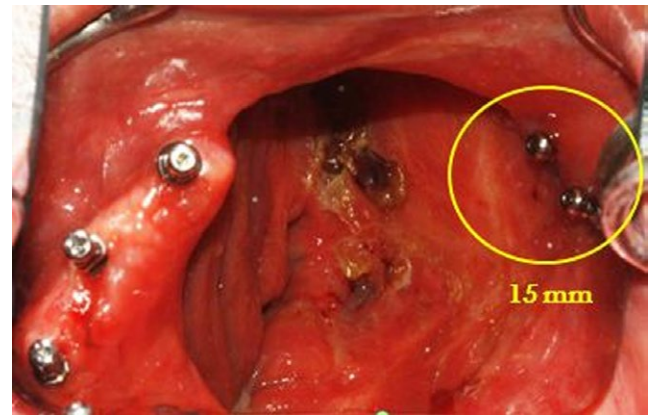


FIGURE 4 Showing depth of implants in maxillary left with impression coping

Based on all the above, it was decided to replace the patient's denture, and the treatment plan included an implant-supported obturator for the maxilla and an implant-supported overdenture for the mandible. A maxillary tray was formed using tray compound (Kerr, Orange, CA, USA). First, an impression was made from the left maxilla with impression copings (Because of deep implants) as healing abutments using addition silicon impression material (Panasil, Eschenburg, Germany) and the closed tray technique (Figure 4). The diagnostic cast was poured with dental stone (Gyproc, Prevest Denpro, Jammu, India), and a custom tray was fabricated by acrylic resin (Yates Motloid, Chicago, IL, USA) (Figure 5). Green stick compound (Tracing Stick, Kemdent, UK) was used for border molding, and final impression was made by polyvinyl siloxane (Oranwash L, Zetaplus, Zhermack, Italy) with open tray impression and splinting technique (Figure 6A). Final cast was poured with type 3 dental stone (Kerr). The mandibular impression was made using zinc oxide eugenol (Kerr) for the posterior mandible and addition silicone (Panasil) for the anterior mandible (Figure 6B). Screw type record base and wax rim were fabricated, vertical dimension was assessed and recording and mounting in semi-adjustable articulator (Dentatus, Spanga, Sweden) were done (Figure 7). Acrylic denture teeth were arranged (semi anatomic, PM2 A2, low cervical height and minimum overbite). Lip support, smile line, hypernasality, and speech were checked. Putty index was made and the relation between implants and the

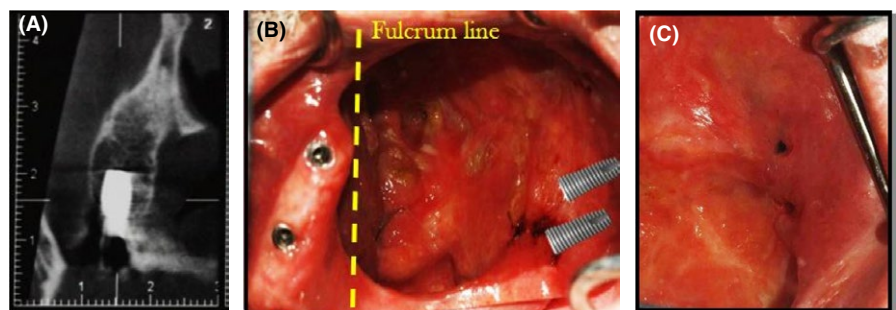


FIGURE 3 A, Implant CBCT. B, Maxillary implant direction. C, Maxillary left implants

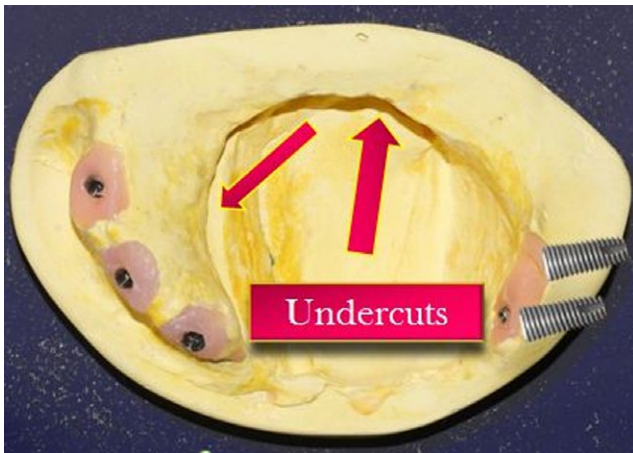


FIGURE 5 Diagnostic cast

teeth was analyzed. The abutment angle and type and framework space were determined by putty index (Figures 8 and 9).

With respect to the angle of implants in the left maxillary wall, which were parallel to the occlusal plane, the magnet seemed to be a suitable option. But the routine magnets available in the market could not be used for our patient because of the large angle between implants in the left maxilla. Thus, a custom magnet was designed for the patient using the magnets available in the market. The magnets were cemented to the framework and then, the housing was embedded right in front of the magnets in the denture (Figure 10).

The protrusive and non-centric relations were recorded for articulator setting. In right lateral articular setting, the condylar inclination was 26° and the Bennett angles were 15.25° . In the left lateral articular setting, the condylar inclination was 25° , and the Bennett angles were 15.1° . Implantium direct casting abutment was used in the right side of the maxilla (G/H = 1 mm, Gold Cylinder, RAB 45 GN, non-hex) and because of the 90° angle of implants in the left maxilla, the Implantium screw abutment (non-hex, SAB 45 55 L, G/H = 5.5 mm), burn out cylinder (SBC 45 BL), and magnet abutment (MGT 55 30 L, D: 5.5 mm, L: 3 mm, attractive force: 700 gf) were used for the left side.

Dio cast abutment was used in the mandible (CIA 48 12 N). The suprastructure framework was designed and its

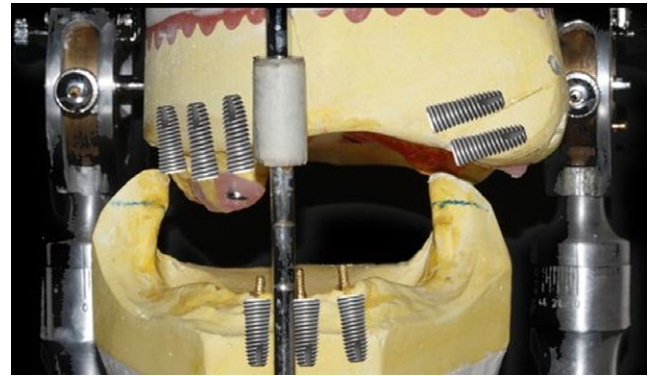


FIGURE 7 Intra arch mandibular and maxillary relationship in articulator

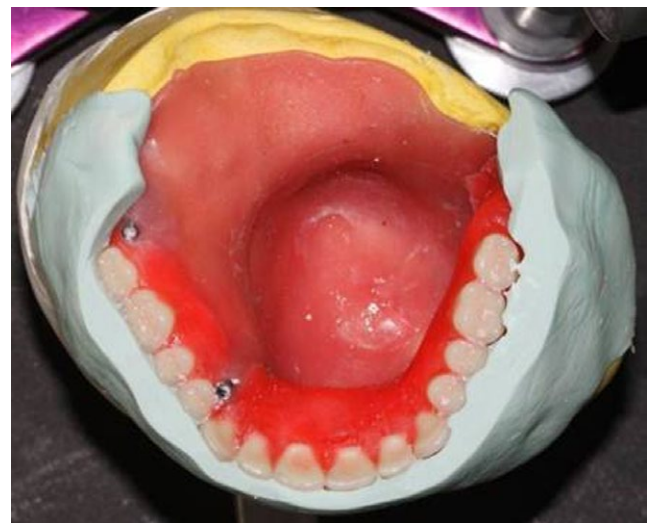

FIGURE 8 Taking putty index from tooth

distal region was relieved. Using mesh-type wax-up in the posterior maxilla, the patient had the ability to reline the denture. The important point was that the conventional magnetic abutments could not be used because of the 90° angle relative to the occlusal plane. Thus, a screw abutment with the longest gingival height was used, and the seat of the magnet was waxed up over it. Then, after casting, the suprastructure

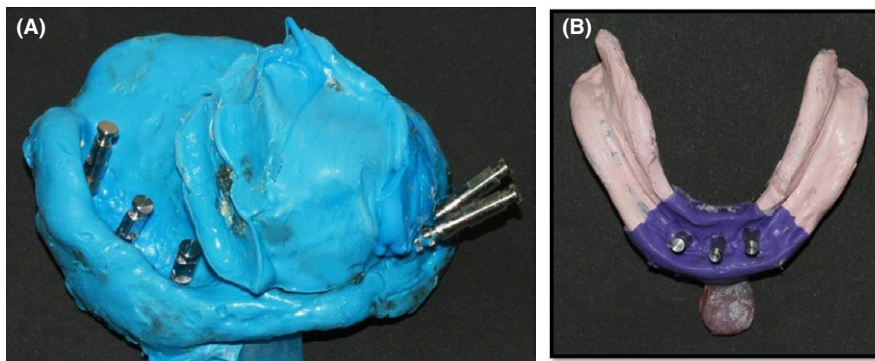


FIGURE 6 A, Final maxillary impression. B, Final mandibular impression

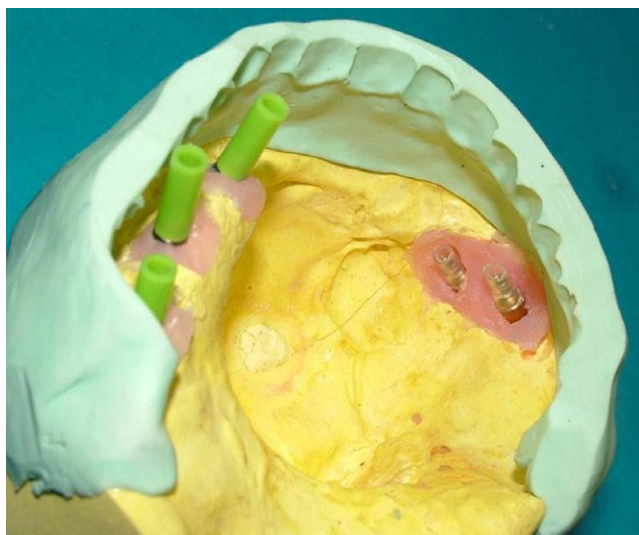

FIGURE 9 Abutment selection

was tried in the mouth and was satisfactory (Figure 11). Two magnets were attached to the housing with Panavia F2 resin cement (Kuraray, Tokyo, Japan), and two magnets were placed in front of them and embedded in acrylic denture base (Figure 12). The denture baking process was done by injection molding, and a hollow type maxillary obturator was fabricated (Figure 13). Lateral and protrusive occlusion balancing was done in remounting casts. The maxillary denture was converted to a hollow type at the defect site to become lighter (Figure 14). A flexible cap with 800-950 g retention was used that had to be changed annually. The mandibular overdenture retention was gained from the ball and bar attachment. The maxillary obturator retention was gained from tissue undercuts, bar and ball, and magnetic attachments. The denture was delivered to the patient and showed satisfactory results at the 5-year follow-up (Figures 15 and 16). The patient's satisfactory score is 2 that showed good results.

3 | DISCUSSION

Rehabilitation of maxillectomy patients is challenging for both the patient and clinician. Several factors play a role in choosing the best treatment plan for such patients such as the extent and size of the defect, number and quality of remaining teeth, and the quality of available bone.^{2,15} Microvascular free flap (soft tissue or bone flaps) and prosthetic restoration are the available treatment options, each having advantages and disadvantages. Prosthetic obturator can be a suitable treatment approach for smaller defects especially in patients who cannot tolerate microvascular surgery because of their medical situation. Retention and stability of prostheses are often compromised in patients with larger defects and edentulous patients, and radiation-induced xerostomia can further

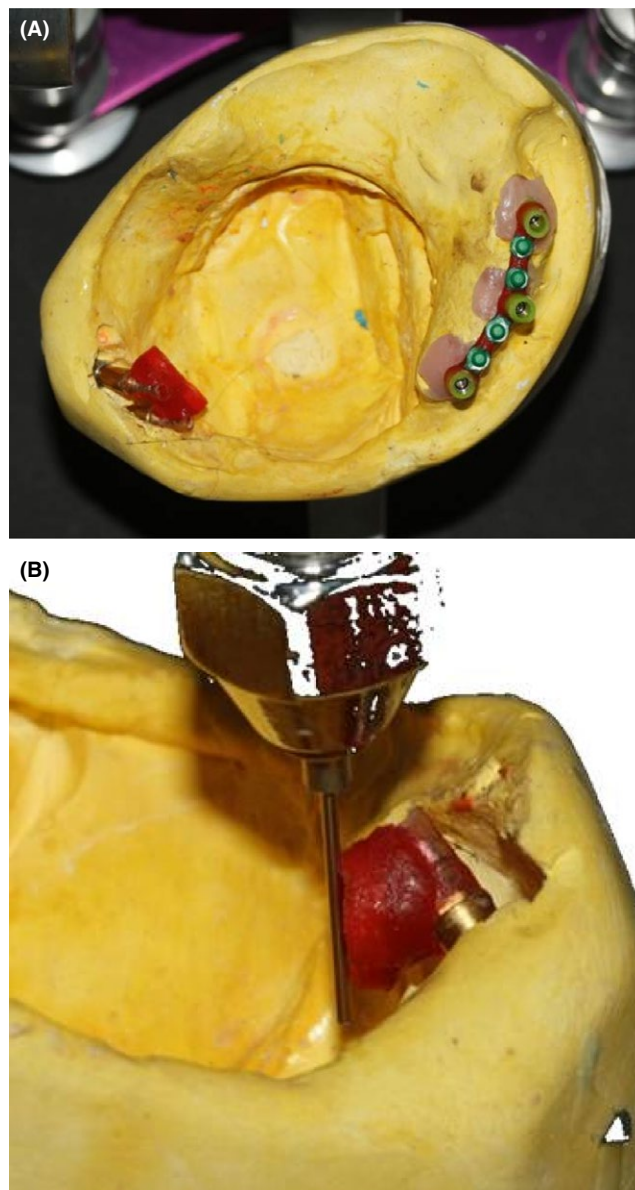


FIGURE 10 A, Maxillary magnetic holding framework duralay wax-up. B, Aligning magnetic holding formwork with surveyor

aggravate this condition.² Maxillectomy often causes mouth opening limitation in patients because grafts cannot be placed in the surgical site in such patients and also due to the secondary intention healing, as well as scar tissue formation following radiotherapy. Thus, such patients have difficulty in placing and removing the conventional hard acrylic obturators; moreover, repeated insertion and removal may traumatize the tissue.¹⁶

The advantages of using maxillofacial prostheses include improved mastication, deglutition, and speech, resuming social life soon after surgery, easy removal of the obturator to examine the tissue under the prosthesis (to detect possible changes), and easy use by the patient. Use of osseointegrated implants to increase the retention and stability of the obturator plays a significant role in maxillofacial rehabilitation and

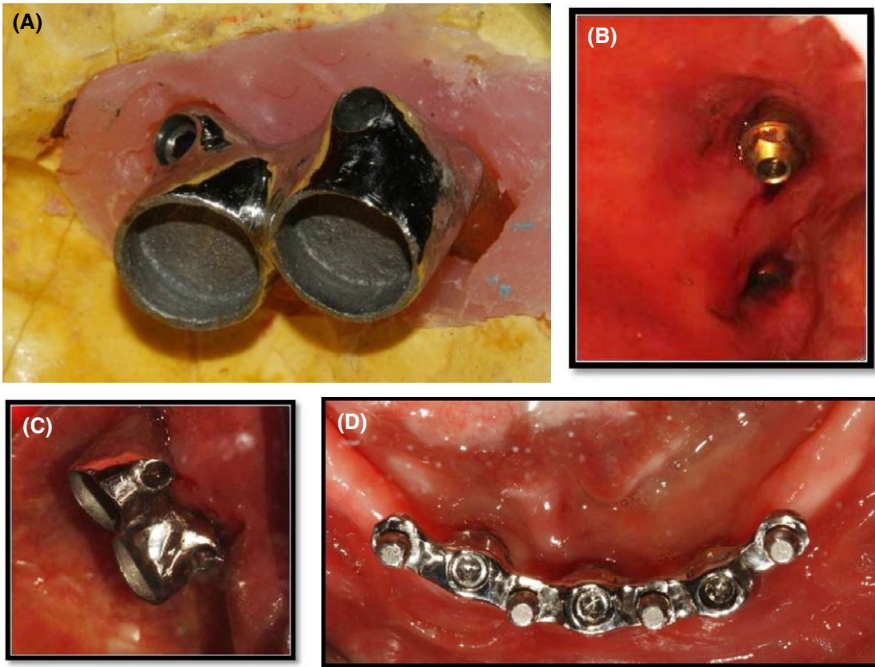


FIGURE 11 A, Final magnetic framework. B, Screw abutment torqued in mouth. C, Magnetic holding framework torqued on screw abutment. D, Intraoral view of mandibular bar and ball framework

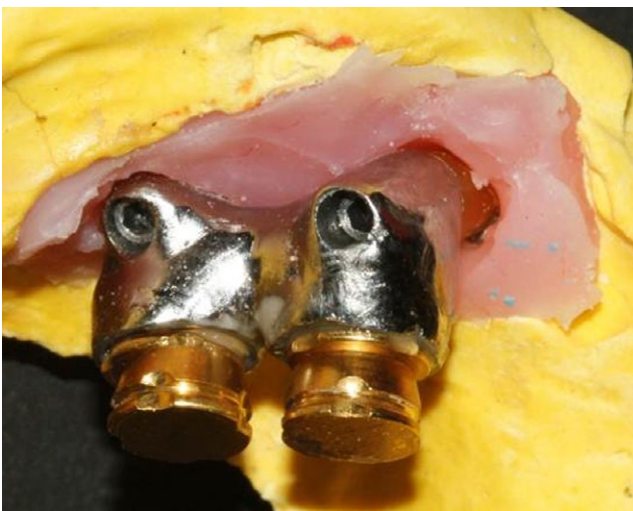


FIGURE 12 Magnets cemented to magnetic holding framework

eliminates the need for invasive surgical procedures such as bone grafting.¹⁷ The survival rate of implant-supported maxillofacial prostheses has been reported to be more than 96.1%.¹⁸

In this case, the use of magnets significantly inhibited the vertical movement of the denture due to gravity. Many patients have reported improvement in denture retention in the defect side following the use of magnets.¹¹ This technique is simple to use and less complex than other methods. Avoiding lateral stress is important for long-term survival of implants; this is what magnets do and guarantees the survival of implants. Magnets have disadvantages such as their low resistance to corrosion and possible cytotoxic effects that may

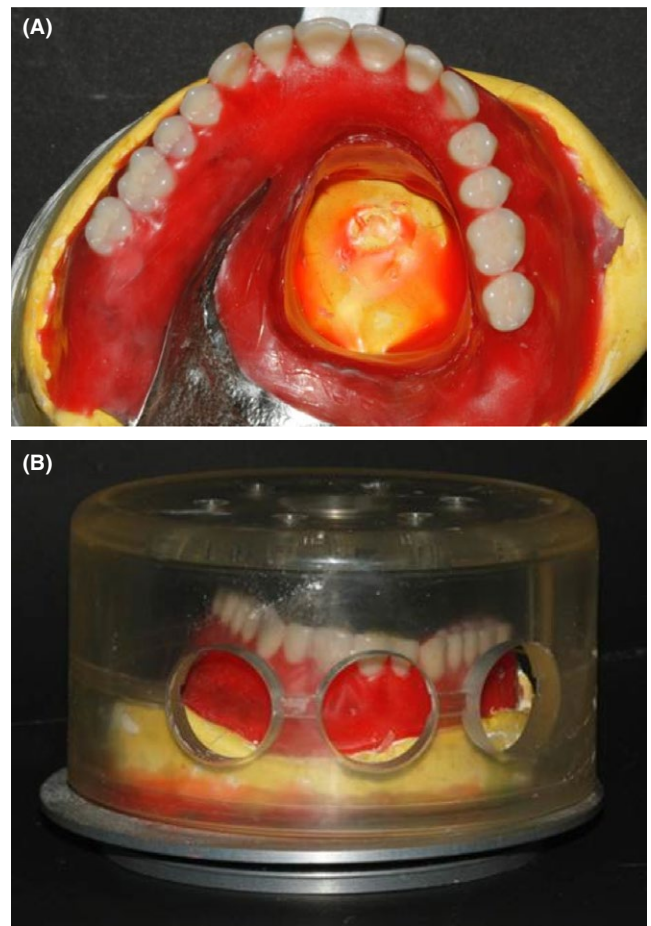


FIGURE 13 A, Maxillary obturator wax-up. B, Injection molding backing processing

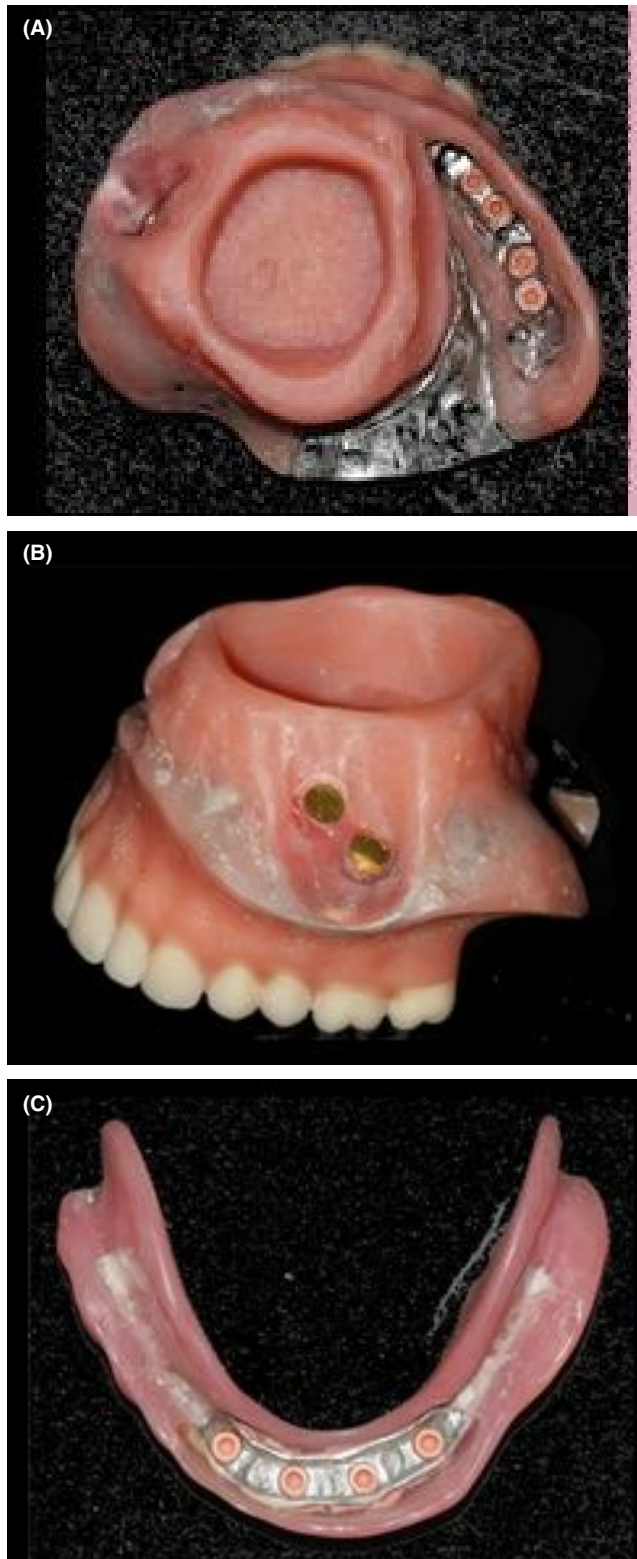


FIGURE 14 Final prosthesis. A, Maxillary obturator intraoral view. B, Maxillary obturator left lateral view. C, Mandibular overdenture intraoral view

contraindicate their use in the oral cavity. However, no clinical study has shown any adverse effect related to the use of magnets in the oral cavity so far.¹⁹

Magnets that connect directly to implants have the highest success rate and efficiency when the angle and position of implants are suboptimal. Magnetic connections resist tensile forces, but do not withstand lateral sliding forces; therefore, lateral forces should not be applied to implants.²⁰

Use of magnetic prostheses may also cause some difficulties for patients, which should be thoroughly explained and discussed with them. Magnets need replacement over time and the patient should be fully aware of their costs and should be provided with instructions on how to protect the prosthesis.²¹

Another problem faced by patients with maxillary defects is the relatively high weight of the prosthesis due to large amounts of acrylic resin used to fill the defect and also for the fabrication of hollow-bulb obturator. However, patients get used to it over time. Relining of the obturator by soft liners often increases patient comfort. The liners are soft and flexible and protect the soft tissue underneath the denture. An appropriate diet, use of chlorhexidine mouthwash and instruction on denture care can result in long-term success of denture and increase the survival rate of prosthesis.²²

CONFLICT OF INTEREST

None declared.

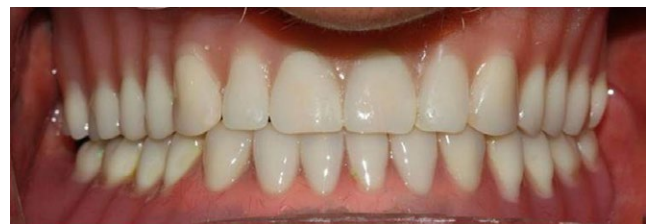

FIGURE 15 Intraoral final frontal view




FIGURE 16 Final frontal view

AUTHOR CONTRIBUTIONS

MA: involved in conception and design of the work, data collection, drafting of the manuscript, critical revision of the manuscript, and final approval of the version to be published. GS: involved in conception and design of the work, data collection, drafting of the manuscript, critical revision of the manuscript, and final approval of the version to be published. XM: involved in data collection, drafting of the manuscript, critical revision of the manuscript, and final approval of the version to be published.

ORCID

Mahnaz Arshad  <http://orcid.org/0000-0002-6278-6278>

REFERENCES

- Yenisey M, Külünk Ş, Kaleli N. An alternative prosthetic approach for rehabilitation of two edentulous maxillectomy patients: clinical report. *J Prosthodont*. 2017;26(5):483-488.
- Mertens C, de San Jose Gonzalez J, Freudlsperger C, Bodem J, Krisam J, Hoffmann J, Engel M. Implant-prosthetic rehabilitation of hemimaxillectomy defects with CAD/CAM suprastructures. *J Craniomaxillofac Surg*. 2016;44(11):1812-1818.
- Alhaji MN, Ismail IA, Khalifa N. Maxillary obturator prosthesis for a hemimaxillectomy patient: a clinical case report. *Saudi J Dent Res*. 2016;7:153-159.
- Murat S, Gurbuz A, Isayev A, Dokmez B, Cetin U. Enhanced retention of a maxillofacial prosthetic obturator using precision attachments: two case reports. *Eur J Dent*. 2012;6:212-217.
- Brown JS, Shaw RJ. Reconstruction of the maxilla and mid-face: introducing a new classification. *Lancet Oncol*. 2010;11:1001-1008.
- Lee JS, Lim YJ. Prosthodontic rehabilitation after myofascial flap surgery of hemimaxillectomy defects in the edentulous patient: a clinical report. *J Craniofac Surg*. 2014;25(2):e96-e98.
- Schwartz HC, Wollin M, Leake DL, Kagan AR. Interface radiation dosimetry in mandibular reconstruction. *Arch Otolaryngol*. 1976;105(5):293-295.
- Boyes-Varley JG, Howes DG, Davidge-Pitts K, Branemark I, McAlpine JA. A protocol for maxillary reconstruction following oncology resection using zygomatic implants. *Int J Prosthodont*. 2007;20:521-531.
- Noh K, Pae A, Lee JW, Kwon YD. Fabricating a tooth- and implant-supported maxillary obturator for a patient after maxillectomy with computer-guided surgery and CAD/CAM technology: a clinical report. *J Prosthet Dent*. 2016;115:637-642.
- Schmidt BL, Pogrel MA, Young CW, Sharma A. Reconstruction of extensive maxillary defects using zygomaticus implants. *J Oral Maxillofac Surg*. 2004;62:82-89.
- Jonkman RE, Van Waas MA, Kalk W. Satisfaction with complete intermediate dentures and complete intermediate overdentures. A 1-year study. *J Oral Rehabil*. 1995;22:791-796.
- Riley MA, Walmsley AD, Harris IR. Magnets in prosthetic dentistry. *J Prosthet Dent*. 2001;86:137-142.
- Arcuri MR, LaVelle WE, Fyler E, Jons R. Prosthetic complications of extraoral implants. *J Prosthet Dent*. 1993;69:289-292.
- Corderio PG, Santamaria E. A classification system and algorithm for reconstruction of maxillectomy and midfacial defects. *Plast Reconstr Surg*. 2000;105(7):2331-2346.
- Sharma AB, Beumer J. Reconstruction of maxillary defects: the case for prosthetic rehabilitation. *J Oral Maxillofac Surg*. 2005;63:1770-1773.
- Singh K, Kumar N, Gupta N, Sikka R. Modification of existed prosthesis into a flexible wall hollow bulb obturator by permanent silicone soft liner for a hemimaxillectomy patient with restricted mouth opening. *J Prosthodont Res*. 2015;59(3):205-209.
- King E, Abbott C, Dovgalski L, Owens J. Orofacial rehabilitation with zygomatic implants: CAD-CAM bar and magnets for patients with nasal cancer after rhinectomy and partial maxillectomy. *J Prosthet Dent*. 2017;117(6):806-810.
- Ueda M, Hibino Y, Niimi A. Usefulness of dental implants in maxillofacial reconstruction. *J Long Term Eff Med Implants*. 1999;9(4):349-366.
- Gowda ME, Mohan MS, Veram K, Roy ID. Implant rehabilitation of partial maxillectomy edentulous patient. *Contemp Clin Dent*. 2013;4(3):393-396.
- Oh WS, Roumanas E. Dental implant-assisted prosthetic rehabilitation of a patient with a bilateral maxillectomy defect secondary to mucormycosis. *J Prosthet Dent*. 2006;96:88-95.
- Colebeck AC, Kase MT, Nichols CB, Golden E, Huryn JM. Use of orbital conformer to improve speech in patients with confluent maxillectomy and orbital defects. *J Prosthodont*. 2016;25(3):241-246.
- Mohamed Usman JA, Ayappan A, Ganapathy D, Nasir NN. Oromaxillary prosthetic rehabilitation of a maxillectomy patient using a magnet retained two-piece hollow bulb definitive obturator; a clinical report. *Case Rep Dent*. 2013;2013:190180.

How to cite this article: Arshad M, Shirani G, Mahmoudi X. Rehabilitation after severe maxillectomy using a magnetic obturator (a case report). *Clin Case Rep*. 2018;6:2347–2354. <https://doi.org/10.1002/ccr3.1874>