

Original Article

Emergency surgical salvage for severe intracranial aneurysm rupture during endovascular coiling procedures not amenable to additional coiling

Eric S. Nussbaum, Archie Defillo, Tariq M. Janjua, Andrea Zelensky, Penny Tatman, Richard Stoller, Jodi Lowary, Leslie A. Nussbaum

Department of Neurosurgery, National Brain Aneurysm Center, St. Joseph's Hospital, St. Paul, MN, USA

E-mail: *Eric S. Nussbaum - lnussbaum@comcast.net; Archie Defillo - adefillo@healtheast.org; Tariq M. Janjua - tmjanjua@healtheast.org; Andrea Zelensky - amzelensky@healtheast.org; Penny Tatman - pjtatman@healtheast.org; Richard Stoller - rstoller@healtheast.org; Jodi Lowary - jllowary@healtheast.org; Leslie A. Nussbaum - lnussbaum@comcast.net

*Corresponding author

Received: 27 May 11

Accepted: 1 June 11

Published: 30 June 11

This article may be cited as:

Nussbaum ES, Defillo A, Janjua TM, Zelensky A, Tatman P, Stoller R, et al. Emergency surgical salvage for severe intracranial aneurysm rupture during endovascular coiling procedures not amenable to additional coiling. *Surg Neurol Int* 2011;2:87.

Available FREE in open access from: <http://www.surgicalneurologyint.com/text.asp?2011/2/1/87/82329>

Copyright: © 2011 Nussbaum ES. This is an open-access article distributed under the terms of the Creative Commons Attribution License, which permits unrestricted use, distribution, and reproduction in any medium, provided the original author and source are credited.

Abstract

Background: We report the management and outcomes of six patients who underwent emergency surgical intervention in the setting of severe intraprocedural rupture during endovascular treatment of an intracranial aneurysm not amenable to additional coiling.

Methods: From July 1997 through December 2010, our neurovascular service treated 1613 patients with coil embolization. During this time, we encountered six patients who suffered severe intraprocedural aneurysm rupture, defined by contrast extravasation during the coiling procedure, in whom additional attempted coiling failed to stop the ongoing extravasation. Hospital records, neuroimaging studies, operative reports, and follow-up clinic notes were complete and reviewed in all cases. The follow-up review in surviving patients ranged from 1.5 to 9 years (average 3.8 years), and no patient was lost to the follow-up review.

Results: In all cases, persistent extravasation necessitated urgent surgical decompression and securing of the ruptured aneurysm. Of these six cases, three patients achieved a good functional status after prolonged rehabilitation, and one of these had only subtle cognitive changes on formal neuropsychological testing. Two patients died.

Conclusion: Intraprocedural rupture during aneurysm coiling is a dangerous and potentially fatal event. Despite the seemingly hopeless nature of this situation, in our experience, aggressive management to control intracranial pressure combined with a rapid reversal of anticoagulation and early surgical intervention can result in reasonable outcomes in some patients.

Key Words: Aneurysm, brain, coiling, microsurgery, rupture

Access this article online

Website:

www.surgicalneurologyint.com

DOI:

10.4103/2152-7806.82329

Quick Response Code:



INTRODUCTION

Perforation or iatrogenic rupture during coil embolization of an intracranial aneurysm rapidly changes a controlled environment into a life-threatening situation. Subarachnoid hemorrhage under these circumstances likely represents the most dangerous complication of endovascular therapy. In our center after iatrogenic aneurysm rupture, the main goals of patient management include rapid control of intracranial pressure (ICP) with urgent ventriculostomy in the endovascular suite followed by neurovascular resuscitation, reversal of anticoagulation, and immediate surgical intervention.

MATERIALS AND METHODS

We retrospectively reviewed the records of all patients with intracranial aneurysms managed by our neurovascular service from July 1997 through December 2010. We identified six patients who underwent emergency surgical intervention in the setting of intraoperative rupture, defined by angiographic evidence of contrast extravasation during endovascular treatment of an intracranial aneurysm, not amenable to further endovascular intervention. Hospital records, neuroimaging studies, operative reports, and follow-up clinic notes were complete and reviewed in all cases. Follow-up review in surviving patients ranged from 1.5 to 9 years (average 3.8 years), and no patient was lost to follow-up review.

RESULTS

We identified six patients with persistent extravasation necessitating urgent surgical decompression despite aggressive attempts to stop the bleeding with additional coil placement and the use of a temporary intra-arterial balloon. In these patients, treatment consisted of immediate institution of barbiturate coma, reversal of anticoagulation with activated recombinant factor VIIa, and ventriculostomy in the endovascular suite. This was followed by emergency decompressive hemicraniectomy with the evacuation of intracerebral hematoma (all cases) and of intraventricular hemorrhage (three cases), nondominant temporal lobectomy (four cases; Figure 1), and securing the ruptured aneurysm in all cases.

In all instances, a generous hemicraniectomy was performed and the cerebrospinal fluid was drained aggressively to achieve adequate brain relaxation. The sphenoid wing was aggressively drilled down, and the sylvian fissure was opened widely. These measures allowed for adequate exposure of the aneurysm in all cases with good establishment of proximal and distal control. We used temporary vascular occlusion in all

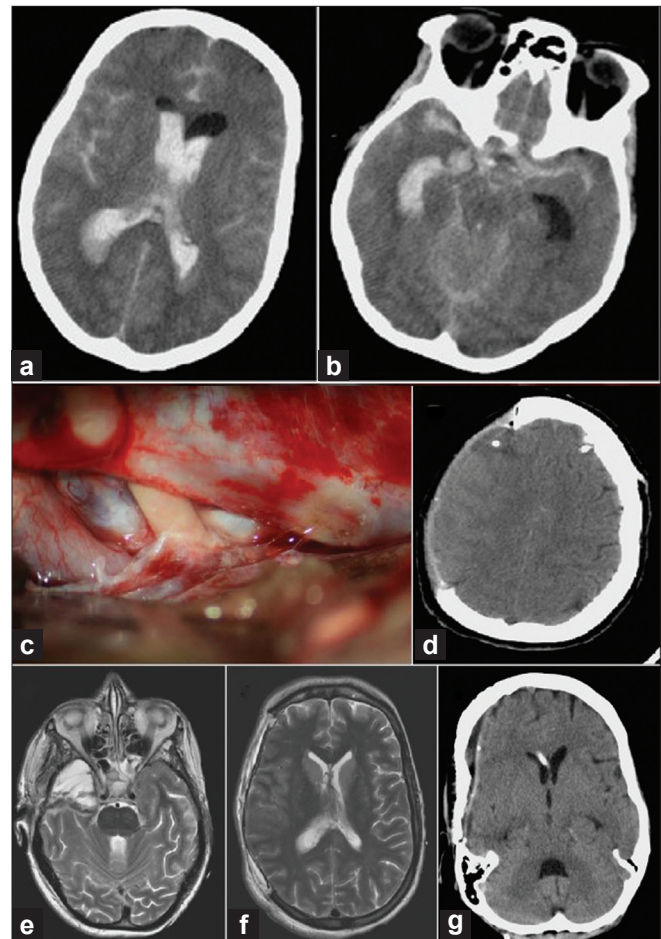


Figure 1: (a–b) Axial CT images demonstrating acute SAH and IVH from a right PCoA aneurysm. (c) Intraoperative view demonstrating the internal carotid artery and cranial nerve III after mesial temporal lobe resection. The right internal carotid artery is located inferomedially. (d and e) Early postoperative axial MR images showing the wide hemicraniectomy without evidence of significant cerebral injury or edema. Note the nondominant temporal lobectomy. (f and g) Late postoperative axial CT images following bone flap replacement and ventriculoperitoneal shunt

cases. The aneurysm could be directly clipped in four instances. One patient was treated by trapping of the involved segment when excellent distal collateral flow was present. Intraoperative angiography was performed in each case to confirm the exclusion of the aneurysm from the circulation without compromise of the involved vasculature.

Postoperatively, all six patients were maintained in barbiturate-induced coma for 5–7 days and managed with intravascular hypothermia to a mean core temperature of 36.5°C. All patients required the placement of a permanent ventriculoperitoneal shunt. Four required temporary tracheotomy and gastrostomy.

Outcomes at 1-year follow-up demonstrated that three patients achieved good functional status after prolonged

rehabilitation; one of these had only subtle cognitive changes on formal neuropsychological testing. One patient had moderate disability, and two suffered severe neurological injury on early magnetic resonance imaging (MRI) and died.

DISCUSSION

The introduction of Guglielmi detachable coil (GDC) embolization has dramatically changed the management of intracranial aneurysms. Aneurysm rupture during endovascular management represents a potentially devastating event. Several mechanisms proposed as causative factors for intraoperative rupture include fluctuations in blood pressure resulting from pain, anxiety, or anesthesia.^[4,5,7] Risk factors directly related to the procedure are iatrogenic rupture caused by guide wire microcatheter perforation and coil penetration, high-pressure contrast injection, and excessive packing of the coil material.^[1,5,6] After acute rupture, there are two basic patterns, those patients in whom coiling can be rapidly completed, achieving adequate aneurysm occlusion, and those patients presenting with persistent extravasation requiring urgent surgical therapy to secure the actively bleeding aneurysm. After iatrogenic perforation, factors such as prolonged systemic hypertension, persistent dye extravasation, and persistent prolongation of the contrast dye transit time suggesting ongoing intracranial pressure elevation are correlated with poor outcomes.^[9] When comparing aneurysm location during iatrogenic rupture, a worse prognosis has been identified in posterior circulation aneurysms as compared with those in the anterior circulation.^[5,6,8,9]

Although patients suffering severe rupture have been described as having worse prognosis, immediate reversal of anticoagulation therapy and surgical intervention is in fact feasible as demonstrated in our experience. In this setting, timely neurosurgical intervention is aimed at decreasing ICP via emergency ventriculostomy or decompressive hemicraniectomy with the evacuation of intraparenchymal hemorrhage and/or nondominant temporal lobectomy. Of the six cases with persistent extravasation necessitating urgent surgical decompression, surgical management under these circumstances was best accomplished by a generous hemicraniectomy. While severe intra-procedural rupture during endovascular therapy is rare, endovascular centers should have emergency surgical backup to address this uncommon but life-threatening situation.

Komiyama *et al.* reported 14 cases of ruptured intracranial aneurysms in which iatrogenic rupture occurred during peroperative cerebral angiography.^[3] Thirteen of the patients died and the remaining patient was severely disabled.^[3] The relatively favorable outcomes in some of

our patients may relate to the fact that the aneurysms were already partially packed with coils, possibly reducing the transmural pressure gradient. Additional factors presumably included rapid maneuvers to reduce brain metabolism with control of ICP, minimization of secondary brain insults, and rapid reversal of anticoagulation with activated factor VIIa.

Guglielmi *et al.* reported five iatrogenic ruptures during 127 treated aneurysms; 2 of the patients died and the remaining 3 were reported to have a good outcome.^[11] The patients who died were classified as poor graded Hunt–Hess SAH (grade IV and V), whereas the ones with a good outcome were graded Hunt–Hess II. Vinuela *et al.* reported a perforation rate of 2.73% during treatment of aneurysmal SAH in 403 treated aneurysms.^[10] The fatality rate was 45.5% as five patients died during 11 iatrogenic ruptures. All five of the patients who died were poor graded Hunt–Hess SAH.^[2]

CONCLUSION

Intraprocedural rupture during aneurysm coiling is a dangerous and potentially fatal event. After iatrogenic rupture during coil embolization, aggressive management for the control of ICP combined with neurovascular resuscitation, rapid reversal of anticoagulation, and early surgical intervention results in a reasonable outcome in selected cases.

REFERENCES

- Guglielmi G, Vinuela F, Duckwiler G. Coil induced thrombosis of intracranial aneurysms. In: Maciunas RJ, ed. Endovascular Neurological Intervention. Park Ridge: AANS; 1995:179-87.
- Guglielmi G, Vinuela F, Sepetka I, Macellari V. Electrothrombosis of saccular aneurysms via endovascular approach. Part I: Electro-chemical basis, technique, and experimental results. *J Neurosurg* 1991;75:1-7.
- Komiyama M, Tamura K, Nagata Y, Fu Y, Yagura H, Yasui T. Aneurysmal rupture during angiography. *Neurosurgery*. 1993;33:798-803.
- Lin JPT, Kricheff II, Chase NE. Blood pressure changes during retrograde brachial angiography. *Radiology*. 1964;83:640-6.
- McDougall CG, Halbach VV, Dowd CF, Higashida RT, Larsen DW, Hieshima GB. Causes and management of aneurysmal hemorrhage occurring during embolization with Guglielmi detachable coils. *J Neurosurg*. 1998;89: 87-92.
- Ricolfi F, Le Geurinel C, Blustajn J, Combes C, Burgieres P, Melon E, Gaston A. Rupture during treatment of recently ruptured aneurysms with Guglielmi electrodetachable coils. *AJNR Am J Neuroradiol*. 1998;19:1653-8.
- Saitoh H, Hayakawa K, Nishimura K, Okuno Y, Murayama C, Miyazawa T, *et al.* Intra-carotid blood pressure changes during contrast medium injection. *AJNR Am J Neuroradiol*. 1996;17:51-4.
- Schievink WI, Wijidicks EF, Piepgras DG, Chu-pin C, O'Fallon M, Whisnant JP. The poor prognosis of ruptured intracranial aneurysms of the posterior circulation. *J Neurosurg*. 1995;82:791-5.
- Tummala RP, Chu RM, Madison MT, Myers M, Tubman D, Nussbaum ES. Outcomes after aneurysm rupture during endovascular coil embolization. *Neurosurgery*. 2001;49:1059-67.
- Vinuela F, Duckwiler G, Mawad M. Guglielmi detachable coil embolization of acute intracranial aneurysm: Perioperative anatomical and clinical outcome in 403 patients. *J Neurosurg*. 1997;86:475-82.