

# Overexpression of neuromedin U is correlated with regional metastasis of head and neck squamous cell carcinoma

LEI WANG<sup>1\*</sup>, CHEN CHEN<sup>1\*</sup>, FEN LI<sup>1,2</sup>, QING-QUAN HUA<sup>1</sup>, SHIMING CHEN<sup>1,2</sup>, BOKUI XIAO<sup>1,2</sup>, MENGYUAN DAI<sup>1</sup>, MAN LI<sup>1</sup>, ANYUAN ZHENG<sup>1</sup>, DI YU<sup>1</sup>, ZHANG WEI HU<sup>1</sup> and ZEZHANG TAO<sup>1,2</sup>

<sup>1</sup>Department of Otolaryngology Head and Neck Surgery,

<sup>2</sup>Research Institute of Otolaryngology Head and Neck Surgery, Renmin Hospital of Wuhan University, Wuhan, Hubei 430060, P.R. China

Received June 1, 2015; Accepted May 5, 2016

DOI: 10.3892/mmr.2016.5347

**Abstract.** Regional metastasis is an important prognostic factor for patients with head and neck squamous cell carcinoma (HNSCC). Neuromedin U (Nmu) is a secreted neuropeptide, named due to its potent uterine contraction-inducing activity. The aim of the present study was to analyze the significance of Nmu in the regional metastasis of HNSCC. The characteristics of 240 patients recruited from the Department of Otolaryngology Head and Neck Surgery, Renmin Hospital of Wuhan University (Wuhan, China) were summarized retrospectively. The positive rate of neck dissection was analyzed according to the material. The expression levels of Nmu in human tumor samples were analyzed using immunohistochemistry. Subsequently, the expression of Nmu was investigated using a tissue microassay to analyze the association between Nmu protein expression and Tumor Node Metastasis (TNM) status. The positive rate of neck dissection was 51.4% in the study sample. The expression levels of Nmu in primary tumors with regional metastasis were higher, compared with those without metastasis. There was increased protein expression of Nmu in the advanced tumor tissues. The data obtained in the present study demonstrated that the expression of Nmu was correlated with regional metastasis and TNM status. Overexpression of Nmu may be involved in the process of regional metastasis of HNSCC, and may serve as a novel and valuable biomarker for predicting regional metastasis in patients with HNSCC.

## Introduction

Head and neck squamous cell carcinoma (HNSCC) is a broad term for cases of SCC arising in the paranasal sinuses, nasal cavity, oral cavity, pharynx and larynx. The majority of these are epithelial malignancies (1), and tobacco and alcohol consumption are the most important risk factors (2). Regional lymph node metastasis is a prominent characteristic of HNSCC and is an important prognostic factor for patients with HNSCC. Patients with regional metastasis have markedly reduced survival rates, compared with those without. Neck dissection is a standard technique used for the treatment of regional metastasis, however, predicting metastasis at early stages of HNSCC remains a challenge clinically, as the technology used to detect regional metastasis is not totally reliable. In patients with an N0 tumor status, 20-30% have been found to show occult metastasis during elective neck dissection, but remained pathologically N0 (3). In addition, cervical lymph node metastasis cannot be accurately judged or predicted.

Currently, biomarkers, including A15-3 and carcinoembryonic antigen, can be used as indices for the detection of tumor progression and metastasis. However, novel biomarkers are urgently required, particularly for detecting metastasis in early stage cancer. Neuromedin U (Nmu) is a secreted neuropeptide, which is isolated from the porcine spinal cord (4). It is named due to its potent uterine contraction-inducing activity. Following its identification, multiple physiological roles have been suggested. The first biological function of Nmu to be identified was smooth muscle contraction of the uterus (5). Current evidence suggests that Nmu is involved in pain, regulation of feeding and energy homeostasis, stress and immune-mediated inflammatory diseases, including asthma (6-11). Nmu has been shown to exist in several peripheral and central activities. Two types of Nmu receptor have been identified in humans; Nmu-R1 is expressed predominantly in the periphery, whereas Nmu-R2 is predominantly expressed in the central nervous system (12).

Until now, few studies have examined the role of Nmu in cancer. Pharmacological unmasking of HNSCC and esophageal squamous cell carcinoma revealed that the expression of Nmu was silenced in these tumors (13,14). The downregula-

---

*Correspondence to:* Mr. Zezhang Tao, Department of Otolaryngology Head and Neck Surgery, Renmin Hospital of Wuhan University, 99 Zhang Zhidong Road, Wuhan, Hubei 430060, P.R. China  
E-mail: taozezhong@hotmail.com

\*Contributed equally

*Key words:* neuromedin U, regional metastasis, head and neck squamous cell carcinoma, biomarker, tissue microassay

tion of genes encoding Nmu indicates that Nmu is potentially involved in preventing the action of tumor suppressors (15). Several studies have reported that Nmu is overexpressed in several types of cancer (16-19). Furthermore, Nmu has a close correlation with metastasis. It is a Rho GDP Dissociation Inhibitor 2-regulated gene, which appears to be important in lung metastasis (18). It may be involved in the hepatocyte growth factor-c-Met paracrine loop regulating cell migration and the invasiveness of pancreatic cancer (16). In addition, Rani *et al* (20) defined Nmu as a candidate drug response biomarker for HER2-overexpressing cancer, and as a candidate therapeutic target to limit metastatic progression.

In the present study, the potential role for Nmu as a novel biomarker of metastasis was investigated to determine whether it may offer value as a novel therapeutic target to inhibit the tumor growth and metastasis of HNSCC. The results demonstrated overexpression of the Nmu protein in the metastatic tissues of HNSCC, and this was correlated with the Tumor Node Metastasis (TNM) stage of HNSCC.

## Materials and methods

*Patient selection and tissue microassay.* The study was approved by the ethics committee of Renmin Hospital of Wuhan University (Wuhan, China). A total of 240 patients were recruited between 2012 to 2014, who were histologically diagnosed with HNSCC and were analyzed retrospectively at the Department of Otolaryngology Head and Neck Surgery of Renmin Hospital of Wuhan University (Table I). The group contained 236 men and four women. The average age of the patients was 60 years old (range, 31-80 years old). Tumor localization included the larynx, pharynx and nasopharynx. None of the patients received preoperative radiotherapy, and neck dissection had been performed on all patients during surgery. The patients were divided into two groups, consisting of those who had regional metastasis and those who did not, which was confirmed histologically. Detailed information, including tumor type, age, gender, differentiation grade and regional metastasis were obtained (Table I). The present study was approved by the appropriate ethical committees of the institutions in which the study was performed. Formal consent was not required

A total of 180 paraffin-embedded tissue blocks from the primary tumors of the patients were obtained, which was consistent with the retrospective samples selected from the Pathology Department of Renmin Hospital of Wuhan University. The paraffin-embedded tissue blocks were divided into two groups: Primary tumor with neck lymph node metastasis; and primary tumor without neck lymph node metastasis. All paraffin-embedded tissue blocks were cut and dried on 4  $\mu$ m-thick paraffin slides for immunohistochemistry.

An independent tissue microassay (TMA) was purchased from US Biomax, Inc. (Rockville, MD, USA; cat. no. HN803b). The TMA consisted of three types of tumors, including tongue carcinoma, laryngeal carcinoma and nasal carcinoma. Normal tissues were also included. In total, 62 men and 18 women formed the group, and the mean age was 53.4 years old (range, 18-90 years old). Detailed information of the TMA is shown in Table II.

*Immunohistochemical staining.* The tissue sections and the TMA tissues were deparaffinized with standard pure xylene for 15 min three times at room temperature, and hydrated in graded alcohols. Phosphate-buffered saline (PBS) was used to wash the sections. Antigen retrieval was performed in boiling citrate buffer (pH 6.0) for 15 min. The sections were then cooled down to room temperature in the buffers. Following washing the sections in PBS for 5 min three times, 0.3% hydrogen peroxide phosphate-citrate buffer was used to block endogenous peroxidase activity for 10 min. The sections were then rinsed with PBS for 5 min, following which they were incubated with primary Nmu antibody (cat. no. HPA025926; Sigma-Aldrich; St. Louis, MO, USA; dilution 1:100) for 12 h at 4°C. The sections were then incubated with horseradish peroxidase-conjugated goat anti-rabbit antibody (cat. no. KIT-9710; Maixin-bio, Fuzhou, China) for 30 min at room temperature. The slides were then stained with diaminobenzidine for 5 min. Hematoxylin was used to counterstain the nuclei, followed by dehydration and mounting. Images of the sections were captured using an Olympus BX40 microscope and CC-12 Soft-Imaging system (Olympus Corporation, Tokyo, Japan).

*Evaluation of immunohistochemical staining.* The staining revealed that Nmu was expressed in the cytoplasm and membrane. To further analyze the results, all the immunostained sections and TMAs were quantified and scored for intensity (0-3) and frequency (0-4). The intensity was scored as follows: Grade 0, negative; grade 1, weak intensity; grade 2, moderate intensity; grade 3, strong intensity. The frequency scores were respectively assigned as 1, 2, 3 and 4 when 0-25, 26-50, 51-75 and 76-100% of the tumor cells were positive. To perform statistical analysis, the Nmu protein intensity and frequency were transformed into a composite expression score (CES) utilizing the following formula: CES = intensity x frequency. The CES range was between 0 to 12, with scores of 0 considered negative, 1-4 considered weakly positive, 5-8 considered positive and 9-12 considered strongly positive.

*Statistic analysis.* All values are expressed as the mean  $\pm$  standard deviation. All statistical analysis was performed using SPSS software (version 19; IBM SPSS, Armonk, NY, USA). The expression levels of Nmu in primary tumor tissues were analyzed using a  $\chi^2$  test. The expression levels of Nmu measured in the TMA was analyzed by one-way of analysis of variance and Bonferroni's multiple comparison tests among groups. P<0.05 was considered to indicate a statistically significant difference.

## Results

*Characteristics of the retrospectively selected patients and the TMA.* The characteristics of all patients recruited in the clinic and the TMA are presented in Tables I and II, respectively. Of the patients recruited from the Department of Otolaryngology Head and Neck Surgery at Renmin Hospital of Wuhan University, men formed the majority of the group and the average age was 60 years old. No statistically significant differences between gender or age and

Table I. Characteristics of patients selected.

Characteristic	Metastasis group (n=123)	No metastasis group (n=117)	P-value
Gender			0.123
Male	123	113	
Female	0	4	
Age at diagnosis (years)			0.085
Median (range)	59.6 (31-73)	60.5 (41-80)	
Tumor type			0.023
Glottis	105	99	
Hypopharynx	10	10	
Supraglottis	3	1	
Nasopharynx	5	2	
Tonsil	0	1	
Differentiation grade			0.065
Well differentiated	118	106	
Moderate	5	7	
Poor	0	0	
Total	123	117	

Table II. Characteristics of the tissue microassay comprising 80 samples.

Characteristic	n (%)
Age (years)	53.4±10.5
Localization	
Tongue	42 (52.5)
Larynx	31 (38.6)
Nose	7 (8.9)
T classification	
T1	5 (8.3)
T2	30 (50.0)
T3	17 (28.3)
T4	8 (13.3)
N classification	
N0	42 (68.9)
N1	16 (26.2)
N2	3 (5.0)
Differentiation	
1	12 (16.7)
2	36 (50.0)
3	24 (33.3)
Staging	
I	5 (0.81)
II	33 (54.1)
III	14 (23.0)
IV	9 (14.8)
Metastasis	8 (10.0)
Normal adjacent tongue tissue	2 (2.5)
Normal	9 (11.2)

metastasis were observed. The glottis was the most common site of tumor formation (85.0%), and 93.3% patients exhibited well-differentiated tumors.

In the present study, all patients underwent neck dissection. A total of 123 patients were confirmed to have regional metastasis using histological examination following surgery. The positive rate of neck dissection was only 51.3%, with 48.7% of the patients confirmed as having negative lymph nodes histologically. These data suggested that certain patients may avoid unnecessary neck dissection.

*Analysis of the expression of Nmu in primary tumors.* The present study first identified the expression of Nmu in the clinical tissue sections of HNSCC. The frequency and intensity of the immunohistochemical staining in all tissue sections were analyzed. Representative images of the expression of Nmu in the tissues are shown in Fig. 1A. Nmu was expressed in the cytoplasmic membrane. The expression level of Nmu was transformed into a single numerical measurement, CES. A significant increase in CES was noted in the primary tumor with metastasis group, compared with the group without metastasis ( $P<0.01$ ; Fig. 1B). From the images, it appeared that the Nmu protein was expressed predominantly among the carcinoma nests in primary tumors with metastasis. These data suggested that Nmu may be involved in the process of metastasis in HNSCC.

*Analysis of the expression of Nmu in a TMA of HNSCC.* Following completion of the analysis of Nmu using the clinical samples of HNSCC, A TMA, which contained three types of head and neck cancer (tongue, larynx and nose) was performed to provide a subset analysis, which also included normal tissues. As shown in Fig. 2, integral images of immunohistochemical staining of the TMA with an anti-Nmu

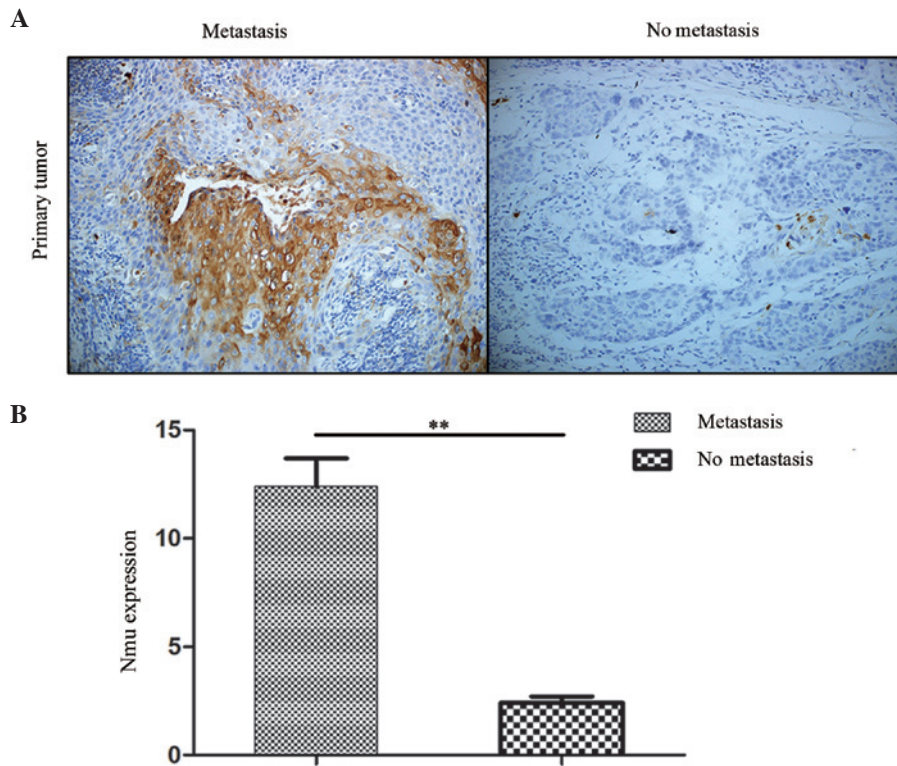


Figure 1. (A) Representative images of IHC staining for Nmu protein in human primary tumors with metastasis and without metastasis (Magnification, x200). (B) IHC index (intensity x percentage of tumor cells) showed that the expression of Nmu in the primary tumor tissues with metastasis was higher, compared with the tissues without metastasis (\*\* $P < 0.01$ ). Nmu, neuromedin U IHC, immunohistochemical.

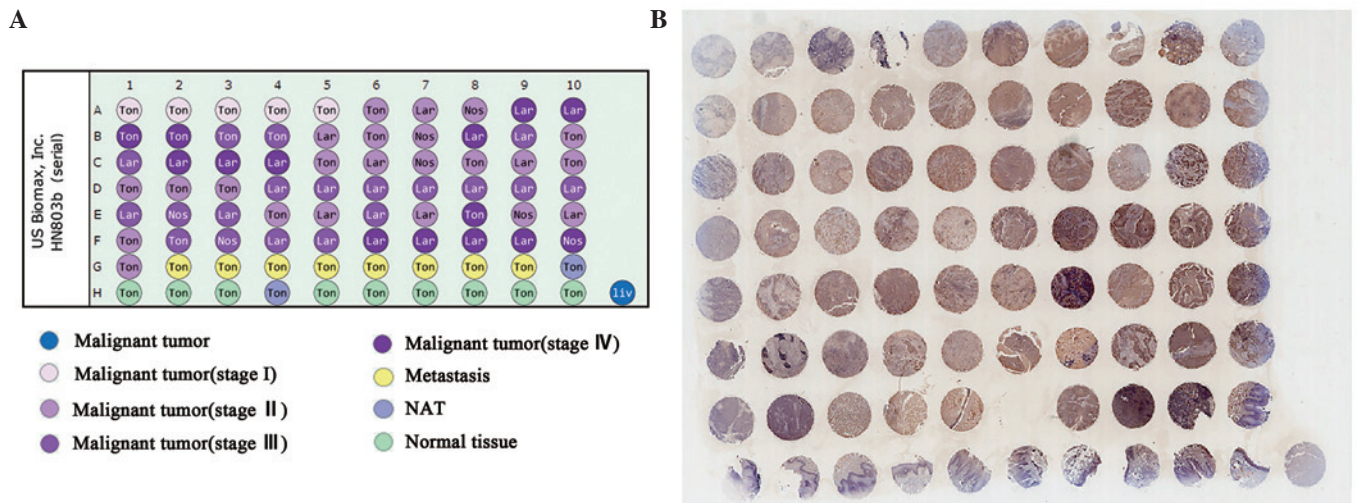


Figure 2. Nmu microarray. (A) Map of the microarray. (B) Representative images of immunohistochemical staining of a head and neck cancer tissue microarray with anti-Nmu antibody. This tissue microarray includes Ton, Lar and Nos carcinomas. NATs and normal tissue are also included. Nmu, neuromedin U; Ton, tongue; Lar, larynx; Nos, nose; liv, liver; NAT, normal adjacent tissue.

antibody were captured. The immunohistochemical (IHC) score of every sample in the TMA was determined. The expression of Nmu among the T-stage, N-stage and grades of differentiation were compared, respectively.

For the T-stage, representative images of the expression of Nmu are shown in Fig. 3. The protein expression of Nmu had a significantly increased CES in T1 tissues, compared with the normal tissues ( $P < 0.05$ ), and the CES in the T2, T3 and T4 tissues was markedly increased, compared with T1

tissues ( $P < 0.01$ ). There was a statistically significant difference between T3 and T2 tissues, however, no statistically significant differences were observed between T2 and T1 tissues or between T3 and T4 tissues, These data suggested that the expression of Nmu was correlated with T-stage, and an increase in the expression of Nmu was found in HNSCC at a high T-stage.

The N-stage represents the lymph node metastasis. The present study analyzed the correlation between the N-stage

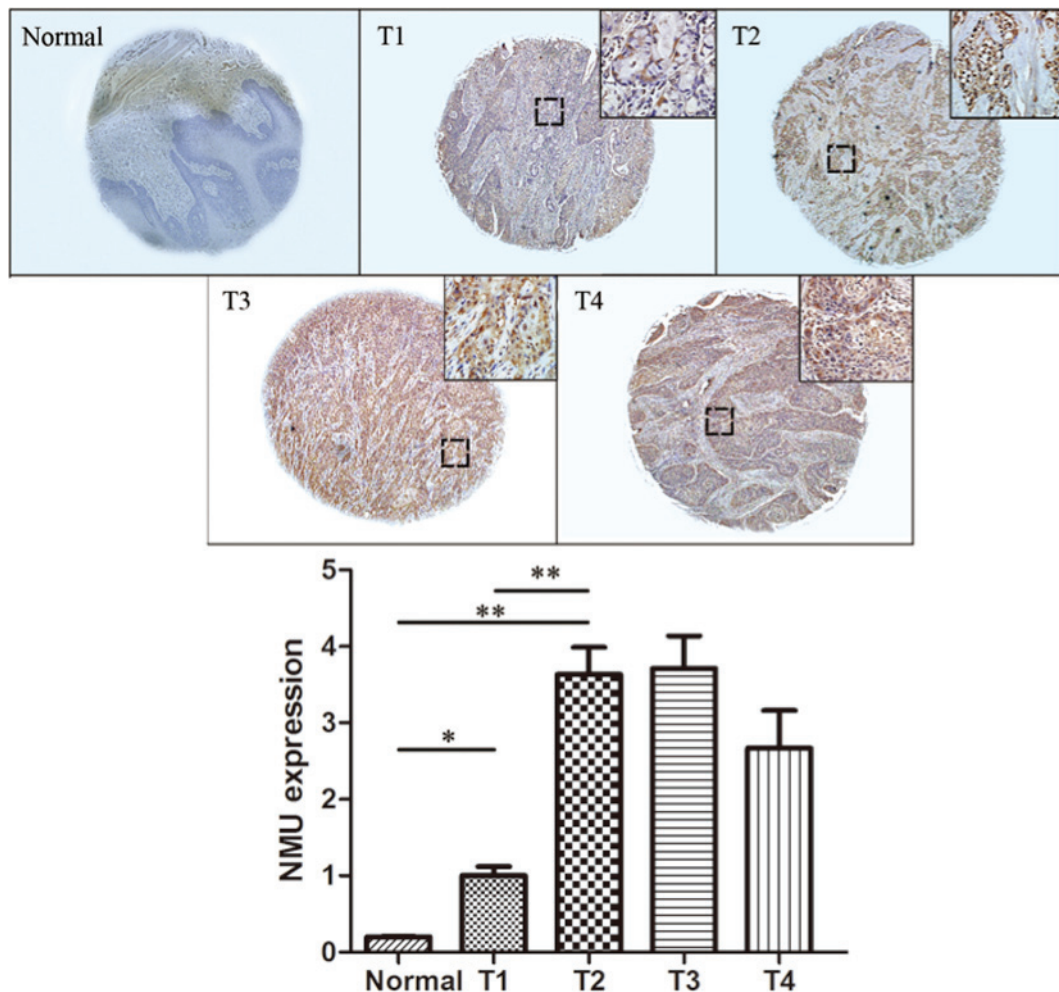


Figure 3. Representative images of IHC staining for Nmu protein in a tissue microarray of tissues at different T-stages. Normal tissue stained negative for Nmu protein. T1 showed weak positive staining, T2 stained positively, T3 and T4 showed strongly positive staining. (Image magnification, x100; enlarged area in top right corner, magnification, x200) IHC index (intensity x percentage of tumor cells) showed a statistically significant difference between T1 and normal tissues, and between T2 and T1 tissues. Data are expressed as the mean  $\pm$  standard deviation (\* $P$ <0.05, \*\* $P$ <0.01). Nmu, neuromedin U; IHC, immunohistochemistry.

and the expression levels of Nmu, for which representative images are shown in Fig. 4A. The CES of the Nmu protein showed that there was a statistically significant difference in the expression of Nmu in the N0 tissues, compared with normal tissues ( $P$ <0.05). There was also a statistically significant difference between the N1 and N0 tissues ( $P$ <0.01). In addition, a statistically significant difference in the expression of Nmu was observed between the N2 and N1 tissues ( $P$ <0.01; Fig. 4B).

Finally, the expression levels of Nmu between tumor grades were compared. Grades 1, 2 and 3 represented well, moderate and poorly differentiated tumor tissues, respectively. The CES was significantly increased in all three grades, compared with the normal tissues ( $P$ <0.05), however, no statistically significant difference was found among the grades. Representative images and the IHC indices are shown in Fig. 5A and B. The results suggested that the expression of Nmu was not correlated with tumor grade.

## Discussion

Clinically, the importance of regional metastasis is well recognized. However, the positive rate of selective neck

dissection requires further improvement, particularly for early stage cancer. Ferlito *et al* showed that only three of 211 patients diagnosed with laryngeal cancer with clinical N0 in the neck were confirmed to have positive lymph node metastasis (21), suggesting that certain aspects of undesirable selective neck dissection in the clinic may be avoided. In the present study, the positive rate of neck dissection was 51.4%, and >40% of patients were confirmed to have negative lymph nodes histologically. This suggested that areas in these patients may have been overtreated. This increases the potential for the incidence rate of surgical complications, and reduces quality of life in patients with HNSCC. Therefore, techniques to detect regional metastasis more accurately requires further investigation.

Biomarkers offer potential for predicting tumor progression and metastasis during the process of cancer therapy in the future. At present, no clinic biomarkers are used for the precise prediction of regional metastasis in HNSCC. The role of Nmu in cancer remains to be fully elucidated. Several studies have reported that Nmu acts as a tumor suppressor gene (15), and Nmu and its receptors are reported to be correlated with cancer (22). Euer *et al* (23) investigated the transcriptional profile of 11 ovarian tumor

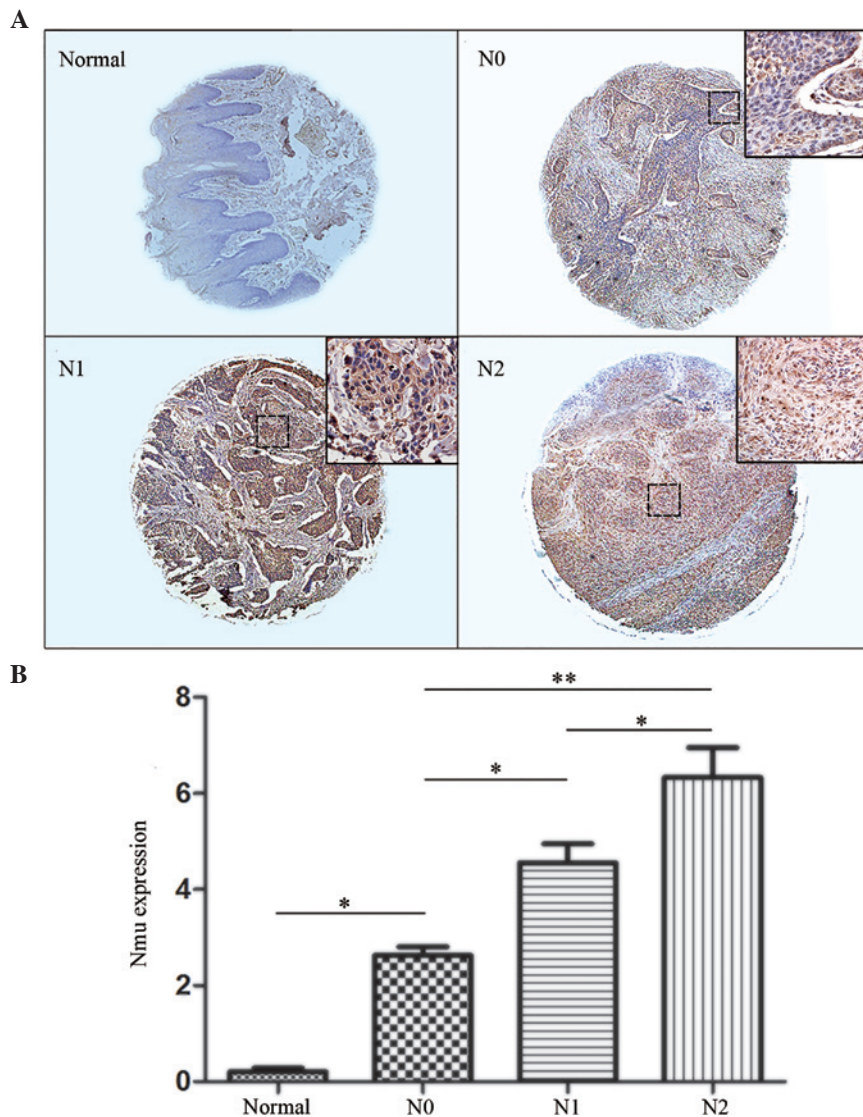


Figure 4. (A) Representative images of IHC staining for Nmu protein in a tissue microarray of tumor tissues of different N-stages. Normal tissue stained negative for Nmu protein. N0, N1 and N2 stages showed weak positive, positive and strongly positive staining, respectively. (Images, magnification, x100; enlarged area of image in top right corner, magnification, x200). (B) IHC index (intensity x percentage of tumor cells). Expression levels of Nmu in the N0 tissues were significantly higher, compared with those in normal tissues. There was a statistically significant difference between N1 and N0, and the N2 index was significantly higher, compared with the N1 index. Data are expressed as the mean  $\pm$  standard deviation ( $P < 0.05$  and  $^{**}P < 0.01$ ). Nmu, neuromedin U; IHC, immunohistochemistry.

cell lines and two immortalized ovarian surface epithelial cell lines using GeneChip technology, and identified Nmu as an ovarian cancer-associated antigen. Using the same method, Nmu was revealed as an oncogene, which had not been previously implicated, in oral cancer (15). Although Nmu has been shown to have a potential role in preventing the action of tumor suppressor genes (15), its functions in cancer require further investigation.

In the present study, the overexpression of Nmu was identified in clinical tissue sections of HNSCC. The expression of Nmu was increased in primary tumors with metastasis, compared with those without metastasis. A TMA was then performed to confirm the expression of Nmu in HNSCC. Analysis of the pathological specimens demonstrated for the first time, to the best of our knowledge, that Nmu was correlated with tumor progression and regional metastasis. As further conformation, the TMA found that Nmu was

overexpressed in advanced tumor tissues. These results indicated that Nmu may be a potential biomarker of tumor and metastasis in HNSCC. Currently, computed tomography and magnetic resonance imaging are important technologies for the detection of metastases clinically. However, statistics have shown that the results of all the pretreatment examinations are significantly different from histopathological results (24). Thus, combining these two forms of examination are likely to improve accuracy when predicting regional metastasis, and may increase the positive rate of neck dissection.

Generally, poorly differentiated tumors show a higher rate of metastasis, however, in the present study, no statistically significant difference was observed in the expression of Nmu among tumor grades. It was concluded that Nmu was not correlated with tumor grade, possibly due to the fact that the poorly differentiated tumor may be in the early stage, whereas well differentiated tumors may be of a later stage. In addition,

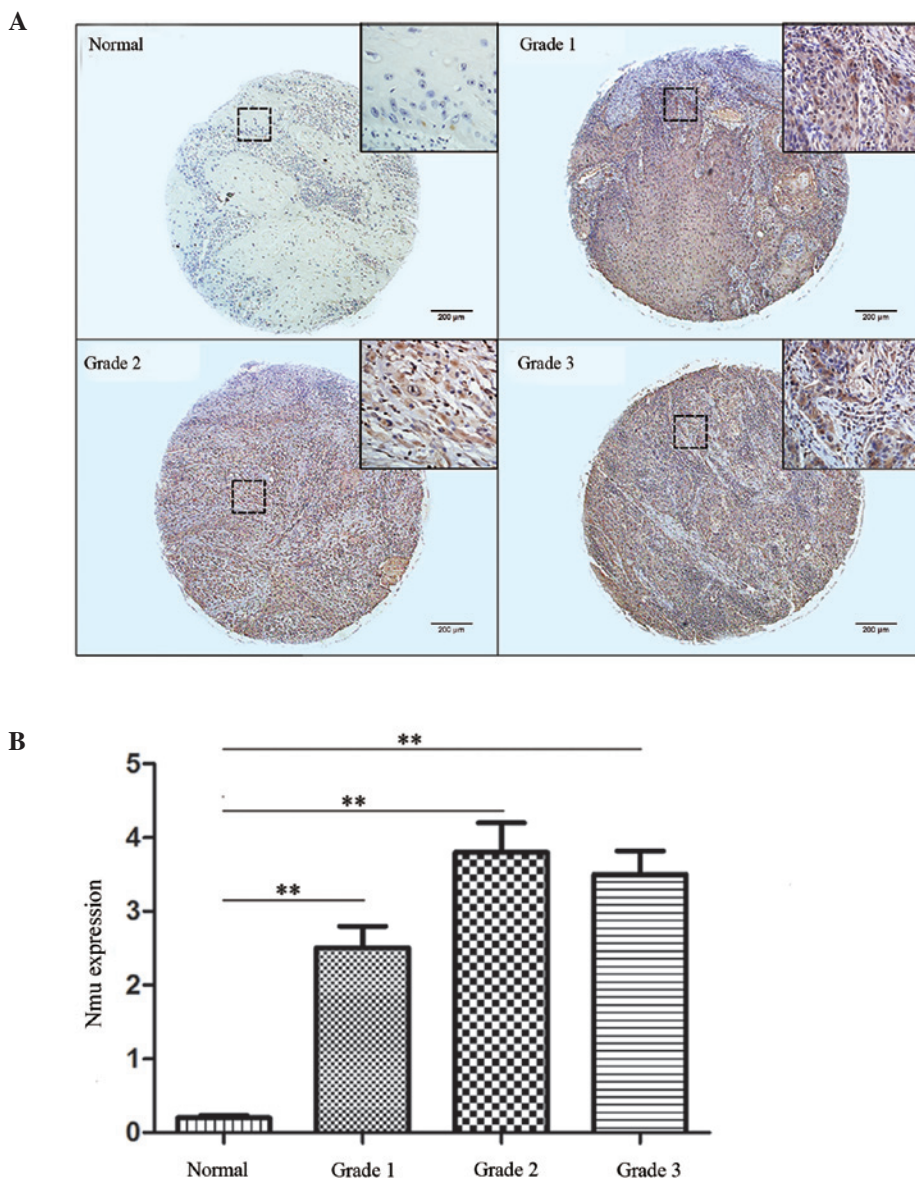


Figure 5. (A) Representative images of IHC staining for Nmu protein in a tissue microarray of different tumor grades. Normal tissue stained negative for Nmu protein. All the tumor grades stained strongly positive. (Images, magnification, x100; enlarged area of image in top right corner, magnification, x200). (B) IHC index (intensity x percentage of tumor cells) is shown. No significant differences were found among the grades (\*\* $P < 0.01$ ). Nmu, neuromedin U; IHC, immunohistochemistry.

the present study found that the protein expression of Nmu in the T4 tissues was decreased, compared with the T3 tissues, although there was no statistical significance between them.

It is important to note that, despite increased data confirming the function of Nmu in metastasis, the mechanism underlying the contribution of Nmu to metastasis remains to be fully elucidated. Further investigations on this mechanism are required in the future to provide a strategy in targeted therapy for metastasis. It may be that the sensitivity of detecting metastasis using the single biomarker of Nmu is low, and the identification of additional biomarkers is required to improve the positive rate of detecting regional metastasis.

In conclusion, the results of the present study suggested that Nmu may be used as a biomarker of regional metastasis. It may be also used as a therapeutic target in the treatment of regional metastasis.

#### Acknowledgements

This study was funded by the National Natural Science Foundation of China (grant nos. 81372880 and 81172569), the doctoral program of Higher Education Research Fund (grant nos. 20130141120093 and 20110141110062) and the Natural Science Foundation of Hubei Province (grant no. 2012FFA045).

#### References

- Argiris A, Karamouzis MV, Raben D and Ferris RL: Head and neck cancer. *Lancet* 371: 1695-1709, 2008.
- Argiris A and Eng C: Epidemiology, staging and screening of head and neck cancer. *Cancer Treat Res* 114: 15-60, 2003.
- Pimenta Amaral TM, Da Silva Freire AR, Carvalho AL, Pinto CA and Kowalski LP: Predictive factors of occult metastasis and prognosis of clinical stages I and II squamous cell carcinoma of the tongue and floor of the mouth. *Oral Oncol* 40: 780-786, 2004.

4. Minamino N, Kangawa K and Matsuo H: Neuromedin U-8 and U-25: Novel uterus stimulating and hypertensive peptides identified in porcine spinal cord. *Biochem Biophys Res Commun* 130: 1078-1085, 1985.
5. Minamino N, Kangawa K and Matsuo H: Neuromedin U-8 and U-25: Novel uterus stimulating and hypertensive peptides in porcine spinal cord. *Biochem Biophys Res Commun* 130: 1078-1085, 1985.
6. Budhiraja S and Chugh A: Neuromedin U: Physiology, pharmacology and therapeutic potential. *Fundam Clin Pharmacol* 23: 149-157, 2009.
7. Yu XH, Cao CQ, Mennicken F, Puma C, Dray A, O'Donnell D, Ahmad S and Perkins M: Pro-nociceptive effects of neuromedin U in rat. *Neuroscience* 120: 467-474, 2003.
8. Kojima M, Haruno R, Nakazato M, Date Y, Murakami N, Hanada R, Matsuo H and Kangawa K: Purification and identification of neuromedin U as an endogenous ligand for an orphan receptor GPR66 (FM3). *Biochem Biophys Res Commun* 276: 435-438, 2000.
9. Nakazato M, Hanada R, Murakami N, Date Y, Mondal MS, Kojima M, Yoshimatsu H, Kangawa K and Matsukura S: Central effects of neuromedin U in the regulation of energy homeostasis. *Biochem Biophys Res Commun* 277: 191-194, 2000.
10. Niimi M, Murao K and Taminato T: Central administration of neuromedin U activates neurons in ventrobasal hypothalamus and brainstem. *Endocrine* 16: 201-206, 2001.
11. Funes S, Hedrick JA, Yang SJ, Shan LX, Bayne M, Monsma FJ and Gustafson EL: Cloning and characterization of murine neuromedin U receptors. *Peptides* 23: 1607-1615, 2002.
12. Domin J, Ghatei MA, Chohan P and Bloom SR: Neuromedin U - a study of its distribution in the rat. *Peptides* 8: 779-784, 1987.
13. Yamashita K, Upadhyay S, Osada M, Hoque MO, Xiao Y, Mori M, Sato F, Meltzer SJ, and Sidransky D: Pharmacologic unmasking of epigenetically silenced tumor suppressor genes in esophageal squamous cell carcinoma. *Cancer Cell* 2: 485-495, 2002.
14. Tokumaru Y, Yamashita K, Osada M, Nomoto S, Sun DI, Xiao Y, Hoque MO, Westra WH, Califano JA and Sidransky D: Inverse correlation between cyclin A1 hypermethylation and p53 mutation in head and neck cancer identified by reversal of epigenetic silencing. *Cancer Res* 64: 5982-5987, 2004.
15. Alevizos I, Mahadevappa M, Zhang X, Ohyama H, Kohno Y, Posner M, Gallagher GT, Varvares M, Cohen D, Kim D, *et al*: Oral cancer in vivo gene expression profiling assisted by laser capture microdissection and microarray analysis. *Oncogene* 20: 6196-6204, 2001.
16. Ketterer K, Kong B, Frank D, Giese NA, Bauer A, Hoheisel J, Korc M, Kleeff J, Michalski CW and Friess H: Neuromedin U is overexpressed in pancreatic cancer and increases invasiveness via the hepatocyte growth factor c-Met pathway. *Cancer Lett* 277: 72-81, 2009.
17. Shetzline SE, Rallapalli R, Dowd KJ, Zou S, Nakata Y, Swider CR, Kalota A, Choi JK and Gewirtz AM: Neuromedin U: A Myb-regulated autocrine growth factor for human myeloid leukemias. *Blood* 104: 1833-1840, 2004.
18. Wu Y, McRoberts K, Berr SS, Frierson HF Jr, Conaway M and Theodorescu D: Neuromedin U is regulated by the metastasis suppressor RhoGDI2 and is a novel promoter of tumor formation, lung metastasis and cancer cachexia. *Oncogene* 26: 765-773, 2007.
19. Harten SK, Esteban MA, Shukla D, Ashcroft M and Maxwell PH: Inactivation of the von Hippel-Lindau tumour suppressor gene induces Neuromedin U expression in renal cancer cells. *Mol Cancer* 10: 89, 2011.
20. Rani S, Corcoran C, Shiels L, Germano S, Breslin S, Madden S, McDermott MS, Browne BC, O'Donovan N, Crown J, *et al*: Neuromedin U: A candidate biomarker and therapeutic target to predict and overcome resistance to HER-tyrosine kinase inhibitors. *Cancer Res* 74: 3821-3833, 2014.
21. Ferlito A, Rinaldo A, Silver CE, Shah JP, Suárez C, Medina JE, Kowalski LP, Johnson JT, Strome M, Rodrigo JP, *et al*: Neck dissection: Then and now. *Auris Nasus Larynx* 33: 365-374, 2006.
22. Brighton PJ, Szekeres PG and Willars GB: Neuromedin U and its receptors: Structure, function and physiological roles. *Pharmacol Rev* 56: 231-248, 2004.
23. Euer NI, Kaul S, Deissler H, Möbus VJ, Zeillinger R and Weidle UH: Identification of LICAM, Jagged2 and Neuromedin U as ovarian cancer-associated antigens. *Oncol Rep* 13: 375-387, 2005.
24. Haberal I, Celik H, Göçmen H, Akmansu H, Yörük M and Ozeri C: Which is important in the evaluation of metastatic lymph nodes in head and neck cancer: Palpation, ultrasonography, or computed tomography? *Otolaryngol Head Neck Surg* 130: 197-201, 2004.