



# Bilateral Hypertensive Papillopathy with Diffuse Retinal Telangiectasis

Utku Limon, Betül İlkay Sezgin Akcay

Department of Retina, University of Health Sciences Umraniye Training and Research Hospital Eye Clinic, Istanbul, Türkiye

## Abstract

A 16-year-old type 1 diabetic female patient was consulted to our clinic for acute bilateral painless vision loss with a 2-week history in the right eye and a 1-week history in the left eye. At the initial visit, the best-corrected visual acuity was 0.2 in the right eye and 0.05 in the left eye. In fundus examination, both optic disks were pale and slightly swollen. In both eyes, superficial telangiectatic vessels were extending from the optic disk to the retina. Telangiectatic vessels disappeared within 10 days with systemic hypertension regulation and without any ocular treatment.

**Keywords:** Hypertensive papillopathy, optic disk, telangiectatic vessels

## Introduction

Bilateral disk edema may occur due to idiopathic intracranial hypertension (IIH), increased intracranial pressure (brain tumor, abscess, and hematoma), cerebral venous thrombosis, non-arteritic and arteritic anterior ischemic optic neuropathy (NA-AION and A-AION), and diabetic and hypertensive papillopathy (1).

Flame-shaped hemorrhages, cotton-wool spots, hard exudates, and papilla edema may develop in advanced hypertensive retinopathy and malignant hypertension. In malignant hypertension, the blood pressure is typically above 180/120 and organ damage may develop (2).

In this case report, we presented a case with malignant hypertension and uncontrolled diabetes with telangiectatic disk and retinal vessels.

## Case Report

A 16-year-old type 1 diabetic female patient who was treated in the pediatric endocrinology clinic due to irregular blood glucose, systemic hypertension, and nephropathy was consulted to our clinic due to acute bilateral painless vision loss. The right eye vision loss started 2 weeks ago and resolved spontaneously within 2 weeks. The left eye vision loss had started 1 week ago. Her best-corrected visual acuity (BCVA) was 0.2 in the right eye and 0.05 in the left eye at the initial visit. Direct and indirect light responses were normal in both eyes. There were no relative afferent pupillary defects. Bilateral color vision was normal. Anterior segment examination was unremarkable in both eyes. Intraocular pressure was 14 mm Hg in the right eye and 13 mm Hg in the left eye. The optic disk was pale and slightly swollen in the right fundus examination. There were telangiectatic vessels and splinter

**How to cite this article:** Limon U, Sezgin Akcay BI. Bilateral Hypertensive Papillopathy with Diffuse Retinal Telangiectasis. *Beyoglu Eye J* 2022; 7(4): 334-338.

**Address for correspondence:** Utku Limon, MD. Department of Retina, University of Health Sciences Umraniye Training and Research Hospital Eye Clinic, Istanbul, Türkiye

**Phone:** +90 506 848 71 90 **E-mail:** utku\_limon@hotmail.com

**Submitted Date:** February 26, 2022 **Revised Date:** May 21, 2022 **Accepted Date:** June 23, 2022 **Available Online Date:** November 15, 2022

*Beyoglu Eye Training and Research Hospital - Available online at [www.beyoglueye.com](http://www.beyoglueye.com)*

**OPEN ACCESS** This is an open access article under the CC BY-NC license (<http://creativecommons.org/licenses/by-nc/4.0/>).



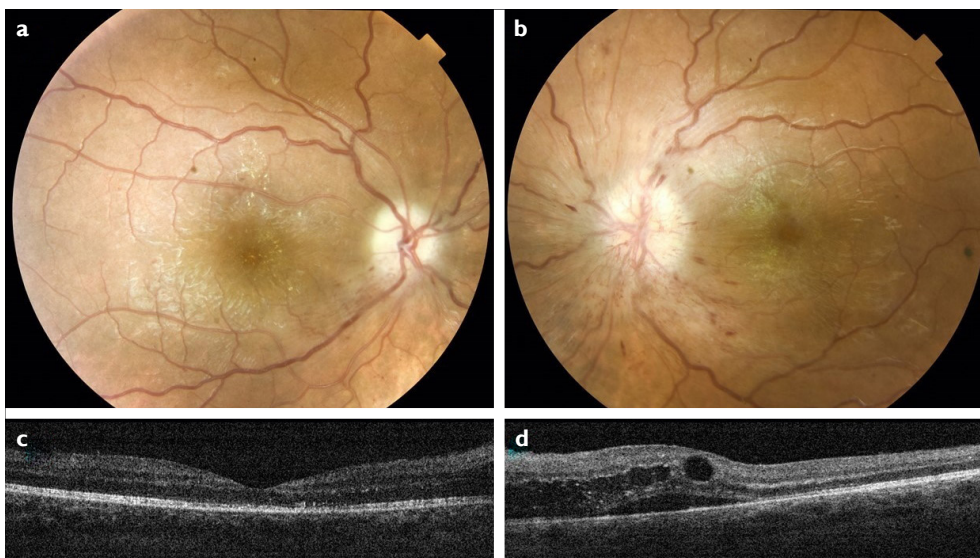
hemorrhages in the lower part of the optic disk. In the left fundus examination, the optic disk was swollen, and superficial telangiectatic vessels were extending from the optic disk to the peripapillary retina. In both eyes, there were small peripapillary splinter hemorrhages and telangiectatic vessels in the mid-peripheral retina.

In optical coherence tomography (OCT), the macula was normal in the right eye, but the intraretinal and subretinal fluid was present in the left eye (Fig. 1). OCT revealed bilateral increase in the retinal nerve fiber layer (RNFL) thickness (average right 153.26 $\mu$ m and average left 186.69 $\mu$ m). In fundus fluorescein angiography (FFA), there was early hyperfluorescence and late dye leakage from the telangiectatic vessels extending from the optic disk to the retina in both eyes. Furthermore, there was early hyperfluorescence in the peripheral retina from telangiectatic vessels in both eyes. There were several microaneurysms in the posterior pole and mid-periphery in both eyes (Non-proliferative diabetic retinopathy). The foveal avascular zone was slightly enlarged in both eyes. There was late hyperfluorescence in the fovea due to macular edema in the left eye. At the same time, there were ischemic areas in the peripheral retina in both eyes (Fig. 2). There was no abnormal fundus autofluorescence on the disk. Humphrey's central 30-2 visual field test was abnormal in both eyes (Fig. 3).

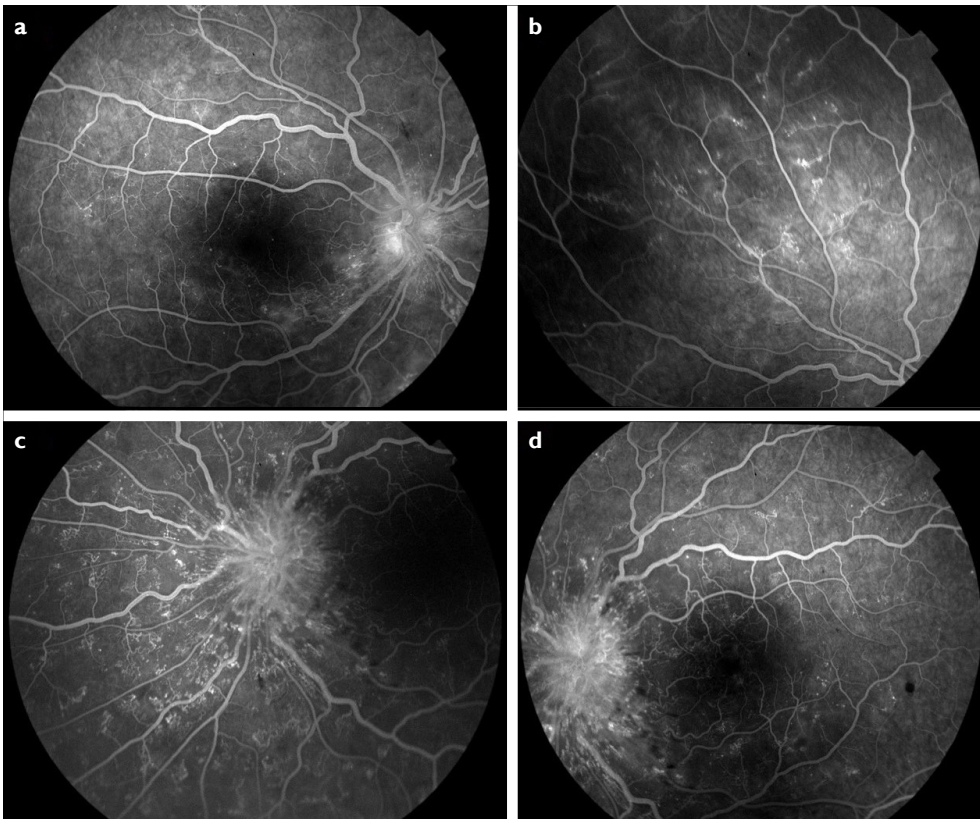
She had been diagnosed with type 1 diabetes 10 years ago and had been using insulin for 10 years. At systemic exam-

ination, blood pressure was 210/124 mmHg, serum glucose level was 485 mg/dl, and serum glycated hemoglobin level was 14.0%. Serum erythrocyte sedimentation rate was 17 mm/h and C-reactive protein was 1 mg/dl (both were within normal limits). Neurological examination was normal. In lumbar puncture, cerebrospinal fluid (CSF) pressure was normal (12 cm). Remarkable cerebral, orbital, or abdominal pathologies were not detected in venous MR angiography, contrast-enhanced cranial MR, orbital MR, and abdominal MR. Laboratory tests for inflammation and infection showed no abnormalities. Renal ultrasonography revealed grade 1 nephropathy. Serum creatinine level was within the normal range.

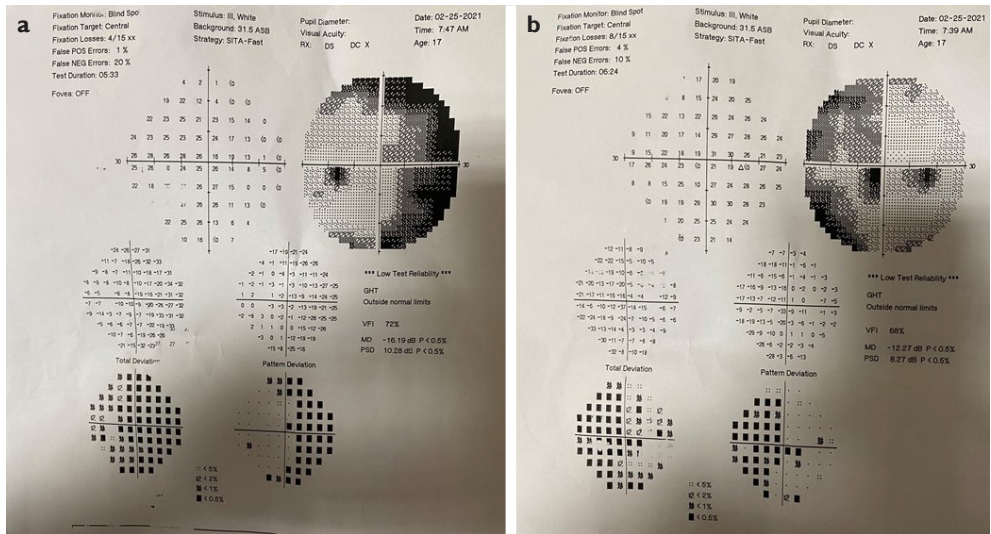
The patient was diagnosed with hypertensive papillopathy based on clinical, funduscopic, and systemic examination. Systemic blood glucose levels and hypertension were regulated by the Pediatric Clinic. Papillopathy, macular edema, and telangiectasis in both eyes disappeared within 10 days without ocular treatment. Both optic disks were pale at the end of 6 months of follow-up (Fig. 4). All the telangiectatic vessels and hyperfluorescent areas in the FFA disappeared in both eyes. In FFA in both eyes, there was an enlarged foveal avascular zone, a small amount of microaneurysm in the posterior pole, and focal ischemic areas with a small number of telangiectatic vessels in the peripheral retina (Fig. 5). Average RNFL thickness had decreased to 99.97  $\mu$ m in the right eye and 98.32  $\mu$ m in the left eye. BCVAs were 0.5 in the right eye and 0.3 in the left eye. Informed consent was obtained.



**Figure 1.** Images were taken at the initial visit (BCVA was 0.2 in the right eye and 0.05 in the left eye) (a) Color fundus photograph of the right eye. The optic disk is pale and slightly swollen. There are telangiectatic vessels and splinter hemorrhages in the lower part of the optic disk. (b) Color fundus photograph of the left eye. The optic disk is swollen and superficial telangiectatic vessels and splinter hemorrhages are extending from the optic disk to the peripapillary retina. (c) Optical coherence tomography (OCT) imaging of the right eye. The macula is normal. (d) OCT imaging of the left eye. There is intraretinal and subretinal fluid.



**Figure 2.** Fundus fluorescein angiography (FFA) images at the initial visit. **(a)** FFA image of the right eye shows hyperfluorescence at the optic disk and inferior retina. There are several microaneurysms in the posterior pole. **(b)** There are telangiectatic vessels in the upper retina of the right eye. **(c)** FFA image of the left eye shows hyperfluorescence at the optic disk. There are telangiectatic vessels in the nasal retina. **(d)** FFA image of the left eye shows hyperfluorescence at the optic disk. There are several microaneurysms in the posterior pole.

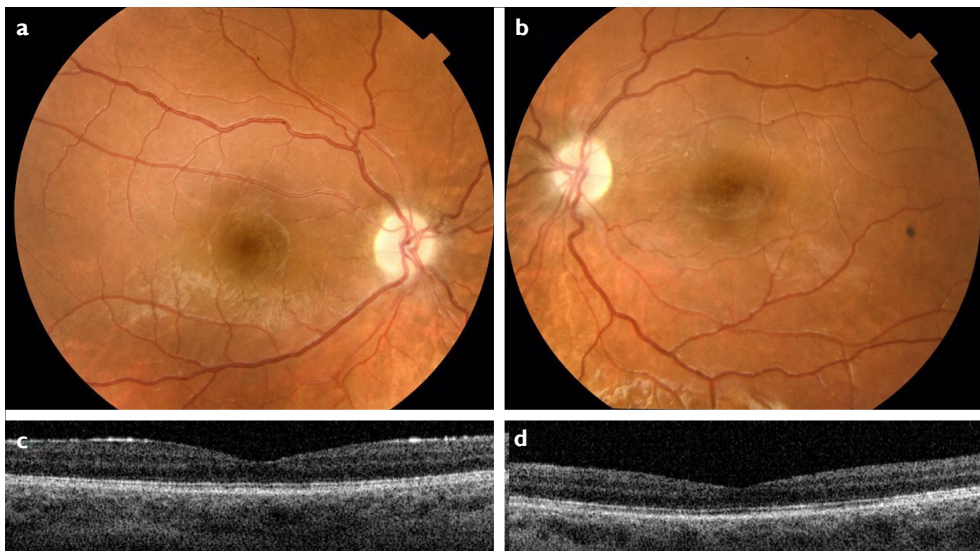


**Figure 3.** Humphrey's central 30–2 visual field images of both eyes at the initial visit. **(a, b)** There are peripheral visual field defects in both eyes.

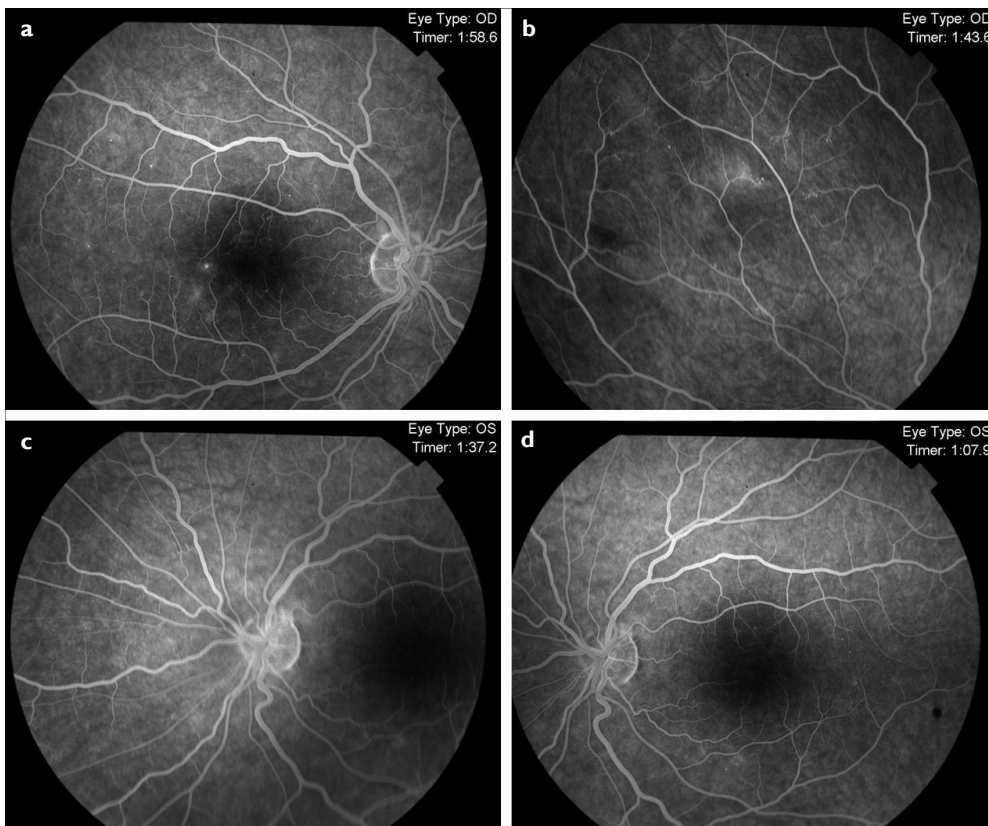
**Discussion**

The eye is one of the target organs damaged by hypertension. Systemic hypertension can cause vision loss by causing

retinopathy, choroidopathy, and optic neuropathy (3). Many causes of optic disk edema must be excluded before the diagnosis of hypertensive papilledema.



**Figure 4.** Fundus fluorescein angiography (FFA) images at 6<sup>th</sup> month. **(a)** There are several microaneurysms in the posterior pole of the right eye. **(b)** Telangiectatic vessels in the upper retina have disappeared. Ischemia and several microaneurysms are seen in the upper retina. **(c)** Telangiectatic vessels in the nasal retina have disappeared. **(d)** There are several microaneurysms in the posterior pole of the left eye.



**Figure 5.** Images were taken in the 6<sup>th</sup> month (BCVA was 20/40 in the right eye and 20/63 in the left eye) **(a, b)** color fundus photograph of the right and left eye. All telangiectatic vessels and splinter hemorrhages have disappeared. **(c, d)** OCT imaging of the right and left eye is normal.

Diabetic papillopathy can be seen in both mild and severe diabetic retinopathy (4). In many cases in the literature, visual acuity increased after papillary edema resolved. Macular

edema without capillary leakage often accompanies and is the main cause of vision loss in patients with diabetic papillopathy (5). Our patient had mild diabetic retinopathy, whereas, in our

case, there was a limited increase in visual acuity in both eyes after resolution of macular edema and papilloedema. Therefore, we excluded the diagnosis of diabetic papillopathy.

The most important differential diagnosis for bilateral papillary edema is IIH. CSF pressure is high in IIH (6). However, in our case, CSF pressure and neurological examination were normal. Another important disease that should be considered in the differential diagnosis is NA-AION. According to some authors, while diabetic papillopathy is a mild form of NA-AION, it is a different disease for others. In NA-AION, unilateral, sudden, and profound vision loss often develops (7). However, in contrast to NA-AION, our case has mild vision loss and there were no NA-AION findings such as choroidal filling defects, or segmental hypofluorescence of the optic disk in FFA. In addition, there was no afferent pupillary defect and altitudinal visual field defect, which are common in NA-AION. At the same time, the age of the patient excludes the diagnosis of NA-AION.

In addition, infectious, inflammatory, and infiltrative causes that may cause optic disk edema should be excluded from the study (8). In our case, laboratory markers for these reasons were normal. Papilledema must also be distinguished from pseudopapilledema such as optic disk drusen with fundus autofluorescence imaging (9).

Papilledema may develop within days or weeks after blood pressure elevation and regresses within days or months after blood pressure normalization. In our case, retinopathy, telangiectatic disk, and retinal vessels regressed after systemic hypertension and diabetes regulation within 10 days. However, both of the optic disks remained pale.

## Conclusion

Bilateral hypertensive papillopathy may be accompanied by diffuse retinal telangiectasis. It should be considered in the differential diagnosis of optic disk edema.

## Disclosures

**Informed consent:** Written informed consent was obtained from the patient for the publication of the case report and the accompanying images.

**Peer-review:** Externally peer-reviewed.

**Conflict of Interest:** None declared.

**Authorship Contributions:** Concept: U.L.; Design: U.L.; Supervision: U.L.; Data collection and/or processing: U.L.; Analysis and/or interpretation: U.L.; Literature search: U.L.D.; Writing: U.L.; Critical reviews: B.İ., S.A.

## References

1. Lagrèze WA. Differential papilledema diagnosis. *Ophthalmologie* 2001;98:417–31.
2. Tsukikawa M, Stacey AW. A review of hypertensive retinopathy and chorioretinopathy. *Clin Optom (Auck)* 2020;12:67–73.
3. Bourke K, Patel MR, Prisant LM, Marcus DM. Hypertensive choroidopathy. *J Clin Hypertens (Greenwich)* 2004;6:471–2.
4. Yildirim M, Kilic D, Dursun ME, Dursun B. Diabetic papillopathy treated with intravitreal ranibizumab. *Int Med Case Rep J* 2017;10:99–103.
5. Bayraktar Z, Alacali N, Bayraktar S. Diabetic papillopathy in Type II diabetic patients. *Retina* 2002;22:752–8.
6. Nichani P, Micieli JA. Retinal manifestations of idiopathic intracranial hypertension. *Ophthalmol Retina* 2021;5:429–37.
7. Tarantini A, Faraoni A, Menchini F, Lanzetta P. Bilateral simultaneous nonarteritic anterior ischemic optic neuropathy after ingestion of sildenafil for erectile dysfunction. *Case Rep Med* 2012;2012:747658.
8. Kale N. Optic neuritis as an early sign of multiple sclerosis. *Eye Brain* 2016;8:195–202.
9. Chawla R, Nair S, Venkatesh P, Garg S, Mittal K. Bilateral disc drusen in a diabetic patient simulating diabetic papillopathy as a cause of disc edema. *Indian J Ophthalmol* 2017;65:1051–3.