




Since January 2020 Elsevier has created a COVID-19 resource centre with free information in English and Mandarin on the novel coronavirus COVID-19. The COVID-19 resource centre is hosted on Elsevier Connect, the company's public news and information website.

Elsevier hereby grants permission to make all its COVID-19-related research that is available on the COVID-19 resource centre - including this research content - immediately available in PubMed Central and other publicly funded repositories, such as the WHO COVID database with rights for unrestricted research re-use and analyses in any form or by any means with acknowledgement of the original source. These permissions are granted for free by Elsevier for as long as the COVID-19 resource centre remains active.



Case Reports and Series

Thrombocytopenia and pneumonitis associated with BNT16B2b2 mRNA COVID-19 vaccine: A case report

Yuichi Kojima^{a,b,*}, Kimihiro Takeyabu^a, Miki Satoh^a, Satoshi Konno^b

^a Department of Respiratory Medicine, Otaru Kyokai Hospital, 1-6-15 Suminoe, Otaru, Hokkaido, Japan

^b Department of Respiratory Medicine, Faculty of Medicine and Graduate School of Medicine, Hokkaido University, North 15 West 7, Kita-ku, Sapporo 060-8638, Japan

ARTICLE INFO

Keywords

BNT16B2b2 mRNA vaccine
 COVID-19 vaccination
 Behçet's disease
 Vaccine adverse effects

ABSTRACT

An 80-year-old Japanese male patient with Behçet's disease presented with a seven-day history of fever, cough, and progressive shortness of breath after receiving a second dose of the BNT16B2b2 mRNA COVID-19 vaccine (Pfizer-BioNTech). The initial diagnosis was community-acquired pneumonia, and antibiotic treatment was started but proved ineffective. Twenty days after onset, his platelet count was significantly decreased. We suspected vaccine-induced pneumonitis and thrombocytopenia. After administration of prednisolone and intravenous immunoglobulin, and platelet transfusions, his platelet count normalized. The pneumonia symptoms improved three weeks after onset. Herein, we also summarize previous reports of cases of pneumonitis and thrombocytopenia associated with SARS-CoV-2 vaccination.

Introduction

Accumulated case reports have revealed several adverse effects of severe acute respiratory syndrome coronavirus 2 (SARS-CoV-2) vaccination. Although thrombocytopenia is relatively common, vaccination-induced pneumonitis is rare, with only five cases reported to date (Yoshifuji et al., 2022; Park et al., 2022; Farooq et al., 2022; So et al., 2022). Here we report the case of a patient who developed thrombocytopenia and pneumonitis concurrently after receiving a SARS-CoV-2 vaccine. We also summarize previous cases of pneumonitis and thrombocytopenia associated with SARS-CoV-2 vaccination.

Case report

An 80-year-old Japanese man presented to our hospital with a seven-day history of fever, cough, and progressive shortness of breath. His medical history included a diagnosis of hypertension (controlled with amlodipine and olmesartan) and Behçet's disease 30 years prior. Because his Behçet's disease was in remission, he had not received treatment in over a decade. He was not taking any other medications or supplements. Family history revealed that a sibling had died from Behçet's disease. The patient had a smoking history of 30 packs per year and had quit smoking at 50 years of age. His body mass index was 23 kg/m². Seven days after receiving the first dose of the BNT16B2b2 mRNA

COVID-19 vaccine (Pfizer-BioNTech), he developed chills that persisted for a week, leading him to visit his family hospital. At the hospital, he was febrile (38 °C) and had a high C-reactive protein level (CRP 158.0 mg/L; reference ≤ 1.4 mg/L). However, his body temperature and CRP levels decreased later, and a second dose of the vaccine was administered three weeks after the first. The day after receiving the second dose, he developed fever (37.8 °C) and showed low peripheral oxygen saturation levels (85 % in room air). Laboratory tests showed elevated white blood cell (18.0×10^9 /L; reference $3.9\text{--}9.8 \times 10^9$ /L) and platelet counts (569.0×10^9 /L; reference $130\text{--}369 \times 10^9$ /L) and high levels of CRP (172.0 mg/L) and D-dimer (3.8 $\mu\text{g/mL}$; reference ≤ 1.0 $\mu\text{g/mL}$). Computed tomography (CT) images showed an area of consolidation with air bronchograms in the right upper lung, ground-glass opacities near the pleura of the left lung, and enlarged mediastinal lymph nodes (Fig. 1). There were no findings suggesting pulmonary hemorrhage, edema, malignancy, or other diseases with similar imaging findings; hence, pneumonia was the most likely cause.

We made a presumptive diagnosis of community-acquired pneumonia and started empirical treatment with ceftriaxone (2 g/day). Due to the lack of response, we switched to levofloxacin and tazobactam/piperacillin on the fourth day after admission. However, his fever did not decrease and his blood cell count and CRP levels remained high. Blood and sputum cultures were negative. Although bronchoalveolar lavage (BAL) was scheduled for day 13 after admission (21 days after the

* Corresponding author.

E-mail address: yul.kozima@frontier.hokudai.ac.jp (Y. Kojima).

<https://doi.org/10.1016/j.clinpr.2022.100204>

Received 28 May 2022; Received in revised form 26 September 2022; Accepted 27 September 2022

Available online 5 October 2022

2590-1702/© 2022 The Authors. Published by Elsevier Ltd on behalf of British Infection Association. This is an open access article under the CC BY-NC-ND license (<http://creativecommons.org/licenses/by-nc-nd/4.0/>).

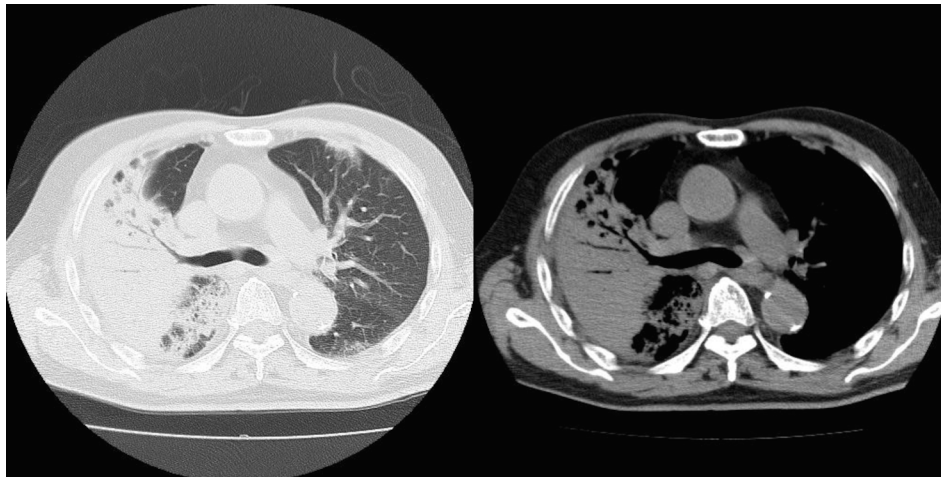


Fig. 1. Computed tomography (CT) images show an area of consolidation with air bronchogram in the right upper lung, ground-glass opacity in the left lung, and enlarged mediastinal lymph nodes.

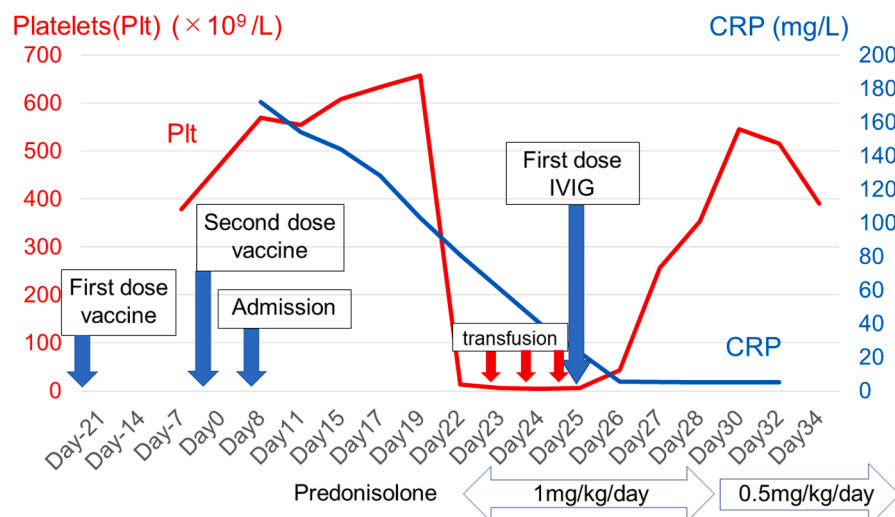


Fig. 2. Platelet count (red line) and C-reactive protein (CRP) levels (blue line) in the course of the patient's treatment. Relevant timepoints in the clinical case and treatment doses are indicated by arrows. IVIG: intravenous immunoglobulin. (For interpretation of the references to colour in this figure legend, the reader is referred to the web version of this article.)

second dose of the vaccine), the patient exhibited a significant reduction in platelet count ($13 \times 10^9/L$) on that date, and the procedure was not performed. At this point, blood tests showed elevated levels of IgG (28.3 g/L; reference 8.7–17.0 g/L), IgA (7.0 g/L; reference 1.1–4.1 g/L), and D-dimer (1.8 $\mu\text{g/mL}$). Contrast-enhanced CT did not reveal any thrombus. We suspected that both the pneumonitis and thrombocytopenia might have been caused by SARS-CoV-2 vaccination, and prednisolone treatment (1 mg/kg/day) together with platelet transfusions for three consecutive days was initiated. Administration of intravenous immunoglobulin (IVIG) was also initiated at a dose of 0.4 mg/kg/day for five consecutive days. His platelet count returned to normal five days after the initiation of therapy. Eight days after treatment initiation, the prednisolone dose was reduced to 0.5 mg/kg/day, and then gradually tapered off (Fig. 2).

On CT images obtained three weeks after symptoms onset, the pneumonia had improved and lymph node enlargement had resolved. Since the completion of steroid tapering, the patient has been doing well and has shown no signs of relapse but continues to be followed up carefully.

Discussion and literature review

With the increase in the administration of SARS-CoV-2 vaccines worldwide, several adverse reactions have been reported. Vaccination-induced pneumonitis seems to be rare, and to the best of our knowledge, only five cases have been reported so far (Table 1) (Yoshifuji et al., 2022; Park et al., 2022; Farooq et al., 2022; So et al., 2022). In three cases, pneumonitis appeared within a few days after administration of the second dose, and patients experienced fever, cough, and dyspnea. CT imaging showed subpleural ground-glass opacities and consolidations in both lungs. In two cases, BAL revealed an elevated level of lymphocytes, and pathological examination showed alveolitis with lymphocyte infiltration in one case. The clinical course seemed to be satisfactory, and the patients responded well to steroid therapy. Of note, four cases were from Asian countries (Japan and Korea), which suggests potential ethnic differences in susceptibility to lung injury by SARS-CoV-2 vaccination, as has been reported for drug-induced pneumonia (Kudoh et al., 2008).

In the current case, we did not perform lung biopsy due to the patient's severe thrombocytopenia. Therefore, we were unable to obtain a pathological diagnosis. However, the poor response to antibiotics and negative bacterial cultures from sputum and blood made an infectious

Table 1
Case series and reports describing COVID-19 vaccine-induced pneumonitis.

Author, Month Year, Country	Age, Sex Comorbidity	Vaccine types	Symptoms	Onset day from vaccination	Treatment	CT findings	BAL findings
Yoshifuji et al. (Yoshifuji et al., 2022) September 2021, Japan	60 M HT, ACO	BNT162b2 mRNA COVID-19 vaccine (second shot)	Dyspnea	Second day	Steroid pulse	GGO with right upper lobe predominance, mild interlobar septal wall thickening, and diffuse bronchial wall thickening.	46.9 % macrophages, 31.3 % lymphocytes, 21.9 % neutrophils N/A
Park et al. (Park et al., 2022) August 2021, South Korea	86 M HT, DM, CKD	BNT162b2 mRNA COVID-19 vaccine (second shot)	Weakness, dyspnea, fever	First day	Steroid	Bilateral diffuse GGO with focal consolidations, centrilobular micronodules and lobular septal thickening	N/A
Farooq et al. ³ January 2022, UK	62 M	ChAdOx1 nCoV-19 (second shot)	Dyspnea, weakness.	N/A	Steroid pulse	Diffuse and patchy GGO. Peripheral consolidation with tractional bronchiolar dilatation.	N/A
So et al. (So et al., 2022) February 2022, Japan	67 M HT, DM 70 M	BNT162b2 mRNA COVID-19 vaccine (first shot) BNT162b2 mRNA COVID-19 vaccine (first shot)	Dry cough. Dyspnea	First day Second day	Steroid Steroid	Diffuse GGO with reticular opacities. N/A	33.0 % macrophages, 29.0 % lymphocytes, 35.0 % neutrophils N/A

ACO, asthma and chronic obstructive pulmonary disease overlap; BAL, bronchoalveolar lavage; CKD, chronic kidney disease; CT, computed tomography; DM, diabetes mellitus; GGO, ground glass opacity; HT, hypertension.

Table 2
Case series and reports describing vaccine-induced thrombocytopenia without thrombosis.

Author.	Age, Sex	Vaccine types	Number of times vaccinated	Onset day from vaccination	Treatment	Clinical outcome
Month Year, Country	Comorbidity					
Malayala et al (Malayala et al., 2021)	60 M	mRNA-1273	First	Second day	N/A	–
March 2021, USA	Hepatitis C	COVID-19 vaccine				
Chittal et al (Chittal et al., 2021)	34F	mRNA-1273	Second	Third day	Steroid	–
November 2021, USA	subclinical hypothyroidism	COVID-19 vaccine				
Vaira et al (Vaira et al., 2021)	81 M	BNT16B2b2 COVID-19 vaccine	Second	Third day	Steroid	–
July 2021, Italy	CKD, DL	mRNA-1273	First	A few hours	IVIG, steroid,	–
Helms et al (Helms et al., 2021)	74 M	COVID-19 vaccine				
April 2021, UK	HT, HL	COVID-19 vaccine			rituximab	
Thaler et al (Thaler et al., 2021)	62F	ChAdOx1 nCoV-19	First	First day	IVIG, steroid	–
July 2021, Austria						
Akiyama et al (Akiyama et al., 2021)	20F	BNT16B2b2 COVID-19 vaccine	First	12th day	Steroid	–
August 2021, Japan						
Razzaq et al (Razzaq et al., 2021)	26 M	ChAdOx1 nCoV-19	N/A	Second day	IVIG, steroid	–
July 2021, Iraq	34F	ChAdOx1 nCoV-19	First	Seventh day	N/A	Death
Wiedmann et al (Wiedmann et al., 2021)						(intracranial hemorrhage)
July 2021, Norway						
Idogun et al (Idogun et al., 2021)	54F	BNT16B2b2 COVID-19 vaccine	Second	Seventh day	IVIG, steroid	–
May 2021, USA						
Qasim et al (Qasim et al., 2021)	28 M	BNT16B2b2 COVID-19 vaccine	Second	Second day	IVIG, steroid	–
November 2021, Qatar						
Lavin et al (Lavin et al., 2021)	29F	ChAdOx1 nCoV-19	N/A	Seventh day	IVIG	Unknown
June 2021, Ireland	35F	ChAdOx1 nCoV-19	N/A	10th day	N/A	Unknown

CKD, chronic kidney disease; DL, dyslipidemia; HT, hypertension; IVIG, intravenous immunoglobulin; UK, United Kingdom; USA, United States of America.

bacterial etiology unlikely. On CT imaging, the lesion appeared to be regional in the early days after admission but gradually progressed to extensive ground-glass opacities in the left lung and consolidation with air bronchograms in the right lung, which suggested an organizing pneumonia (OP) pattern. In addition, symptoms, CRP levels, and CT imaging improved after steroid therapy was initiated. Overall, we speculate that this was vaccine-induced pneumonitis.

Remarkably, in three of the previously reported cases, pneumonia developed only after administration of the second vaccine dose (Yoshifuji et al., 2022; Park et al., 2022; Farooq et al., 2022). However, in the present case, the patient already developed a strong inflammatory response after the first dose (as indicated by the fever and high CRP levels). Although no imaging tests were performed at the time, this suggests that pneumonia might have already been present at that point.

In contrast to pneumonia, many cases of thrombocytopenia without thrombosis associated with SARS-CoV-2 vaccines have been reported (Table 2) (Malayala et al., 2021; Chittal et al., 2021; Vaira et al., 2021; Helms et al., 2021; Thaler et al., 2021; Akiyama et al., 2021; Razzaq et al., 2021; Wiedmann et al., 2021; Idogun et al., 2021; Qasim et al., 2021; Lavin et al., 2021). Symptoms developed within a week of first-dose administration. In most cases, patients were treated with steroids and/or IVIG, and the treatment efficacy was satisfactory. There have also been some reports of thrombocytopenia with thrombosis or

bleeding, with high mortality and poor response to steroid therapy.

In the present case, the co-occurrence of pneumonitis and thrombocytopenia might have been coincidental; however, abnormalities in the immune system resulting from Behçet's disease might also provide an explanation (Nakamura et al., 2016; Kushima et al., 2021). Thus, careful management and follow-up are needed when patients with immunologic conditions are vaccinated against SARS-CoV-2.

Conclusion

In summary, we report a case of thrombocytopenia and pneumonitis after inoculation of the BNT16B2b2 mRNA vaccine in a patient with Behçet's disease. Careful consideration of case reports on the adverse effects of vaccination is important for the appropriate management of patients with COVID-19 worldwide in the ongoing pandemic.

Declaration of Competing Interest

The authors declare that they have no known competing financial interests or personal relationships that could have appeared to influence the work reported in this paper.

Acknowledgements

Funding: This research did not receive any specific grant from funding agencies in the public, commercial, or not-for-profit sectors.

References

- Akiyama, H., Kakiuchi, S., Rikitake, J., Matsuba, H., Sekinada, D., Kozuki, Y., Iwata, N., 2021. Immune thrombocytopenia associated with Pfizer-BioNTech's BNT162b2 mRNA COVID-19 vaccine. *IDCases*. 25, e01245.
- Chittal, A., Rao, S., Lakra, P., Nacu, N., Haas, C., 2021. A Case of COVID-19 Vaccine-induced thrombotic thrombocytopenia. *J. Community Hosp. Intern. Med. Perspect*. 11, 776–778. <https://doi.org/10.1080/20009666.2021.1980966>.
- Farooq, M., Mohammed, Y., Zafar, M., Dharmasena, D., Rana, U.I., Kankam, O., 2022. COVID-19 vaccine-induced pneumonitis, myositis and myopericarditis. *Cureus* 14, e20979. <https://doi.org/10.7759/cureus.20979>.
- Helms, J.M., Ansteatt, K.T., Roberts, J.C., Kamatam, S., Foong, K.S., Jo-mel, S.L., et al., 2021. Tarantino, Severe, refractory immune thrombocytopenia occurring after SARS-CoV-2 vaccine. *J. Blood Med.* 12, 221–224. <https://doi.org/10.2147/JBM.S307047>.
- Idogun, P.O., Ward, M.C., Teklie, Y., Wiese-Rometsch, W., Baker, J., 2021. Newly diagnosed idiopathic thrombocytopenia post COVID-19 vaccine administration. *Cureus* 13, e14853.
- Kudoh, S., Kato, H., Nishiwaki, Y., Fukuoka, M., Nakata, K., Ichinose, Y., Tsuboi, M., Yokota, S., Nakagawa, K., Suga, M., Jiang, H., Itoh, Y., Armour, A., Watkins, C., Higenbottam, T., Nyberg, F., 2008. Interstitial lung disease in Japanese patients with lung cancer: a cohort and nested case-control study. *Am. J. Respir. Crit. Care Med.* 177 (12), 1348–1357.
- Kushima, H., Kinoshita, Y., Watanabe, K., Takamatsu, Y., Ishii, H., 2021. Association of immune thrombocytopenia and interstitial pneumonia. *Int. Med.* 58, 3083–3086. <https://doi.org/10.2169/internalmedicine.2664-19>.
- Lavin, M., Elder, P.T., O'Keefe, D., Enright, H., Ryan, E., Kelly, A., El Hassadi, E., McNicholl, F.P., Benson, G., Le, G.N., Byrne, M., Ryan, K., O'Connell, N.M., O'Donnell, J.S., 2021. Vaccine-induced immune thrombotic thrombocytopenia (VITT) - a novel clinico-pathological entity with heterogeneous clinical presentations. *Br. J. Haematol.* 195 (1), 76–84.
- Malayala, S.V., Mohan, G., Vasireddy, D., Atluri, P., 2021. Purpuric rash and thrombocytopenia after the mRNA-1273 (Moderna) COVID-19 vaccine. *Cureus* 13, e14099.
- Nakamura, A., Miyamura, T., Wu, B., Suematsu, E., 2016. Recurrent interstitial pneumonitis in a patient with wntero-Behçet's disease initially treated with mesalazine. *Case Rep. Rheumatol.* 5636489 <https://doi.org/10.1155/2016/5636489>.
- Park, J.Y., Kim, J.-H., Lee, I.J., Kim, H.I., Park, S., Hwang, Y.I., Jang, S.H., Jung, K.-S., 2022. COVID-19 vaccine-related interstitial lung disease: a case study. *Thorax*. 77 (1), 102–104.
- Qasim, H., Ali, E., Yassin, M.A., 2021. Immune thrombocytopenia relapse post covid-19 vaccine in young male patient. *IDCases* 26, e01344.
- Razzaq, A.K., Al-Jasim, A., Piccaluga, P.P., 2021. Oxford-AstraZeneca Coronavirus disease-2019 vaccine-induced immune thrombocytopenia on day two. *Case Rep Hematol.* 2021, 1–3.
- So, C., Izumi, S., Ishida, A., Hirakawa, R., Kusaba, Y., Hashimoto, M., et al., 2022. COVID-19 mRNA vaccine-related interstitial lung disease: Two case reports and literature review. *Respirol Case Rep.* 10, e0938.
- Thaler, J., Ay, C., Gleixner, K.V., Hauswirth, A.W., Cacioppo, F., Grafeneder, J., Quehenberger, P., Pabinger, I., Knöbl, P., 2021. Successful treatment of vaccine-induced prothrombotic immune thrombocytopenia (VIPIT). *J Thromb Haemost.* 19 (7), 1819–1822.
- Vaira, L.A., Podda, L., Doneddu, P., Careddu, M.G., Fozza, C., De Riu, G., 2021. Secondary thrombocytopenia after SARS-CoV-2 vaccine: Report of a case of hemorrhage and hematoma after minor oral surgery. *J. Stomatol. Oral Maxillofac Surg.* 123, 95–97. <https://doi.org/10.1016/j.jormas.2021.07.010>.
- Wiedmann, M., Skattør, T., Stray-Pedersen, A., Romundstad, L., Antal, E.-A., Marthinsen, P.B., Sørvoll, I.H., Leiknes Ernsten, S., Lund, C.G., Holme, P.A., Johansen, T.O., Brunborg, C., Aamodt, A.H., Schultz, N.H., Skagen, K., Skjelland, M., 2021. Vaccine induced immune thrombotic thrombocytopenia causing a severe form of cerebral venous thrombosis with high fatality rate: a case series. *Front Neurol.* 12, 721146 <https://doi.org/10.3389/fneur.2021.721146>.
- Yoshifuji, A., Ishioka, K., Masuzawa, Y., Suda, S., Murata, S., Uwamino, Y., Fujino, M., Miyahara, H., Hasegawa, N., Ryuzaki, M., Hoshino, H., Sekine, K., 2022. COVID-19 vaccine induced interstitial lung disease. *J. Infect. Chemother.* 28 (1), 95–98.