

# Micro-reentry right atrial tachycardia originating from fossa ovalis: a case report of high-density mapping by PentaRay catheter

Jin-Yi Li <sup>1\*</sup>, Xiang-Wei Lv <sup>2</sup>, Guo-Qiang Zhong <sup>1</sup>, and Hong-Hong Ke<sup>1</sup>

<sup>1</sup>Department of Cardiology, The First Affiliated Hospital of Guangxi Medical University, No. 6 Shuangyong Road, Nanning City, 530021 Nanning, China; and <sup>2</sup>Department of Cardiology, The First Affiliated Hospital of Guilin Medical College, No. 15 Lequn Road, Guilin City, 541001 Guilin, China

Received 16 February 2019; first decision 18 April 2019; accepted 21 August 2019; online publish-ahead-of-print 31 August 2019

## Background

Micro-reentry tachycardia usually emerges in scar tissues related to post-atrial fibrillation ablation and cardiomyopathy. It is difficult to identify the micro-reentry circuit accurately by conventional mapping method.

## Case summary

A 74-year-old man presented with paroxysmal atrial tachycardia (AT) presenting as palpitations. He was evaluated by an electrophysiological examination using a high-density CARTO mapping system. The mapping results showed the AT with a cycle length of 184 ms was focused on his right atrial fossa ovalis (FO). In this small area, the high-density mapping demonstrated a significant micro-reentrant tachycardia. Radiofrequency ablation at the centre of the micro-reentrant circuit successfully terminated the AT. No recurrences were observed during a 12-month follow-up.

## Discussion

This case demonstrated a micro-reentrant AT originates from the FO without cardiomyopathy or previous ablation with specific loops. This is an unusual location for AT though and can cause difficulty for operators if it terminates or is non-sustained. High-density mapping using a PentaRay catheter can effectively characterize micro-reentrant circuits and determine the real target for ablation therapy.

## Keywords

Atrial tachycardia • Micro-reentry • Fossa ovalis • Mapping • PentaRay catheter • Case report

## Learning points

- A micro-reentry atrial tachycardia (AT) can originate from non-scar tissue.
- A high-density mapping by PentaRay catheter can effectively characterize the micro-reentry circuits of AT and reveal the real target for ablation therapy.

## Introduction

Micro-reentrant tachycardia is usually found in scarred tissue or in patients who have undergone previous catheter ablation.<sup>1–4</sup> Most focal atrial tachycardia (AT) from non-scar regions arose from either the crista terminalis or tricuspid annulus. The crista terminalis has long been appreciated as a ‘ring of fire’.<sup>5</sup> Furthermore, due to the small size of the re-entrant circuit and the poor spatial resolution of mapping by using a single electrode catheter and point-by-point

\* Corresponding author. Tel: +86 07715356618, Email: 17834968@qq.com

Handling Editor: Ross Hunter

Peer-reviewers: Philipp Sommer and Habib Khan

Compliance Editor: Rahul Mukherjee

Supplementary Material Editor: Peregrine Green

© The Author(s) 2019. Published by Oxford University Press on behalf of the European Society of Cardiology.

This is an Open Access article distributed under the terms of the Creative Commons Attribution Non-Commercial License (<http://creativecommons.org/licenses/by-nc/4.0/>), which permits non-commercial re-use, distribution, and reproduction in any medium, provided the original work is properly cited. For commercial re-use, please contact [journals.permissions@oup.com](mailto:journals.permissions@oup.com)

mapping, it is difficult to accurately identify the 'isthmus', 'external', and 'internal' loops and then to distinguish micro-reentrant tachycardia from non-reentrant focal tachycardia. In this report, we first describe a patient with micro-reentrant AT originating from the fossa ovalis (FO) without cardiomyopathy or previous ablation, which was mapped using a PentaRay catheter with high-density mapping.

## Timeline

6 months before presentation	He suffered from repeated palpitations. Then, atrial tachycardia (AT) was documented.
At presentation	He was admitted to undergo radiofrequency catheter ablation (RFCA) of AT.
During procedure	Atrial tachycardia was mapped throughout the procedure by high-density mapping and then was identified as a micro-reentry tachycardia at the right atrial fossa ovalis (FO). Finally, the AT was successfully treated by RFCA without any complications.
After the RFCA	Electrocardiogram examination after the RFCA showed a normal morphology.
Follow-up at 12 months	He has remained well without any arrhythmias.

## Case presentation

A 74-year-old previously healthy man was referred to our institution for repeated palpitations over 6 months. A Holter electrocardiogram (ECG) from the local hospital showed persistent AT. No oral antiarrhythmia drugs were prescribed. The initial workup included baseline ECG, routine blood tests, chest X-ray, echocardiogram, and coronary angiography. There was frequent unifocal initiating AT with a P-wave morphology of positive amplitude in I, II, III, aVF, and V<sub>1</sub> (Figure 1A).

The patient underwent an electrophysiological study and ablation. Endocardial mapping of the atrium was performed using a PentaRay catheter (Biosense Webster, Inc., CA, USA) and a smart-touch contact force (CF)-sensing catheter (Biosense Webster, Inc., CA, USA) with the CARTO mapping system (Carto, Biosense Webster). Spontaneous AT was identified and mapped throughout the procedure using activation mapping, voltage mapping, and ripple mapping. Intracardiac electrophysiology during AT [cycle length (CL) 184 ms] showed atrial signals with an eccentric pattern of atrial activation on the coronary sinus catheter (Figure 1C). Further activation mapping showed the earliest activation zone of AT originated in the right atrial FO. Ripple mapping showed activation progressing from the FO to both the right atrium and left atrium (Figure 1B and Supplementary material online, Video S1). Voltage mapping revealed no low-voltage regions in either atrium (Figure 1D).

In the FO, further high-density mapping (HDM) using the PentaRay catheter and point-to-point mapping using the CF-sensing catheter (Biosense Webster, Inc., CA, USA) demonstrated significantly long-

duration fractionated electrograms covering a considerable percentage of the CL of the tachycardia within a localized region (Figure 2C and D). About 107 points at 12 cm<sup>2</sup> were taken for the map. The colours of the wavefront on the activation maps can be tracked by following the regions where red meets purple (Figure 2A and B). Concealed entrainment was fulfilled only at the FO, which implied the tachycardia mechanism is micro-reentrant in nature.

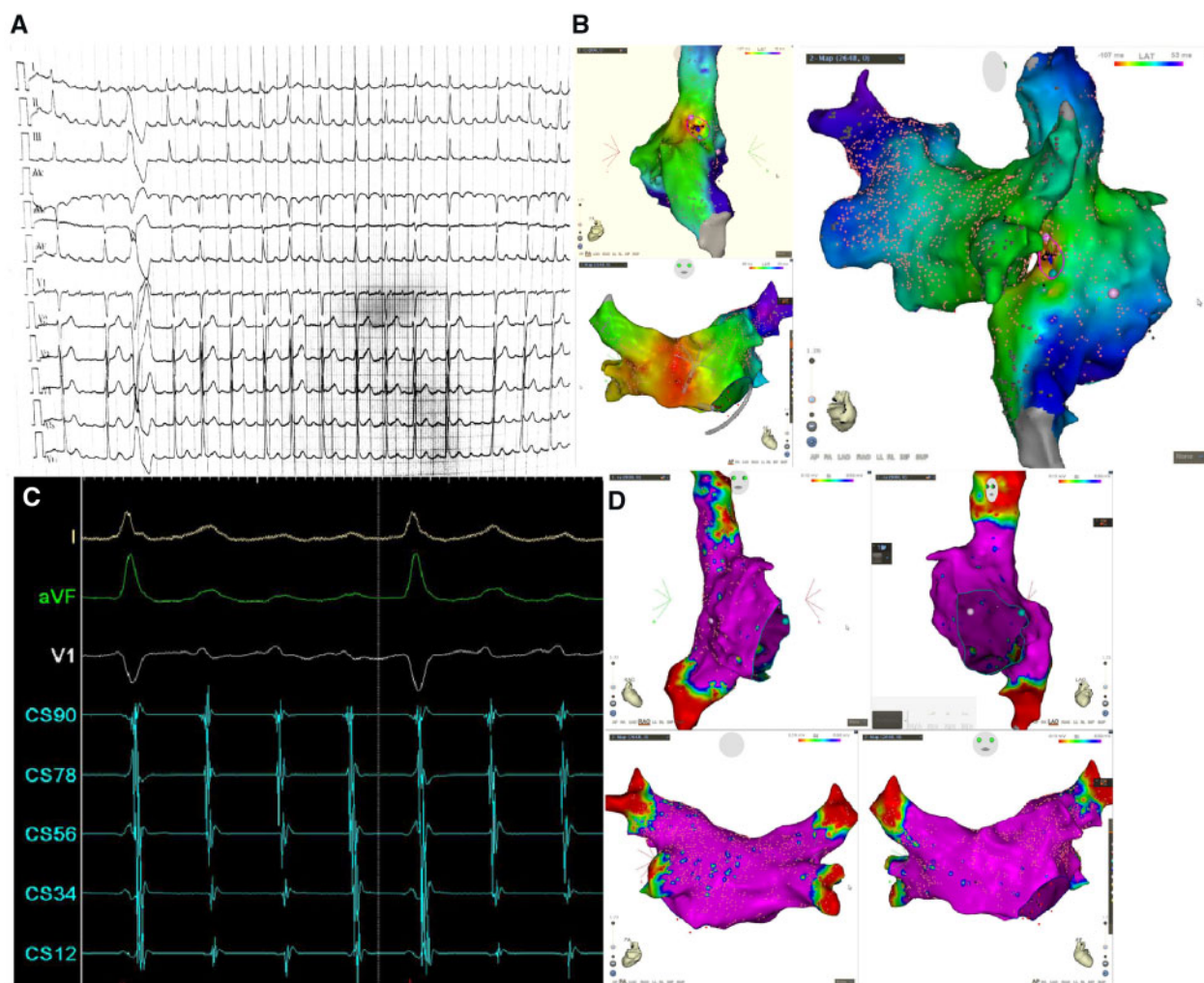
A radiofrequency catheter ablation (RFCA) current was delivered at 30 W in power-controlled mode at 43°C and a normal saline velocity of 17 mL per minutes. The RFCA was delivered to the middle of the micro-reentrant circuit, terminating the AT immediately after 3 s (Supplementary material online, Video S2). No AT was induced during programme stimulation and isoproterenol infusion (10 µg/min). The patient had no further episodes of AT over the ensuing 12 months until he was discharged to his home without antiarrhythmic drugs.

## Discussion

We first described a case of micro-reentry AT originating from the FO without cardiomyopathy or previous ablation using a PentaRay catheter with high-density mapping. This case is novel as it involves *de novo* AT without clear cause. A possible mechanism is remodelling and fibrosis supporting AT, even in patients without other evidence of cardiomyopathy or previous ablation. Likewise, the FO is often a low voltage zone. This is an unusual location for AT though and can cause difficulty for operators if it terminates or is non-sustained. Atrial tachycardia occurs in up to 30–50% of patients with previous atrial fibrillation (AF) ablation.<sup>6</sup> As much as 75% of post-AF ablation AT is macro-reentrant in nature. The remaining 25% of cases are focal AT, resulting from triggered activity or enhanced automaticity and micro-reentrant tachycardias.<sup>7</sup> Atrial tachycardia due to micro-reentry was defined as AT that was inducible with programmed stimulation, showed electrogram fractionation [ $\geq 35\%$  of tachycardia cycle length (TCL)] at a focal site of successful ablation, and had  $\geq 75\%$  of TCL mapped.<sup>8</sup> The electrophysiological data of this case indicated that the AT mechanism was micro-reentrant. The re-entry circuit was small and could not be identified as the 'isthmus', 'external', or 'internal' loops.<sup>9</sup> Entrainment mapping can be used to differentiate micro-reentry tachycardia from true focal tachycardia.<sup>1</sup> Micro-reentry circuits usually occur at sites of gaps of ablation.<sup>1</sup> Mapping made with PentaRay can identify heterogeneity within areas of low voltage, localize channels of surviving bundles, record higher bipolar voltage amplitude with shorter electrogram duration and allow accurate time annotation.<sup>10</sup> The present case shows that micro-reentrant AT can originate from the special zone such as FO without cardiomyopathy or previous ablation. The high-density maps using the PentaRay can effectively reveal a small re-entrant circuit.

## Conclusions

A micro-reentry AT can originate from non-scar tissue. A high-density mapping by PentaRay catheter can effectively characterize the micro-reentry circuits of AT and reveal the real target for ablation therapy.



**Figure 1** Atrial tachycardia with a P-wave morphology of positive amplitude in I, II, III, aVF, and V1 (A). Ripple mapping showed activation progressing from the fossa ovalis to both the right atrium and left atrium (B). Intracardiac electrophysiology during atrial tachycardia (cycle length 184 ms) showed atrial signals with proximal-to-distal activation on the coronary sinus catheter (C). Voltage mapping revealed no low-voltage regions in either atrium (D).

## Lead author biography



Jin-Yi Li, born in 1981, now working in the Department of Cardiology, the First Affiliated Hospital of Guangxi Medical University. He graduated from Guangxi Medical University in 2009 with a doctorate in medicine. His specialty is clinical electrophysiology. He studied in the Heart Rhythm Institute of University of Oklahoma Health Science Center (USA) as a visiting scholar from January to June 2019.

## Supplementary material

**Supplementary material** is available at *European Heart Journal - Case Reports* online.

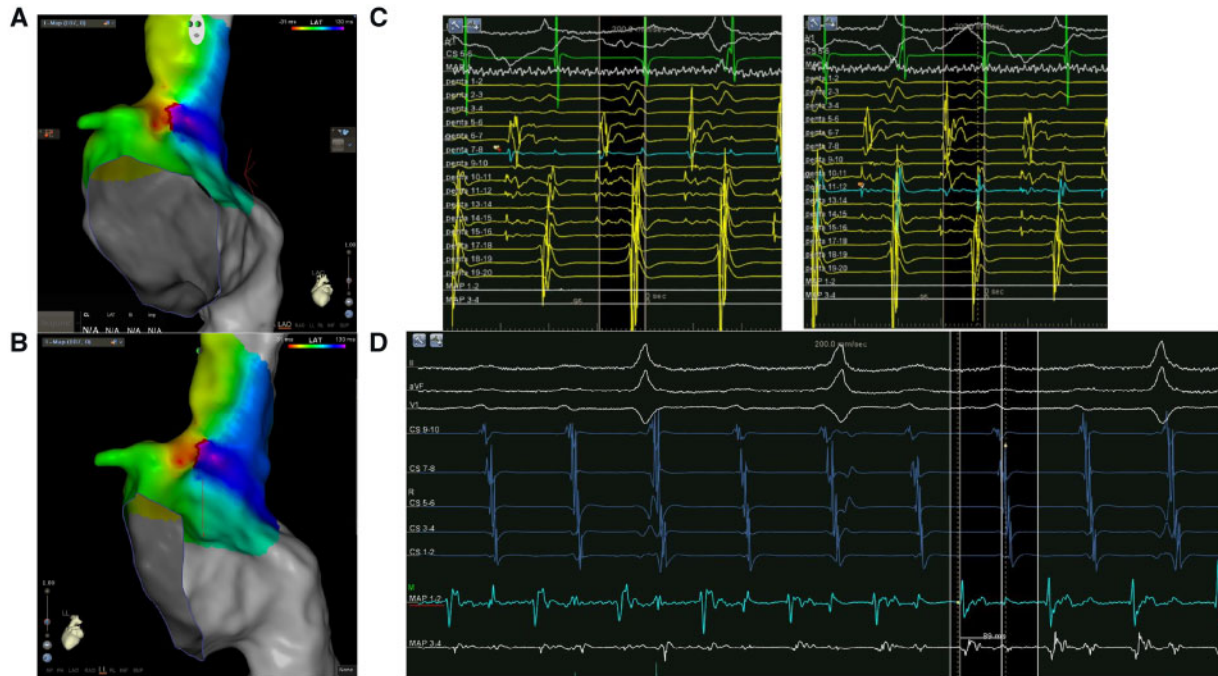
**Slide sets:** A fully edited slide set detailing this case and suitable for local presentation is available online as **Supplementary data**.

**Consent:** The author/s confirm that written consent for submission and publication of this case report including image(s) and associated text has been obtained from the patient in line with COPE guidance.

**Conflict of interest:** none declared.

## References

1. Ng FS, Guerrero F, Luther V, Sikkil M, Lim PB. Microreentrant left atrial tachycardia circuit mapped with an ultra-high-density mapping system. *Heart Rhythm Case Rep* 2017;**3**:224–228.



**Figure 2** In the fossa ovalis, the colours of the wavefront on further activation maps with high-density mapping using the PentaRay catheter and the contact force-sensing catheter can be tracked by following the regions where red meets purple (A and B). The local electrogram of the earliest activation site during the tachycardia exhibited significantly long-duration fractionated electrograms covering a considerable percentage of the cycle length of the tachycardia within a localized region (C and D).

2. Ali H, Foresti S, Cappato R. Small reentry in a mega coronary sinus: anatomical and high-density activation mapping. *J Cardiovasc Electrophysiol* 2017;**28**: 1086–1087.
3. Oliveira RS, Alonso S, Campos FO, Rocha BM, Fernandes JF, Kuehne T, dos Santos RW. Ectopic beats arise from microreentries near infarct regions in simulations of a patient-specific heart model. *Sci Rep* 2018;**8**:16392.
4. Pokushalov E, Turov A, Shugayev P, Artyomenko S, Shirokova N. Successful epicardial catheter ablation of micro-reentrant ventricular tachycardia in a 14-year-old child. *Pediatr Cardiol* 2009;**30**:533–535.
5. Iwai S, Markowitz SM, Stein KM, Mittal S, Slotwiner DJ, Das MK, Cohen JD, Hao SC, Lerman BB. Response to adenosine differentiates focal from macroreentrant atrial tachycardia: validation using three-dimensional electroanatomic mapping. *Circulation* 2002;**106**:2793–2799.
6. Morady F, Oral H, Chugh A. Diagnosis and ablation of atypical atrial tachycardia and flutter complicating atrial fibrillation ablation. *Heart Rhythm* 2009;**6**:S29–S32.
7. Chae S, Oral H, Good E, Dey S, Wimmer A, Crawford T, Wells D, Sarrazin J-F, Chalfoun N, Kuhne M, Fortino J, Huether E, Lemerand T, Pelosi F, Bogun F, Morady F, Chugh A. Atrial tachycardia after circumferential pulmonary vein ablation of atrial fibrillation: mechanistic insights, results of catheter ablation, and risk factors for recurrence. *J Am Coll Cardiol* 2007;**50**:1781–1787.
8. Liu CF, Cheung JW, Ip JE, Thomas G, Yang H, Sharma S, Markowitz SM, Lerman BB. Unifying algorithm for mechanistic diagnosis of atrial tachycardia. *Circ Arrhythm Electrophysiol* 2016;**9**:e004028.
9. Stevenson WG, Khan H, Sager P, Saxon LA, Middlekauff HR, Natterson PD, Wiener I. Identification of reentry circuit sites during catheter mapping and RF ablation of VT late after myocardial infarction. *Circulation* 1993;**88**: 1647–1670.
10. Anter E, Tschabrunn CM, Josephson ME. High-resolution mapping of scar-related atrial arrhythmias using smaller electrodes with closer interelectrode spacing. *Circ Arrhythm Electrophysiol* 2015;**8**:537–545.