

Lumbar epidural depth using transverse ultrasound scan and its correlation with loss of resistance technique: A prospective observational study in Indian population

ABSTRACT

Background and Objectives: The objective of the present study was to evaluate the skin-epidural space distance as assessed by ultrasonography and conventional loss of resistance (LOR) technique and to find the correlation of epidural depth with body mass index (BMI).

Methods: Ninety-eight patients of either sex, American Society of Anesthesiology I/II, BMI <30 kg/m² requiring lumbar epidural for surgery were enrolled. The epidural space was assessed with a curvilinear ultrasound (US) probe, 2–5 MHz, in the transverse plane at L3–L4 intervertebral space. Thereafter, the epidural depth from skin was assessed with conventional LOR method while performing the epidural. The needle depth (ND) was measured using a sterile linear scale, and any change in the needle direction or intervertebral space was noted.

Results: The patients were demographically similar. Depth of epidural space measured by US depth (UD) was 3.96 ± 0.44 cm (range 3.18–5.44 cm) and by ND was 4.04 ± 0.52 cm (range 2.7–5.7 cm). The Pearson's correlation coefficient (r) between UD and ND was 0.935 (95% confidence interval: 0.72–0.92, $r^2 = 0.874$, $P < 0.001$), and Bland–Altman analysis revealed the 95% limits of agreement –0.494–0.652 cm.

Conclusion: The present study demonstrates a good correlation between UD and ND and shows that the preprocedural US scan in transverse plane provides accurate needle entry site with a high success rate in single attempt for lumbar epidurals in patients with a BMI <30 kg/m².

Key words: Lumbar epidural; needle depth; transverse plane; ultrasound; ultrasound depth

Introduction

Ultrasound (US) guidance for regional anesthesia has gained popularity as it is easily performed and provides opportunity to confirm the landmarks and deposit the local anesthetic at correct place besides associated improved safety and decreased rate of complications.^[1] Millions of

neuraxial blocks are performed as a blind, tactile procedure because of its simplicity and traditional method of learning all over the world and the use of US for central neuraxial blocks – epidural or spinal – is still lagging behind.^[1,2] Recently, there has been considerable interest in the use of

This is an open access article distributed under the terms of the Creative Commons Attribution-NonCommercial-ShareAlike 3.0 License, which allows others to remix, tweak, and build upon the work non-commercially, as long as the author is credited and the new creations are licensed under the identical terms.

For reprints contact: reprints@medknow.com

How to cite this article: Chauhan AK, Bhatia R, Agrawal S. Lumbar epidural depth using transverse ultrasound scan and its correlation with loss of resistance technique: A prospective observational study in Indian population. Saudi J Anaesth 2018;12:279-82.

Access this article online

Website: www.saudija.org	Quick Response Code 
DOI: 10.4103/sja.SJA_679_17	

AMIT KUMAR CHAUHAN, ROHAN BHATIA, SANJAY AGRAWAL¹

Department of Anaesthesia, Himalayan Institute of Medical Sciences, Dehradun, Uttarakhand, ¹Department of anaesthesia, AIIMS, Bhopal, Madhya Pradesh, India

Address for correspondence: Dr. Rohan Bhatia, Department of Anaesthesia, Himalayan Institute of Medical Sciences, Dehradun, Uttarakhand, India. E-mail: rohan_bhatia789@rediffmail.com

ultrasonography for lumbosacral regional anesthesia, and it has been proposed as a preoperative assessment tool for neuraxial blockade.^[3,4]

Neuraxial US guidance is increasingly used for real-time neuraxial blockade and interventions in rheumatology practice such as steroid epidural injections due to the better resolution provided by recent improvements in US technology. The US guidance can sometimes be challenging, especially in old and obese patients.^[5,6] Lumbar epidural catheterizations are commonly used to access the epidural space and failure can result in the loss of diagnostic information, inability to deliver treatment, or inadequate analgesia.^[7,8] Studies have shown that loss of resistance (LOR) technique can result in inaccurate needle placement in up to 30% of lumbar epidural blocks.^[9] This occurs because of the high variability of the distance between the skin and the epidural space and its surface anatomical references which can hinder correct identification of the space.^[10] This inaccuracy can increase the risk of nerve injuries, paresthesia, hematoma formation, and multiple injection attempts leading to chances of postdural puncture headache.^[11] With this background information, we planned a prospective observational study to evaluate the skin-epidural space distance as assessed by US depth (UD) versus conventional LOR technique needle depth (ND) and its correlation with body mass index (BMI) <30 kg/m² in patients listed for surgery under lumbar epidural anesthesia.

Methods

This prospective observational study was conducted after approval from the Institutional Ethics Committee (SRHU/HIMS/ETHICS/2017/126), and written informed consent was obtained from the patients listed for surgery under lumbar epidural anesthesia. A total of 100 patients of either sex, 20–45 years of age, American Society of Anesthesiology Grade I/II and with a BMI of 18.5–29.9 kg/m² were included in the study. Patient refusal for epidural anesthesia, history of neurological diseases, previous spinal surgery, deformities of the spine, infection at the puncture site, coagulopathies, and any other contraindication to neuraxial block were excluded from this study. Pregnant patients and patients with BMI >30 kg/m² were also excluded from the study. All patients were kept nil per orally for 6 h for solid foods and 2 h for clear liquids. In the operating room, intravenous access was established in nondominant hand and patients were preloaded with ringer lactate 10 ml/kg. Intraoperative monitoring included blood pressure, oxygen saturation, temperature, and electrocardiography. The epidural procedure was performed with patient in the sitting position after cleaning the skin with 6% chlorhexidine antiseptic

solutions, and the area was draped with sterile sheet. US imaging of the spine was performed in transverse axial plane at the level of L3–L4 intervertebral space by a trained anesthesiologist using 2–5 Mhz curved array C5-2 US probe (Portable Philips clear value 350 and 550 US system Philips US, 22100 Bothell Everett Highway, Bothell WA 98021-8431 USA). The spinous process, corresponding to the midline of the vertebrae, was identified as a small hyperechoic (bright) signal, immediately underneath the skin overlying, a long triangular hypoechoic (dark) acoustic shadow. The US probe was moved cephalad or caudal to capture a view of the upper or lower intervertebral space in an acoustic window identifying the ligamentum flavum–dura mater complex as posterior complex (PC) and posterior longitudinal ligament-vertebral body as anterior complex (AC). The best possible image was captured with the PC and the AC as midline structures, which produced a hyperechoic “=” sign in the middle of the interspace. At this time, the US probe was positioned perpendicular to the long axis of the lumbar spine in transverse plane. The ligamentum flavum–dura mater complex PC was used as a reference, as opposed to the ligamentum flavum and the dura mater separately. The depth of epidural space was noted by built-in caliper of US from the skin to the inner surface of the ligamentum flavum–dura mater complex or PC [Figure 1].

The point of insertion of Tuohy epidural needle was marked on the skin corresponding to intersection of lines coinciding with the center of the upper horizontal surface of the probe (midline) and midpoint of the right lateral vertical surface of the probe. The needle was introduced at the predetermined insertion point obtained by US. Epidural space localization was done with conventional LOR method by another anesthesiologist, who was unaware of US epidural

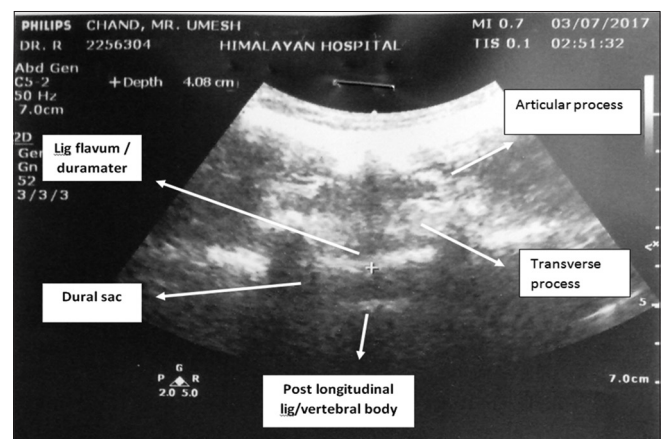


Figure 1: Transverse plane-axial view: Midline hyperechoic structures represent the upper ligamentum flavum–dura unit posterior complex and lower posterior longitudinal ligament-vertebral body anterior complex; bilateral symmetrical hyperechoic structures indicate articular and transverse processes with their acoustic shadows

depth. The ND was measured using a sterile linear scale after administration of local anesthetic agent. Any change in the direction of needle or change of intervertebral space was also noted.

Sample size calculation was done utilizing tests of association using bivariate correlations, and a good correlation between UD and ND was considered meaningful with reference to previous studies.^[10,12,13] Therefore, assuming the correlation of 90% with 95% confidence interval (CI), a sample size of 71 cases was required with 7% precision of error. However, in our study, we included a total of 100 cases to compensate for any dropout patients. Descriptive statistics were analyzed with SPSS version 17.0 software (Inc, Chicago, IL, USA). Continuous variables were presented as mean ± standard deviation while categorical variables were expressed as frequencies and percentages. The Pearson's Chi-square test or Chi-square test of association was used to determine relationship between two categorical variables. The Pearson's coefficient correlation between UD and ND was performed. Linear regression model was used to identify the coefficient of determination of UD to predict ND. Bland–Altman plot was also made to show the agreement between two depths. $P < 0.05$ was considered statistically significant.

Results

A total of 100 patients fulfilling the eligibility criteria were included in the study of which 98 completed the study. Two patients were excluded from study as they refused for epidural anesthesia. The demographic profile of the patients is depicted in Table 1. Distribution of patients as per surgical procedures was general surgery (2%), obstetrics and gynecology (26%), orthopedics (28%), and urology (42%). Out of 98 patients, 63 (64.3%) patients were in normal weight range between 18.5 and 24.9 kg/m², and 35 (35.7%) were in overweight range, i.e., between 25 and 29.9 kg/m². The UD was 3.96 ± 0.44 cm whereas the ND was 4.04 ± 0.52; the mean difference ± standard error of mean between the measurements was statistically not significant – 0.079 ± 0.068 cm, 95% CI: –0.214–0.056, $P = 0.250$). The Pearson's correlation coefficient (r) between the UD and the ND was 0.935 (95% CI: 0.72–0.92, $r^2 = 0.874$, $P < 0.001$) and the graphical representation of UD versus ND shows that the best-fit line deviates little from the perfect agreement [Figure 2] while Bland–Altman analysis revealed the 95% limits of agreement were –0.494–0.652 cm [Figure 3].

We found a correlation coefficient of $r = 0.955$, $P < 0.001$ between UD and ND in 35 (35.7%) overweight patients with BMI range 25–29.9 kg/m², which showed a good correlation

between UD and ND [Table 2]. We found that the epidural needle placement was done without any reinsertions in 80 (81.6%) patients whereas 18 (18.4%) patients required 2 or more than 2 needle insertion attempts. These 18 patients were with BMI 25.72 ± 2.32 kg/m², i.e., they were in the overweight range.

Discussion

Our study demonstrates a good agreement of epidural depth determination between US and the conventional LOR technique ND. Obesity obscures the anatomical landmarks

Table 1: Demographic profile of patients

Characteristic	Mean±SD	Range
Patients' age (year)	37.32±7.68	20-45
Height (cm)	162.99±6.87	146-177
Weight (kg)	64.22±8.65	45-85
BMI (kg/m ²)	24.05±2.58	18.97-29.51
UD (cm)	3.96±0.44	3.18-5.44
ND (cm)	4.04±0.52	2.70-5.7

BMI: Body mass index; UD: Ultrasound depth; ND: Needle depth; SD: Standard deviation

Table 2: Agreement between ultrasound depth and needle depth

	BMI	Coefficient r
BMI ($n=98$) - 18.5-29.9 kg/m ²	Pearson's correlation coefficient (r)	0.935
	95% CI	0.72-0.92
	P	<0.001
BMI ($n=63$) - 18.5-24.9 kg/m ²	Pearson's correlation coefficient (r)	0.869
	95% CI	0.611-0.819
	P	<0.001
BMI ($n=35$) - 25-29.9 kg/m ²	Pearson's correlation coefficient (r)	0.955
	95% CI	0.727-0.908
	P	<0.001

n : Number of patients. CI: Confidence interval; BMI: Body mass index

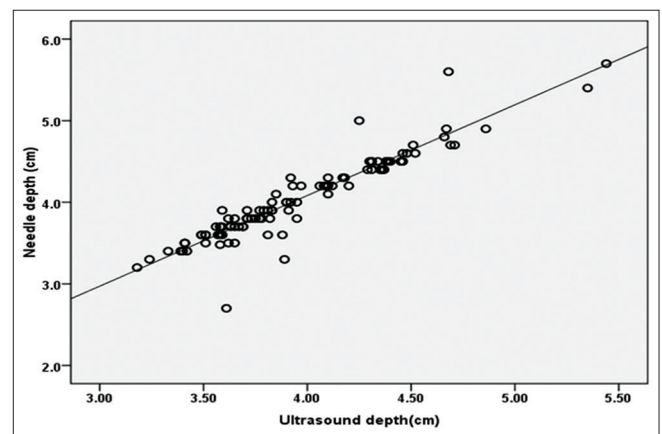


Figure 2: Overall agreement between ultrasound depth and needle depth in cm

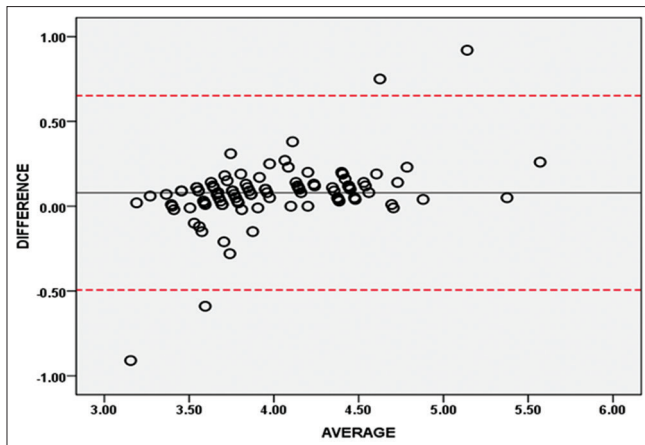


Figure 3: Bland–Altman analysis; agreement between ultrasound depth in cm and needle depth in cm. The upper 95% confidence limit was 0.652 cm, and the lower limit was – 0.494 cm

necessary for tactile epidural space localization. The presence of adipose tissue may increase the false-positive rate when identifying the epidural space by the loss-of-resistance technique. The combination of these factors accounts for a higher incidence of technical difficulty, more puncture attempts, a higher rate of needle reangulation, and complications. We found a good correlation in between UD and ND, in both normal as well as overweight patients, and US proved to be a good tool for preprocedural epidural space evaluation irrespective of the patients' BMI. Previous studies have also demonstrated a correlation between the distance from the skin to the lumbar epidural space with the BMI in a mixed population consisting of obese and nonobese parturients.^[8,10,12-14] Our results, involving normal and overweight patients, are consistent with those studies.

In our study, a few complications were also seen in overweight patients, 4 (4.1%) had hemorrhagic tap, and 2 (2.0%) patients had dural tap. The overall correlation of procedure complications in relation to BMI was not significant $P = 0.133$.

The limitations of this study were not including the patients with BMI >30 kg/m² and parturients. Moreover, we have only used preprocedural US evaluation instead of real-time guidance for the epidural.

Conclusion

The use of preprocedural US imaging in transverse plane provides accurate puncture site, higher success rate, and

decrease in attempts for lumbar epidurals. Our study shows a good correlation between UD and actual ND in Indian patients with BMI <30 kg/m².

Financial support and sponsorship

Nil.

Conflicts of interest

There are no conflicts of interest.

References

1. Teissler HH, Lozano C, Plavsic KS. The use of ultrasonography for the guidance of epidural analgesia in obstetric anesthesia. *Donald Sch J Ultrasound Obstet Gynecol* 2014;8:44-51.
2. Reynolds F. Damage to the conus medullaris following spinal anaesthesia. *Anaesthesia* 2001;56:238-47.
3. Provenzano DA, Narouze S. Sonographically guided lumbar spine procedures. *J Ultrasound Med* 2013;32:1109-16.
4. Chin KJ, Chan V. Ultrasonography as a preoperative assessment tool: Predicting the feasibility of central neuraxial blockade. *Anesth Analg* 2010;110:252-3.
5. Shankar H. Ultrasound-guided steroid injection for obturator neuralgia. *Pain Pract* 2008;8:320-3.
6. Darrieutort-Laffite C, Bart G, Planche L, Glemarec J, Maugars Y, Le Goff B, *et al.* Usefulness of a pre-procedure ultrasound scanning of the lumbar spine before epidural injection in patients with a presumed difficult puncture: A randomized controlled trial. *Joint Bone Spine* 2015;82:356-61.
7. Shaikh F, Brzezinski J, Alexander S, Arzola C, Carvalho JC, Beyene J, *et al.* Ultrasound imaging for lumbar punctures and epidural catheterisations: Systematic review and meta-analysis. *BMJ* 2013;346:f1720.
8. Shah KH, Richard KM, Nicholas S, Edlow JA. Incidence of traumatic lumbar puncture. *Acad Emerg Med* 2003;10:151-4.
9. Pak MH, Lee WH, Ko YK, So SY, Kim HJ. Ultrasonographic measurement of the ligamentum flavum depth; is it a reliable method to distinguish true and false loss of resistance? *Korean J Pain* 2012;25:99-104.
10. Helayel PE, da Conceição DB, Meurer G, Swarovsky C, de Oliveira Filho GR. Evaluating the depth of the epidural space with the use of ultrasound. *Braz J Anesthesiol* 2010;60:376-82.
11. de Filho GR, Gomes HP, da Fonseca MH, Hoffman JC, Pederneiras SG, Garcia JH, *et al.* Predictors of successful neuraxial block: A prospective study. *Eur J Anaesthesiol* 2002;19:447-51.
12. Arzola C, Davies S, Rofaeel A, Carvalho JC. Ultrasound using the transverse approach to the lumbar spine provides reliable landmarks for labor epidurals. *Anesth Analg* 2007;104:1188-92.
13. Balki M, Lee Y, Halpern S, Carvalho JC. Ultrasound imaging of the lumbar spine in the transverse plane: The correlation between estimated and actual depth to the epidural space in obese parturients. *Anesth Analg* 2009;108:1876-81.
14. Gnaho A, Nguyen V, Villevielle T, Frota M, Marret E, Gentili ME, *et al.* Assessing the depth of the subarachnoid space by ultrasound. *Rev Bras Anesthesiol* 2012;62:520-30.