



# The right atrium in young patients with type 1 diabetes mellitus: Insights from the three-dimensional speckle-tracking echocardiographic MAGYAR-Path Study<sup>☆</sup>

Attila Nemes<sup>\*</sup>, Árpád Kormányos, Zoltán Ruzsa, Tamás Várkonyi, Csaba Lengyel

Department of Medicine, Albert Szent-Györgyi Medical School, University of Szeged, Szeged, Hungary

## ARTICLE INFO

### Keywords:

Echocardiography  
Right atrium  
Three-dimensional  
Speckle-tracking  
Type 1 diabetes mellitus

## ABSTRACT

**Introduction:** Early onset of cardiomyopathy represented by myocardial volumetric and deformation properties is a major concern for patients with type 1 diabetes mellitus (T1DM). Three-dimensional (3D) speckle-tracking echocardiography (3DSTE) is a novel methodology with capability of 3D assessment of the right atrium (RA) via virtual models. The present study was designed for detailed comparative analysis of T1DM-associated RA volumetric and functional abnormalities to those of matched healthy controls to be examined by 3DSTE.

**Methods:** The present study comprised of 17 patients with typical features of T1DM (mean age:  $36.4 \pm 13.0$  years, 59% males). Their results were compared to those of 31 age- and gender-matched healthy controls (mean age:  $35.0 \pm 2.9$  years, 61% males).

**Results:** 3DSTE-derived RA volumes respecting the cardiac cycle and RA stroke volumes and emptying fractions did not show differences between young T1DM patients and matched controls. From peak RA strains representing RA reservoir function, mean segmental RA 3D strain proved to be significantly increased. Some regional basal/midatrial end-systolic peak RA strains were found to be significantly increased as well in T1DM patients as compared to controls. T1DM duration and HbA1c correlated with certain RA strains and RA volume-based functional properties.

**Conclusions:** In young patients with T1DM, preserved RA volumes respecting the cardiac cycle are accompanied with increase in certain regional end-systolic peak RA strains, which seems to be associated with T1DM duration and HbA1c.

## 1. Introduction

Early onset of cardiomyopathy represented by myocardial volumetric and deformation properties is a major concern for patients with type 1 diabetes mellitus (T1DM). Abnormalities in myocardial mechanics could be demonstrated featuring heart chambers in young patients with T1DM [1–7]. The right atrium (RA), however, was poorly examined due to its limited availability for routine echocardiographic techniques [8,9]. Three-dimensional (3D) speckle-tracking echocardiography (STE) is a novel methodology with capability of 3D assessment of RA via virtual models [10–14]. In recent 3DSTE studies, disease-specific alterations were found in RA features [15]. Therefore, the

present study was designed for detailed comparative analysis of T1DM-associated RA volumetric and functional abnormalities to those of matched healthy controls to be examined by 3DSTE.

## 2. Materials and methods

### 2.1. Study population

The present study comprised of 17 patients with typical features of T1DM (mean age:  $36.4 \pm 13.0$  years, 59% males, duration of T1DM:  $16.9 \pm 11.9$  years, HbA1c:  $34.9 \pm 1.1\%$ ). All patients were treated with subcutaneous insulin pump with a daily insulin dose of  $38.9 \pm 7.8$  IU.

<sup>☆</sup> This author takes responsibility for all aspects of the reliability and freedom from bias of the data presented and their discussed interpretation. registration no: 71/2011

<sup>\*</sup> Corresponding author at: Department of Medicine, Albert Szent-Györgyi Medical School, University of Szeged, H-6725 Szeged, Semmelweis street 8 P.O. Box 427, Hungary.

E-mail address: [nemes.attila@med.u-szeged.hu](mailto:nemes.attila@med.u-szeged.hu) (A. Nemes).

<https://doi.org/10.1016/j.ijcha.2022.101064>

Received 25 March 2022; Received in revised form 9 May 2022; Accepted 23 May 2022

2352-9067/© 2022 The Authors. Published by Elsevier B.V. This is an open access article under the CC BY-NC-ND license (<http://creativecommons.org/licenses/by-nc-nd/4.0/>).

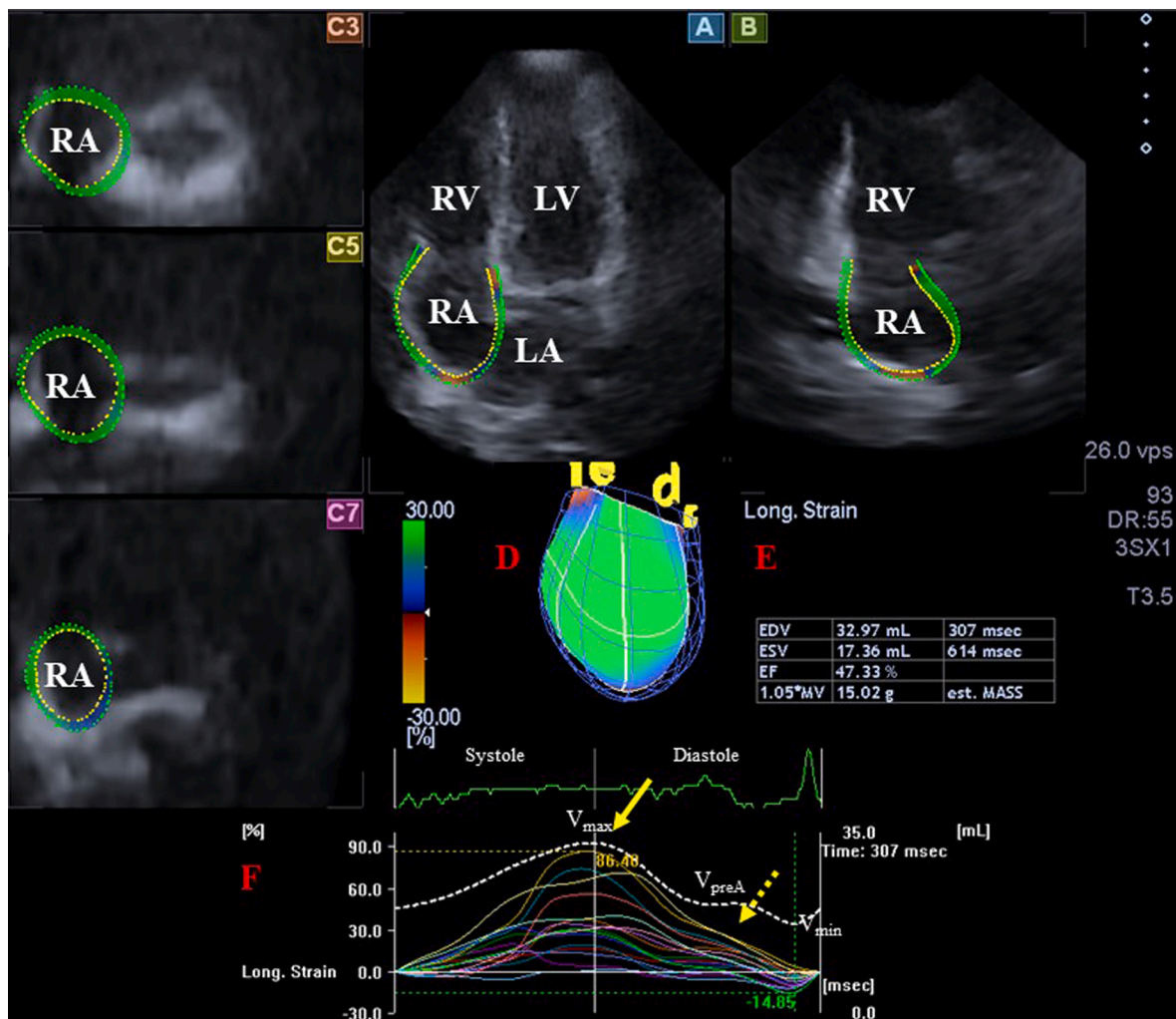
Definition of T1DM was based on the American Diabetes Association [16] and World Health Organization criteria [17]. None of them had any clinical signs of ischaemic heart disease or had angina pectoris. Their results were compared to those of 31 age- and gender-matched healthy controls (mean age:  $35.0 \pm 2.9$  years, 61% males). A subject was considered to be healthy in the absence of any disorder, disease or other pathological states, who did not have any risk factors or receive any drugs regularly and in case of whom echocardiographic and electrocardiographic findings proved to be normal. All patients and healthy controls were in sinus rhythm and underwent complete 2-dimensional Doppler echocardiography and 3DSTE. The presented results are from the **MAGYAR-Path** (Motion Analysis of the heart and Great vessels by 3-dimensional speckle-tracking echocardiography in Pathological cases) Study, which was organized at the Department of Medicine, University of Szeged, Hungary ('magyar' means 'Hungarian' in Hungarian language). This study complied with the Declaration of Helsinki and its updated forms, all subjects gave informed consent and the study was approved by the institution's human research committee (project number: 71/2011 and updated versions).

## 2.2. Two-dimensional echocardiography

Routine two-dimensional (2D) echocardiography was performed in all patients and controls by a Toshiba Artida™ echocardiographic tool (Toshiba Medical Systems, Tokyo, Japan) to be attached to a PST-30BT (1–5 MHz) phased-array transducer. Complete echocardiographic assessment included measurement of left atrial (LA) and left ventricular (LV) dimensions, volumes and ejection fraction, basal, midventricular and long-axis RV diameter, tricuspid annular plane systolic excursion (TAPSE), right ventricular fractional area change (RV-FAC) and pulsed Doppler evaluation of parameters featuring LV diastolic function (transmitral E and A waves, and their ratio). Colour Doppler echocardiography helped qualitative assessment of valvular regurgitations and continuous Doppler was used to exclude valvular stenosis by measuring valvular gradients [18].

## 2.3. Three-dimensional speckle-tracking echocardiography

3DSTE was performed according to the protocol of the MAGYAR-Path Study described earlier in previous papers using the same Toshiba Artida™ echocardiographic tool (Toshiba Medical Systems, Tokyo,



**Fig. 1.** Images from a three-dimensional (3D) echocardiographic full-volume dataset demonstrating the right atrium (RA) are seen with apical four-chamber view (A), apical two-chamber view (B), short-axis views at basal (C3), midatrial (C5) and superior (C7) RA level. Virtual 3D cast of the RA (red D), calculated RA volumes (red E) and RA volume changes over time (dashed line, red F) are also presented together with peak (yellow arrow, coloured lines) segmental RA strains and RA strains at atrial contraction (yellow dashed arrow, coloured lines). **Abbreviations.** LA = left atrium, LV = left ventricle, RA = right atrium, RV = right ventricle,  $V_{max}$  = end-systolic maximum RA volume,  $V_{min}$  = end-diastolic minimum RA volume,  $V_{preA}$  = preatrial contraction RA volume.

Japan) attached to a 1–4 MHz matrix phased-array PST-25SX transducer [15]. Firstly, 3D echocardiographic datasets were acquired following optimizations from an apical window within a single-breath-hold. Digitally 6 subvolumes were collected, which were later merged into a single 3D pyramid-shaped full volume dataset. RA measurements were performed on RA-focused volumes. For analysis, a special so called 3D Wall Motion Tracking software version 2.7 (Toshiba Medical Systems, Tokyo, Japan) was used. For RA quantifications, datasets were displayed in apical two- (AP2CH) and four-chamber (AP4CH) views and 3 short-axis views at different RA levels selected by the examiner at basal, midatrial and superior RA levels. Reference points were put on the RA endocardium in AP2CH and AP4CH views around the RA from the lateral to the septal edges of the tricuspid annular ring at end-diastole, then automatic reconstruction was started, the complete endocardial RA surface was determined and complete 3D cast of the RA was created (Fig. 1). Respecting the cardiac cycle, the following RA volumes were determined [15,19]:

- Maximum RA volume was measured at end-systole, just before tricuspid valve opening ( $V_{\max}$ )
- RA volume before atrial contraction was determined at early-diastole at the time of P wave on the electrocardiography ( $V_{\text{preA}}$ )
- Minimum RA volume was calculated at end-diastole, just before tricuspid valve closure ( $V_{\min}$ ).

For featuring different phases of the RA function, the following RA stroke volumes (SV) and RA emptying fractions (EF) were calculated using  $V_{\max}$ ,  $V_{\text{preA}}$  and  $V_{\min}$ :

*Reservoir function (systolic):*

- Total Atrial Stroke Volume (TASV):  $V_{\max} - V_{\min}$ .
- Total Atrial Emptying Fraction (TAEF):  $\text{TASV}/V_{\max} \times 100$ .

*Conduit function (early diastolic):*

- Passive Atrial Stroke Volume (PASV):  $V_{\max} - V_{\text{preA}}$
- Passive Atrial Emptying Fraction (PAEF):  $\text{PASV}/V_{\max} \times 100$ .

*Active contraction/booster pump function (late diastolic):*

- Active Atrial Stroke Volume (AASV):  $V_{\text{preA}} - V_{\min}$ .
- Active Atrial Emptying Fraction (AAEF):  $\text{AASV}/V_{\text{preA}} \times 100$ .

Using the same datasets, RA strains, quantitative features of RA contractility could also be calculated respecting the cardiac cycle [15,20,21]:

- Curves proved to have twin peaks: the first characterizes systolic reservoir function (called as peak RA strain), while the second characterizes late diastolic active contraction (booster pump) function (RA strain at atrial contraction),
- According to the complex contractile movement of each segment, the following unidirectional/unidimensional strains were calculated: radial strain (RS) featuring thickening and thinning of the RA segment, longitudinal strain (LS) (characterizing lengthening and shortening of the RA segment) and circumferential strain (CS) (quantifying widening and narrowing of the RA segment). Area strain (AS) and 3D strain (3DS) strains are combinations of LS-CS and LS-CS-RS, respectively.
- Global (characterizing the whole RA) and mean segmental (mean of the 16 segments) RA strains were calculated. Regional RA strains (superior, midatrial and basal) were also calculated from segmental RA strains.

## 2.4. Statistical analysis

Continuous variables are presented as mean  $\pm$  standard deviation, while categorical variables are presented as numbers and percentages.  $P < 0.05$  was considered to be significantly different. Student *t* test, Fisher's exact test and chi-squared test were used, when appropriate. Numerical correlations were established by a Pearson correlation. Statistical calculations were performed using MedCalc software (MedCalc, Mariakerke, Belgium).

## 3. Results

### 3.1. Demographic parameters

Demographic data of T1DM patients and matched controls are presented in Table 1. The mean heart rate of subjects was in normal range ( $74 \pm 6$  bpm). Fasting plasma glucose and creatinine levels did not differ between the groups, while HbA1c proved to be significantly increased in T1DM patients ( $8.0 \pm 1.5\%$  vs.  $5.1 \pm 0.9\%$ ,  $p < 0.05$ ).

### 3.2. Two-dimensional echocardiographic data

Routine two-dimensional Doppler echocardiographic parameters, RV dimensions, RV-FAC and TAPSE are presented in Table 1 with no significant differences between the groups examined. None of T1DM patients and matched healthy controls showed  $\geq$  grade 1 valvular regurgitations or had significant valvular stenosis.

### 3.3. 3DSTE-derived RA volumes and volume-based functional properties

3DSTE-derived RA volumes respecting the cardiac cycle and RA stroke volumes and emptying fractions did not show differences between young T1DM patients and matched controls (Table 2).

**Table 1**

Demographic and clinical data and three-dimensional speckle-tracking echocardiographic parameters of patients with type 1 diabetes mellitus and controls.

	Controls (n = 31)	T1DM patients (n = 17)	p- value
<b>Risk factors</b>			
Age (years)	35.0 $\pm$ 2.9	36.4 $\pm$ 13.0	0.59
Male gender (%)	19 (61)	10 (59)	1.00
Hypertension (%)	0 (0)	7 (41)	<0.01
Hypercholesterolemia (%)	0 (0)	6 (35)	<0.01
Diabetes mellitus (%)	0 (0)	17 (100)	<0.01
Smoking (%)	0 (0)	5 (29)	<0.01
Body mass index (kg/m <sup>2</sup> )	25.1 $\pm$ 3.1	23.4 $\pm$ 2.8	0.79
<b>Two-dimensional echocardiography</b>			
LA diameter (mm)	35.6 $\pm$ 4.4	33.6 $\pm$ 7.0	0.04
LV end-diastolic diameter (mm)	48.1 $\pm$ 4.0	46.8 $\pm$ 5.4	0.40
LV end-diastolic volume (ml)	110.0 $\pm$ 23.2	103.4 $\pm$ 28.3	0.37
LV end-systolic diameter (mm)	31.8 $\pm$ 3.2	30.1 $\pm$ 3.7	0.13
LV end-systolic volume (ml)	39.9 $\pm$ 11.5	36.1 $\pm$ 10.9	0.21
Interventricular septum (mm)	9.3 $\pm$ 1.4	9.0 $\pm$ 1.8	0.63
LV posterior wall (mm)	9.7 $\pm$ 1.9	9.0 $\pm$ 0.9	0.09
LV ejection fraction (%)	64.3 $\pm$ 4.0	64.8 $\pm$ 6.6	0.82
E/A	1.31 $\pm$ 0.07	1.48 $\pm$ 0.44	0.88
basal RV diameter (mm)	35.6 $\pm$ 4.3	36.4 $\pm$ 3.9	0.89
midventricular RV diameter (mm)	31.0 $\pm$ 2.2	32.6 $\pm$ 2.0	0.91
long-axis RV diameter (mm)	77.0 $\pm$ 6.3	79.3 $\pm$ 7.1	0.89
TAPSE (mm)	24.8 $\pm$ 2.1	24.5 $\pm$ 3.1	0.91
RV-FAC (%)	46.1 $\pm$ 4.2	45.2 $\pm$ 7.3	0.88

**Abbreviations:** E/A = ratio of transmitral early (E) and late (A) diastolic flow velocities, LA = left atrium, LV = left ventricle, RV-FAC = right ventricular fractional area change, TAPSE = tricuspid annular plane systolic excursion, T1DM = type 1 diabetes mellitus

**Table 2**

Comparison of three-dimensional speckle-tracking echocardiography-derived volumetric right atrial parameters between patients with type 1 diabetes mellitus and controls.

	Controls(n = 31)	T1DM patients(n = 17)
<b>Calculated Volumes</b>		
V <sub>max</sub> (ml)	46.1 ± 14.7	40.8 ± 13.7
V <sub>preA</sub> (ml)	33.8 ± 10.7	32.9 ± 13.5
V <sub>min</sub> (ml)	26.6 ± 10.4	29.9 ± 11.7
<b>Stroke Volumes</b>		
TASV (ml)	19.6 ± 8.7	19.2 ± 8.5
PASV (ml)	12.3 ± 8.2	10.9 ± 4.8
AASV (ml)	7.3 ± 3.7	8.3 ± 4.7
<b>Emptying fractions</b>		
TAEF (%)	42.7 ± 13.5	46.8 ± 12.5
PAEF (%)	26.2 ± 11.9	27.2 ± 8.7
AAEF (%)	22.8 ± 11.8	27.6 ± 10.3

**Abbreviations:** V<sub>max</sub> = maximum right atrial volume, V<sub>min</sub> = minimum right atrial volume, V<sub>preA</sub> = right atrial volume before atrial contraction, TASV = total atrial stroke volume, TAEF = total atrial emptying fraction, AASV = active atrial stroke volume, AAEF = active atrial emptying fraction, PASV = passive atrial stroke volume, PAEF = passive atrial emptying fraction, T1DM = type 1 diabetes mellitus

**3.4. 3DSTE-derived RA strains**

From peak RA strains representing RA reservoir function, mean segmental RA-3DS proved to be significantly increased. None of the other global and mean segmental peak RA strains differed between the groups examined (Table 3). Some regional basal/midatrial peak RA strains detailed in Table 4 were found to be significantly increased as well in T1DM patients as compared to controls. No differences could be detected in any global, mean segmental and regional RA strains at atrial contraction between T1DM patients and matched controls (Tables 5 and 6).

**3.5. Correlations**

Duration of T1DM correlated with peak global and mean segmental CS (r = -0.55, p = 0.04 and r = -0.60, p = 0.02, respectively) and regional peak basal and midatrial CS (r = -0.62, p = 0.01 and r = -0.59, p = 0.02, respectively) and regional basal CS at atrial contraction (r = -0.54, p = 0.04). HbA1c correlated with LA diameter (r = 0.62, p = 0.01), TASV (r = -0.61, p = 0.02), TAEF (r = -0.59, p = 0.02), PASV (r = -0.59, p = 0.02), PAEF (r = -0.54, p = 0.04), AASV (r = -0.53, p = 0.04), AAEF (r = -0.53, p = 0.04), peak global and mean segmental LS (r = -0.59, p = 0.02 and -0.59, p = 0.02, respectively), peak global and mean segmental AS (r = -0.54, p = 0.04 and r = -0.57, p = 0.03,

**Table 3**

Comparison of three-dimensional speckle-tracking echocardiography-derived peak global and mean segmental right atrial strains between patients with type 1 diabetes mellitus and controls.

	Controls(n = 31)	T1DM patients(n = 17)
<b>Global strains</b>		
Radial (%)	-12.3 ± 7.0	-13.7 ± 5.5
Circumferential (%)	18.1 ± 14.8	21.4 ± 12.7
Longitudinal (%)	35.2 ± 16.8	39.7 ± 12.8
3D (%)	-4.0 ± 3.7	-6.1 ± 5.0
Area (%)	58.5 ± 43.4	65.7 ± 30.4
<b>Mean segmental strains</b>		
Radial (%)	-17.1 ± 6.4	-18.5 ± 4.0
Circumferential (%)	23.9 ± 14.7	26.7 ± 11.8
Longitudinal (%)	39.6 ± 15.8	42.2 ± 12.5
3D (%)	-9.5 ± 4.3	-11.7 ± 4.2*
Area (%)	66.6 ± 42.7	72.2 ± 29.2

\* p < 0.05 vs Controls

**Abbreviations:** 3D = three-dimensional, T1DM = type 1 diabetes mellitus

**Table 4**

Comparison of three-dimensional speckle-tracking echocardiography-derived peak regional right atrial strains between patients with type 1 diabetes mellitus and controls.

	Controls(n = 31)	T1DM patients(n = 17)
RS basal (%)	-14.8 ± 7.3	-19.6 ± 5.5*
RS midatrial (%)	-16.8 ± 6.5	-16.9 ± 4.9
RS superior (%)	-20.9 ± 14.3	-19.2 ± 8.5
CS basal (%)	23.6 ± 12.6	24.4 ± 12.1
CS midatrial (%)	20.8 ± 12.9	26.3 ± 11.5
CS superior (%)	29.0 ± 26.3	30.9 ± 21.9
LS basal (%)	42.5 ± 19.4	32.8 ± 10.9
LS midatrial (%)	47.9 ± 21.7	62.5 ± 24.4*
LS superior (%)	22.6 ± 16.9	25.5 ± 10.8
3DS basal (%)	-8.3 ± 5.5	-12.3 ± 5.4*
3DS midatrial (%)	-8.4 ± 3.6	-9.8 ± 4.3
3DS superior (%)	-13.0 ± 10.5	-13.8 ± 8.2
AS basal (%)	59.8 ± 32.7	49.8 ± 22.1
AS midatrial (%)	75.3 ± 49.2	97.7 ± 43.0*
AS superior (%)	63.7 ± 67.3	67.5 ± 50.3

\* p < 0.05 vs Controls

**Abbreviations:** RS = radial strain, CS = circumferential strain, LS = longitudinal strain, 3DS = three-dimensional strain, AS = area strain, T1DM = type 1 diabetes mellitus

**Table 5**

Comparison of three-dimensional speckle-tracking echocardiography-derived global and segmental right atrial strains at atrial contraction between patients with type 1 diabetes mellitus and controls.

	Controls(n = 31)	T1DM patients(n = 17)
<b>Global strains</b>		
Radial (%)	-5.6 ± 5.9	-6.0 ± 5.5
Circumferential (%)	10.0 ± 8.4	9.3 ± 7.6
Longitudinal (%)	11.3 ± 9.2	8.4 ± 5.3
3D (%)	-3.2 ± 5.2	-3.5 ± 3.9
Area (%)	22.9 ± 18.9	17.5 ± 11.5
<b>Mean segmental strains</b>		
Radial (%)	-8.2 ± 4.5	-8.7 ± 3.9
Circumferential (%)	12.0 ± 7.1	12.0 ± 7.2
Longitudinal (%)	12.1 ± 6.4	11.2 ± 4.9
3D (%)	-5.1 ± 4.3	-5.3 ± 3.5
Area (%)	24.7 ± 17.7	25.0 ± 12.0

**Abbreviations:** 3D: three-dimensional, T1DM = type 1 diabetes mellitus

**Table 6**

Comparison of three-dimensional speckle-tracking echocardiography-derived regional right atrial strains at atrial contraction between patients with type 1 diabetes mellitus and controls.

	Controls(n = 31)	T1DM patients(n = 17)
RS basal (%)	-7.8 ± 6.6	-9.4 ± 5.2
RS midatrial (%)	-7.9 ± 5.2	-8.2 ± 4.5
RS superior (%)	-9.4 ± 6.5	-8.5 ± 6.3
CS basal (%)	10.8 ± 5.7	10.2 ± 8.0
CS midatrial (%)	10.5 ± 6.5	11.7 ± 7.6
CS superior (%)	16.1 ± 16.2	15.3 ± 12.0
LS basal (%)	10.8 ± 8.3	8.1 ± 4.6
LS midatrial (%)	14.0 ± 8.5	14.7 ± 8.8
LS superior (%)	11.6 ± 8.5	10.6 ± 5.9
3DS basal (%)	-4.0 ± 5.6	-5.5 ± 3.6
3DS midatrial (%)	-4.3 ± 4.5	-4.6 ± 4.0
3DS superior (%)	-7.9 ± 6.8	-6.0 ± 6.3
AS basal (%)	20.2 ± 16.8	19.0 ± 11.0
AS midatrial (%)	24.9 ± 17.0	25.7 ± 16.7
AS superior (%)	31.0 ± 31.7	33.1 ± 25.1

**Abbreviations:** RS = radial strain, CS = circumferential strain, LS = longitudinal strain, 3DS = three-dimensional strain, AS = area strain, T1DM = type 1 diabetes mellitus



respectively) and peak regional midatrial AS ( $r = -0.61$ ,  $p = 0.02$ ). Daily dose of insulin did not show correlation with any echocardiographic parameter.

#### 4. Discussion

Several conflicting results are available in T1DM patients in early phases of disease process. For instance, LV mass, volumes, and global function represented by LV ejection fraction and CS/LS/RS were found to be similar in patients with T1DM and in controls. T1DM subjects with normal structure, LV ejection fraction, and strain, have increased extracellular volume and increased systolic torsion [1]. In contrast, young adults with T1DM without known heart disease were demonstrated to have subclinical myocardial dysfunction represented by reduced LV endocardial and epicardial LS and increased mechanical dispersion assessed by multi-layered 2DSTE [2]. Moreover, LV systolic and diastolic discoordination could also be demonstrated providing early evidence of cardiomyopathy [3]. Diastolic functions of both ventricles and LA mechanical functions were found to be impaired in T1DM patients with prolonged intra- and interatrial electromechanical delays [4]. In patients with T1DM, LA phasic function was found to be decreased in adolescents and young adults, while LA stiffness was increased in adult patients aged > 30 years [5]. Using the most recent 3DSTE, all LA volumes were increased and were respecting the cardiac cycle, total atrial stroke volume was increased and peak mean segmental LA-CS was reduced together with alterations in certain segmental strains in young T1DM patients [6]. On the right heart, diastolic right ventricular (RV) dysfunction with preserved subclinical myocardial systolic function could be detected in young adults with T1DM without known heart disease in early stages of the disease [7]. However, T1DM-related RA abnormalities were not examined by 3DSTE until now.

Similarly to LA, RA has a triphasic function during the cardiac cycle functioning as a reservoir in systole, serving as a conduit in early diastole and being as a booster pump in late diastole. According to the guidelines, routine echocardiography offers limited opportunity for the evaluation of the RA including measurement of RA dimensions [8]. 3DSTE has an ability for detailed volumetric and functional assessment of all phases of RA function by volumetric, volume-based and strain parameters [9]. In the present study, RA volumes and volume-based functional properties did not differ between T1DM patients and matched controls. However, larger HbA1c was associated with lower RA volume-based functional properties. From RA strains representing RA contractility during the cardiac cycle, only certain basal/midatrial regional peak RA strains and mean segmental RA-3DS representing end-systolic reservoir phase of RA function were found to be increased in T1DM patients, which could be considered as a compensatory effect theoretically against dysfunctioning RV via tricuspid annulus [7]. Moreover, longer duration of T1DM and higher HbA1c were associated with lower RA contractility represented by certain strains suggesting extenuation of this compensation. Comparing results from MAGYAR-Path Study, atria show significant differences in T1DM-associated volumetric and functional abnormalities [6]. While LA show increased volumes and reduced function, RA show preserved volumes with increased regional function. However, further studies are warranted to confirm our findings and for deeper insights into its pathophysiology. Theoretically, 3DSTE has a capability of detailed RV assessment even in T1DM, therefore 3DSTE-derived detailed volumetric and functional analysis of the RV is requested, which adequately reflects physiological conditions.

##### 4.1. Limitation section

The following important limitations have arisen during evaluations:

- It is well known that 3DSTE suffers in lower image quality as compared to that of 2D echocardiography due to low temporal and spatial image resolutions. Moreover, size of 3DSTE-capable

transducer is larger than that for 2D echocardiography, which could significantly affect data acquisitions.

- Although 3DSTE-derived normal reference values of RA volumes and strains are available [19,20], and disease-specific alterations of RA abnormalities are suggested in previous studies [15], further independent validation studies are warranted comparing results against other echocardiographic and non-echocardiographic imaging methods.
- Due to the small sizes and special shapes, RA appendage, caval veins and coronary sinus were not included in the 3DSTE-derived RA cast.
- 3DSTE is capable of measuring volumes and strains from the 3D model of other cardiac chambers. However, the present study aimed quantification only of RA volumes and functional properties in this study.
- There is a big debate, whether atrial septum is a part of which atrium. During assessments, atrial septum was considered to be a part of RA in this study like in our previous studies.
- 3DSTE-derived RV volumetric and functional parameters were not be measured due to non-existence of adequate software for their assessment at the time of examinations. Theoretically 3DSTE would have a role for detailed RV assessment in this regard, but further technical improvements and developments are required.
- There is no specific 3DSTE-derived RA segmentation model available, therefore LV segmentation model was used during evaluations.
- Hypertension and smoking habit were present in significant part of T1DM patients, which are known to affect LA function [4-6].

##### 4.2. Conclusions

In young patients with T1DM, preserved RA volumes respecting the cardiac cycle are accompanied with increase in certain regional end-systolic peak RA strains suggesting a compensatory mechanism, which seems to be associated with T1DM duration and HbA1c.

##### CRediT authorship contribution statement

**Attila Nemes:** Conceptualization, Writing – original draft, Writing – review & editing. **Árpád Kormányos:** Methodology, Investigation, Data curation. **Zoltán Ruzsa:** Writing – review & editing. **Tamás Várkonyi:** Resources. **Csaba Lengyel:** Resources.

##### Declaration of Competing Interest

The authors declare that they have no known competing financial interests or personal relationships that could have appeared to influence the work reported in this paper.

##### Funding

no funding.

##### Ethical approval

All procedures performed in studies involving human participants were in accordance with the ethical standards of the institutional and/or national research committee and with the 1964 Helsinki declaration and its later amendments or comparable ethical standards.

Informed consent was obtained from all individual participants included in the study.

##### References

- [1] Z. Vasanji, R.J. Sigal, N.D. Eves, D.L. Isaacs, M.G. Friedrich, K. Chow, R. B. Thompson, Increased left ventricular extracellular volume and enhanced twist function in type 1 diabetic individuals, *J. Appl. Physiol.* (1985) 123 (2017) 394–401.
- [2] M. Berceanu, O. Mirea, I. Donoiu, C. Militaru, A. Săftoiu, C. Istrătoae, Myocardial Function Assessed by Multi-Layered Two-Dimensional Speckle Tracking Analysis in

- Asymptomatic Young Subjects with Diabetes Mellitus Type 1, *Cardiology* 145 (2020) 80–87.
- [3] M. Schäfer, P. Bjornstad, B.S. Frank, A. Baumgartner, U. Truong, D. Enge, J.C. von Alvensleben, M.B. Mitchell, D.D. Ivy, A.J. Barker, J.E.B. Reusch, K.J. Nadeau, Frequency of Reduced Left Ventricular Contractile Efficiency and Disordinated Myocardial Relaxation in Patients Aged 16 to 21 Years With Type 1 Diabetes Mellitus (from the Emerald Study), *Am. J. Cardiol.* 128 (2020) 45–53.
- [4] G. Acar, A. Akcay, A. Sokmen, M. Ozkaya, E. Guler, G. Sokmen, H. Kaya, A. B. Nacar, C. Tuncer, Assessment of atrial electromechanical delay, diastolic functions, and left atrial mechanical functions in patients with type 1 diabetes mellitus, *J. Am. Soc. Echocardiogr.* 22 (2009) 732–738.
- [5] M. Ifuku, K. Takahashi, Y. Hosono, T. Iso, A. Ishikawa, H. Haruna, N. Takubo, K. Komiya, M. Kurita, F. Ikeda, H. Watada, T. Shimizu, Left atrial dysfunction and stiffness in pediatric and adult patients with Type 1 diabetes mellitus assessed with speckle tracking echocardiography, *Pediatr. Diabetes* 22 (2021) 303–319.
- [6] A. Nemes, G.Á. Piros, C. Lengyel, P. Domsik, A. Kalapos, T.T. Várkonyi, A. Orosz, T. Forster, Complex evaluation of left atrial dysfunction in patients with type 1 diabetes mellitus by three-dimensional speckle tracking echocardiography: results from the MAGYAR-Path Study, *Anatol. J. Cardiol.* 16 (2016) 587–593.
- [7] M. Berceanu, O. Mirea, G.C. Tártea, I. Donoiu, C. Militaru, O. Istrătoaie, A. Săftoiu, The Significance of Right Ventricle in Young Subjects with Diabetes Mellitus Type 1. An echocardiographic study, *Curr. Health Sci. J.* 45 (2019) 174–178.
- [8] L.G. Rudski, W.W. Lai, J. Afilalo, L. Hua, M.D. Handschumacher, K. Chandrasekaran, S.D. Solomon, E.K. Louie, N.B. Schiller, Guidelines for the echocardiographic assessment of the right heart in adults: a report from the American Society of Echocardiography endorsed by the European Association of Echocardiography, a registered branch of the European Society of Cardiology, and the Canadian Society of Echocardiography, *J. Am. Soc. Echocardiogr.* 23 (2010) 685–713.
- [9] M. Tadic, The right atrium, a forgotten cardiac chamber: an updated review of multimodality imaging, *J. Clin. Ultrasound* 43 (2015) 335–345.
- [10] K.A. Ammar, T.E. Paterick, B.K. Khanderia, M.F. Jan, C. Kramer, M.M. Umland, A. J. Tercius, L. Baratta, A.J. Tajik, Myocardial mechanics: understanding and applying three-dimensional speckle tracking echocardiography in clinical practice, *Echocardiography* 29 (2012) 861–872.
- [11] J.A. Urbano-Moral, A.R. Patel, M.S. Maron, J.A. Arias-Godinez, N.G. Pandian, Three-dimensional speckle-tracking echocardiography: methodological aspects and clinical potential, *Echocardiography* 29 (2012) 997–1000.
- [12] Y. Seo, T. Ishizu, K. Aonuma, Current status of 3-dimensional speckle tracking echocardiography: a review from our experiences, *J. Cardiovasc. Ultrasound* 22 (2014) 49–57.
- [13] Y. Seo, T. Ishizu, A. Atsumi, R. Kawamura, K. Aonuma, Three-dimensional speckle tracking echocardiography, *Circ. J.* 78 (2014) 1290–1301.
- [14] A. Nemes, A. Kalapos, P. Domsik, T. Forster, Three-dimensional speckle-tracking echocardiography – a further step in non-invasive three-dimensional cardiac imaging, *Orv. Hetil.* 153 (2012) 1570–1577.
- [15] A. Nemes, P. Domsik, A. Kalapos, Á. Kormányos, N. Ambrus, T. Forster, Three-dimensional speckle-tracking echocardiography detects different patterns of right atrial dysfunction in selected disorders: a short summary from the MAGYAR-Path Study, *Quant. Imaging Med. Surg.* 8 (2018) 182–186.
- [16] American Diabetes Association. All about diabetes. [www.diabetes.org/about-diabetes.sjp](http://www.diabetes.org/about-diabetes.sjp) (Version current at January 1, 2021).
- [17] World Health Organization. Diabetes programme. What is diabetes? [www.who.int/diabetes/BOOKLET\\_HTML/en/index4.html](http://www.who.int/diabetes/BOOKLET_HTML/en/index4.html) (Version current at January 1, 2021).
- [18] R.M. Lang, L.P. Badano, V. Mor-Avi, J. Afilalo, A. Armstrong, L. Ernande, F. A. Flachskampf, E. Foster, S.A. Goldstein, T. Kuznetsova, P. Lancellotti, D. Muraru, M.H. Picard, E.R. Rietzschel, L. Rudski, K.T. Spencer, W. Tsang, J.U. Voigt, Recommendations for cardiac chamber quantification by echocardiography in adults: an update from the American Society of Echocardiography and the European Association of Cardiovascular Imaging, *Eur. Heart J. Cardiovasc. Imaging* 16 (2015) 233–270.
- [19] A. Nemes, Á. Kormányos, P. Domsik, A. Kalapos, N. Ambrus, C. Lengyel, Normal reference values of three-dimensional speckle-tracking echocardiography-derived right atrial volumes and volume-based functional properties in healthy adults (Insights from the MAGYAR-Healthy Study), *J. Clin. Ultrasound* 48 (2020) 263–268.
- [20] A. Nemes, Á. Kormányos, P. Domsik, A. Kalapos, N. Ambrus, C. Lengyel, T. Forster, Normal reference values of right atrial strain parameters using three-dimensional speckle-tracking echocardiography (results from the MAGYAR-Healthy Study), *Int. J. Cardiovasc. Imaging* 35 (2019) 2009–2018.
- [21] S. Chadaide, P. Domsik, A. Kalapos, L. Sággy, T. Forster, A. Nemes, Three-dimensional speckle tracking echocardiography-derived left atrial strain parameters are reduced in patients with atrial fibrillation (results from the MAGYAR-Path Study), *Echocardiography* 30 (2013) 1078–1083.