

## Transurethral Surgical Anatomy of the Arterial Bleeder in the Enucleated Capsular Plane of Enlarged Prostates During Holmium Laser Enucleation of the Prostate

Min Soo Choo, Hahn-Ey Lee<sup>1</sup>, Jungbum Bae<sup>2</sup>, Sung Yong Cho<sup>3</sup>, Seung-June Oh<sup>4</sup>

Department of Urology, Dongtan Sacred Heart Hospital, Hwaseong;

<sup>1</sup>Department of Urology, Gachon University Gil Medical Center, Incheon;

<sup>2</sup>Department of Urology, Dongguk University Ilsan Hospital, Goyang;

<sup>3</sup>Department of Urology, SMG-SNU Boramae Medical Center, Seoul;

<sup>4</sup>Department of Urology, Seoul National University Hospital, Seoul, Korea

**Purpose:** To identify the endoscopic vascular anatomy of the prostate during Holmium laser enucleation of the prostate (HoLEP), and analyze the clinical risk factors associated with significant arterial bleeding.

**Methods:** We identified 107 consecutive patients with benign prostatic hyperplasia who underwent HoLEP between September 2009 and August 2010, performed by a single surgeon (S.J.O.). Two independent reviewers reviewed the surgery video database and completed a prespecified form. The location of bleeding arteries was marked at the level of the bladder neck, proximal prostate, distal prostate, and verumontanum. Arterial bleeding was classified into one of three grades according to bleeding severity (grades 2 and 3 indicate significant bleeding).

**Results:** The mean prostate volume was  $65.1 \pm 31.5$  mL, and the mean prostate-specific antigen (PSA) level was  $3.69 \pm 3.58$  ng/mL. During the HoLEP procedure, the most common locations of significant bleeders were the 2–5 and 7–10 o'clock positions in the proximal prostate. The average number of bleeding arteries was  $12.1 \pm 7.9$  per procedure, and  $1.93 \pm 1.20$  per 10 mL of prostate volume. Multivariate analysis revealed that prostate volume and serum PSA were significant parameters for estimating the number of bleeding vessels.

**Conclusions:** During the HoLEP procedure, the most common locations of significant bleeders were the 2–5 and 7–10 o'clock positions in the proximal prostate. Prostate volume was associated with the number of bleeders. A careful approach to the capsular plane of the proximal prostate facilitates early hemostasis during the HoLEP procedure, especially with larger adenomas.

**Keywords:** Lasers; Blood supply; Anatomy; Prostatic hyperplasia; Transurethral resection of prostate

### INTRODUCTION

The procedure of Holmium laser enucleation of the prostate (HoLEP) has the advantage of complete anatomic enucleation of the prostate [1,2]; however, this procedure is technically difficult to perform and has a steep learning curve [3-5]. HoLEP requires blunt dissection between the prostatic adenoma and the capsule, with the beak of the resectoscope serving as the “surgeon’s finger” during simple open prostatectomy. However, blunt dissection can cause bothersome bleeding. Although HoLEP is well

known to be an exceptionally hemostatic procedure, significant bleeding can still occur in certain patient populations, such as those with cardiac disease, large glands, prostate cancer, or infections [6].

Few reports have detailed the gross anatomy of the prostatic arterial supply. Bilhim et al. [7] reported that the prostate arteries reach the prostate capsule at the prostatovesical junction posterolaterally. Leventis et al. [8] reported that multiple capsular arteries transversely enter from the lateral and anterior borders of the gland. Hinman [9] described that the urethral branches of

**Corresponding author:** Seung-June Oh  
Department of Urology, Seoul National University Hospital, 101 Daehak-ro, Jongno-gu, Seoul 110-744, Korea  
Tel: +82-2-2072-2406 / Fax: +82-2-742-4665 / E-mail: [sjo@snu.ac.kr](mailto:sjo@snu.ac.kr)  
Submitted: July 24, 2014 / Accepted after revision: August 28, 2014

This is an Open Access article distributed under the terms of the Creative Commons Attribution Non-Commercial License (<http://creativecommons.org/licenses/by-nc/3.0/>) which permits unrestricted non-commercial use, distribution, and reproduction in any medium, provided the original work is properly cited.

the prostatic arteries enter near the vesical neck at the 5 and 7 o'clock positions and constitute the blood supply to the adenoma; thus, persistent excessive bleeding can be controlled with a posterior capsular suture near the neck.

The endoscopic anatomy during HoLEP is different from the gross anatomy during open prostatectomy; however, the endoscopic vascular anatomy of the prostate is not known. There also are currently no standard guidelines concerning the endoscopic anatomy of the prostate vessels. Therefore, evaluating the endoscopic vascular anatomy of the prostate is necessary and such knowledge can help considerably shorten the learning curve of HoLEP. In this study, we identified the endoscopic vascular anatomy of the prostate as observed during the HoLEP procedure and analyzed the clinical risk factors associated with significant arterial bleeding.

## MATERIALS AND METHODS

This study was conducted with approval from the Seoul National University Hospital Institutional Review Board (H-1205-071-410) and was performed in strict accordance with the ethical guidelines of the Declaration of Helsinki. As this was retrospective study based on a video database and data were analyzed anonymously (i.e., personal identifiers were removed), the IRB waived the requirement for the acquisition of informed consent from patients.

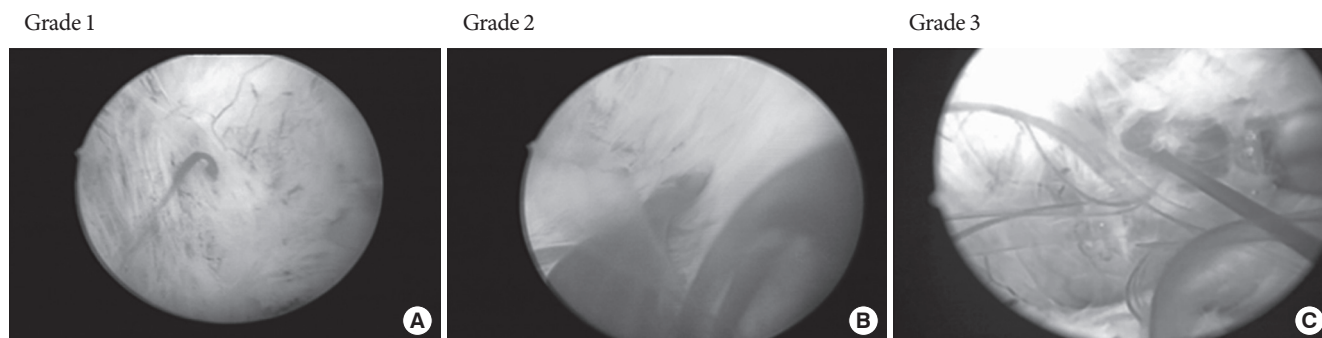We identified consecutive 107 patients with lower urinary tract symptoms (LUTS) caused by benign prostatic hyperplasia (BPH), who underwent HoLEP between September 2009 and August 2010 performed by a single surgeon (S.J.O.). Before September 2008, the surgeon had performed 136 HoLEP procedures; therefore, we considered that the surgeon has adequate surgical skill at the time of the study. All patients underwent urodynamic pressure flow tests. Prostatic biopsies were performed to exclude cancer when the serum prostate-specific antigen (PSA) level was elevated ( $>4$  ng/mL) or when a digital rectal examination produced suspicious results. The indications for HoLEP surgery were as follows: age  $\geq 50$  years; clinical LUTS (International Prostate Symptom Score  $\geq 8$ ); anatomical BPH (prostate volume  $\geq 25$  mL); and the absence of a previous radiotherapy or surgery in the bladder and/or prostate, genitourinary malignancy or trauma history, or recent symptomatic urinary tract infection.

The surgical procedure for HoLEP at our institution has been previously described in detail [10-14]. Patients were instructed

to discontinue anticoagulant medication at least 5 days before surgery. In the few patients for whom anticoagulants were essential perioperatively because of cardiovascular or cerebrovascular issues, a management plan was provided by the corresponding specialty departments. When a bleeding vessel was encountered, the laser fiber was defocused by pulling the laser back slightly from the bleeding point to achieve hemostasis. The surgical database was created from real-time recorded MPEG files of HoLEP surgeries by using the GI-7000HD full HD quality PACS gateway (iS System, Goyang, Korea) at our institution, obtained with an IMAGE 1 H3-P fullHD pendulum camera head and IMAGE 1 HUBHD camera control unit SCB with an SDI module (Karl Storz Endoskope, Tuttlingen, Germany).

Two independent reviewers retrospectively reassessed our prospectively collected video database of the HoLEP procedure and completed a prespecified form. At our institute, all HoLEP procedures are recorded and stored in a video database. Both reviewers initially reviewed 10 videos together, and agreed on the classification of the bleeding grades. Then, the reviewers divided the groups for analysis and reviewed the videos separately. The location and number of bleeding arteries were marked according to the face of a clock at the level of the bladder neck, proximal prostate, distal prostate, and verumontanum. Arterial bleeding was classified into three grades according to the bleeding severity, as follows: grade 1, the bleeding was assumed to be arterial but was easily coagulated; grade 2, the bleeding interfered with the surgical procedure but was easily coagulated, or the bleeding was not severe but coagulation was prolonged; and grade 3, the bleeding completely obscured the operative field and coagulation was difficult and time consuming (Fig. 1). Grades 2 and 3 bleeding were classified as significant bleeding. The location and number of bleeding vessels, and the predictive clinical factors were analyzed.

Perioperative data such as patient age, body mass index, prostate volume, serum PSA level, comorbidities, medications, preoperative biopsy results, postoperative pathology findings, total operation time, and enucleation and morcellation times were recorded prospectively. The prostate size was calculated preoperatively by using the prolate ellipsoid formula ( $\pi/6 \times \text{height} \times \text{width} \times \text{length}$ ) based on transrectal ultrasonography measurements in three dimensions. The baseline characteristics of all patients were summarized as the mean  $\pm$  standard deviation for continuous variables and frequencies, or as percentages for categorical variables. Prostate volume was stratified as follows: small,  $<40$  g; intermediate, 40–75 g; and large,  $>75$  g. A large number



**Fig. 1.** Grading of bleeders. (A) The grade 1 bleeder was assumed to be arterial but was easily coagulated. (B) The grade 2 bleeder interfered with the surgical procedure, but was easily coagulated, or when the bleeding was not severe, but coagulation was prolonged. (C) The grade 3 bleeder was definitive pumping artery that completely obscured the operative field and coagulation was difficult and time-consuming.

of bleeder was defined as  $\geq 10$  significant bleeders.

Data were statistically analyzed by using the Student t-test and/or the Pearson chi-square test. Variables were established by using univariate analysis, and those factors determined to be significant were entered into multivariate analysis with a logistic regression model. In all tests, a two-sided P-value of  $< 0.05$  was considered to be statistically significant. Statistical analysis was performed with SPSS ver. 13.0 (SPSS Inc., Chicago, IL, USA).

## RESULTS

The mean age of the patients was  $68.6 \pm 6.8$  years. The mean prostate volume was  $65.1 \pm 31.5$  mL, and the mean PSA was  $3.69 \pm 3.58$  ng/mL. Concerning underlying diseases, 50.5% of the evaluated patients had hypertension, 17.8% had diabetes, 35.5% had a history of taking anticoagulant medications, and 16.8% were taking a 5- $\alpha$ -reductase inhibitor (5-ARI). Preoperative prostate biopsies were performed in 16.7% of the patients. The mean operative and enucleation times were  $61.1 \pm 32.1$  and  $45.2 \pm 20.6$  minutes, respectively. Prostate cancer was incidentally detected in 9.3% of the specimens through postoperative pathologic examination (Table 1).

During HoLEP, the most common locations of significant bleeders were at the 3–4 and 8–9 o'clock positions in the proximal prostate. At the bladder neck, bleeding arteries were most commonly located at the 3 and 10 o'clock positions. In the proximal prostate, significant bleeding arteries were noted at the 3–4 and 8–9 o'clock positions. Bleeding arteries were commonly located at the 2–3 and 8–9 o'clock positions in the distal prostate. At the verumontanum, bleeding arteries were located on the lateral aspects bilaterally (Fig. 2).

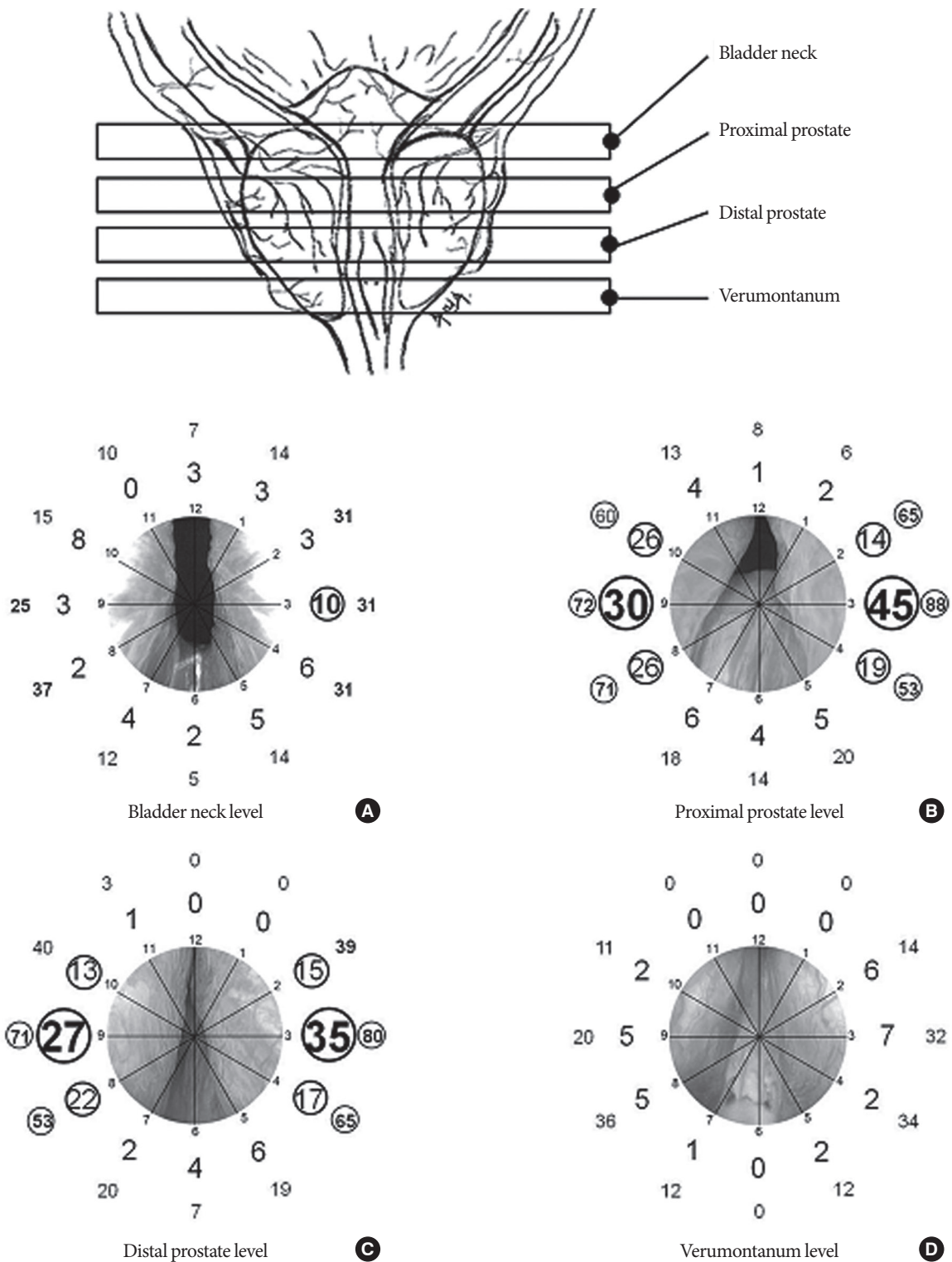
**Table 1.** Baseline characteristics

Characteristic	Value
Age (yr)	$68.9 \pm 6.8$
Body mass index (kg/m <sup>2</sup> )	$24.2 \pm 2.9$
Prostate volume (mL)	$65.1 \pm 31.5$
PSA (ng/mL)	$3.69 \pm 3.58$
Hypertension	54 (50.5)
Diabetes mellitus	19 (17.8)
5 Alpha reductase inhibitor	18 (16.8)
Anticoagulant medication	38 (35.5)
Preoperative biopsy done	18 (16.7)
Pathology - prostate cancer	10 (9.3)
Operative time (min)	$61.1 \pm 32.1$
Enucleation time (min)	$45.2 \pm 20.6$

Values are presented as mean  $\pm$  standard deviation or number (%).

The average number of bleeding arteries per operation was  $12.1 \pm 7.9$ , and not only the total number of bleeders but also the number of significant bleeders increased significantly in proportion to the prostate volume. The density of bleeders and significant bleeders was 1.93 and 0.53 per 10 mL of prostate volume, respectively. The density of significant bleeders also correlated with the prostate volume but did not reach statistical significance ( $P = 0.226$ ) (Table 2).

The prostate volume was a significant parameter for estimating a large number of bleeding vessels, suggesting that more bleeders existed in larger prostates. Preoperative use of anticoagulant medications or 5-ARIs was not a significant risk factor for bleeding vessels. The operation time was also not associated with the number of bleeders. On the basis of a univariate analy-



**Fig. 2.** Location of bleeders. (A) Bladder neck level, (B) proximal prostate level, (C) distal prostate level, and (D) verumontanum level. The large numbers within the inner circles show the number of significant bleeders at each location marked by the hours of a clock. The small numbers marked within the outer circles show the number of total bleeders at each location. We considered more than 10 significant bleeders as frequent, and more than 50 bleeders as frequent for each location, and marked frequent bleeders within circles.

**Table 2.** The number and density of bleeding vessels according to prostate volume

	No. (%)	Bleeder	P-value	Bleeder per 10 mL	P-value
Total no. of bleeders		12.1 ± 7.9	<0.001	1.93 ± 1.20	0.798
< 40 mL	18 (16.8)	6.8 ± 6.2		2.01 ± 1.69	
40–75 mL	63 (58.9)	9.9 ± 5.4		1.97 ± 1.22	
≥ 75 mL	26 (24.3)	19.6 ± 8.4		1.79 ± 0.73	
No. of significant bleeders		3.7 ± 4.2	<0.001	0.53 ± 0.63	0.226
< 40 mL	18 (16.8)	1.5 ± 6.2		0.42 ± 0.84	
40–75 mL	63 (58.9)	2.3 ± 2.2		0.49 ± 0.63	
≥ 75 mL	26 (24.3)	7.9 ± 4.7		0.71 ± 0.40	

Values are presented as mean ± standard deviation or number (%).

**Table 3.** Perioperative predictive factors for a large number of bleeders

Parameter	Univariate	Multivariate		
	P-value	OR	95% CI	P-value
Prostate volume	0.002			
< 40 mL vs. 40–75 mL		1.5	0.4–5.0	0.514
< 40 mL vs. ≥ 75 mL		6.1	1.1–33.8	0.037*
Prostate-specific antigen	0.003			
< 4 ng/mL vs. ≥ 4 ng/mL		1.2	0.3–5.0	0.724
Preoperative biopsy	0.004	1.0	0.2–4.8	0.603
Pathology - prostate cancer	0.008	1.5	0.2–8.2	0.280

Displays only significant variables in univariate analysis.

OR, odds ratio; CI, confidence interval.

\*P < 0.05

sis, the PSA level, a history of a preoperative biopsy, and postoperative pathologic findings were associated with the number of bleeders. However, multivariate analysis revealed that the prostate volume was the only significant parameter for estimating the number of bleeding vessels (Table 3).

## DISCUSSION

Our findings suggest that the most common locations of penetration of the supplying artery were the 3–4 and 8–9 o'clock positions in the proximal prostate. The number of bleeders was associated with the prostate volume. At the level of the distal prostate and verumontanum, bleeders were observed in similar locations. This could be due to the course of the prostate arteries in a parallel direction to the urethra, and to the penetration of the supplying artery to the adenoma at both lateral sides of the prostate. To our knowledge, this is the first study to confirm the arterial anatomy of the prostate under an endoscopic view. Such an accurate knowledge of the endoscopic surgical anatomy allows

to easily control bleeding and to identify the major bleeder during or after enucleation.

A previous study has reported that the urethral arteries penetrate the prostatovesical junction at the 1–5 and 7–11 o'clock positions [13]. The urethral arteries then turn caudally, parallel to the urethra, to supply the prostate gland [13]. These arteries provide the main blood supply to the adenoma in men with BPH [15]. The other main branch of the prostatic artery is the capsular artery, which is arranged on the prostate surface after passing the capsule at the 2, 5, 7, and 10 o'clock positions [7]. The bulk of the capsular artery runs posterolaterally and pierces the prostate at right angles to supply the glandular tissues [16]. The results of previous studies are consistent with our findings. Significant arterial bleeders were observed mainly at the 2–5 and 7–10 o'clock positions near the prostatic capsule.

It is essential to know the endoscopic vascular anatomy of the prostate during HoLEP to perform efficient surgery and to master the learning curve. In our clinic, we push the prostate adenoma superiorly and inferiorly with the beak of the resectoscope; this traction makes it easier to find the anatomic plane. In some clinics, the surgeon broadly coagulates the area surrounding the prostate, which may control bleeding but consumes energy, time, and fiber. In our institution, we try to perform maximally efficient surgery by using a combination of sharp dissection with a laser and blunt dissection with the beak of the resectoscope; thus, we coagulate vessels when they are encountered, but not in advance.

Most urologists do not perform HoLEP because it is a technically difficult procedure with a steep learning curve. Furthermore, there is an additional learning curve during transition from small to moderate glands to a larger prostate [3]. Bloodless removal of prostatic adenomas may overcome the steep learning curve for beginners or surgeons without proper training and experience. Understanding the distribution of vessels and predict-

ing the location of bleeders facilitate excellent hemostasis. The shift from open to endoscopic surgery presents a completely new experience for surgeons in terms of the view of the surgical anatomy, and thus requires acquiring new anatomical knowledge besides learning the new operative procedure [17].

We found that the prostate volume is associated with the number of bleeders. Larger prostates have an increased surface area of the prostatic capsule and need more blood supply with increased vascular density. Achieving hemostasis is more challenging in patients with larger prostates despite the hemostatic efficiency of the laser [6]. Shah et al. [18] reported that the decrease in hemoglobin level after HoLEP was greater in patients with a large prostate than in those with a smaller prostate. Intraoperative bleeding, which results in higher transfusion rates, represents a clinically significant adverse outcome that is proportional to prostate volume during open prostatectomy [19]. Robot-assisted laparoscopic prostatectomy has also been reported to result in significantly greater estimated blood loss and transfusion rates in patients with large prostates, especially >75 g [20]. However, the number of bleeders was not correlated with the PSA level, and we did not discover any difference in artery distribution according to prostate volume. Although there is a previous report about the impact of prostate cancer on hemostasis [21], preoperative biopsy and postoperative pathologic findings were not significantly associated with the number and distribution of the bleeders in our study.

In our study, no pronounced advantages of using 5-ARIs for bleeding vessels were found. Several studies involving the use of 5-ARIs have shown decreased prostatic bleeding in patients with BPH and those undergoing BPH-related surgery [22]. Decreased prostatic bleeding is caused directly by decreasing intraprostatic 5- $\alpha$ -dihydrotestosterone levels, which in turn results in decreased stromal cell hypertrophy, suburethral vascular endothelial growth factor expression, and angiogenesis [23]. Some reports suggested that 5-ARIs may only affect microvessel density [22,23] and vascular endothelial growth factor expression [24] at the suburethral level, but not at the hyperplastic prostate level. The 5-ARIs may have little effect on significant bleeding vessels because these drugs only decrease microvessel density in the suburethral region, with little if any effect on the deeper hyperplastic prostate tissues [25]. The grossly visible perforating creeping vessels that bleed during dissection of adenomas cannot be significantly reduced with 5-ARI use alone.

The major strengths of this study include the prospective data collection, the performance of all operations by a single surgeon

who is already skilled in HoLEP, and the consecutive enrollment of the patients. One of the limitations of this study is that the design was retrospective; however, the use of video reviews represents an advantage. We did not intentionally coagulate vessels at specific sites; thus, the impact of significant bleeders could be determined. Another limitation of this study was the possibility of incorrectly determining the direction and level of the bleeders. The location of the bleeders was marked according to the subjective judgment of the reviewer; however, the effect was thought to be minimal because the two reviewers are sufficiently experienced. In addition, the two reviewers double-checked the locations and grades of the bleeders. In case of disagreements, a consensus was reached after a discussion between the two reviewers.

In conclusion, the most common locations of significant bleeders during HoLEP are the 3–4 and 8–9 o'clock positions in the proximal prostate. A cautious approach to these locations can help predict arterial bleeders and facilitate hemostasis. Prostatic volume is the most significant risk factor for predicting the number of arterial bleeders. Therefore, while performing HoLEP, especially in larger adenomas, careful manipulation is necessary when approaching the capsular plane of the proximal prostate.

## CONFLICT OF INTEREST

No potential conflict of interest relevant to this article was reported.

## REFERENCES

1. Gilling PJ, Kennett K, Das AK, Thompson D, Fraundorfer MR. Holmium laser enucleation of the prostate (HoLEP) combined with transurethral tissue morcellation: an update on the early clinical experience. *J Endourol* 1998;12:457-9.
2. Osterberg EC, Choi BB. Review of current laser therapies for the treatment of benign prostatic hyperplasia. *Korean J Urol* 2013;54: 351-8.
3. Shah HN, Mahajan AP, Sodha HS, Hegde S, Mohile PD, Bansal MB. Prospective evaluation of the learning curve for holmium laser enucleation of the prostate. *J Urol* 2007;177:1468-74.
4. Netsch C, Bach T, Herrmann TR, Neubauer O, Gross AJ. Evaluation of the learning curve for Thulium Vapo Enucleation of the prostate (ThuVEP) using a mentor-based approach. *World J Urol* 2013; 31:1231-8.
5. Barski D, Richter M, Winter C, Arsov C, de Geeter P, Rabenalt R, et

- al. Holmium laser ablation of the prostate (HoLAP): intermediate-term results of 144 patients. *World J Urol* 2013;31:1253-9.
6. Martin AD, Nunez RN, Humphreys MR. Bleeding after holmium laser enucleation of the prostate: lessons learned the hard way. *BJU Int* 2011;107:433-7.
  7. Billhim T, Pisco JM, Furtado A, Casal D, Pais D, Pinheiro LC, et al. Prostatic arterial supply: demonstration by multirow detector angio CT and catheter angiography. *Eur Radiol* 2011;21:1119-26.
  8. Leventis AK, Shariat SF, Utsunomiya T, Slawin KM. Characteristics of normal prostate vascular anatomy as displayed by power Doppler. *Prostate* 2001;46:281-8.
  9. Hinman F. Atlas of urologic surgery. 2nd ed. Philadelphia: Saunders; 1998.
  10. Jeong CW, Oh JK, Cho MC, Bae JB, Oh SJ. Enucleation ratio efficacy might be a better predictor to assess learning curve of holmium laser enucleation of the prostate. *Int Braz J Urol* 2012;38:362-71.
  11. Bae J, Oh SJ, Paick JS. The learning curve for holmium laser enucleation of the prostate: a single-center experience. *Korean J Urol* 2010;51:688-93.
  12. Bae J, Choo M, Park JH, Oh JK, Paick JS, Oh SJ. Holmium laser enucleation of prostate for benign prostatic hyperplasia: seoul national university hospital experience. *Int Neurourol J* 2011;15:29-34.
  13. Duclos JM, Chanzy M, Alexandre JH. Prostatic vascularization. *Arch Anat Pathol (Paris)* 1972;20:355-8.
  14. Kim M, Lee HE, Oh SJ. Technical aspects of holmium laser enucleation of the prostate for benign prostatic hyperplasia. *Korean J Urol* 2013;54:570-9.
  15. Flocks RH. The arterial distribution within the prostate gland: its role in transurethral resection. *J Urol* 1937;37:524-48.
  16. Chung BI, Sommer G, Brooks JD. Anatomy of the lower urinary tract and male genitalia. In: Wein AJ, Kavoussi LR, Novick AC, Partin AW, Peters CA, editors. *Campbell-Walsh urology*. 10th ed. Philadelphia: Saunders; 2012. p. 33-70.
  17. Ficarra V, Novara G, Artibani W, Cestari A, Galfano A, Graefen M, et al. Retropubic, laparoscopic, and robot-assisted radical prostatectomy: a systematic review and cumulative analysis of comparative studies. *EurUrol* 2009;55:1037-63.
  18. Shah HN, Sodha HS, Kharodawala SJ, Khandkar AA, Hegde SS, Bansal MB. Influence of prostate size on the outcome of holmium laser enucleation of the prostate. *BJU Int* 2008;101:1536-41.
  19. Hsu EI, Hong EK, Lepor H. Influence of body weight and prostate volume on intraoperative, perioperative, and postoperative outcomes after radical retropubic prostatectomy. *Urology* 2003;61:601-6.
  20. Boczek J, Erturk E, Golijanin D, Madeb R, Patel H, Joseph JV. Impact of prostate size in robot-assisted radical prostatectomy. *J Endourol* 2007;21:184-8.
  21. Litt MR, Bell WR, Lepor HA. Disseminated intravascular coagulation in prostatic carcinoma reversed by ketoconazole. *JAMA* 1987;258:1361-2.
  22. Pareek G, Shevchuk M, Armenakas NA, Vasovic L, Hochberg DA, Basillote JB, et al. The effect of finasteride on the expression of vascular endothelial growth factor and microvessel density: a possible mechanism for decreased prostatic bleeding in treated patients. *J Urol* 2003;169:20-3.
  23. Hochberg DA, Basillote JB, Armenakas NA, Vasovic L, Shevchuk M, Pareek G, et al. Decreased suburethral prostatic microvessel density in finasteride treated prostates: a possible mechanism for reduced bleeding in benign prostatic hyperplasia. *J Urol* 2002;167:1731-3.
  24. McVary KT, Roehrborn CG, Avins AL, Barry MJ, Bruskewitz RC, Donnell RF, et al. Update on AUA guideline on the management of benign prostatic hyperplasia. *J Urol* 2011;185:1793-803.
  25. Strom KH, Gu X, Spaliviero M, Wong C. The effects of 5 $\alpha$ -reductase inhibition on benign prostatic hyperplasia treated by photoselective vaporization prostatectomy with the 120 Watt Green Light HPS laser system. *J Am Coll Surg* 2011;212:244-50.