



Expanding the role of fractional flow reserve derived from computed tomography (FFR_{CT}) for the non-invasive imaging of patients with coronary stents: rise of the machines?

Andrea Matteucci¹ · Gianluca Massaro² · Mamas A. Mamas³ · Giuseppe Biondi-Zoccai^{4,5}

Received: 7 March 2021 / Accepted: 31 March 2021 / Published online: 23 April 2021
© European Society of Radiology 2021

My washing machine overwhelms me with its options and its sophistication.

Uma Thurman

Coronary artery disease and multimodality imaging

Several non-invasive cardiovascular imaging modalities, such as echocardiography, cardiac magnetic resonance (CMR), positron emission tomography (PET), single-photon emission computed tomography (SPECT), and computed tomography (CT), are available for the diagnostic assessment of patients with or at risk of coronary artery disease (CAD). The choice of imaging modalities should be made by determining the best combination of tests with the least risk to the patient that are able to answer the specific clinical question posed. The

This comment refers to the article available at <https://doi.org/10.1007/s00330-021-07922-w>

✉ Giuseppe Biondi-Zoccai
giuseppe.biondizoccai@uniroma1.it

¹ Department of Experimental Medicine, Tor Vergata University of Rome, Rome, Italy

² Division of Cardiology, Tor Vergata University of Rome, Rome, Italy

³ Keele Cardiovascular Research Group, Centre for Prognosis Research, Institute for Primary Care and Health Sciences, Keele University, Keele, UK

⁴ Department of Medical-Surgical Sciences and Biotechnologies, Sapienza University of Rome, Corso della Repubblica 79, 04100 Latina, Italy

⁵ Mediterranea Cardiocentro, Napoli, Italy

concomitant presence of myocardial necrosis with myocardial ischemia, stunning, or hibernation can complicate the management of coronary lesions and often requires a multimodal imaging approach [1]. Coronary CT angiography (CCTA) has been recommended for the assessment and diagnosis of recent-onset chest pain of suspected cardiac origin. However, the high sensitivity of CCTA is typically counterbalanced by low specificity, resulting in a potential excess of invasive coronary angiographies (ICA). Further limitations are suboptimal imaging due to irregular heart-beat, calcification, and, most challenging, stent artefacts.

Fractional flow reserve derived from computed tomography

Recently, there is growing interest in CCTA-derived fractional flow reserve (FFR_{CT}), capitalizing on three-dimensional reconstruction and computational fluid dynamics (CFD). Compared to conventional approaches, FFR_{CT} has higher diagnostic accuracy than CCTA alone [2], and its use is associated with lower detection of lesion-free coronary arteries on invasive angiography, i.e. increased specificity [3]. Furthermore, functional assessment of coronary artery stenosis by FFR_{CT} based on state-of-the-art computation fluid dynamics (CFD) has shown a good correlation with invasive fractional flow reserve (FFR), but it is burdened by considerable processing time and is computationally demanding.

Most recently, machine learning (ML) applications, incorporating artificial intelligence tools, have been employed to calculate virtual FFR from CT images. Indeed, ML approaches may quickly analyze large amounts of data and make systems capable of learning automatically and adapting to new inputs, typically including a combination of pattern recognition and computational learning to derive FFR. Accordingly, ML-derived FFR_{CT} may yield diagnostic performance comparable to that obtained from CFD, as well as invasive FFR, especially in patients with de novo CAD and

limited calcifications [4]. Conversely, the role of FFR_{CT} , even obtained with ML algorithms, remains unclear in patients with prior PCI, given the challenges inherent in image acquisition and processing in stented coronary segments.

New developments after coronary stenting

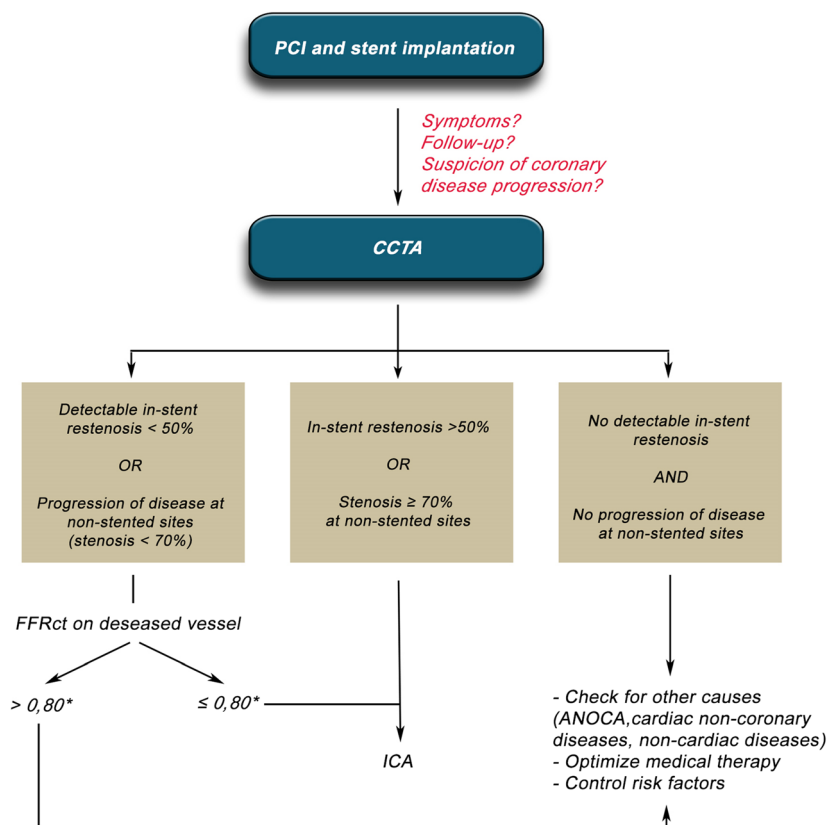
In this issue of European Radiology, a carefully conducted observational study investigated the feasibility and prognostic value in predicting cardiovascular adverse events of FFR_{CT} in patients with prior stent implantation [5]. The authors used a dedicated FFR_{CT} software based on a deep ML platform. To validate the use of FFR_{CT} , they retrospectively selected a cohort of 33 patients from the CHINA FFR_{CT} study with previous coronary stent implantation and with invasive FFR assessment and CCTA images at least 3 months after the index procedure [6]. They reported that FFR_{CT} had a good correlation with invasive FFR and an accuracy of 86% to detect hemodynamically significant in-stent restenosis. The authors then explored the role of ML-based FFR_{CT} in predicting major adverse cardiac events (MACE) in 115 patients with stented coronary

vessels and with baseline and follow-up CCTA. Statistical analysis with a supervised ML-approach (Lasso regression) and Cox proportional hazard model indicated age and follow-up $\Delta FFR_{CT}/\text{length}$ as the only two variables independently associated with MACE at follow-up. Given the low number of in-stent restenosis $\geq 50\%$ at CCTA, the authors however focused their model mainly on patients with low-to-moderate risk. Another limitation of this type of studies is the inability to action a post-procedure FFR_{CT} . For example, TARGET FFR showed that targets could be identified in over 40% of patients that had undergone a PCI procedure for further treatment. If we are to identify patients at high risk of future MACE events through FFR_{CT} , how are we to action this? Through further invasive management? Through more aggressive risk factor control? The study highlights many more such questions that pose uncertainty to the cardiovascular research community.

Where are we now?

To date, research has been intense on the feasibility and prognostic implications of FFR_{CT} in patients with suspected CAD.

Fig. 1 Clinical application of coronary CT angiography and FFR_{CT} for management of patients who underwent coronary stent implantation. CCTA = coronary CT angiography, FFR_{CT} = CCTA-derived fractional flow reserve, ANOCA = angina with no obstructive coronary artery disease



* The optimal cut-off value of FFR_{CT} for detecting significant CAD has not been yet adequately defined, although $FFR_{CT} \leq 0,80$ is empirically used as the cut-off for proceeding to invasive coronary angiography. For in-stent restenosis, other cut-off values can be considered (0,88 (Li et al. JACC Cardiovasc Interv 2017) or 0,86 (Agarwal et al. JACC Cardiovasc Interv 2016)). Further studies are needed for validation.

This is the first valid attempt to provide an answer even in patients with prior stent implantation. Upon these premises, we can propose a tentative approach at its implementation (Fig. 1), while concomitantly searching for optimal cutoff values for FFR_{CT}. The value of 0.75–0.80 has been validated to identify hemodynamically and prognostically significant CAD by FFR, but some studies have raised questions on the applicability of this threshold to FFR_{CT}. Matsumura-Nakano et al [7] found a modest correlation with invasive FFR, with a significant overestimation of hemodynamic significance, and identified a 0.71–0.80 grey zone. Whether the good correlation between invasive FFR and FFR_{CT} that emerges from this study is related to the different FFR_{CT} protocol used (ML vs CFD), to the different target (in-stent vs native vessel lesions), or to other factors needs to be demonstrated with further studies.

Where are we going?

These important insights pave the way for new applications of non-invasive coronary imaging. Interesting areas of research will be left main lesions, bifurcations, trifurcations, chronic total occlusions, and overlapping stents. Indeed, these lesions typically have a higher peri-procedural complication toll, and thus need stronger indications to motivate invasive management. Notably, left main lesions have already been studied with other imaging techniques, including intravascular ultrasound and SPECT, with favorable prognostic results [8]. Even myocardial bridges, commonly encountered with CCTA, may coexist with CAD and thus interact in the diagnostic and prognostic appraisal of patients [9]. We are hopeful that ML-based FFR_{CT} will prove its worth even in this complex yet prevalent setting.

Rise of the machines

Is this truly the era of the rise of the machines? We are probably not there yet, but clearly new technologies applied to various areas of research will prove extremely beneficial in the short and long term, as demonstrated by the recent experience with the COVID-19 pandemic. All this will dramatically reshape cardiovascular practice and the provision of healthcare in the future for all cardiovascular patients as well as practitioners.

Funding The authors state that this work has not received any funding.

Declarations

Conflict of interest The authors of this manuscript declare relationships with the following companies: Giuseppe Biondi-Zoccai has consulted for Cardionovum, Bonn, Germany, Innovheart, Milan, Italy, Meditrial, Rome, Italy, and Replycare, Rome, Italy.

Statistics and biometry No complex statistical methods were necessary for this paper.

Informed consent Written informed consent was not required for this study because it is an Editorial Comment

Ethical approval Institutional Review Board approval was not required because it is an Editorial Comment.

Methodology

• Editorial Comment

References

1. Nudi F, Iskandrian AE, Schillaci O et al (2020) Non-invasive cardiovascular imaging for myocardial necrosis, viability, stunning and hibernation: evidence from an umbrella review encompassing 12 systematic reviews, 286 studies, and 201,680 patients. *Minerva Cardioangiol.* <https://doi.org/10.23736/S0026-4725.20.05158-0>
2. Nørgaard BL, Leipsic J, Gaur S et al (2014) Diagnostic performance of noninvasive fractional flow reserve derived from coronary computed tomography angiography in suspected coronary artery disease: the NXT trial (Analysis of Coronary Blood Flow Using CT Angiography: Next Steps). *J Am Coll Cardiol* 63:1145–1155
3. Douglas PS, Pontone G, Hlatky MA et al (2015) Clinical outcomes of fractional flow reserve by computed tomographic angiography-guided diagnostic strategies vs. usual care in patients with suspected coronary artery disease: the prospective longitudinal trial of FFR(CT): outcome and resource impacts study. *Eur Heart J* 36:3359–3367
4. Nørgaard BL, Hjørt J, Gaur S et al (2017) Clinical use of coronary CTA-derived FFR for decision-making in stable CAD. *JACC Cardiovasc Imaging* 10:541–550
5. Tang CX, Guo BJ, Schoepf JU et al (2021) Feasibility and prognostic role of machine learning-based FFRCT in patients with stent implantation. *Eur Radiol.* <https://doi.org/10.1007/s00330-021-07922-w>
6. Tang CX, Liu CY, Lu MJ et al (2020) CT FFR for ischemia-specific CAD with a new computational fluid dynamics algorithm: a Chinese multicenter study. *JACC Cardiovasc Imaging* 13:980–990
7. Matsumura-Nakano Y, Kawaji T, Shiomi H et al (2019) Optimal cutoff value of fractional flow reserve derived from coronary computed tomography angiography for predicting hemodynamically significant coronary artery disease. *Circ Cardiovasc Imaging* 12: e008905
8. Nudi F, Nudi A, Neri G et al (2020) Myocardial perfusion imaging in patients with unprotected left main disease. *Minerva Cardioangiol.* <https://doi.org/10.23736/S0026-4725.20.05180-4>
9. La Grutta L, Malagò R, Toia P et al (2019) Clinical relevance of myocardial bridging detected by coronary CT angiography in patients with atypical chest pain. *Minerva Cardioangiol* 67:84–86

Publisher's note Springer Nature remains neutral with regard to jurisdictional claims in published maps and institutional affiliations.