


Delayed diagnosed Gradenigo's syndrome associated with acute otitis media

SAGE Open Medical Case Reports
Volume 8: 1–4
© The Author(s) 2020
Article reuse guidelines:
sagepub.com/journals-permissions
DOI: 10.1177/2050313X20966119
journals.sagepub.com/home/sco



Berat Demir¹ , Ghazi Abuzaid¹, Zeynep Ergenc²
and Eda Kepenekli²

Abstract

Gradenigo's syndrome presents as a triad of retroorbital pain, ipsilateral abducens palsy, and purulent otorrhea. If the otologic pathologies in Gradenigo's syndrome go unnoticed, the condition could be misdiagnosed with neurological diseases because of retroorbital pain and abducens palsy. Treatment of Gradenigo's syndrome remains controversial. Although some reports state that long-term antibiotic treatment is sufficient, we recommended that management ought to be guided on a case-by-case basis depending on patient and disease factors. Herein, we report a delayed diagnosed pediatric case of Gradenigo's syndrome associated with acute otitis media that was treated with ventilation tube insertion.

Keywords

Gradenigo's syndrome, petrous apicitis, abducens palsy, acute otitis media

Date received: 5 August 2020; accepted: 24 September 2020

Introduction

The occurrence of Gradenigo's¹ syndrome has decreased with the advent and use of antibiotics; clinically, the condition is characterized by the triad of deep retroorbital pain, ipsilateral abducens palsy, and purulent otorrhea caused by petrous apicitis. Although the disease is diagnosed with this triad, clinically, 13.6%–42.1% of patients with petrous apicitis present with the classical triad.² Although the incidence of Gradenigo's syndrome has decreased to 2 per 100,000, its treatment and management strategies remain unclear.³ Some clinicians prefer surgical intervention because of 2.3% patient mortality due to petrous apicitis.⁴ We present a case report of Gradenigo's syndrome as a complication of acute otitis media.

Case description

A 7-year-old boy was admitted to the pediatric emergency department because of high fever and ear pain. His medical history was unremarkable. Otoloscopic examination was not performed at admission. A neurological and full-system examination indicated no pathology. Routine laboratory blood tests indicated leukocytosis with neutrophilia and elevated C-reactive protein (CRP) levels. The patient was subsequently diagnosed with upper airway tract infection and

discharged with a prescription of oral amoxicillin. Twelve days later, the patient was referred to the pediatric emergency department with persistent fever, headache, right diplopia due to abducens nerve palsy, and right orbitofacial pain. Subsequent neurological examination showed no signs of any pathology. Ophthalmologic evaluation confirmed the presence of binocular horizontal diplopia, which was worse for distant objects, as well as concomitant strabismus with esotropia to the right side secondary to right abducens palsy. The patient was diagnosed with meningitis; he was hospitalized, and ceftriaxone (50 mg/kg/day per day) was given for 2 days. A cranial magnetic resonance imaging (MRI) was performed, which showed complete opacification and high signal in the mastoid air cells, middle ear, and petrous apex on

¹Department of Otorhinolaryngology-Head and Neck Surgery, Pendik Training and Research Hospital, Marmara University Medical Faculty, Istanbul, Turkey

²Division of Pediatric Infectious Diseases, Department of Pediatrics, Marmara University Pendik Training and Research Hospital, Istanbul, Turkey

Corresponding Author:

Berat Demir, Department of Otorhinolaryngology-Head and Neck Surgery, Pendik Training and Research Hospital, Marmara University Medical Faculty, Mimar Sinan Caddesi No. 41, Fevzi Cakmak Mahallesi, Ust Kaynarca-Pendik, 34899 Istanbul, Turkey.
Email: drberatdemir80@hotmail.com



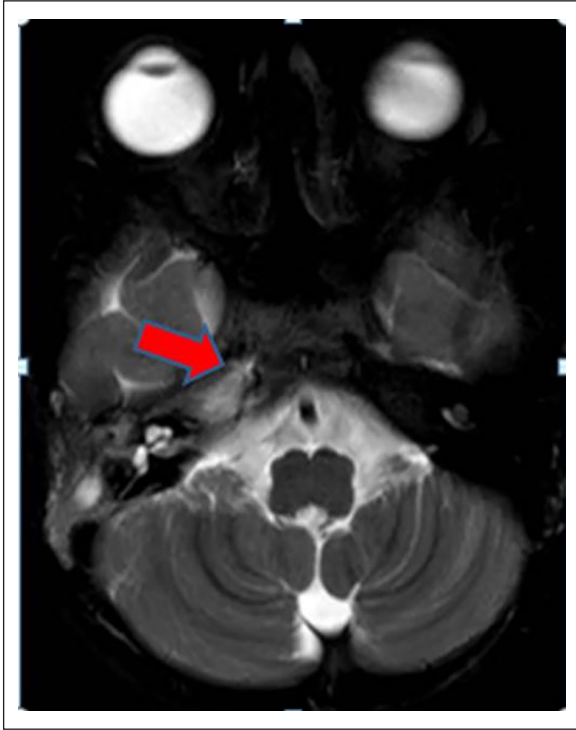

Figure 1. Axial T2 weighted MR image (before treatment) shows hyperintensity in right mastoid cells, middle ear and also petrous apex.

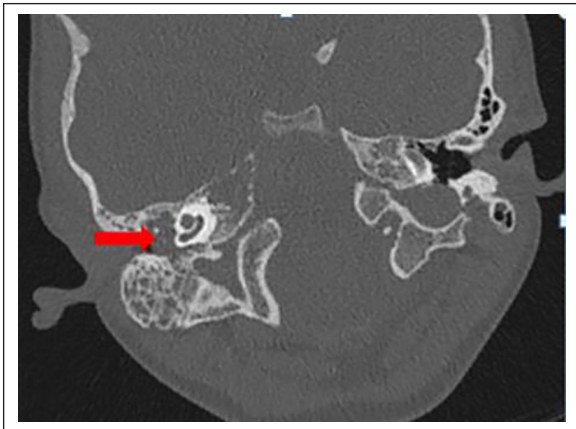


Figure 2. Coronal reformatted CT image (before treatment) shows hyperdensity in right mastoid cells, middle ear and petrous apex. Also destruction in petrous apex is seen.

T2 scans on the right side (Figure 1). Subsequently, the ear, nose, and throat department was consulted. Otoloscopic examination showed bulging of the right tympanic membrane without any tenderness in the retroauricular area and mastoid. Temporal computed tomography (CT) was performed, which showed complete opacification in the mastoid air cells and middle ear. In addition, the CT images showed erosion in the petrous apex indicative of petrous apicitis on the right

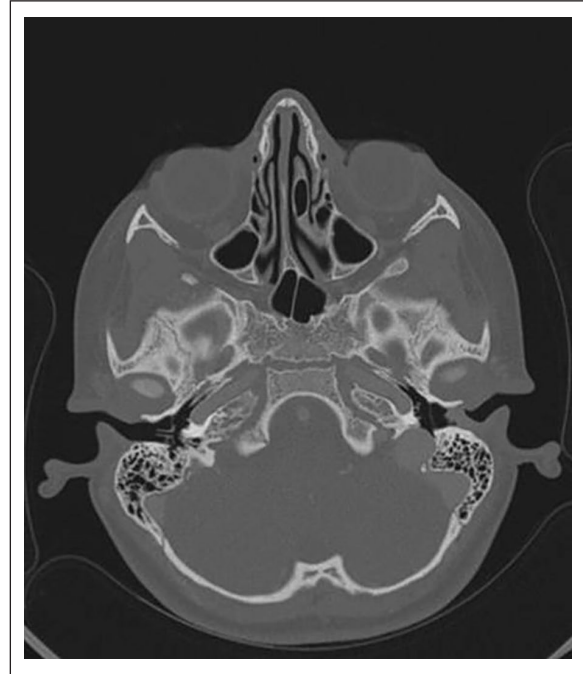

Figure 3. Axial CT image (after treatment) identifies complete resolution of the lesions in right ear and tympanostomy tube.

side (Figure 2). Concomitant right acute mastoiditis with petrositis, right orbitofacial pain, and right abducens palsy was indicative of Gradenigo's syndrome. Audiogram showed mild conductive hearing loss. A right myringotomy was performed and a ventilation tube was inserted with intravenous administration of cefoperazone + sulbactam sodium (3×800 mg/day) and vancomycin (4×240 mg/day) for 2 weeks, which was followed by oral amoxicillin/clavulanate therapy. Middle ear fluid aspirate culture grew no pathogen. On postoperative day 2, the patient's fever, pain, and abducens nerve palsy improved dramatically. On postoperative day 4, he had no pain or symptom of abducens palsy, but the right diplopia for distant targets persisted. Simultaneously, laboratory tests showed no abnormality in white blood cell count and CRP level. On postoperative day 7, his diplopia resolved completely and the tympanic membrane showed improvement. Follow-up CT scans performed after the intravenous therapy showed improvement of the right mastoiditis and edema at the apex (Figure 3). At 2 weeks postoperatively, the patient was discharged with further recommendations for monthly ophthalmologic follow-up. It has been 2 months since the disease and there was no problem in follow-up. Informed consent was obtained from the parents for the use and publication of his data.

Discussion

Approximately 85% of children experience at least one attack of acute otitis media in their lifetime.³ Spread of the

infection from the middle ear to the petrous apex affects the abducens nerve through the Dorello's canal, as well as the branches of the trigeminal nerve through the Meckel's cave. Retroorbital pain is a result of the involvement of the trigeminal nerve, and horizontal diplopia may occur with involvement of the abducens nerve, which innervates the lateral rectus muscle.⁵ Both CT and MRI play crucial role in the diagnosis of petrous apicitis.⁴ CT can help to determine the bone structure, while MRI can identify the cranial involvement. Although inflammatory pseudotumor, sarcoidosis, tuberculosis, intracranial abscess, lateral sinus thrombosis, Tolosa-Hunt syndrome, and malignancy have been reported as the differential diagnoses of petrous apicitis,² neurological diseases should also be considered in the differential diagnosis because of retroorbital pain and abducens palsy when ear examination is not performed, such as in our case.

Approximately 30% of cases have pneumatized petrous apex,⁶ and petrous apicitis is rare in patients with otitis media. Owing to its high mortality rate, treatment of petrous apicitis is critical. However, an optimal treatment protocol is still lacking. Although some authors recommend surgery, some have advocated the use of antibiotic therapy. Chole and Donald,⁶ and Bozan et al.⁷ advocated radical surgery. However, most studies have reported antibiotic therapy as the acceptable first-line treatment for Gradenigo's syndrome.^{2,4,5,8} The petrous apex is a hard-to-reach area surgically. Considering both the difficulties and complications associated with surgery, it seems more feasible to avoid complicated surgery as the first-line treatment. However, in this patient, we inserted a ventilation tube with intravenous administration of board-spectrum antibiotics. The combination of medical and surgical treatment dramatically improved all signs and symptoms. Insertion of a ventilation tube is less invasive procedure and without any adverse effects. Clinically, the patient showed dramatic improvement of fever, pain, and abducens palsy. Although recovery was achieved with long-term antibiotic therapy, a simple surgical intervention shortened the recovery time. Leakage of cerebrospinal fluid, cerebral edema, increased intracranial pressure, pneumocephalus, and seizures are the possible complications of surgery.² In view of these complications, ventilation tube insertion is less invasive procedure. Moreover, surgical drainage of the mastoid or the insertion of a ventilation tube is recommended in selected cases unresponsive to conservative management.⁴ We therefore recommend surgery for petrous apicitis cases refractory to medical treatment, but we recommend that this surgery be less invasive such as ventilation tube application. If simple surgical interventions such as ventilation tube application are ineffective, complicated surgeries may be considered. Surgical approaches, including the translabyrinthine and transcochlear approaches, are particularly useful to reach the petrous apex but destroy the cochlea. In patients with pre-existing deafness, the risks posed by access to the petrous apex are relatively less than those without

pre-existing deafness, due to the surgical risk of cochlear damage. Infracochlear, infralabyrinthine, retrolabyrinthine, middle fossa, and subarcuate approaches preserve hearing. However, in patients with petrous apicitis, the surgical approach may vary depending on the degree of the patient's hearing loss, anatomy, and the surgeon's experience.

It is very important to start empirical antibiotic treatment at the earliest clinical suspicion of petrous apex involvement. *Streptococcus pneumoniae*, beta hemolytic *Streptococci*, *Staphylococcus* spp., *Haemophilus influenzae*, *Pseudomonas* spp., *Moraxella catarrhalis*, and various anaerobes are known to cause otitis media.^{2,4} In our patient, although the aspirate from the ventilation tube insert was cultured, the results were negative. Gadre and Chole⁴ reported 15 positive cases on examination of 44 patients. In empirical antibiotic treatment, a 6-week regimen of vancomycin and metronidazole in combination with ceftriaxone is preferred.⁴ In our patient, we used cefoperazone, as well as a third-generation cephalosporin, such as ceftriaxone, along with sulbactam and vancomycin for 6 weeks.

Conclusion

Gradenigo's syndrome rarely occurs in the postmodern antibiotic era. Otolaryngologic examination must be performed in patients who are admitted to the emergency department with fever.

In children with pathology on ear examination, petrous apicitis should be considered if the symptoms accompany neurological findings. Management ought to be guided on a case-by-case basis depending on patient and disease factors.

Declaration of conflicting interests

The author(s) declared no potential conflicts of interest with respect to the research, authorship, and/or publication of this article.

Funding

The author(s) received no financial support for the research, authorship, and/or publication of this article.

Ethical approval

Our institution does not require ethical approval for reporting individual cases or case series.

Informed consent

Written informed consent was obtained from the patient(s) parents for their anonymized information to be published in this article.

ORCID iD

Berat Demir  <https://orcid.org/0000-0002-8574-4927>

References

1. Gradenigo G. Über circumscribte Leptomeningitis mit spinalen Symptomen und über Paralyse des N. abducens otitischen Ursprungs. *Archiv für Ohrenheilkunde* 1904; 62: 255–270.

2. Rossi N, Swonke ML, Reichert L, et al. Gradenigo's syndrome in a four-year-old patient: a rare diagnosis in the modern antibiotic era. *J Laryngol Otol* 2019; 133(6): 535–537.
3. Goldstein NA, Casselbrant ML, Bluestone CD, et al. Intratemporal complications of acute otitis media in infants and children. *Otolaryngol Head Neck Surg* 1998; 119(5): 444–454.
4. Gadre AK and Chole RA. The changing face of petrous apicitis—a 40-year experience. *Laryngoscope* 2018; 128(1): 195–201.
5. Ozkacmaz S. Acute otitis media associated with Gradenigo syndrome and transverse sinus thrombosis: a case report. *J Int Med Res* 2019; 47(3): 1348–1352.
6. Chole RA and Donald PJ. Petrous apicitis. Clinical considerations. *Ann Otol Rhinol Laryngol* 1983; 92: 544–551.
7. Bozan N, Duzenli U, Yalinkilic A, et al. Gradenigo syndrome induced by suppurative otitis media. *J Craniofac Surg* 2018; 29(7): e645–e646.
8. Choi KY and Park SK. Petrositis with bilateral abducens nerve palsies complicated by acute otitis media. *Clin Exp Otorhinolaryngol* 2014; 7(1): 59–62.