

# Acute Primary Epiphyseal Osteomyelitis of Proximal Tibia - A Case Report and Review of the Literature

Lakshmana Das<sup>1</sup>, Tarun Goyal<sup>1</sup>, Souvik Paul<sup>1</sup>, Tushar Gupta<sup>1</sup>

## Learning Point of the Article:

Despite being a rarely reported entity, acute primary epiphyseal osteomyelitis warrants high suspicion and early diagnosis to prevent dreaded long term complications.

## Abstract

**Introduction:** Acute pyogenic epiphyseal osteomyelitis is a rare condition, mostly affecting children. This case report discusses the importance of clinical suspicion and the role of adjuncts in the diagnosis of these cases.

**Case Presentation:** A 12-year-old female presented with pain in the right knee for 1 week and difficulty in walking for 4 days. Diagnosis was made with the help of magnetic resonance imaging MRI and guided biopsy. *Pseudomonas aeruginosa* was isolated from culture. She was treated with intravenous antibiotics with a good response.

**Discussion:** Despite being a rarely reported entity, primary epiphyseal osteomyelitis should be kept as one of the differentials of the painful swollen knee in a child. Early diagnosis with the help of proper radiological investigations is the key to prevent the sequelae of this disease.

**Keywords:** Epiphyseal osteomyelitis, *Pseudomonas aeruginosa*, tibia, children, epiphysitis, pyogenic osteomyelitis.

## Introduction

Acute hematogenous osteomyelitis is common in children. It most commonly affects the metaphysis of long bones and typical clinical presentation makes diagnosis difficult to miss [1]. Primary osteomyelitis involving the epiphysis is rare, and the presentation is often atypical and vague, which may lead to missed or delayed diagnosis [2]. If treated appropriately, it usually follows a benign course in an otherwise healthy child. An acute or subacute form can set in regardless of age [3, 4]. Cases of epiphyseal osteomyelitis have previously been reported in the distal femur, proximal tibia, proximal femur, and proximal radius [5, 6, 7, 8, 9, 10]. We present a rare case of acute primary epiphyseal osteomyelitis of proximal tibia caused by *Pseudomonas aeruginosa* in a 12-year-old female with a review of the literature and various diagnostic modalities helpful in establishing an early diagnosis.

## Case Report

A 12-year-old female presented to the outpatient department with pain in the right knee for 1 week and difficulty bearing weight for the past 4 days. The pain was insidious in onset without any preceding trauma and was aggravated with weight-bearing and knee bending. She had no constitutional symptoms. The child's body mass index was 19.2 kg/m<sup>2</sup>, height was between the 3rd and 10th centile, and her weight fell in 25–50th centile as per the revised Indian Academy of Pediatrics growth charts [11]. On clinical evaluation, the child was hemodynamically stable and afebrile. There was diffuse swelling over the right knee and local temperature was elevated. Marked tenderness was present over the lateral joint line and lateral tibial plateau. Knee movements were painful and restricted and a flexion deformity of 10 degrees was noted. There was no effusion in the knee joint. Her initial knee radiograph was normal (Fig. 1). Laboratory work-up showed a total leukocyte count of 12,700/mm<sup>3</sup> with a

Access this article online

Website:  
www.jocr.co.in

DOI:  
10.13107/jocr.2021.v11.i12.2564

## Author's Photo Gallery



Dr. Lakshmana Das



Dr. Tarun Goyal



Dr. Souvik Paul



Dr. Tushar Gupta

<sup>1</sup>Department of Orthopaedics, All India Institute of Medical Sciences, Rishikesh, Uttarakhand, India.

### Address of Correspondence:

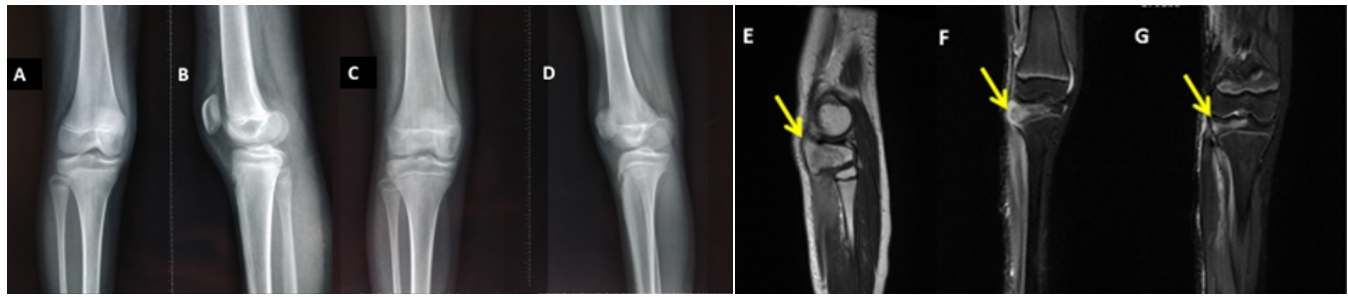
Dr. Souvik Paul,  
Department of Orthopaedics, All India Institute of Medical Sciences, Rishikesh, Uttarakhand, India.  
E-mail: 1990.souvik@gmail.com

Submitted: 03/09/2021; Review: 16/10/2021; Accepted: November 2021; Published: December 2021

DOI:10.13107/jocr.2021.v11.i12.2564

This is an open access journal, and articles are distributed under the terms of the Creative Commons Attribution-NonCommercial-ShareAlike 4.0 License <https://creativecommons.org/licenses/by-nc-sa/4.0/>, which allows others to remix, tweak, and build upon the work non-commercially, as long as appropriate credit is given and the new creations are licensed under the identical terms





**Figure 1:** (a and b) Apparently normal radiograph at the time of presentation, (c and d) radiograph at 2-year follow-up, and (e-g) hyperintensities in T2/STIR images in the epiphysis of proximal tibia with diffuse post-contrast enhancement (f and g) in pre-operative magnetic resonance imaging.

neutrophilic predominance, erythrocyte sedimentation rate of 29 mm3, and C-reactive protein of 5.28. Her serum Vitamin D was 12.3 ng/dl and other blood metabolic parameters such as liver and renal functional tests, serum calcium, phosphate, and alkaline phosphatase were normal. She was seronegative for HIV. Magnetic resonance imaging (MRI) showed hyperintensities in T2/STIR images in the epiphysis of the proximal tibia, more marked on the lateral aspect. There was a diffuse post-contrast enhancement, suggestive of edema (Fig. 1). Otherwise, the knee joint was unremarkable with no effusion or synovial hypertrophy. No local pus collection could be appreciated along the tibia. Ultrasonography-guided biopsy from the lateral tibial epiphysis was done and samples were sent for histopathological and microbiological examinations. Histopathological examination showed dense inflammatory infiltrate comprising neutrophils and lymphocytes, without any atypical or malignant cells. After 48 h of incubation, *P. aeruginosa* was isolated in the aerobic culture. Diagnosis of pyogenic proximal tibial epiphysitis was made. She was immobilized in an above knee POP slab and started on supportive measures including pain relief and nutritional care. No empirical antibiotic therapy was started. Culture-specific antibiotic treatment was started according to the antibiogram (intravenous ceftazidime 1000 mg thrice daily for 3 weeks followed by oral faropenem 200 mg twice daily for 3 weeks). Inflammatory markers were monitored at regular intervals. After 1 week of initiation of intravenous antibiotics, she improved clinically and inflammatory markers showed a decreasing trend. C-reactive protein was 2.0 and 1.7 at day 7 and 14 of treatment with antibiotics, respectively. She was completely pain free on day 12 and was started on passive knee range of motion, isometric quadriceps strengthening exercises, and partial weight-bearing with support. She attained a full painless range of motion (0–145 degrees) on day 20 and was allowed full weight-bearing without support. At 24 months follow-up, the child was active with knee range of motion 0–140 degrees of flexion and normal plain radiograph (Fig. 1). No local growth disturbance was noted.

## Discussion

The estimated incidence of acute primary pyogenic osteomyelitis is 0.5–1 in 5000 cases [1]. However, the incidence is constantly increasing due to more virulent organisms and better diagnostic modalities. Primary pyogenic osteomyelitis usually involves the metaphysis of long bones [2, 3] and various hypotheses have been proposed for the same in the literature. However, the isolated involvement of epiphysis is rare.

Only a few cases have been reported in the literature so far (Table 1). Primary epiphyseal osteomyelitis was thought to be most commonly affecting children <3 years [12] but it can involve any age. The predisposing factors are poor host immunity, malnutrition, and overcrowding. The predominant site being the distal femur or proximal tibia (Table 1). The most common isolated organism being *Staphylococcus aureus* [2]. *P. aeruginosa* has been reported in few cases of metaphyseal osteomyelitis in adults mostly as nosocomial or chronic infection [13], but this reports a unique case of primary acute pyogenic epiphyseal osteomyelitis due to community-acquired *P. aeruginosa* infection in an otherwise healthy child. The usual presentation is with only mild-to-moderate local signs and symptoms and minimal or absent systemic manifestation which makes the diagnosis difficult [14]. Febrile episodes are seen only in 60–66% of children [15]. Long-term prognosis is highly favorable without any growth arrest if timely managed, although a delayed diagnosis can result in septic arthritis and destruction of growth plate [16]. MRI is more sensitive in diagnosing and localizing the site and extent of the lesion in primary epiphyseal osteomyelitis (sensitivity: 85–100% and specificity: 75–100%) with the earliest changes detected as early as 2–5 days following the onset of symptoms [17]. However, infection and inflammation cannot be differentiated. Nuclear imaging techniques such as three-phase bone scanning (sensitivity – 85–92% and specificity – 54–87%), gallium-67 citrate scanning (sensitivity – 81–100% and specificity – 40%), and indium 111 labeled leukocytes scintigraphy (sensitivity – 100%, specificity – 70–95%, and accuracy – 86%) are also helpful. False-negative bone scans are obtained if performed in early course of infection

due to increase in medullary pressure in the lesion and in neonates [18, 19, 20]. Nuclear imaging techniques are also helpful in multifocal disease. Higher sensitivity and specificity of MRI in the early diagnosis of acute epiphyseal osteomyelitis makes it the imaging modality of choice. Ultrasonography is sensitive in detecting joint effusion and can obtain guided

specimen from the epiphysis, without exposure to radiation. Bone biopsies and aspirates are culture positive in 31–83% of the cases, so negative growth does not rule out infection [21]. The mainstay in the treatment of primary pyogenic epiphyseal osteomyelitis is timely diagnosis and initiation of antibiotics according to the antibiogram [22]. Most cases respond to the

**Table 1:** A literature review of articles describing acute pyogenic epiphyseal osteomyelitis

S. No.	Author	Year	No. of cases	Age	Site	Symptom duration	Plain radiograph	Culture	Management	Follow-up	Outcome
1	Hwang et al.	2016	1	12 years	Distal tibia	9 days	Lytic lesion	Joint fluid and tissue – S. aureus	1. Arthroscopic debridement followed by open debridement curettage and irrigation. 2. IV antibiotics for 3 weeks followed by oral antibiotics	18 months	Normal
2	Green et al.	1981	8 (5)	2–4 years	Proximal tibia-2, Distal femur-2, Proximal femur-1.	N/A	N/A	N/A	1. Curettage and irrigation 2. Antibiotics	N/A	N/A
3	Rosenbaum and Blumhagen	1985	9 (7)	21 months–9 years	Distal femur-6, Proximal tibia-1, Proximal humerus-1.	1–28 days	Lytic lesion	Blood culture- 1 case positive for S. pneumoniae 2)Tissue culture-2 positives (1 – S. aureus, 2 – H. influenza)	1. Arthrocentesis-5 cases 2. IV antibiotics followed by oral antibiotics	N/A	N/A
4	Abdelgawad et al.	2007	1	17 months	Distal femur	6 days	Normal	1. Blood – negative. 2. Tissue culture– Salmonella Typhi B	1. Fluoroscopy-guided abscess drainage – thrice done 2. IV antibiotics for 4 weeks	N/A	Normal
5	Sorensen et al.	1988	3	20 months	Proximal tibia	14 days	Lytic lesion	Tissue culture – negative	1. Curettage and bone grafting 2. IV antibiotics for 10 days	9 months	Normal
				2 years 4 months	Proximal tibia	14 days	Lytic lesion	Tissue culture – negative	1. Curettage and bone grafting 2. No antibiotics	9 years	Partial epiphysiod esis
				4 years	Distal femur	7 days	Lytic lesion	Tissue culture – S. aureus	1. Curettage and bone grafting 2. IV antibiotics for 5 months	3 years	Normal
6	Rasool	2001	2	2–12 year, Mean-7.5 years	Proximal and distal femur	Mean-2 weeks–3 months	Lytic lesion	N/A	1. Fluoroscopic guided extra-articular biopsy and curettage 2. IV antibiotics for 4–5 days followed by oral antibiotics for 6 weeks 3. Immobilization for 4–6 weeks	Mean 2.4 years	Normal
7	Maffulli and Fixsen	1990	1	6 years	Proximal radius. (Epiphysitis with septic arthritis)	2 months	Lytic lesion	Tissue culture – negative	1. Curettage and irrigation 2. IV antibiotics for 1 week and oral antibiotics for 6 weeks	10 months	Normal (Reossification of radial head)
8	Longjohn et al.	1995	2	4 years 2 months	Lateral femoral epiphysis	2 weeks	Lytic lesion	Blood culture – S. aureus. Tissue culture – S. aureus	1. Curettage and irrigation 2. IV antibiotics for 4 weeks and oral antibiotics for 10 days	6 years	Normal
				23 months	Proximal tibial epiphysis	3 days	Lytic lesion	Blood and tissue culture – no growth	1. Fluoroscopy-guided aspiration 2. IV antibiotics for 3 weeks and oral antibiotics for 3 weeks	2 years	Normal
9	Kramer et al.	1986	1	11 years	N/A	6 days	N/A	Blood culture – Neg Joint fluid – S. aureus	N/A	N/A	N/A
10	Kao et al.	2003	2	28 months	Distal femur	10 days	Lytic lesion	Blood and joint aspirate – Neg Tissue – Salmonella enteritidis	1. Curettage 2. IV antibiotics for 5 weeks	16 months	Normal
				27 months	Distal femur	2 months	Radiolucen t lesion	Blood culture – S. aureus Joint aspirate – negative	1. Arthrotomy and curettage 2. IV antibiotics for 10 weeks	6 months	Normal

Footnote: The numbers mentioned in brackets are the actual number of cases of isolated epiphysitis, Neg: Negative, N/A: Not available, S. aureus: Staphylococcus aureus



antibiotics but if there is no response to antibiotic treatment, surgical intervention is indicated in the form of curettage, aspiration, and debridement.

### Conclusion

Despite being a rarely reported entity, primary epiphyseal osteomyelitis should be kept as one of the differentials of the painful swollen knee in a child. Early diagnosis with the help of proper radiological investigations is the key to prevent sequelae of this disease.

**Declaration of patient consent :** The authors certify that they have obtained all appropriate patient consent forms. In the form, the patient's parents have given their consent for patient images and other clinical information to be reported in the journal. The patient's parents understand that his names and initials will not be published and due efforts will be made to conceal their identity, but anonymity cannot be guaranteed.

**Conflict of interest:** Nil **Source of support:** None

### Clinical Message

Although historically primary epiphyseal osteomyelitis ran a benign course, soon it may follow a more aggressive course due to increased virulence and antibiotic resistance in organisms. Therefore, high suspicion of infection is warranted and diagnostic modalities should be appropriately used without sticking to a single modality. Early diagnosis and initiation of treatment prevent long-term sequelae and crippling.

### References

- Hwang HJ, Jeong WK, Lee DH, Lee SH. Acute primary hematogenous osteomyelitis in the epiphysis of the distal tibia: A case report with review of the literature. *J Foot Ankle Surg* 2016;55:600-4.
- Green NE, Beauchamp RD, Griffin PP. Primary subacute epiphyseal osteomyelitis. *J Bone Joint Surg Am* 1981;63:107-14.
- Rosenbaum DM, Blumhagen JD. Acute epiphyseal osteomyelitis in children. *Radiology* 1985;156:89-92.
- Abdelgawad AA, Rybak LD, Sheth M, Rabinowitz SS, Jayaram N, Sala DA, et al. Treatment of acute salmonella epiphyseal osteomyelitis using computed tomography-guided drainage in a child without sickle cell disease. *J Pediatr Orthop B* 2007;16:415-8.
- Sorensen TS, Hedeboe J, Christensen ER. Primary epiphyseal osteomyelitis in children: Report of three cases and review of the literature. *J Bone Joint Surg Br* 1988;70:818-20.
- Rasool MN. Primary subacute haematogenous osteomyelitis in children. *J Bone Joint Surg Br* 2001;83:93-8.
- Maffulli N, Fixsen JA. Osteomyelitis of the proximal radial epiphysis: A case report. *Acta Orthop Scand* 1990;61:269-70.
- Longjohn DB, Zions LE, Stott NS. Acute hematogenous osteomyelitis of the epiphysis. *Clin Orthop Relat Res* 1995;316:227-34.
- Kramer SJ, Post J, Sussman M. Acute hematogenous osteomyelitis of the epiphysis. *J Pediatr Orthop* 1986;6:493-5.
- Kao FC, Lee ZL, Kao HC, Hung SS, Huang YC. Acute primary hematogenous osteomyelitis of the epiphysis: Report of two cases. *Chang Gung Med J* 2003;26:851-6.
- Khadilkar VV, Khadilkar AV. Revised Indian academy of pediatrics 2015 growth charts for height, weight and body mass index for 5-18-year-old Indian children. *Indian J Endocr Metab* 2015;19:470-6.
- Weichert S, Sharland M, Clarke NM, Faust SN. Acute haematogenous osteomyelitis in children: Is there any evidence for how long we should treat? *Curr Opin Infect Dis* 2008;21:258-62.
- Schmitt SK. Osteomyelitis. *Infect Dis Clin North Am* 2017;31:325-38.
- Rang M. The growth plate and its disorders. *Br J Surg* 1969;56:478-8.
- Dartnell J, Ramachandran M, Katchburian M. Haematogenous acute and subacute paediatric osteomyelitis: A systemic review of the literature. *J Bone Joint Surg Br* 2012;94:584-95.
- Morrissy RT, Haynes DW. Acute hematogenous osteomyelitis: A model with trauma as an etiology. *J Pediatr Orthop* 1989;9:447-56.
- Chiappini E, Mastrangelo G, Lazzeri S. A case of acute osteomyelitis: An update on diagnosis and treatment. *Int J Environ Res Public Health* 2016;13:539.
- Connolly LP, Connolly SA, Drubach LA, Jaramillo D, Treves ST. Acute hematogenous osteomyelitis of children: Assessment of skeletal scintigraphy-based diagnosis in the era of MRI. *J Nucl Med* 2002;43:1310-6.
- Johnson JE, Kennedy EJ, Shereff MJ, Patel NC, Collier BD. Prospective study of bone, indium-111-labeled white blood cell, and gallium-67 scanning for the evaluation of osteomyelitis in the diabetic foot. *Foot Ankle Int* 1996;17:10-6.
- Schauwecker DS, Park HM, Mock BH, Burt RW, Kernick CB, Ruoff AC 3rd, et al. Evaluation of complicating osteomyelitis with Tc-99m MDP, In-111 granulocytes, and Ga-67 citrate. *J Nucl Med* 1984;25:849-53.
- Manche E, Rombouts-Godin V, Rombouts JJ. Acute hematogenous osteomyelitis due to ordinary germs in children with closed injuries. Study of a series of 44 cases. *Acta Orthop Belg* 1991;57:91-6.
- Paakkonen M, Kallio MJ, Lankinen P, Peltola H, Kallio PE. Preceding trauma in childhood hematogenous bone and joint infections. *J Pediatr Orthop B* 2014;23:196-9.



**Conflict of Interest:** Nil

**Source of Support:** Nil

**Consent:** The authors confirm that informed consent was obtained from the patient for publication of this case report

#### How to Cite this Article

Das L, Goyal T, Paul S, Gupta T. Acute Primary Epiphyseal Osteomyelitis of Proximal Tibia – A Case Report and Review of the Literature. Journal of Orthopaedic Case Reports 2021 December;11(12):52-56.

