

Comparison of mastoid air cell volume in patients with or without a pneumatized articular tubercle

Mehmet Zahit Adışen¹, Merve Aydoğdu^{1,*}

¹Department of Oral and Maxillofacial Radiology, Faculty of Dentistry, Kirikkale University, Kirikkale, Turkey

ABSTRACT

Purpose: The aim of this study was to compare mastoid air cell volumes in patients with or without a pneumatized articular tubercle (PAT) on cone-beam computed tomography (CBCT) images.

Materials and Methods: The CBCT images of 224 patients were retrospectively analyzed for the presence of PAT. The Digital Imaging and Communications in Medicine data of 30 patients with PAT and 30 individuals without PAT were transferred to 3D Doctor Software. Mastoid air cell volumes were measured using semi-automatic segmentation on axial sections. Data were analyzed using SPSS version 20.0.

Results: The patients with PAT and those without PAT had a mean mastoid volume of $6.31 \pm 2.86 \text{ cm}^3$ and $3.25 \pm 1.99 \text{ cm}^3$, respectively. There were statistically significant differences in mastoid air cell volumes between patients with and without PAT regardless of sex and mastoid air cell side ($P < 0.05$).

Conclusion: The detection of PAT on routine dental radiographic examinations might be a potential prognostic factor that could be used to detect extensive pneumatization in the temporal bone. Clinicians should be aware that there may be widespread pneumatization of mastoid air cells in patients in whom PAT is detected. Advanced imaging should be performed in these cases, and possible complications due to surgical interventions should be considered. (*Imaging Sci Dent* 2022; 52: 27-32)

KEY WORDS: Cone beam computed tomography; Mastoid/diagnostic imaging; Temporal bone/anatomy & histology; Imaging, Three-Dimensional/methods

Introduction

Pneumatization refers to the development of air-filled cavities in bone. These accessory air cells, which are common in paranasal sinuses, are observed in many bones, including the temporal bone.¹ The presence of air cells in the zygomatic extension of the temporal bone is referred to as a zygomatic air cell defect or a pneumatized articular tubercle (PAT).² PAT is defined as an asymptomatic radiolucent defect that does not extend beyond the zygomatico-temporal suture and is not associated with any bony growth or cortical destruction. However, it structurally weakens the roof of the glenoid fossa, resulting in a fragile temporoman-

dibular joint (TMJ),³ in which infections, tumors, or fractures may progress more easily.⁴ Any surgical intervention affecting the articular eminence may also have an increased risk of perforation.⁵ It is important to recognize the presence of PAT in this area, as it may imitate some pathologies such as vascular malformations, eosinophilic granuloma, aneurysmal bone cyst, metastatic lesions, and early stages of fibrous dysplasia.⁶

Panoramic radiography is frequently used to detect PAT on imaging, and this method has been used in most studies of the prevalence of PAT. The detection of PAT on routine dental radiographs may be a prognostic factor that can be used to detect extensive pneumatization of mastoid air cells; therefore, a tomographic examination is recommended before surgical procedures.⁷ However, no volumetric research has been conducted on this subject.

Cone-beam computed tomography (CBCT) is used as a reliable technique in volume measurement research because

Received June 16, 2021; Revised September 13, 2021; Accepted September 18, 2021
Published online November 18, 2021

*Correspondence to : Dr. Merve Aydoğdu

Department of Oral and Maxillofacial Radiology, Faculty of Dentistry, Kirikkale University, Yenişehir Çelebi Sokak No: 1, 71450 Yahşihan/Kirikkale, Turkey
Tel) 90-318-2244927, E-mail) dt.merveaydogdu@gmail.com

Copyright © 2022 by Korean Academy of Oral and Maxillofacial Radiology

This is an Open Access article distributed under the terms of the Creative Commons Attribution Non-Commercial License (<http://creativecommons.org/licenses/by-nc/3.0>) which permits unrestricted non-commercial use, distribution, and reproduction in any medium, provided the original work is properly cited.

Imaging Science in Dentistry · pISSN 2233-7822 eISSN 2233-7830

it eliminates the disadvantages of 2-dimensional conventional imaging methods (e.g., magnification and superposition) and has advantages, including a low radiation dose compared to computed tomography, low costs, and a short scanning time.⁸ The aim of this study was to compare the mastoid air cell volume in patients with or without PAT on CBCT images.

Materials and Methods

The CBCT images of 654 patients admitted to the Department of Oral and Maxillofacial Radiology of Faculty of Dentistry of Kirikkale for various indications (impacted tooth localization, implant planning, evaluation of growth and development, etc.) between July 2016 and June 2019 were retrospectively analyzed. The retrospective study plan was approved by the faculty administration (E.6818). Ethical approval for the study was given by the Non-Interventional Research Ethics Committee of Kirikkale University (decision no. 2019/17-10/15). Patients with an undetectable zygomatic extension due to technical errors and those with a history of trauma, infection, or anomalies in the maxillofacial region were not included in the sample. Small field-of-view (FOV) images that did not present mastoid air cells were also excluded from the sample. Ultimately, images from 224 patients (98 males, 126 females) aged 17-65 years were analyzed. The images were taken by an X-ray technician with 10 years of experience using an I-CAT apparatus (Imaging Sciences International, Hatfield, PA) using 23 cm × 17 cm FOV set at 18.54 mA, 120 kVp, and 8.9 s. An oral maxillofacial radiologist evaluated the images over the course of a month. The diagnosis of PAT was based on the presence of air cells in the articular eminence in the anterior mandibular condyle on sagittal and coronal cross-sections.

In total, PAT was detected in 39 patients on scanned

CBCT images. Nine of these patients were excluded from the study group due to insufficient image quality and/or not showing the entire mastoid cell area in the imaging dataset. As a result, a study group was formed with 30 PAT patients. The Digital Imaging and Communications in Medicine (DICOM) data of 30 patients with PAT and 30 patients without PAT were transferred to 3D Doctor Software (Able Software Corp., Lexington, MA, USA) (Fig. 1). The 2 groups were set to be homogeneous in terms of age and sex by matching patients without PAT to those with PAT by age and sex. To calculate the mastoid air cell volumes, a region of interest was drawn in the axial sections and the thresholding value was determined (Fig. 2). As a result, the 3-dimensional images of the right and left mastoid air cells and the numerical values of the volume measurements were automatically calculated by the program (Fig. 3). In the semi-automatic segmentation method that was used, the operator interactively outlined the mastoid air cells in the axial sections, determined the thresholding range of the region of interest, and manually changed the threshold for different datasets in advancing axial sections. Meanwhile, the program automatically provided segmentation of the relevant area, for which the operator determined the density range, and volumetric data were obtained. Second measurements of all images were performed at a 1-month interval under the same conditions to assess intra-observer reliability. Data were analyzed using SPSS version 20.0 (IBM Corp, Armonk, NY, USA.). The independent-sample t-test was used. The Cronbach alpha test was used to evaluate intra-observer reliability.

Results

The patients ranged in age from 17 to 65 years, with a mean age of 27.8 ± 11.2 years. The intra-observer reliability

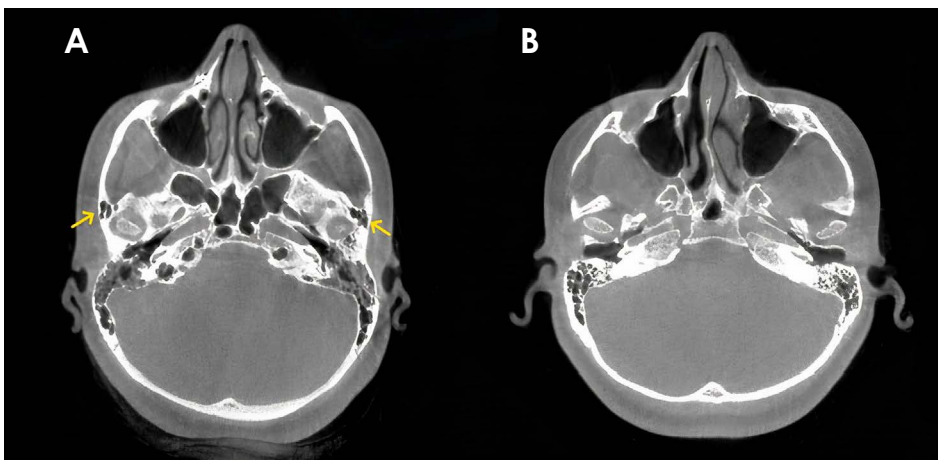


Fig. 1. Axial cone-beam computed tomographic image of a patient with a pneumatized articular tubercle (A) and without a pneumatized articular tubercle (B).

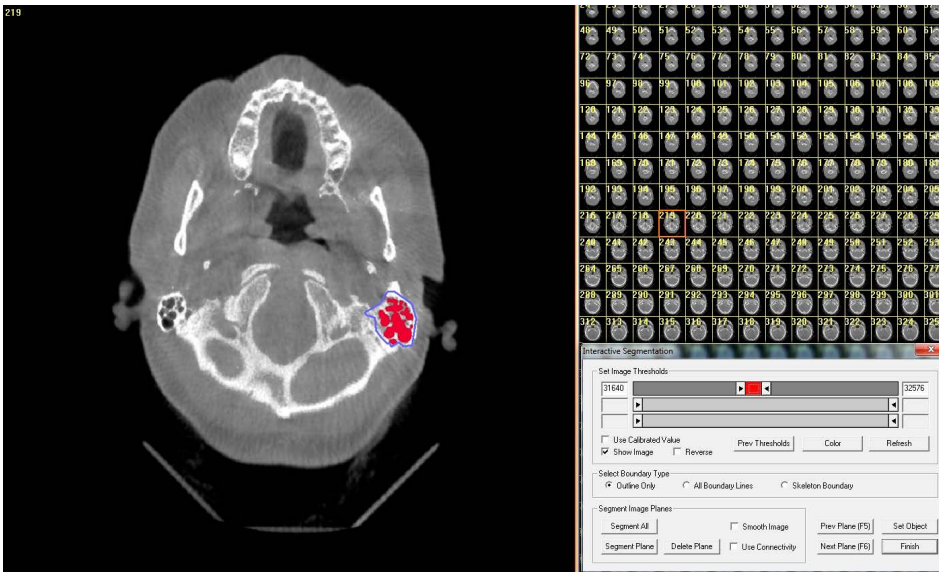


Fig. 2. Semi-automatic segmentation of axial sections on 3D Doctor software. External boundaries of the mastoid air cells are determined on axial sections. The threshold value is adjusted, and the volumes are measured.

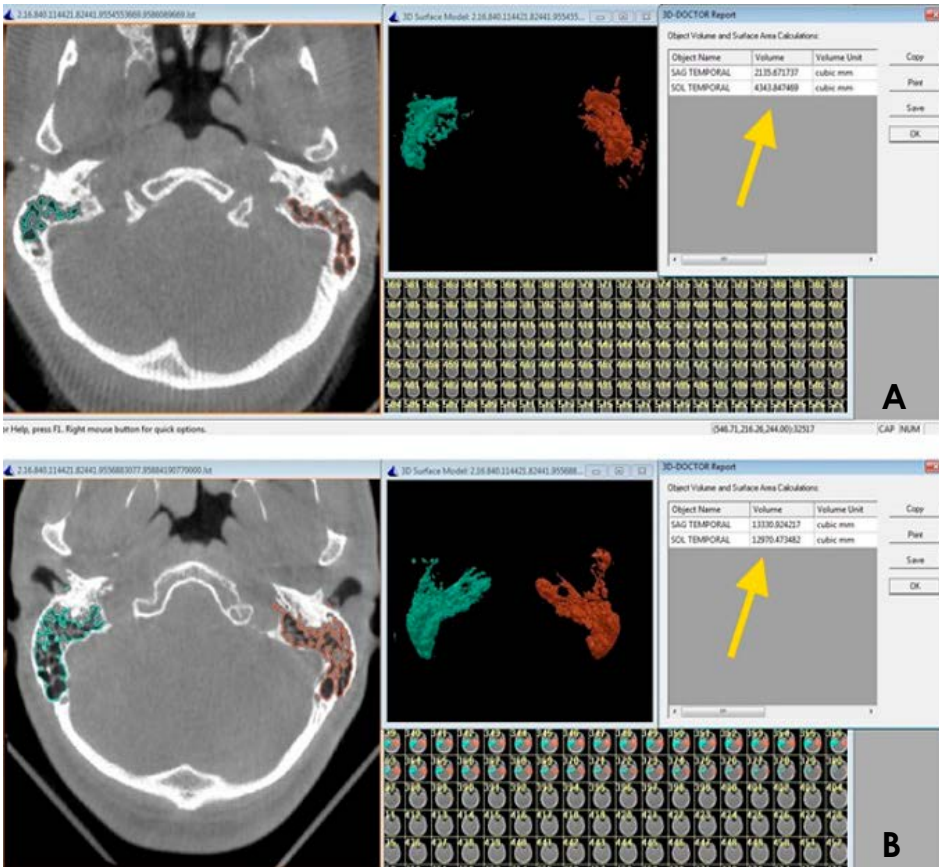


Fig. 3. A. Three-dimensional image of mastoid air cells in a patient without a pneumatized articular tubercle. B. Three-dimensional image of mastoid air cells in a patient with a pneumatized articular tubercle.

was high for repeated measurements (Cronbach alpha > 0.88). The experimental and control groups had a mean mastoid volume of $6.31 \pm 2.86 \text{ cm}^3$ and $3.25 \pm 1.99 \text{ cm}^3$, respectively. The mean volume of the mastoid air cells in patients with PAT was $6.14 \pm 2.84 \text{ cm}^3$ on the right side and $6.48 \pm 2.91 \text{ cm}^3$ on the left side. In patients without PAT, the

mean volume of mastoid air cells was $3.22 \pm 1.98 \text{ cm}^3$ on the right side and $3.28 \pm 2.03 \text{ cm}^3$ on the left side. The male patients with and without PAT had a mean mastoid volume of $5.77 \pm 2.16 \text{ cm}^3$ and $3.27 \pm 1.91 \text{ cm}^3$, respectively. The female patients with and without PAT had a mean mastoid volume of $7.55 \pm 3.83 \text{ cm}^3$ and $3.16 \pm 2.31 \text{ cm}^3$, respectively.

Table 1. Comparison of mastoid air cell volumes in patients with or without pneumatized articular tubercle (unit: cm³)

		Patients with pneumatized articular tubercle		Patients without pneumatized articular tubercle	
		Range	Mean	Range	Mean
Sex	Male	2.08-11.84	5.77 ± 2.16	0.73-9.97	3.27 ± 1.91*
	Female	1.68-13.94	7.55 ± 3.83	0.75-8.86	3.16 ± 2.31*
Side	Right	2.08-13.64	6.14 ± 2.84	0.73-9.97	3.22 ± 1.98*
	Left	1.68-13.94	6.48 ± 2.91	0.75-9.7	3.28 ± 2.03*
Total		1.68-13.94	6.31 ± 2.86	0.73-9.97	3.25 ± 1.99*

*P<0.05

There were statistically significant differences in mastoid air cell volumes between patients with and without PAT regardless of sex and mastoid air cell side, as shown in Table 1 (P<0.05).

Discussion

Temporal bone pneumatization is divided into 5 compartments: accessory air cells in the 1) middle ear; 2) mastoid; 3) peri-labyrinth; 4) petrous apex; and 5) squamous, zygomatic, occipital, and styloid fragments. These air cells reduce the weight of the skull, provide sound resonance during phonation, and control and moisturize the air inhaled during respiration. The mastoid air cells also serve as a gas reservoir that compensates for changes in pressure in the middle ear and provides insulation against heat changes.⁹ Lima et al.¹⁰ stated that the volumetric analysis of mastoid air cells plays a key role in understanding the mastoid physiology and pathogenesis and that computed tomography (CT) is the best way to determine mastoid pneumatization. Due to its low dose of radiation and rapid imaging, CBCT has recently emerged as an alternative to CT to evaluate anatomical structures in the maxillofacial region.¹¹ Demirel et al.¹² used a grading system of CBCT images to evaluate pneumatization in the mastoid and TMJ regions in terms of age and sex. Grade 0 was defined as pneumatization limited to the mastoid process, grade 1 as pneumatization between the mastoid process and the glenoid fossa, grade 2 as pneumatization between the deepest point of the glenoid fossa and the tip of the articular eminence, and grade 3 as pneumatization extending beyond the crest of the articular eminence. The authors reported a 12.2% prevalence of pneumatization (grade 2 and 3) in the articular eminence and concluded that defining the grading system in TMJ procedures was of paramount importance. Demirel et al.¹² also reported no significant correlation between pneumati-

zation grade, age, and sex. However, Khojastepour et al.¹³ found significant correlations between the pneumatization grade and PAT lacunarity. The multilacunar and unilacunar types of PAT were significantly less frequent in patients with grade 3 pneumatization than in patients with grade 1 or 2 pneumatization.

In this study, CBCT images were used to measure mastoid air cell volumes. Based on the literature, this was the first study to use CBCT images to measure the volume of mastoid air cells. However, similar studies have measured mastoid volume. Swarts et al.¹⁴ used Schuller’s projection radiographs and CT images to measure the width of mastoid air cells in 20 patients and found a strong correlation between 2-dimensional radiography width measurements and CT volume measurements (r=0.77). The authors reported that patients with otitis media (left: 2.9 ± 1.6 cm³; right: 3.7 ± 3.1 cm³) had a smaller mastoid volume than those without otitis media (left: 6.6 ± 5.5 cm³, right: 6.2 ± 3.6 cm³).

The mean mastoid air cell volumes on CT images have been reported to range from 1.3 to 22.67 cm³.¹⁵ The patients in the current study with and without PAT had a mean mastoid air cell volume of 6.31 ± 2.86 cm³ and 3.25 ± 1.99 cm³, respectively, which was within the range of what has been reported by previous studies.

Some studies have analyzed the relationship between mastoid pneumatization and other air cells. Hindi et al.¹⁶ used CT images to examine the distribution of mastoid air cells and temporal bone, ethmoid sinus, and sphenoidal sinus pneumatization across ethnic groups. A positive correlation between sphenoid sinus and mastoid cell pneumatization was reported. It was stated that this relationship may be caused by the close proximity of these 2 anatomic regions to the nasal cavity, as well as exposure to similar repulsive forces and pathological events affecting the pneumatization process. In addition, the longer-lasting development of the sphenoid sinus and mastoid air cells than other

paranasal sinuses can also cause this condition. Kim et al.¹⁷ analyzed the relationship between paranasal sinuses and mastoid air cells and reported a positive correlation between the sphenoidal sinus and mastoid air cells.

Sistani et al.¹⁸ conducted a study based on the theory that every factor that changes middle ear pressure affects the pneumatization of mastoid air cells. In their study, they investigated the relationship between nasal septum deviation, mastoid air cell volume, and chronic otitis. Although their study reported no relationship between the severity of nasal septum deviation and the incidence of mastoid pneumatization, the volume of mastoid air cells on the deviation side was found to be lower in patients with moderate or severe nasal septum deviation. In addition, there was a positive correlation between the severity of nasal septum deviation and chronic otitis. Patients with septum deviation were not included in the present study.

Pneumatization of the mastoid air cells depends on genetic and environmental factors. Pneumatization begins at the end of the fetal period and develops until the age of 15 years in both boys and girls. Childhood infections may prevent or stop pneumatization in the mastoid bone, which might result in sclerosis.¹⁹ In the literature, it has been reported that the mastoid length was shorter in individuals with pathological eardrum and middle ear adhesions, and that pneumatization was lower in subjects with short mastoid processes. However, it is not clear whether reduced temporal bone pneumatization is the effect or cause of middle ear infections.^{20,21} In the present study, these factors were considered; therefore, it included patients older than 17 years of age and excluded patients with a history of infection or anomaly in the craniofacial region (otitis media).

The mastoid absorbs and disperses the impacts of kinetic energy. İlea et al.²⁰ showed that mastoid pneumatization and architecture play a role in the mechanical preservation of temporal bone structures in direct lateral trauma. This was similar to the findings of the demonstrative study done by Kellmann and Schmidt,²² according to whom the task of the paranasal sinuses is to protect the eyeball from impacts to the eye. As a result of the presence of the paranasal sinuses, when a direct blow to the eyeball occurs, the eyeball remains intact while the orbital floor breaks. İlea et al.²⁰ also reported that mastoid sinuses with hyperpneumatization had a higher sensitivity to fracture than mastoids with good pneumatization. Pneumatization in the temporal bone protects the surrounding vital organs such as the cochlea, vestibule, facial nerves, and carotid artery in temporal bone fractures. Kang et al.²³ investigated the relationship between the degree of pneumatization and clinical findings after temporal bone

fracture. The clinical sequelae evaluated included hearing loss, facial nerve paresis or paralysis, and vestibular disorders. In patients with a high degree of pneumatization in the temporal bone, the incidence of otic capsule fractures and the severity of hearing impairment decreased in temporal bone fractures. The potential protective effect of pneumatization in temporal bone fractures was confirmed by that study.

Some studies have used panoramic radiography, CT, and CBCT to measure the prevalence of PAT. The prevalence of PAT on panoramic radiographs has been reported to range from 1.03% to 6.2%. Bhalchim et al.⁶ reported the prevalence of PAT as 1.96% on panoramic radiography and 12.5% on CBCT. In addition, unlike the unilaterally located and unilocular PAT type seen on panoramic radiography, the bilaterally located and multilocular PAT types were also observed on CBCT.

PATs are usually asymptomatic air-cell cavities but are more common in individuals with TMJ disease and dysfunction.²⁴ Bronoosh et al.⁷ argued that large pneumatization might be observed in mastoid air cells and that PAT could be a prognostic factor for the likelihood of pneumatization. Based on this suggestion, this study compared patients with and without PAT in terms of mastoid cell volume and found a significant difference between the 2 groups. The results showed that patients with PAT had larger mastoid air cells than patients without PAT. This information is especially important for surgical interventions on the temporal bone. Perforation of the mastoid air cells due to a surgical intervention in this region might lead to a potential pathway for the propagation of pathological events such as infection, tumor, and fracture.^{4,25} Moreover; numerous complications such as air leakage into the glenoid fossa, cerebrospinal fluid leakage, facial paralysis, and TMJ ankylosis might develop.^{26,27}

In conclusion, mastoid air cells were found to have a larger volume in patients with PAT. Therefore, the possibility of widespread pneumatization of mastoid air cells should be recognized in patients with PAT detected on panoramic radiography. Advanced imaging should be performed in these cases, and potential complications due to surgical interventions should be considered.

Conflicts of Interest: None

References

1. Deluke DM. Pneumatization of the articular eminence of the temporal bone. *Oral Surg Oral Med Oral Pathol Oral Radiol Endod* 1995; 79: 3-4.

2. Shetty SR, Psaaf A, Bayati M, Khazi SS, Reddy SM. Zygomatic air cell defect - a brief review. *Azerbaijan Med Assoc J* 2016; 1: 89-92.
3. Al-Faleh W, Ibrahim M. A tomographic study of air cell pneumatization of the temporal components of the TMJ in patients with temporomandibular joint disorders. *Egypt Dent J* 2005; 51: 1835-42.
4. Miloglu O, Yilmaz AB, Yildirim E, Akgul HM. Pneumatization of the articular eminence on cone beam computed tomography: prevalence, characteristics and a review of the literature. *Dentomaxillofac Radiol* 2011; 40: 110-4.
5. Ladeira DB, Barbosa GL, Nascimento MC, Cruz AD, Freitas DQ, Almeida SM. Prevalence and characteristics of pneumatization of the temporal bone evaluated by cone beam computed tomography. *Int J Oral Maxillofac Surg* 2013; 42: 771-5.
6. Bhalchim SG, Jugade SC, Ramaswami E, Gogri AA, Kadam SG, Umarji HR. Prevalence of pneumatized articular tubercle using panoramic radiography and cone beam-computed tomography: a retrospective study. *Contemp Clin Dent* 2018; 9(Suppl 2): S221-6.
7. Bronoosh P, Shakibafard A, Mokhtare MR, Munesi Rad T. Temporal bone pneumatization: a computed tomography study of pneumatized articular tubercle. *Clin Radiol* 2014; 69: 151-6.
8. Scarfe WC, Farman AG. What is cone-beam CT and how does it work? *Dent Clin North Am* 2008; 52: 707-30.
9. Magnuson B. Functions of the mastoid cell system: auto-regulation of temperature and gas pressure. *J Laryngol Otol* 2003; 117: 99-103.
10. Lima MA, Farage L, Cury MC, Bahmad Júnior F. Mastoid surface area-to-volume ratios in adult Brazilian individuals. *Braz J Otorhinolaryngol* 2013; 79: 446-53.
11. Scarfe WC, Farman AG, Sukovic P. Clinical applications of cone-beam computed tomography in dental practice. *J Can Dent Assoc* 2006; 72: 75-80.
12. Demirel O, Kaya E, Üçok CÖ. Evaluation of mastoid pneumatization using cone-beam computed tomography. *Oral Radiol* 2014; 30: 92-7.
13. Khojastepour L, Paknahad M, Abdalipur V, Paknahad M. Prevalence and characteristics of articular eminence pneumatization: a cone-beam computed tomographic study. *J Maxillofac Oral Surg* 2018; 17: 339-44.
14. Swartz JD, Cullen Doyle BM, Alper CM, Doyle WJ. Surface area-volume relationships for the mastoid air cell system and tympanum in adult humans: Implications for mastoid function. *Acta Otolaryngol* 2010; 130: 1230-6.
15. Cinamon U. The growth rate and size of the mastoid air cell system and mastoid bone: a review and reference. *Eur Arch Otorhinolaryngol* 2009; 266: 781-6.
16. Hindi K, Alazzawi S, Raman R, Prepageran N, Rahmat K. Pneumatization of mastoid air cells, temporal bone, ethmoid and sphenoid sinuses. Any correlation? *Indian J Otolaryngol Head Neck Surg* 2014; 66: 429-36.
17. Kim J, Song SW, Cho JH, Chang KH, Jun BC. Comparative study of the pneumatization of the mastoid air cells and paranasal sinuses using three-dimensional reconstruction of computed tomography scans. *Surg Radiol Anat* 2010; 32: 593-9.
18. Sistani SS, Dashipour A, Jafari L, Ghahderijani BH. The possible associations of nasal septal deviation with mastoid pneumatization and chronic otitis. *Open Access Maced J Med Sci* 2019; 7: 2452-6.
19. Palva T, Palva A. Size of the human mastoid air cell system. *Acta Otolaryngol* 1966; 62: 237-51.
20. Ilea A, Butnaru A, Sfrângeu SA, Hedeşiu M, Dudescu CM, Berce P, et al. Role of mastoid pneumatization in temporal bone fractures. *AJNR Am J Neuroradiol* 2014; 35: 1398-404.
21. Turgut S, Tos M. Correlation between temporal bone pneumatization, location of lateral sinus and length of the mastoid process. *J Laryngol Otol* 1992; 106: 485-9.
22. Kellman RM, Schmidt C. The paranasal sinuses as a protective crumple zone for the orbit. *Laryngoscope* 2009; 119: 1682-90.
23. Kang TK, Ha R, Oh JH, Sunwoo W. The potential protective effects of temporal bone pneumatization: a shock absorber in temporal bone fracture. *PLoS One* 2019; 14: e0217682.
24. Heim N, Götz W, Reich RH, Faron A. The prevalence of pneumatized articular eminence in the temporal bone. Do we need a high resolution computed tomography-based novel risk classification for eminectomy? *J Craniomaxillofac Surg* 2018; 46: 1996-2002.
25. Stieglitz LH, Giordano M, Gerganov V, Raabe A, Samii A, Samii M, et al. Petrous bone pneumatization is a risk factor for cerebrospinal fluid fistula following vestibular schwannoma surgery. *Neurosurgery* 2010; 67(2 Suppl Operative): 509-15.
26. Faerber TH, Ennis RL, Allen GA. Temporomandibular joint ankylosis following mastoiditis: report of a case. *J Oral Maxillofac Surg* 1990; 48: 866-70.
27. Tu TY. Cholesteatoma surgery in pneumatized and non-pneumatized temporal bones. *J Chin Med Assoc* 2005; 68: 458-62.