



Since January 2020 Elsevier has created a COVID-19 resource centre with free information in English and Mandarin on the novel coronavirus COVID-19. The COVID-19 resource centre is hosted on Elsevier Connect, the company's public news and information website.

Elsevier hereby grants permission to make all its COVID-19-related research that is available on the COVID-19 resource centre - including this research content - immediately available in PubMed Central and other publicly funded repositories, such as the WHO COVID database with rights for unrestricted research re-use and analyses in any form or by any means with acknowledgement of the original source. These permissions are granted for free by Elsevier for as long as the COVID-19 resource centre remains active.



medicina *intensiva*

<http://www.medintensiva.org/en/>



SCIENTIFIC LETTER

Macklin effect as an early radiological predictor of barotrauma in ARDS COVID-19 patients in invasive mechanical ventilation

Efecto Macklin como predictor radiológico precoz de barotrauma en pacientes COVID-19 con SDRA en ventilación mecánica invasiva

F.J. Casadiego Monachello^{a,*}, M.C. de la Torre Terron^a,
J.A. Mendez Barraza^a, S. Casals Vila^b

^a Servicio de Medicina Intensiva, Hospital de Mataró, Mataró, Barcelona, Spain

^b Servicio de Radiología, Hospital de Mataró, Mataró, Barcelona, Spain

Barotrauma, defined as tissue damage caused by a pressure gradient between a non-ventilated body cavity and the surrounding air or fluid, is a frequent complication in patients with acute respiratory distress syndrome (ARDS).¹

It has recently been evidenced that COVID-19 pneumonia is associated with respiratory failure and ARDS, which may require invasive mechanical ventilation (IMV) in the more serious cases. It has been seen that ARDS COVID-19 patients requiring IMV have a higher incidence of barotrauma than patients with ARDS due to other etiologies,² even with the use of protective ventilation strategies.³

Barotrauma can manifest as pneumothorax (PTX), pneumomediastinum (PMD) or subcutaneous emphysema.³ In an attempt to predict the risk of PTX/PMD in ARDS COVID-19 patients requiring IMV, use has been made of the Macklin effect, described as a lineal accumulation of air adjacent to

the bronchovascular sheath in the lung parenchyma window of the thoracic CT scan, as an early radiological predictor⁴ allowing the selection of patients who are more likely to develop this complication.

We report the incidence of barotrauma in our Intensive Care Unit (ICU) of Hospital de Mataró (Mataró, Spain) and the number of patients with PTX/PMD in which the Macklin effect was observed in the lung parenchyma window of a thoracic CT scan performed before the first radiological evidence of the disorder (Fig. 1).

A retrospective analysis was made of all the patients admitted to our ICU due to COVID-19 from 1 March 2020 to 31 October 2021, subjected to IMV and who developed PTX/PMD. We excluded cases of iatrogenic barotrauma, patients without IMV during admission, and subjects with no previous thoracic CT scan prior to the first radiological evidence of barotrauma (Fig. 1). Of the 321 patients admitted to our ICU, 216 (67.2%) required IMV, and of these, 14 (6.48%) presented PTX/PMD during their clinical course. Of the 14 patients with PTX/PMD, only 7 (50%) had a previous thoracic CT scan prior to the first radiological evidence of PTX/PMD that allowed evaluation of the presence of the Macklin effect. In 6 of these 7

DOI of original article: <https://doi.org/10.1016/j.medint.2022.07.003>

* Corresponding author.

E-mail address: fcasadiego@cscdm.cat
(F.J. Casadiego Monachello).

<https://doi.org/10.1016/j.medine.2022.09.005>

2173-5727/© 2022 Published by Elsevier España, S.L.U.

Please cite this article as: F.J. Casadiego Monachello, M.C. de la Torre Terron, J.A. Mendez Barraza et al., Macklin effect as an early radiological predictor of barotrauma in ARDS COVID-19 patients in invasive mechanical ventilation, *Medicina Intensiva*, <https://doi.org/10.1016/j.medine.2022.09.005>

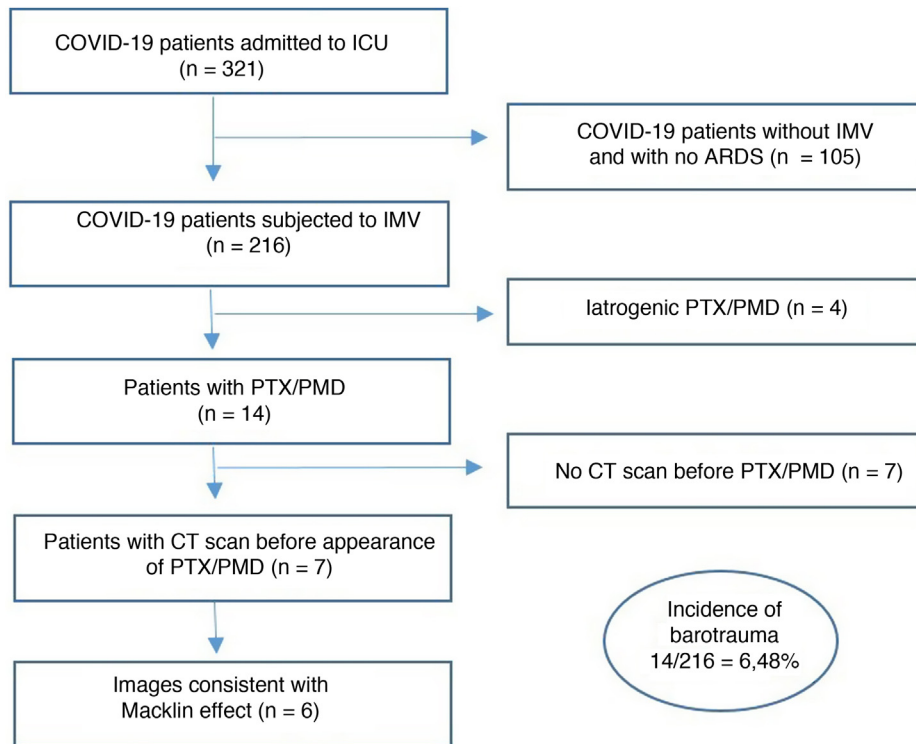


Figure 1 Inclusion and exclusion criteria flowchart.

Inclusion and exclusion criteria flowchart. COVID-19: Coronavirus disease 2019; ARDS: acute respiratory distress syndrome; IMV: invasive mechanical ventilation; CT: computed tomography; PMD: pneumomediastinum; PTX: pneumothorax.

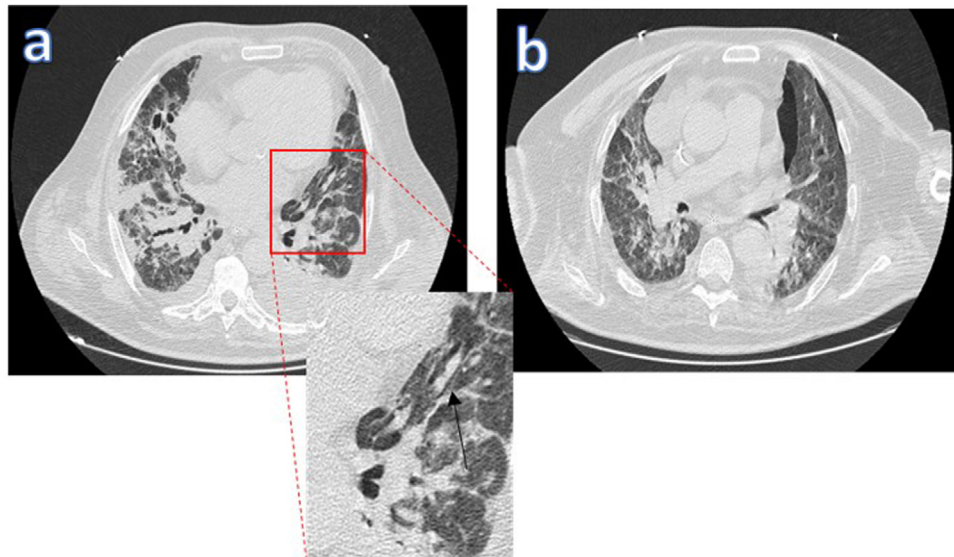


Figure 2 Macklin effect in a COVID-19 patient with ARDS subjected to IMV. The lung parenchyma window of the thoracic CT scan [a] shows a lineal accumulation of air adjacent to the bronchovascular sheath of the left upper lung lobe (the black arrow indicates the Macklin effect). [b] Appearance of pneumothorax days later.

patients (85.7%), we found images consistent with the Macklin effect in the lung parenchyma window of a thoracic CT scan performed days before the appearance of barotrauma (Fig. 2).

As limitations of this study, mention must be made of the limited sample size involved, the need for an experienced

radiologist, and the obtainment of an early thoracic CT scan allowing evaluation of the presence of the Macklin effect in order to be able to estimate the risk and vulnerability of these patients.

We confirm that the Macklin effect was a good early radiological predictor of the development of PTX/PMD in our

ARDS COVID-19 patients requiring IMV, supporting the high specificity (95.6%) and sensitivity (89.2%) reported in other studies.⁴ In COVID-19 patients subjected to IMV and who suffer respiratory worsening, with evidence of the Macklin effect in a basal thoracic CT scan, we should continue to apply protective ventilation strategies and moreover perform a control thoracic CT scan or conventional thoracic radiographic study (conditioned to availability) in order to discard the appearance of barotrauma as the cause of such worsening. On the basis of the above, we recommend an early thoracic CT scan at the time of respiratory failure and admission to the ICU, in order to assess the presence of the Macklin effect, with the aim of adjusting the ventilatory strategies to minimize the appearance of PTX/PMD as a complication, in view of the high mortality rate (60%) observed in patients with barotrauma and associated ARDS due to COVID-19.⁵

Ethical particulars

The present study was approved by the Clinical Research Ethics Committee of Hospital de Mataró on 17 June 2022 (Reference: CEIm 01/22).

Conflicts of interest

The authors declare that they have no conflicts of interest.

Financial support

None.

References

1. Battisti AS, Haftel A, Murphy-Lavoie HM. Barotrauma. *Treasure Island (FL): StatPearls Publishing*; 2022. PMID: 29493973.
2. McGuinness G, Zhan C, Rosenberg N, Azour L, Wickstrom M, Mason DM, et al. Increased incidence of barotrauma in patients with COVID-19 on invasive mechanical ventilation. *Radiology*. 2020;297:E252–62, <http://dx.doi.org/10.1148/radiol.2020202352>.
3. Rajdev K, Spanel AJ, McMillan S, Lahan S, Boer B, Birge J, et al. Pulmonary barotrauma in COVID-19 patients with ARDS on invasive and non-invasive positive pressure ventilation. *J Intensive Care Med*. 2021;36:1013–7, <http://dx.doi.org/10.1177/08850666211019719>.
4. Palumbo D, Zangrillo A, Belletti A, Guazzarotti G, Calvi MR, Guzzo F, et al. COVID-BioB Study Group. A radiological predictor for pneumomediastinum/pneumothorax in COVID-19 ARDS patients. *J Crit Care*. 2021;66:14–9, <http://dx.doi.org/10.1016/j.jcrc.2021.07.022>.
5. Belletti A, Todaro G, Valsecchi G, Losiggio R, Palumbo D, Landoni G, et al. Barotrauma in Coronavirus Disease 2019 patients undergoing invasive mechanical ventilation: a systematic literature review. *Crit Care Med*. 2022;50:491–500, <http://dx.doi.org/10.1097/CCM.0000000000005283>.