







Clinical and radiological results of surgically treated patients with adolescent idiopathic scoliosis and the effects of pulmonary rehabilitation on respiration functions

Fatih Dogar, MD^{a,b,*} , Mahmut Argun, MD^b , Sevki Erdem, MD^{b,c} , Kaan Gurbuz, MD^{b,d} , Ali Saltuk Argun, MD^b , Ibrahim Halil Kafadar, MD^b 

Abstract

Background: In the present study, we aimed to evaluate the effects of pulmonary rehabilitation on respiratory functions after the surgery on the basis of early radiological findings, pain degree, function, and satisfaction scores in operated patients with adolescent idiopathic scoliosis (AIS).

Methods: Thirty patients with AIS were included in the present study, who were divided into 2 groups. Scoliosis surgery and diaphragmatic breathing and pursed lip exercises were applied in Group 1 (n = 15), whereas merely scoliosis surgery was applied in Group 2 (n = 15). Pulmonary functions, arterial blood gas analysis, Cobb and kyphosis angles, apical vertebral rotation, and apical vertebral translation were measured before and 1st and 6th months after the surgery. Using the SRS-30 test, the psychosocial statuses of the patients and their satisfaction degrees with surgery applied were measured before and after the surgery.

Results: Six months after the surgery, the values of Cobb and kyphosis angles and apical vertebral rotations, and apical vertebral translation of the patients were determined to be significantly ameliorated, which is consistent with the literature. Forced vital capacity (l) and forced expiratory volume in the first second (l/s) were observed to be significantly improved in both groups after the surgery (respectively, $P = .001$, $P = .014$, $P = .001$, $P = .005$). In addition, the partial pressure of oxygen (pO_2) value was found to be significantly increased 6 months after the surgery compared with that before the surgery in Group 2 ($P = .022$). SRS-30 showed that most of the scores in Group 1 were dramatically increased; a significant difference between the groups was not recorded.

Conclusion: Patients with AIS have been found to be satisfied with the surgery. Conversely, pulmonary rehabilitation has been shown to slightly improve the respiratory functions in the patients with AIS, 1 and 6 months after the surgery.

Abbreviations: AIS = adolescent idiopathic scoliosis, AVR = apical vertebral rotation, AVT = apical vertebral translation, FEV 1 = forced expiratory volume in the first second, FVC = forced vital capacity, HCO_3 = hydrogen carbonate, pCO_2 = partial pressure of carbon dioxide, pH = potential of hydrogen, pO_2 = partial pressure of oxygen, SaO_2 = oxygen saturation, SRS = Scoliosis Research Society, TLC = total lung capacity, VC = vital capacity.

Keywords: adolescent idiopathic scoliosis, posterior fusion, posterior spinal instrumentation, pulmonary rehabilitation

1. Introduction

Scoliosis is the most prevailing deformity of the spine. Vertebral deformity not only remains limited to the frontal axis but also unveils an immersive deformity. An intravertebral extinction

causes lateral gliding in the frontal plane, rotation in the axial plane, and lordosis in the intervertebral plane.^[1]

Idiopathic scoliosis comprises nearly 80% of the patients with scoliosis, and 85% of these patients are adolescents.^[2] Report-

Editor: Fatima Naumeri.

The authors did not declare any specific grant from funding agencies in the public, commercial, or not-for-profit sectors in this article.

The authors have no conflicts of interest to disclose.

The datasets generated during and/or analyzed during the current study are available from the corresponding author on reasonable request.

^a Kahramanmaraş Sutcu Imam University, Faculty of Medicine, Department of Orthopaedics and Traumatology, Kahramanmaraş, ^b Erciyes University, Faculty of Medicine, Department of Orthopaedics and Traumatology, Kayseri, ^c Istanbul Haydarpaşa Numune Training and Research Hospital, Department of Orthopaedics and Traumatology, Istanbul, ^d Kayseri City Hospital, Department of Orthopaedics and Traumatology, Kayseri, Turkey.

* Correspondence: Fatih Dogar, Kahramanmaraş Sutcu Imam University, Faculty of Medicine, Department of Orthopaedics and Traumatology, Kahramanmaraş, Turkey (e-mail: drfatihdogar@hotmail.com).

Copyright © 2021 the Author(s). Published by Wolters Kluwer Health, Inc.

This is an open access article distributed under the terms of the Creative Commons Attribution-Non Commercial License 4.0 (CCBY-NC), where it is permissible to download, share, remix, transform, and buildup the work provided it is properly cited. The work cannot be used commercially without permission from the journal.

How to cite this article: Dogar F, Argun M, Erdem S, Gurbuz K, Argun AS, Kafadar İH. Clinical and radiological results of surgically treated patients with adolescent idiopathic scoliosis and the effects of pulmonary rehabilitation on respiration functions. *Medicine* 2021;100:7(e24675).

Received: 30 July 2020 / Received in final form: 20 November 2020 / Accepted: 16 January 2021

<http://dx.doi.org/10.1097/MD.00000000000024675>

edly, hereditary factors (genetic, melatonin scantiness, and connective tissue abnormalities) play a role in the etiology of adolescent idiopathic scoliosis (AIS).^[3-5] Several pulmonary problems might occur in scoliosis since the disease badly affects the constitutive components of the thorax.^[1] Therefore, a significant decrease has been clearly observed in the pulmonary function tests of the patients with scoliosis. Total lung capacity (TLC) and vital capacity (VC) of static lung volumes are primarily decreased.^[6] Partial arterial carbon dioxide pressure (PaCO₂) of the patients with scoliosis subsequently increased, and hypoxemia occurs. Surgical correction is known to be the best way to prevent the hypoxic status in scoliosis, but whether pulmonary rehabilitation increases the effectivity of scoliosis surgery is yet to be confirmed^[6] (Fig. 1).

The pulmonary rehabilitation programs of scoliosis surgery comprised pursed lip and diaphragmatic breathing exercises that are used to enhance lung ventilation, increase the mobility of thorax, and prevent some complications such as atelectasis.^[6]

With the development of third-generation posterior instrumentation systems, the posterior instrumentation systems have become a good alternative to anterior instrumentation in the surgical treatment of AIS. Consequently, in this study, we preferred to apply the posterior instrumentation system in surgical treatment.^[5]

In the present study, we aimed to examine the effects of pulmonary rehabilitation on the respiratory functions of patients with AIS who were classified using the Lenke System and treated with a third-generation instrumentation system. Further, we evaluated the effects of pulmonary rehabilitation after the surgery on the basis of early radiological findings and pain, function, and satisfaction scores.

2. Methods

Ethics Committee of Erciyes University Faculty of Medicine approved this prospective study (Approval no: 2011/47, Approval date: 04.01.2011, Session: 2010/16), and all patients provided written informed consent. We included 30 patients who were diagnosed with AIS in the Department of Orthopedics and Traumatology between 2010 and 2012. We compared the findings of the clinical examination, radiologic image, pulmonary function test, and blood gas that were obtained before the surgery and the first and sixth months after the surgery.

Blood gas of the patients was analyzed in 1 ml heparinized tubes with Siemens Rapid Lab 1265. In addition, using SensorMedics Vmax 20C before and after the surgery (in the first and sixth months), pulmonary function values were measured.

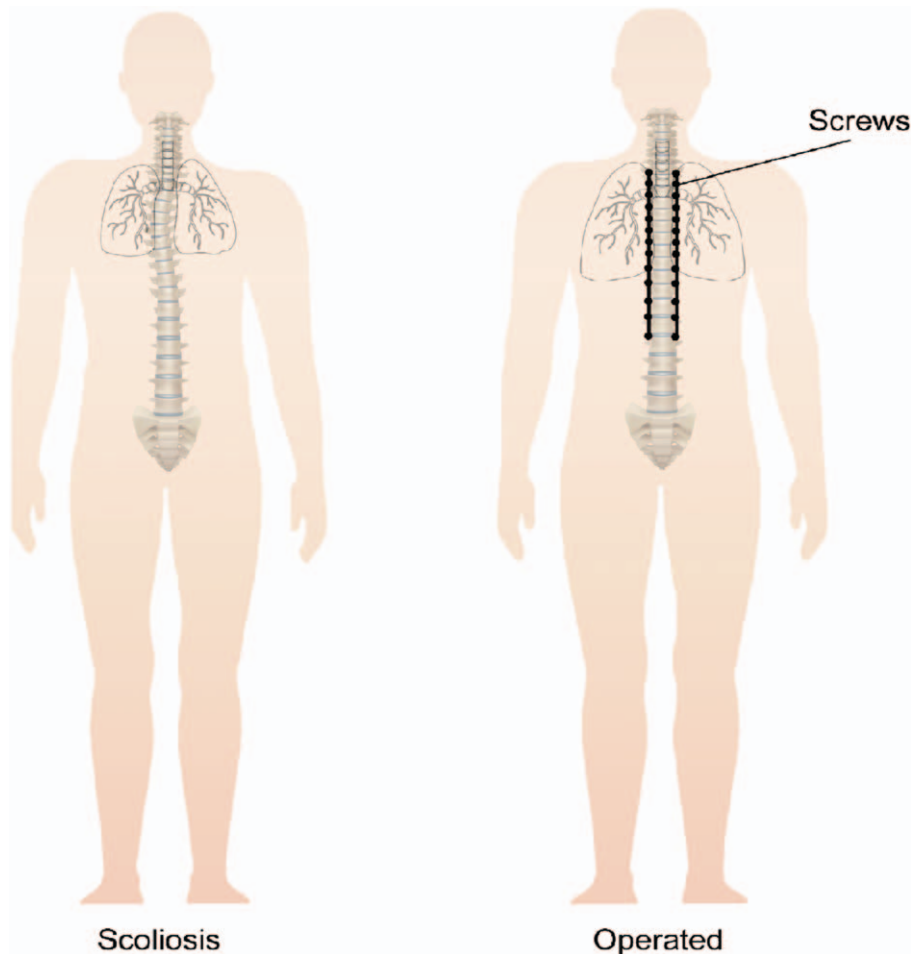


Figure 1. Image showing that deformity corrected and lung capacity increased after surgery in scoliosis patients.

The Lenke System was used to evaluate the radiological images.^[7] Scoliosis and thoracic kyphosis (between T₄ and T₁₂) angles were measured using the Cobb method.^[11] The distance between the center sacral vertical line and C₇, body deviation, and pelvic tilt were examined for balance measurement. The distance from the midpoint of the apical vertebral body to the central mid-sacral line was measured, and consequently, apical vertebral translation (AVT) was determined.^[8] Using the Nash–Moe method,^[8] the rotation of the apical vertebrae was measured. We used the Lenke classification system criteria to analyze the graphs of the patients.

2.1. Patients

The patients were divided into 2 groups (Groups 1 and 2; n = 15) with blocked randomization. Pulmonary rehabilitation exercises were applied in Group 1 after taking informed consent forms but not in Group 2. The posterior spinal instrumentation using third-generation pedicle screws and the posterior fusion were performed in the 2 groups. Posterior fusion was performed with a combination of autografting and allografting. After the surgery, the pain, function, appearance, mental health, and satisfaction score of patients were evaluated using the SRS-30 form prepared by the Scoliosis Research Society.^[9]

2.2. Surgery

Prophylactically, all patients were administered with 1g of cefazolin sodium intravenously (IV) preoperative. Antibiotic prophylaxis was sustained until the patient is discharged. After the incision over the spinous processes, the dissection was continued subperiosteally to the transverse processes, and the soft tissue was removed by cutting the interspinous and supraspinous

ligaments of the facet joint capsule. We started the instrumentation from the convex side of the curvature. The apical vertebrae were fixed using pedicle screws at appropriate levels. Curvature correction was achieved via the combination of compression from the convex side, derotation from the apical region, and distraction from the concave side. During the correction, normal sagittal physiological curvatures were preserved, and the stability of the system was increased using transverse connectors (Fig. 2).

2.3. Pulmonary rehabilitation

Diaphragmatic breathing and pursed lip exercises were applied in Group 1 in 6 months, 3 times per day for 10 minutes. In diaphragmatic breathing exercises, the patients lay comfortably on their backs, and a pillow is placed under their heads and knees. Each patient's right and left hands are placed on the patient's abdomen and the upper side of the patient's chest, respectively. While breathing through the nose, the patient should feel the upward movement of the abdomen with the right hand. Later on, the patient exhales slowly by puckered lips for 4 seconds. Meanwhile, the downward movement of the abdominal region should be felt. The movement of the upper thorax should be minimal. In the puckered lip breath, the patient breathes through the nose and exhales through puckered lips. The duration of exhalation is extended up to 7 seconds.

2.4. Statistical analysis

The normality of data obtained was controlled using the Shapiro–Wilk test. The Mann–Whitney *U* test was used to compare the abnormally distributed quantitative variables between the 2 groups, and chi-square analysis was used to compare the qualitative variables with abnormal distributions. Freidman and

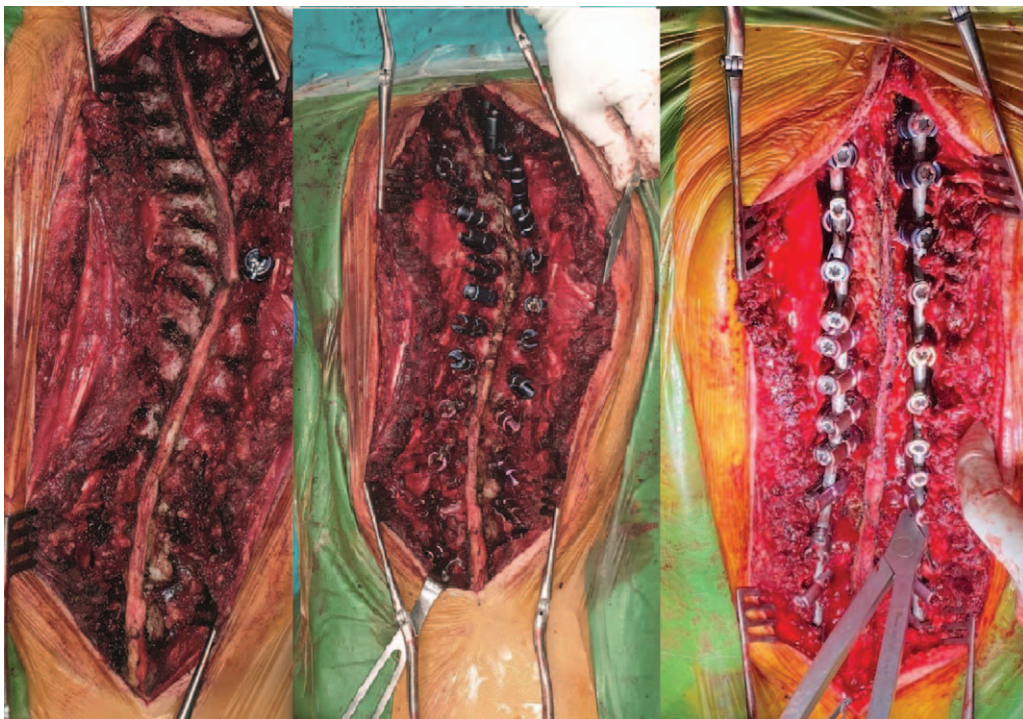

Figure 2. Intraoperative images of another AIS patient before and after correction with posterior spinal instrumentation.

Wilcoxon's tests were used to compare repeated measures. Dunnett's test was used for multiple comparisons. Data were analyzed using the IBM SPSS Statistics 25.0 packet program; $P < .05$ was considered statistically significant.

3. Results

3.1. Demographic analysis

The present study comprised 30 patients. We included 20 females (66.7%) and 10 males (33.3%). The age averages of female and male patients are 15.9 ± 3.44 (range 12–23) and 17.2 ± 3.55 (range 14–23), respectively. The age average of all participants was 16.3 years (12–23). The age average of scoliosis diagnosis is 12.9 years (range 6–19), the average follow-up period was 21.26 ± 6.1 months (range 12–30), and the duration of hospital stay is 4.86 ± 1.31 days (range 3–8) (Table 1).

3.2. Curvatures and skeletal maturities of the patients

The curves of patients were radiologically evaluated using the Lenke classification before the surgery (Table 2). It can be observed that the main curvature direction in type 1 is left, whereas that in type 2 is right. In 1 patient, the thoracic curvature direction is right, and the lumbar curvature direction is left; in another patient, the thoracic curvature is left, and the lumbar curvature direction is left. In type 4, the thoracic curvature direction is left, and the lumbar curvature direction is right. In type 5, thoracic/lumbar curvature direction is left in 3 patients and right in 1 patient. A thoracic curve is observed in 6 of 7 patients, and the major lumbar curve is observed in 1 patient.

The salient complaints were back pain in 7 patients (23.3%), back deformity in 13 patients (43.3%), and back pain and back deformity in 10 patients (33.3%). Corset treatment was applied in 6 patients (20%), and in patients in whom the curvatures progressed during the corset therapy, the operation was recommended. Seven patients used exercise (23.3%), and 2 patients (6.6%) used corset treatment and exercise. Conversely, 15 patients (50%) did not receive therapy because they were found to be not within the surgical limits. The maturity of the patients was clinically evaluated. There was menarche in 17 female patients (85%).

3.3. Recovery after the surgery

The vertebrae, involved in fusion, ranged from T₂ in proximal to L₅ in distal; the most extended fusion axle was between T₂ and L₄ vertebral. Vertebral levels included in the fusion ranged from 6 to 12, with an average of 9.5. A facet excision and decortication were performed in all patients, and an allograft was used because

Table 1

Demographic characteristics of the cases.

	Range	Average \pm SD
Age at operation (yr)		
Female	12–23	15.9 \pm 3.44
Male	14–23	17.2 \pm 3.55
Total	12–23	16.3 \pm 3.48
Age at diagnosis (yr)	6–19	12.93 \pm 3.13
Follow-up time (mo)	12–30	21.26 \pm 6.10
Duration of hospital stay (d)	3–8	4.86 \pm 1.31

SD = standard deviation.

their own autograft was not enough. In surgery, at least 30 cm³ allograft and at most 120 cm³ allograft were used, with an average of 75 cm³.

The major curvatures were detected using the Cobb method on standing AP roentgenograms. The average Cobb angle measured was $48.93^\circ \pm 2.54^\circ$ (30.1° – 81.3°) before the surgery, whereas it became $15.85^\circ \pm 1.76^\circ$ (3.9° – 45.2°), with an improvement of 33.08° (68%) after surgery. The improvement was found to be significant ($P = .001$).

When the patients were examined at the sagittal plane, before the surgery, lordosis was observed in 2 patients (6.6%); hyperkyphosis ($>40^\circ$), in 3 patients (10%); and normal kyphosis (20° – 40°), in 25 patients (83.3%). After the surgery, the kyphosis angle reached up to $33.44^\circ \pm 1.48^\circ$ (23° – 60°), and the difference was statistically significant ($P = .007$).

Apical vertebral rotations (AVRs) of the patients were measured using the Nash–Moe method. Before the surgery, the AVRs were found between stages 1 and 3 (median 2), whereas they were between stages 0 and 2 (median 1) after the surgery. The change was statistically significant ($P = .001$).

The AVTs of the patients were measured as 42.56 ± 4.46 mm (8.6–115.9) preoperatively. In control measurements after the surgery, they were found as 17.79 ± 2.60 mm (3.20–70.60); 58.2% correction was statistically significant ($P = .001$). In addition, preoperative and postoperative comparative outcomes of Cobb and kyphosis angles, AVRs, and AVTs of groups obtained statistically significant improvement and are presented in Table 3.

3.4. Pulmonary functions tests

Although preoperative forced vital capacity (FVC) values in Group 1 were 3.28 ± 1 l, they were found to be 2.73 ± 0.79 l in the first month and 3.31 ± 0.87 l in the sixth month. The difference was statistically significant ($P = .001$). Although the preoperative FEV₁ values in Group 1 were 2.89 ± 0.86 l/s, they were found to

Table 2

Distribution of patients by curvature type, lumbar spine qualifier, and thoracic sagittal qualifier.

Curvature type	Case number		Lumbar spine qualifier			Thoracic sagittal qualifier		
	Item	Rate (%)	A	B	C	(–)	N	(+)
Type 1	7	23.3	4	1	2	–	7	–
Type 2	4	13.3	3	–	1	–	4	–
Type 3	6	20	–	2	4	2	3	1
Type 4	2	6.6	–	1	1	–	1	1
Type 5	4	13.3	–	–	4	–	4	–
Type 6	7	23.3	–	–	7	–	6	1

Table 3**Comparison of average improvement in Cobb angle, thoracic kyphosis angle, apical vertebra rotation, and translation values.**

	Group 1 Preoperative	Group 1 Postoperative	Group 2 Preoperative	Group 2 Postoperative	P
Cobb angle (°) ±SD	46.59 ± 10.76	13.05 ± 7.76	51.27 ± 16.61	18.65 ± 10.79	.001
Kyphosis angle (°) ±SD	37.42 ± 13.11	32.48 ± 9.65	39.70 ± 13.15	33.73 ± 6.37	.007
AVR (stage) (median) (min–max)	2 (1–3)	1 (0–2)	2 (1–3)	1 (0–2)	.001
AVT (mm) ±SD	37.88 ± 12.5	17.76 ± 8.26	47.25 ± 32.17	21.81 ± 17.84	.001

AVR=apical vertebral rotations, AVT=apical vertebral translations, min–max=minimum–maximum, SD=standard deviation.

Table 4**Comparison of respiratory function values between Group 1 and Group 2 before and after surgery.**

	Group 1 (n=15)			P	Group 2 (n=15)			P
	Preoperative	1 mo after surgery	6 mo after surgery		Preoperative	1 mo after surgery	6 mo after surgery	
FVC (l) ±SD	3.28 ± 1	2.73 ± 0.79	3.31 ± 0.87	.001	2.57 ± 0.76	2.28 ± 0.64	2.66 ± 0.66	.014
FEV ₁ (l/s) ±SD	2.89 ± 0.86	2.47 ± 0.72	2.93 ± 0.78	.001	2.30 ± 0.67	2.15 ± 0.59	2.44 ± 0.56	.005
FEV ₁ /FVC (%) ±SD	89 ± 8.24	90.59 ± 5.14	88.8 ± 6.93	.33	88.93 ± 7.94	90.33 ± 6.93	92.26 ± 4.52	.2

FEV₁=forced expiratory volume in the first second, FVC=forced vital capacity, SD=standard deviation.

be 2.47 ± 0.72 l/s in the first month and 2.93 ± 0.78 l/s in the sixth month. The difference was statistically significant ($P=.001$). Conversely, although preoperative FVC values in Group 2 were 2.57 ± 0.76 l, they were found to be 2.28 ± 0.64 l in the first month and 2.66 ± 0.66 l in the sixth month. The difference was statistically significant ($P=.014$). Similarly, although preoperative FEV₁ values in Group 2 were 2.30 ± 0.67 l/s, they were found to be 2.15 ± 0.59 l/s in the first month and 2.44 ± 0.56 l/s in the sixth month. The difference was statistically significant ($P=.005$). The difference in FEV₁/FVC rates was found to be statistically non-significant in both groups (Table 4).

3.5. Blood parameters

All patients' blood gas parameters, potential of hydrogen (pH), partial pressure of carbon dioxide (pCO₂), partial pressure of oxygen (pO₂), hydrogen carbonate (HCO₃), and oxygen saturation (SaO₂) were analyzed preoperatively and postoperatively. All blood parameters in Group 1 showed changes after the surgery compared with those before the surgery; nevertheless, the increases were non-significant ($P=.085$). Conversely, some parameters in Group 2 were significantly increased after the surgery, but the value pCO₂ was determined to be decreased after the surgery. Furthermore, the pO₂ value significantly increased in Group 2 after the surgery compared with that before the surgery ($P=.022$) (Table 5).

3.6. SRS-30

We used the SRS-30 form to evaluate the pain, function, appearance, mental health, and satisfaction degrees of the patients. A significant difference was not detected between the groups in terms of pain, function, appearance, mental health, and satisfaction score from the surgery (respectively $P=.325, .436, .87, .486, .412$) (Fig. 3). Moreover, none of the patients had a neurological deficit and superficial wound infections and needed revision surgery.

3.7. Sample patient

A 15-year-old female patient was referred to our clinic with a back complaint. She was diagnosed with Lenke's 1A N-type of curvature. The major curvature during the application was measured as 42°, and we recommended surgical correction.

Instrumentation by pedicle screws and hook was conducted between T₂ and L₁. Posterior spinal fusion was performed, and the major curvature was measured as 5° (89.2% correction). Kyphosis angle was 44° and 31° before and after the surgery, respectively. FEV₁ value was 2.46 l/s before the surgery and increased to 2.83 l/s after the surgery (Fig. 4).

4. Discussion

It is demonstrated that pulmonary rehabilitation exercises after the surgery provide an improvement in respiratory functions

Table 5**Comparison of blood parameters between Group 1 and Group 2 patients before and after surgery.**

	Group 1 (n=15)			P	Group 2 (n=15)			P
	Preoperative	1 mo after surgery	6 mo after surgery		Preoperative	1 mo after surgery	6 mo after surgery	
pH ±SD	7.42 ± 0.02	7.43 ± 0.02	7.438 ± 0.01	.09	7.42 ± 0.02	7.43 ± 0.03	7.45 ± 0.03	.129
pO ₂ (mm Hg) ±SD	88.58 ± 7.02	89.18 ± 10.03	92.32 ± 6.4	.085	85.16 ± 10.96	82.02 ± 14.39	94.15 ± 9.43	.022
pCO ₂ (mm Hg) ±SD	31.79 ± 6.32	30.16 ± 3.31	32.02 ± 2.03	.155	30.26 ± 4.43	30.92 ± 4.89	29.02 ± 4.17	.127
HCO ₃ (mEq/l) ±SD	22.09 ± 3.06	21.89 ± 1.81	22.99 ± 1.44	.091	21.67 ± 2.43	22.5 ± 1.42	22.17 ± 0.96	.799
SaO ₂ (%) ±SD	96.78 ± 0.83	96.88 ± 0.85	97.04 ± 0.9	.368	92.64 ± 7.82	94.69 ± 3.69	96.98 ± 0.99	.188

HCO₃=hydrogencarbonate, pCO₂=partial pressure of carbon dioxide, pH=potential of hydrogen, pO₂=partial pressure of oxygen, SaO₂=oxygen saturation, SD=standard deviation.

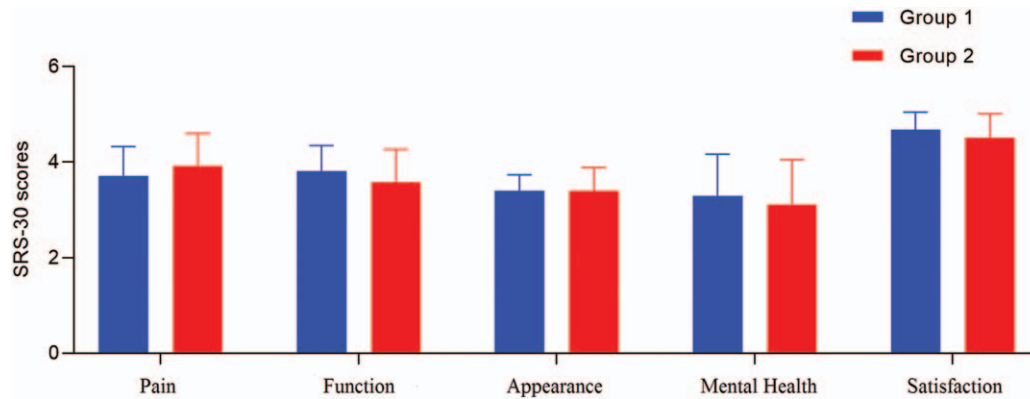


Figure 3. Comparison of SRS-30 values between the groups.

based on the good clinical and radiological results of patients with AIS treated surgically, which is the most important finding of the present study.

Hippocrates introduced the AIS. It was shaped by Lenke later on. Lenke classification is a treatment-based classification system in AIS. With Lenke System, although instrumentation is not required for non-structural regions in AIS, instrumentation and fusion are needed for regions with structural curvature.^[10] Third-generation posterior systems are widely used to provide a robust and reliable internal fixation in scoliosis surgery.

Storer et al^[11] obtained a 68.1% correction with hooks and a 70.3% correction with screws. In another study, segmental pedicle screws and hooks were compared; there was a 76% correction in the patients in whom screws were implemented and a 50% correction in those in whom hooks were implemented.^[12] Together, these data suggest that using pedicle screws at each

level is preferred to achieve a more effective improvement and less loss of correction.^[12] Segmental pedicle screws, hooks, and hybrid were compared in another study. Yilmaz et al^[13] obtained a major curve correction rate that was significantly different among all groups (screw = $71.9\% \pm 13.8\%$, hybrid = $61.4\% \pm 16.6\%$, and hook = $48.1\% \pm 19.7\%$). In the present study, the major curvature angle at the frontal plane was 48.93° , and after the surgery, the Cobb angle was found to be 15.85° ($33.08\%/68\%$ correction), which is consistent with the literature.^[11-13]

Benli et al^[14] reported an average improvement of 7.9° in the kyphosis angle of the thoracic region. They published that 83.5% of the patients were found to have a normal kyphosis angle. In our study, the average thoracal kyphosis value of the patients was measured to be 38.5° , and it declined to 33.4° after the surgery. Moreover, all patients were detected to have a normal kyphosis value after the surgery.

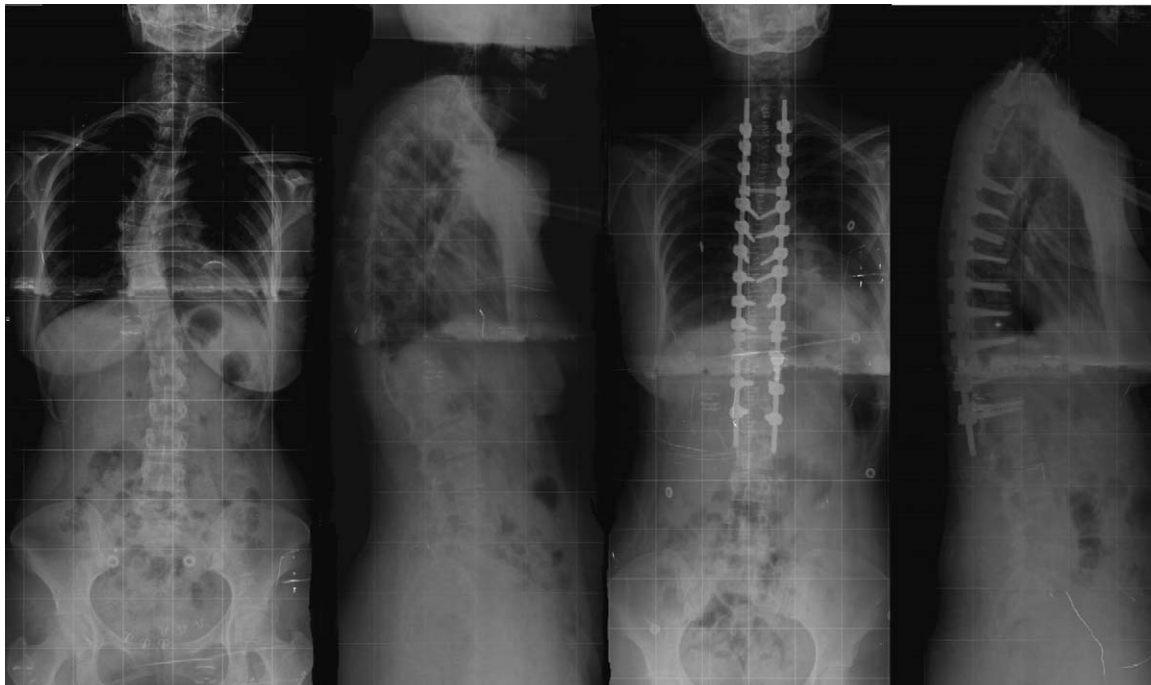


Figure 4. Radiological view of the sample patient pre- and postoperatively.

In their study of scoliosis, Lenke et al^[15] reported 41% improvement in vertebral rotation. Further, studies conducted with computed tomography reported a 42.5% improvement with the surgery in vertebral rotation.^[16] In another study, the uniplanar screw group showed a smaller proportion of higher-grade residual rotation at the first-erect postoperative visit ($P=.001$). This same difference was also noted between screw groups 1 year postoperatively ($P=.001$).^[17] The present study measured apical vertebral rotation (AVR) using the Nash–Moe method. Vertebral rotation, which was stage 2 (range 1–3) before the surgery, was found to be stage 1 (range 0–2) in postoperative control. The average improvement in vertebral rotations was determined to be 49.2%, which is consistent with the literature.^[15–17]

Richards et al^[18] provided a 77% improvement in body balance and body deviation from 25 to 5 mm. In the study of Yilmaz et al,^[13] the hook group had the least amount of AVT correction, whereas the screw and the hybrid groups were similar (pedicle = $67.3\% \pm 15.5\%$, hybrid = $57.5\% \pm 22.4\%$, and hook = $39.9\% \pm 32.5\%$) ($P < .001$). AVT is an important criterion in the prognosis of body balance.^[18] Gulsen et al^[19] measured AVT as 43.1 ± 5.57 mm before the surgery, but the translation was found to be 18.2 ± 2.56 mm with a 57.7% improvement (24.9 mm). In our study, the AVT of major curvature was measured as 42.56 ± 4.46 mm (range 8–115.9) before the surgery. After the surgery, it was determined to be 17.79 ± 2.60 mm (range 3.20–70.60) with a 58.2% improvement (24.77 mm). The extent of the improvement was statistically significant ($P < .05$), which is consistent with the literature. In addition, comparative outcomes of Cobb and kyphosis angles and AVRs and AVTs of groups preoperatively and postoperatively were found to be statistically significant, and similar outcomes were seen in the literature.^[13–19]

Currently, spine deformations are known to have adverse effects on the development of the thorax by changing the shape and reducing the normal motility of the thorax, and it must be emphasized that the thoracic cage is part of the deformity (rib–vertebral–sternal complex). There is a normal interaction between the spine, thoracic cage, and lungs. Both early-onset spinal deformities and precocious spinal arthrodesis alter the spinal growth and affect the development of the thorax by changing its shape and reducing its normal mobility. The treatment of the growing spine is a unique challenge and involves the preservation of the thoracic spine, thoracic cage, and lung growth without reducing spinal motion.^[20,21]

Patients with scoliosis were observed to have decreased TLC, VC, and functional residual capacity. The pulmonary compliance of patients with scoliosis who breath with their low lung volumes shows a gradual decrease. This situation increases the respiration workload on thorax muscles, depending on the age and curvature extent of the patients. Surgical correction and pulmonary rehabilitation are known to be the best ways to prevent this status in scoliosis.^[22] Pursed lip and diaphragmatic breathing exercises increase the ventilation and oxygenation and reduce muscle activity and respiratory workload by enabling patients with AIS to control respiration.^[23] Pehrsson et al found that pulmonary function test values increased significantly in patients with idiopathic scoliosis in 25 years following posterior spinal fusion surgery.^[24] Conversely, Buckland et al^[25] reported pulmonary function tests preoperative to 5-year improvement in the first second of forced expiratory volume (FEV_1) (2.74 – 2.98 l/s, $P=.005$) and FVC (3.23 – 3.47 l, $P=.008$) but TLC did not change ($P=.517$). Another study reported that patients with

severe AIS Lenke type 1A showed limited cardiorespiratory tolerance to maximum exercise, which did not improve 2 years after the surgery.^[26]

In the present study, Group 1 patients, who received posterior spinal instrumentation and fusion surgery followed by respiratory exercise, had respiratory values 6 months after the surgery (FVC 3.31 l, FEV_1 2.93 l/s) similar to their respiratory function test values before the surgery (FVC 3.28 l and FEV_1 2.89 l/s). Conversely, Group 2 patients, in which only received posterior spinal instrumentation and fusion surgery, the values 6 months after the surgery (FVC 2.66 l, FEV_1 2.44 l/s) showed a slight increase compared with those before the surgery (FVC 2.57 l and FEV_1 2.30 l/s). Similarly, the FEV_1/FVC value before the surgery (88.8%) did not change as much as that after the surgery (89%) ($P=.33$). In Group 2, we found a slight increase in FEV_1/FVC value after the surgery (92.2%) compared to that before the surgery (88%). However, the difference was not significant ($P=.2$).

Alveolar hypoventilation and reduced tidal volume due to increased respiration frequency cause apparent hypoxemia during an effort in patients with scoliosis. pCO_2 which is normal in the early period, increases in the long term. After the surgery, with the straightening of the spine, the mobility of the thorax, and the VC of the lungs increase, and pO_2 values are improved.^[27,28] The pO_2 values of both groups after the surgery increased compared with those before the surgery, and it was found that the increase in the group who did not have a respiratory exercise was more than that in the group who had a respiratory exercise and was statistically significant. However, pCO_2 and HCO_3 values in both groups did not show a significant difference between preoperative and postoperative measurements. SaO_2 values were determined to be significantly increased in postoperative measurement in both groups.

The Scoliosis Research Society designed a form to evaluate the results of spinal surgeries. The questions in the form were divided into 5 different categories: pain, function, appearance, mental health, and satisfaction from the surgery.^[29] Bayraktar et al found that after scoliosis surgery, the average pain score was 4.2, the function score was 4.4, the appearance score was 4.2, the mental health score was 3.8, and the satisfaction score was 4.2.^[30] In our study, the SRS-30 form was filled out by the patients in their last control, and it was observed that the function, appearance, mental health, and satisfaction scores of the group who had a respiratory exercise were higher than those of the group who had not.

Our study has some limitations. First, the current prospective study could be considered to be the low sample size in the groups, but the number was appropriate according to the power analysis calculation. Second, all patients' surgical operations were performed at 1 center by the same surgical team. Third, some patients were excluded because of a lack of a 1-year follow-up. This exclusion also procures the pulmonary results of the study. Last, the results of all pulmonary tests performed at early postoperative period could not be compared with the late postoperative period results.

Consequently, Cobb and kyphosis angles and AVR and AVT scores of the patients of both groups with AIS were found to be improved, which is consistent with the literature.^[10–19] In the present study, we anticipated that even if there is no significant improvement in respiratory function values in patients with AIS who performed respiratory exercises compared with the patients who did not, respiratory function values and blood gas

parameters will improve more with long respiratory rehabilitation, and lung capacity will be better eventually. We observed that patients with AIS are satisfied with the surgical treatment in terms of pain, function, activity, appearance, mental health, and satisfaction.

Acknowledgments

The authors are indebted to Biostatistics Assoc. Prof. Gökmen Zararsiz for statistical support and power analysis in this study. Language and grammar of this article was revised and edited by ENAGO (<https://www.enago.com.tr>).

Author contributions

FD, MA, and SE constructed the idea or hypothesis for research; FD took the responsibility in drafting of the whole the manuscript; KG reviewed the article not only for critical reading and editing but also for its scientific content; FD and IHK took responsibility in drafting of the project and ethical approval; FD and ASA took the responsibility in the execution of the experiments, data management, and reporting. All authors reviewed and approved the last version of the manuscript.

Conceptualization: Fatih Dogar, Mahmut Argun, Sevki Erdem, Kaan Gurbuz, Ali Saltuk Argun, Ibrahim Halil Kafadar.

Data curation: Fatih Dogar, Mahmut Argun, Sevki Erdem, Kaan Gurbuz, Ali Saltuk Argun, Ibrahim Halil Kafadar.

Formal analysis: Fatih Dogar, Mahmut Argun, Sevki Erdem, Kaan Gurbuz, Ali Saltuk Argun, Ibrahim Halil Kafadar.

Funding acquisition: Fatih Dogar, Kaan Gurbuz, Ali Saltuk Argun, Ibrahim Halil Kafadar.

Investigation: Fatih Dogar, Mahmut Argun.

Methodology: Fatih Dogar, Mahmut Argun, Sevki Erdem, Kaan Gurbuz, Ali Saltuk Argun, Ibrahim Halil Kafadar.

Project administration: Fatih Dogar, Mahmut Argun, Sevki Erdem.

Resources: Fatih Dogar, Sevki Erdem, Kaan Gurbuz, Ibrahim Halil Kafadar.

Software: Fatih Dogar, Mahmut Argun, Kaan Gurbuz, Ali Saltuk Argun.

Supervision: Fatih Dogar, Mahmut Argun, Ali Saltuk Argun, Ibrahim Halil Kafadar.

Validation: Fatih Dogar, Sevki Erdem.

Visualization: Fatih Dogar, Mahmut Argun, Sevki Erdem, Ali Saltuk Argun.

Writing – original draft: Fatih Dogar, Mahmut Argun, Kaan Gurbuz, Ibrahim Halil Kafadar.

Writing – review & editing: Fatih Dogar, Kaan Gurbuz.

References

- [1] Choudhry MN, Ahmad Z, Verma R. Adolescent idiopathic scoliosis. *Open Orthop J* 2016;10:143–54.
- [2] Roach JW, Mehlman CT, Sanders JO. Does the outcome of adolescent idiopathic scoliosis surgery justify the rising cost of the procedures? *J Pediatr Orthop* 2011;31:77–80.
- [3] Kikanloo SR, Tarpada SP, Cho W. Etiology of adolescent idiopathic scoliosis: a literature review. *Asian Spine J* 2019;13:519–26.
- [4] Fadzani M, Bettany-Saltikov J. Etiological theories of adolescent idiopathic scoliosis: past and present. *Open Orthop J* 2017;11:1466–89.
- [5] Weinstein SL, Dolan LA, Cheng JC, et al. Adolescent idiopathic scoliosis. *Lancet* 2008;371:1527–37.
- [6] Kim YJ, Lenke LG, Bridwell KH, et al. Pulmonary function in adolescent idiopathic scoliosis relative to the surgical procedure. *J Bone Joint Surg Am* 2005;87:1534–41.
- [7] Lenke LG. Lenke classification system of adolescent idiopathic scoliosis treatment recommendations. *Instr Course Lect* 2005;54:537–42.
- [8] Mohanty SP, PaiKanhagad M, Gullia A. Curve severity and apical vertebral rotation and their association with curve flexibility in adolescent idiopathic scoliosis. *Musculoskelet Surg* 2020;10:12306–20.
- [9] Carrico G, Meves R, Avanzi O. Cross-cultural adaptation and validity of an adapted Brazilian Portuguese version of Scoliosis Research Society-30 questionnaire. *Spine* 2012;37:60–3.
- [10] Lenke LG, Edwards CC, Bridwell KH. The Lenke classification of adolescent idiopathic scoliosis: how it organizes curve patterns as a template to perform selective fusions of the spine. *Spine* 2003;28:199–207.
- [11] Storer SK, Vitale MG, Hyman JE, et al. Correction of adolescent idiopathic scoliosis using thoracic pedicle screw fixation versus hook constructs. *J Pediatr Orthop* 2005;25:415–9.
- [12] Kim YJ, Lenke LG, Kim J, et al. Comparative analysis of pedicle screw versus hybrid instrumentation in posterior spinal fusion of adolescent idiopathic scoliosis. *Spine* 2006;31:291–8.
- [13] Yilmaz G, Borkhuu B, Dhawale AA, et al. Comparative analysis of hook, hybrid, and pedicle screw instrumentation in the posterior treatment of adolescent idiopathic scoliosis. *J Pediatr Orthop* 2012;32:490–9.
- [14] Benli T, Ateş B, Akalın S, et al. 10 years follow-up surgical results of adolescent idiopathic scoliosis located with TSRH instrumentation. *Eur Spine J* 2006;14:298–332.
- [15] Lenke L, Bridwell K, Baldus C, et al. Cotrel-Dubouset instrumentation for adolescent idiopathic scoliosis. *J Bone Joint Surg Am* 1992;74:1056–67.
- [16] Lee SM, Suk SI, Chung ER. Direct vertebral rotation: a new technique of three-dimensional deformity correction with segmental pedicle screw fixation in adolescent idiopathic scoliosis. *Spine* 2004;29:343–9.
- [17] Dalal A, Upasani VV, Bastrom TP, et al. Apical vertebral rotation in adolescent idiopathic scoliosis: comparison of uniplanar and polyaxial pedicle screws. *J Spinal Disord Tech* 2011;24:251–7.
- [18] Richards BS, Scaduto A, Vanderhave K, et al. Assessment of trunk balance in thoracic scoliosis. *Spine* 2005;30:1621–62.
- [19] Gulsen M, Ozkan C, Kavak C. Anterior and hybrid posterior instrumentation in the treatment of adolescent idiopathic scoliosis with Lenke type 1 curves. *J Turkish Spinal Surg* 2009;20:9–22.
- [20] Canavese F, Dimeglio A, Granier M, et al. Arthrodesis of the first six dorsal vertebrae in prep-ubertal New Zealand white rabbits and thoracic growth to skeletal maturity: the role of the “Rib-Vertebral-Sternalcomplex”. *Minerva Ortop Traumatol* 2007;58:369–78.
- [21] Canavese F, Dimeglio A. Normal and abnormal spine and thoracic cage development. *World J Orthop* 2013;4:167–74.
- [22] Vedantam R, Lenke LG, Bridwell KH, et al. A prospective evaluation of pulmonary function in patients with adolescent idiopathic scoliosis relative to the surgical approach used for spinal arthrodesis. *Spine* 2000;25:82–90.
- [23] Ruiz-Juretschke C, Pizones J, Delfino R, et al. Long-term pulmonary function after open anterior thoracolumbar surgery in thoracolumbar/lumbar idiopathic adolescent scoliosis. *Spine* 2017;42:1241–7.
- [24] Pehrsson K, Danielson A, Nachemson A. Pulmonary function in adolescent idiopathic scoliosis. A 25 year follow up after surgery or start of brace treatment. *Thorax* 2001;56:388–93.
- [25] Buckland AJ, Woo DBS, Vasquez-Montes DMS, et al. The Relation ship between 3-dimensional spinal alignment, thoracic volume, and pulmonary function in surgical correction of adolescent idiopathic scoliosis. *Spine* 2020;45:983–92.
- [26] Lorente A, Barrios C, Burgos JM, et al. Cardio respiratory function does not improve 2 years after posterior surgical correction of adolescent idiopathic scoliosis. *Spine* 2017;42:1391–7.
- [27] Moramarco M, Fadzani M, Moramarco K, et al. The influence of short-term scoliosis-specific exercise rehabilitation on pulmonary function in patients with AIS. *Curr Pediatr Rev* 2016;12:17–23.
- [28] Yazsaz B, Jazayeri R, Lonner B. The effect of surgical approaches on pulmonary function in adolescent idiopathic scoliosis. *Clin Spine Surg* 2009;22:278–83.
- [29] Acaroglu E. Adolescent general evaluation and conservative treatment in idiopathic scoliosis. *Acta Orthop Traumatol Turc* 2002;1:10–4.
- [30] Bayraktar BA, Elvan A, Selmani M, et al. Effects of Schroth exercises combined with orthotic treatment on balance control in adolescent idiopathic scoliosis. *J Exerc Rehabil* 2018;5:125–34.