

# The comparative study of Yaz and Ovocept-ld on patients with simple ovarian cysts referring to Iran-Isfahan Shariati Hospital

Soheyla Riahinejad, Azam Foroughi Pour, Leila Dehghani, Saadat Hajizadeh<sup>1</sup>

Department of Medical Sciences, <sup>1</sup>Faculty of Midwifery Group, Nursing and Midwifery College, Islamic Azad University, Najafabad Branch, Isfahan, Iran

## Abstract

**Background:** Functional ovarian cysts include follicular, corpus luteum, and theca lutein cysts are the most common adnexal masses (about 50%) in women of reproductive age. Treatment with the combined monophasic oral contraceptives reduces functional ovarian cysts. Yaz (drospirenone/ethinyl estradiol) is a low-dose combined oral contraceptive pill containing 20 µg ethinyl estradiol and 3 mg drospirenone. In addition to contraceptive effects, Yaz has anti-mineralocorticoid and anti-adrenergic effects. Ovocept- low-dose LD is also a low-dose combined oral contraceptive drug containing 30 µg ethinyl estradiol and 3 mg norgestrol. Ovocept-LD has some side-effects such as weight gain, spotting, breast tenderness, nausea, and headache.

**Materials and Methods:** Being a clinical study, the present research was carried out on 42 patients with the simple ovarian cysts from 2010 to 2012. 84 Patients were assigned to A and B groups. Group A received Yaz once a day for a period of 28 days and group B received Ovocept-LD once a day for a period of 21 days. After treating by Yaz and Ovocept-LD, Cysts were evaluated by ultrasound. Results were analyzed by the SPSS software. A  $P < 0.05$  was considered the significance threshold.

**Results:** Obtained results indicated that both Yaz and Ovocept-LD had an effect on the simple ovarian cysts. Statistical tests, however, has shown that the effect of Yaz has been significantly more than that of Ovocept-LD.

**Conclusion:** Given the faster and better recovery effect, and the lesser side effects of Yaz as compared to Ovocept-LD, it is recommended to use Yaz for the simple ovarian cysts.

**Key Words:** Ovocept-LD, simple ovarian cyst, Yaz

### Address for correspondence:

Dr. Leila Dehghani, Department of Medical Sciences, Najafabad Branch, Islamic Azad University, Isfahan, Iran. E-mail: L\_Deighani2002@yahoo.com

**Received:** 08-12-2012, **Accepted:** 13-03-2013

Access this article online	
Quick Response Code:	Website: www.advbiores.net
	DOI: 10.4103/2277-9175.142315

## INTRODUCTION

Functional ovarian masses consist of follicular, corpus luteum and theca lutein cysts. Being benign, these cysts usually cause no symptoms and require no surgery.<sup>[1]</sup> Follicular cysts are the most common functional cysts and rarely grow more than 8 cm. If the follicle is larger than 3 cm in diameter, then it may be termed a follicular cyst.<sup>[2]</sup> Around 2/3<sup>rd</sup> of ovarian

Copyright: © 2014 Riahinejad. This is an open-access article distributed under the terms of the Creative Commons Attribution License, which permits unrestricted use, distribution, and reproduction in any medium, provided the original author and source are credited.

**How to cite this article:** Riahinejad S, Pour AF, Dehghani L, Hajizadeh S. The comparative study of Yaz and Ovocept-ld on patients with simple ovarian cysts referring to Iran-Isfahan Shariati Hospital. Adv Biomed Res 2014;3:205.

masses occur in reproductive age (27-40) of which 80-85% are benign. These ovarian masses are mostly functional ovarian cysts. Functional cysts are masses with thin wall, containing fluid or semisolid material, which can be caused by hormonal or functional disorders. Naturally, they are not malignant.<sup>[3]</sup> If the follicle, at any follicular-phase, reaches a size larger than 3 cm (it rarely grows to a size of 10 cm), it will be recognized a follicular cyst. This is caused by abnormalities in gonadotropin secretion, which is commonly asymptomatic; however, sometimes has one of the following symptoms: menstrual cycle lengthening, bleeding between menstrual periods, or spotting.<sup>[4]</sup> Sometimes, it is ruptured spontaneously and results in abdominal pain and tenderness which is revealed mostly within 1-2 days, and occasionally causes ovarian torsion (in cysts larger than 4-6 cm). Ultrasound is of help in its diagnosis.<sup>[5]</sup> Small cysts are screened or treated with contraceptive pills while laparotomies are performed on the large ones. Luteum cysts are less common. Normally 2-4 days after ovulation, corpus luteum bleeding and subsequently, the blood absorption take place, then the serous fluid is collected and corpus luteum cyst, being 5-10 cm in diameter and containing serous, occur if bleeding or corpus luteum activity continues.<sup>[6,7]</sup> Its clinical characteristics range from no symptom to peritoneal hemorrhage caused by the cyst rupture. In a quarter of cases, the cyst is ruptured that may be due to coitus, trauma to the abdomen, or abdominal examination. This is usually very painful and lasts for less than 24 h. At times, due to intra-abdominal bleeding, one goes into shock. There are symptoms of unilateral pain, spotting, and tender adnexal mass if the cyst remains intact.<sup>[8]</sup> Progetine or contraceptives are employed to small cysts (smaller than 6 cm), where laparotomies are used for the large cysts.<sup>[9]</sup>

Being a very rare functional ovarian cysts, theca lutein cysts are usually bilateral and occur in association with a pregnancy (including molar pregnancy).<sup>[10]</sup> These types of cysts may be associated with the multiple pregnancies, molar pregnancies, choriocarcinoma, diabetes, sensitivity to Rhesus isoimmunisation RH, taking clomiphene citrate, ovulation induction with the human menopausal gonadotropin, human chorionic gonadotropin, and a gonadotropin releasing hormone1 analogues. Although, theca lutein cysts might have several holes and be quite large (>30 cm), they regress spontaneously.<sup>[11]</sup> Treatment with combined monophasic oral contraceptives reduces the risk of functional ovarian cysts dramatically.<sup>[11]</sup>

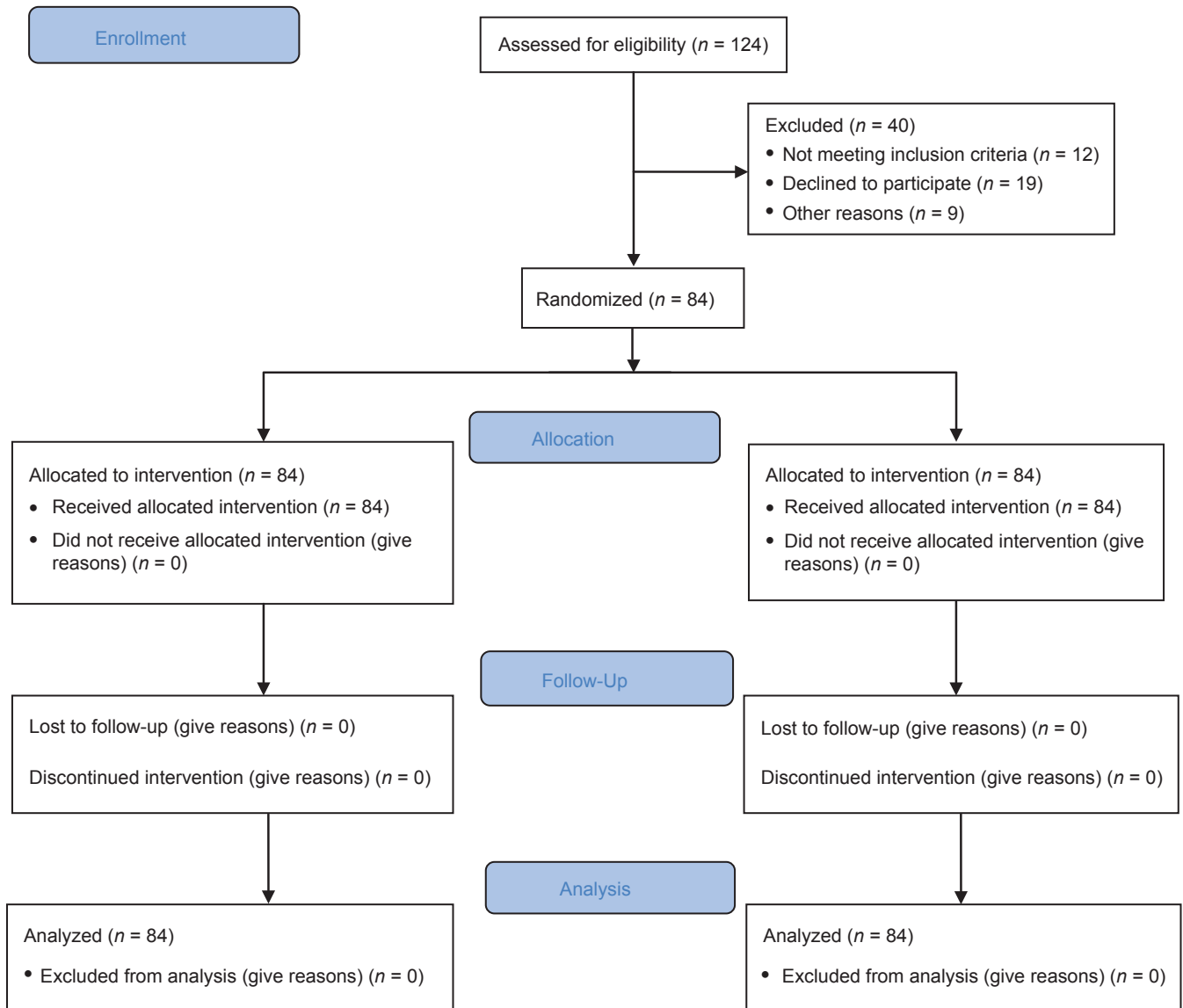
Since, the estrogen existing in combined monophasic oral contraceptives causes several complications such as spotting, nausea, vomiting, headaches, and

weight gain, in this research we decided to compare the level of estrogen existing in Ovocept-LD with that of Yaz (which is one of the modern contraceptives) according to their effect on the recovery speed of simple ovarian cysts and the extent to which they cause complications.

Yaz is one of combined monophasic oral contraceptives containing 20 µg ethinyl estradiol and 3 mg drospirenone. It is taken in a 24 day active treatment period, followed by a 4 hormone-free day period (24/4). In addition to contraceptive properties; Yaz has anti-androgenic and anti-mineralocorticoid properties. Ovocept-LD is a low-dose combined oral contraceptive containing ethinyl estradiol and norgestrel, which is prescribed to be taken in a 21-day active treatment period, followed by a 7-day non-treatment period (21/7).<sup>[12,13]</sup> The 24/4 dosage regimen of Yaz provides a shorter hormone-free period as compared to the 21/7 dosage regimen of Ovocept-LD.<sup>[14]</sup> The present study is aimed to compare the effect of Yaz and Ovocept-LD on the simple ovarian cysts of patients referring to Shariati Hospital between 2010 and 2011.

## MATERIALS AND METHODS

The present research is based on a clinical study carried out on women referring to the women's clinics of Shariati Hospital complaining of menstrual disorders and (or) abdominal pain or under abdominal pain who was diagnosed to have simple ovarian cysts by gynecologists (paraclinical) (look at the Consort 2010 flow diagram at the end of the text) [Figure 1]. Ovarian ultrasound was requested for patients, from whom 84 qualified people were selected. The patients were divided into A and B groups through randomization while they had the chance to select one of these two pills to be treated with. The group A underwent treatment with Yaz once a day and for a period of 28 days. The treatment with Ovocept-LD was carried out on group B once a day for a period of 21 days. After finishing the first period of treatment, the 2<sup>nd</sup> ovarian ultrasound was carried out and in case of no improvement for the cyst, the treatment with Yaz and Ovocept-LD was carried out on patients for the 2<sup>nd</sup> time (as the former period). Having finished the 2<sup>nd</sup> period, the treatments were compared. A check-list was prepared for samples and the cysts' diameter seen, prior and after treatment, through ultrasound was mentioned in it and the check-list was completed for both groups. The sampling was simple and the size of the sample was obtained from the following formula. Inclusion criteria included the observation of simple ovarian cyst in the ultrasound and with 3-8 cm in size and tendency of the patient to participate in the study. Exclusion criteria of study included the existence of



**Figure 1:** Consort 2010 flow diagram

relative and absolute cases of taking contraceptive pills and existence of acute abdominal symptoms such as the symptoms of peritoneal and sensitivity of uterine. Tools of collecting data were the questionnaire, interview, and method of analyzing data with SPSS software and *t*-test and Chi-square statistical methods.  $P < 0.05$  was considered as significant.

## RESULTS

The results obtained from the present study showed there was no meaningful and considerable difference between both groups regarding the number of pregnancies, the number of deliveries resulting in a live birth, the menstrual pattern before the treatment and a history of cysts. In Yaz group (A), cysts of 33 patients

were eliminated after one period of treatment; cysts of 7 patients were eliminated after two periods of treatment; cysts of two patients decreased in size after two periods of treatment. The consequence of treatment in Ovocept-LD group (B), the cysts of 5 patients were eliminated after one period of treatment; 27 patients' cysts were eliminated after two periods of treatment; 10 patients' cysts decreased in size after two periods of treatment. Based on the statistical tests, after the 1<sup>st</sup> period of treatment, the rate of response to treatment in Yaz group had been significantly more than Ovocept-LD group  $P \leq 0.01$  ( $P = 001$ ). In Ovocept-LD group after two periods of taking pills, cysts of 32 patients were eliminated and cysts of 10 patients decreased in size. In Yaz group, in total, cysts of 40 patients were eliminated after two periods of taking

pills and cysts of two patients decreased in size after same periods. The rate of response to the treatment in two periods in Yaz group had been significantly more than Ovocept-LD group ( $P = 0.026$  0 026). The mean of cyst's diameter in both groups of Yaz and Ovocept-LD had been 47/3 mm and 49/5 mm before the treatment, and after the 1<sup>st</sup> period of treatment 35/3 mm and 10/6 mm, and after the 2<sup>nd</sup> period of treatment 4/7 mm and 2/2 mm respectively. Based on the test of repeated measure, both types of pills are effective on the decrease of cysts; however, Yaz is significantly more effective (all data were stated in Tables 1-5).

## DISCUSSION

Many studies show that the Yaz has mineralocorticoid feature that can decrease bloating and fluid retention

**Table 1: Frequency distribution of the pill complications in both groups**

Yaz	Ovocept-LD	
5	19	Nausea
11	12	Spotting
3	3	Headache
25	11	Uncomplicated

**Table 2: Frequency distribution of cysts in both groups**

Yaz	Ovocept-LD	
19	19	right ovary
23	23	the left ovary

**Table 3: Frequency distribution of treatment consequence in both groups in terms of the treatment period**

Treatment	Ovocept-LD (%)	Yaz (%)
Cyst removal after 1 period of treatment	5 (11.9)	33 (78.6)
Cyst removal after 2 periods of treatment	27 (64.3)	7 (16.7)
Cyst's size reduction after 2 periods of treatment	10 (823)	2 (4.8)

**Table 4: A comparison in the cyst's diameter in both groups after and prior treatment**

Treatment	Yaz	Ovocept-LD	P
Prior to treatment	49.5	47.3	0.49
After 1 period of treatment	10.6	53.3	0.001
After 2 periods of treatment	2.2	4.7	0.3

**Table 5: Frequency distribution of treatment result in both groups**

Treatment	Ovocept-LD	Yaz (%)
Cyst full removal after treatment periods	32 (76.2)	40 (95.2)
Reduction in the cyst's size after 2 treatment periods	10 (23.8)	2 (4.8)

and has great effectiveness in preventing the pregnancy in 99% of cases. Furthermore, many studies show that the hormonal fluctuations of this pill decrease in comparison to the oral contraceptive pills.<sup>[15]</sup> A study on women suffering from polycystic ovary by Kebapcilar *et al.* showed that three periods of treatment with Yaz decreased ovarian cysts considerably.<sup>[16]</sup> In addition, a study carried out by Kriplani *et al.* on women suffering from polycystic ovary indicated that the group which had received Yaz, after 6 months, had much lower hirsutism and ovarian cysts in comparison with the control group.<sup>[17]</sup> The results of these two studies are similar to the present research. A study under the name of "hormone therapy effects on functional ovarian cysts" was carried out on 93 women. They ranged in age from 17 to 55 with one-sided and two-sided cysts with sizes of 3.1-6.1 cm. The patients were divided into two groups. The patients in group 1 were assigned the oral contraceptive pills containing 35 µg ethinyl estradiol and 1 mg norethindrone. The patients in group 2 received the oral contraceptive pills containing 50 µg ethinyl estradiol and 1 mg norethindrone. After 6 weeks, patients were appraised by transvaginal ultrasound. In group 1, during this time, the cysts of 16 (54%) patients were eradicated. Within the same time, the cysts of 19 (62%) patients from group 2 were fully eliminated. This difference statistically was meaningful.<sup>[18]</sup> A study was conducted on 239 patients whose cysts were removed. These patients were randomly assigned to 3 groups. The group 1 was left untackled after the treatment through surgery. The group 2 took the oral contraceptive pills periodically after the surgical operation. The group 3 took those pills permanently. The result of the study revealed that the recurrence of cysts was reduced considerably in those patients taking pills permanently.<sup>[19]</sup> Furthermore in Palep-Singh study has been shown that Yaz could provide good cycle control for women with PCOS.<sup>[20,21]</sup> Overall, it could be concluded because of the faster and better recovery effect, and the less important side effects of Yaz as compared to Ovocept-LD, it is recommended to use Yaz for the simple ovarian cysts.

## ACKNOWLEDGMENTS

SR carried out the plan and coordinated the study. AF participated in most of the experiments and prepared the manuscript. LD organized, finalized, and participated in manuscript preparation. All authors have read and approved the content of the manuscript.

## REFERENCES

1. Luque-Ramírez M, Alvarez-Blasco F, Botella-Carretero JI, Martínez-Bermejo E, Lasunción MA, Escobar-Morreale HF. Comparison of ethinyl-estradiol plus cyproterone acetate versus metformin effects on

- classic metabolic cardiovascular risk factors in women with the polycystic ovary syndrome. *J Clin Endocrinol Metab* 2007;92:2453-61.
2. Whiteside JL, Keup HL. Laparoscopic management of the ovarian mass: A practical approach. *Clin Obstet Gynecol* 2009;52:327-34.
  3. Holt VL, Cushing-Haugen KL, Daling JR. Risk of functional ovarian cyst: Effects of smoking and marijuana use according to body mass index. *Am J Epidemiol* 2005;161:520-5.
  4. Mavromatidis G, Sotiriadis A, Dinas K, Mamopoulos A, Rousso D. Large luteinized follicular cyst of pregnancy. *Ultrasound Obstet Gynecol* 2010;36:517-20.
  5. Engiz O, Berberoglu M, Siklar Z, Bilir P, Ocal G. Treatment of autonomous ovarian follicular cyst with long-term anastrozole therapy. *Indian J Pediatr* 2009;76:950-1.
  6. Monnayer S, Guyonnet J, Toutain PL. A preclinical pharmacokinetic/ pharmacodynamic approach to determine a dose of GnRH, for treatment of ovarian follicular cyst in cattle. *J Vet Pharmacol Ther* 2004;27:527-35.
  7. Swire MN, Castro-Aragon I, Levine D. Various sonographic appearances of the hemorrhagic corpus luteum cyst. *Ultrasound Q* 2004;20:45-58.
  8. Huang PH, Tsai KB, Tsai EM, Su JH. Hemorrhagic corpus luteum cyst torsion in term pregnancy: A case report. *Kaohsiung J Med Sci* 2003;19:75-8.
  9. Atri M. Ectopic pregnancy versus corpus luteum cyst revisited: Best Doppler predictors. *J Ultrasound Med* 2003;22:1181-4.
  10. Nguyen KT, Reid RL, Sauerbrei E. Antenatal sonographic detection of a fetal theca lutein cyst: A clue to maternal diabetes mellitus. *J Ultrasound Med* 1986;5:665-7.
  11. Lanes SF, Birmann B, Walker AM, Singer S. Oral contraceptive type and functional ovarian cysts. *Am J Obstet Gynecol* 1992;166:956-61.
  12. Feng Y, Johansson J, Shao R, Mannerås-Holm L, Billig H, Stener-Victorin E. Electrical and manual acupuncture stimulation affect oestrous cyclicity and neuroendocrine function in an 5 $\alpha$ -dihydrotestosterone-induced rat polycystic ovary syndrome model. *Exp Physiol* 2012;97:651-62.
  13. Crave JC, Fimbel S, Lejeune H, Cugnardey N, Déchaud H, Pugeat M. Effects of diet and metformin administration on sex hormone-binding globulin, androgens, and insulin in hirsute and obese women. *J Clin Endocrinol Metab* 1995;80:2057-62.
  14. Rebelo AC, Zuttin RS, Verlengia R, Cesar Mde C, de Sá MF, da Silva E. Effect of low-dose combined oral contraceptive on aerobic capacity and anaerobic threshold level in active and sedentary young women. *Contraception* 2010;81:309-15.
  15. Tanne JH. Bayer to spend \$20m to correct misleading advertising for oral contraceptive Yaz. *BMJ* 2009;338:b674.
  16. Kebapçilar L, Baghaei F, Holm G. Coagulation and fibrinolytic disturbances in woman with polycystic ovary syndrome. *J Clin Endocrinol Metab* 1968;96:2011.
  17. Kriplani A, Periyasamy AJ, Agarwal N, Kulshrestha V, Kumar A, Ammini AC. Effect of oral contraceptive containing ethinyl estradiol combined with drospirenone vs. desogestrel on clinical and biochemical parameters in patients with polycystic ovary syndrome. *Contraception* 2010;82:139-46.
  18. Alessandro D, Genazzani AP. Ovarian cystic formation during depot formulation of GnRH-A Therapy and effect of pretreatment with oral contraceptive pills on ovarian cysts. *Fertil Steril* 2008;7:109-13.
  19. Johnson N, Reilly S. The pill for ovarian cysts. *Biol Med* 2010;12:25-8.
  20. Palep-Singh M, Mook K, Barth J, Balen A. An observational study of Yasmin in the management of women with polycystic ovary syndrome. *J Fam Plann Reprod Health Care* 2004;30:163-5.
  21. Guido M, Romualdi D, Giuliani M, Suriano R, Selvaggi L, Apa R, *et al.* Drospirenone for the treatment of hirsute women with polycystic ovary syndrome: A clinical, endocrinological, metabolic pilot study. *J Clin Endocrinol Metab* 2004;89:2817-23.

**Source of Support:** Nil, **Conflict of Interest:** None declared.