

Rehabilitation for a Patient with Hemiplegia, Ataxia, and Cognitive Dysfunction Caused by Pontine Hemorrhage

Tetsuya Tsunoda^a Shinichiro Maeshima^a Makoto Watanabe^b
Ayako Nagai^b Yoshiya Ueno^b Yasunori Ozeki^a Sayaka Okamoto^a
Shiho Mizuno^a Shigeru Sonoda^a

^aDepartment of Rehabilitation Medicine II, School of Medicine, and ^bRehabilitation Center, Nanakuri Sanatorium, Fujita Health University, Tsu, Japan

Key Words

Rehabilitation · Brain stem · Pontine hemorrhage · Ataxia · Cognitive dysfunction

Abstract

Patients with pontine hemorrhage usually experience severe disturbances of consciousness, pupillary abnormalities, quadriplegia, and respiratory failure. However, little is known regarding cognitive dysfunction in patients with pontine hemorrhage. We report the case of a rehabilitation patient presenting with hemiplegia, ataxia, and cognitive dysfunction caused by a pontine hemorrhage. A 55-year-old, right-handed male suffered sudden onset of vertigo, dysarthria, and hemiplegia on the right side. He was diagnosed with brain stem hemorrhage, and conservative treatment was administered. The vertigo improved, but dysarthria, ataxia, hemiplegia, and gait disorder persisted. He was disoriented with respect to time and place and showed a poor attention span, impaired executive function, and reduced volition. A computed tomography revealed hematomas across the pons on both sides, but no lesions were obvious in the cerebellum and cerebrum. Single-photon emission tomography showed decreased perfusion in the brain stem, bilateral basal ganglia, and frontal and parietal lobes in the left hemisphere. The patient received exercise therapy and cognitive rehabilitation, and home modifications were performed to allow him to continue living at home under the supervision of his family. His symptoms improved, along with enhanced regional cerebral blood flow to the frontal and temporal lobes. These findings suggest that the pontine hemorrhage caused diaschisis resulting in secondary reduction of activity in the cerebral hemisphere and

the occurrence of cortical symptoms. Therefore, rehabilitation is necessary, along with active instructions for the family members of patients with severe neurological deficits.

© 2015 The Author(s)
Published by S. Karger AG, Basel

Introduction

Primary pontine hemorrhages are rare and account for approximately 5–10% of intracranial hemorrhages [1, 2]. However, the prognosis of the disease is poor, with the overall mortality rate being 40–50% [3, 4]. Moreover, patients with pontine hemorrhage usually experience severe disturbances of consciousness, pupillary abnormalities, quadriplegia, and respiratory failure [3, 5]. However, little is known regarding cognitive dysfunction in patients with pontine hemorrhage. Recently, we had the opportunity to examine a rehabilitation patient who presented with hemiplegia, ataxia, and cognitive dysfunction caused by a pontine hemorrhage.

Case Report

The patient was a 55-year-old, right-handed male with 12 years of experience in education, with no prior history of neurological problems, metabolic complications, or any preexisting neuropsychological conditions, and he worked as a carpenter. He was brought to the local physician by ambulance following sudden onset of vertigo, dysarthria, and hemiplegia on the right side. A brain stem hemorrhage was diagnosed based on cranial computed tomography (CT) findings, and conservative treatment for hypertension and brain swelling was initiated. The vertigo improved, but dysarthria and hemiplegia persisted. The patient was referred to our hospital for rehabilitation 25 days after the onset of stroke.

Neurological Examinations

Initial examination revealed dysarthria, horizontal nystagmus, and Horner's sign on the left side. Right-sided paralysis (Brunnstrom stage upper 2, lower 2, finger 1) including the right facial area, increased deep tendon reflex, and extensor plantar reflexes (Babinski sign) were also observed. The patient also exhibited hypoesthesia of the right side of the body, including the face, and ataxia of the left upper and lower limbs and trunk.

Neuropsychological Tests

The patient remained polite and cooperative throughout the examinations. He was disoriented and made errors regarding dates and places, although he remembered past events well and recalled childhood experiences and conversations conducted before the illness. No confabulation was observed. The results of the neuropsychological tests are shown in [table 1](#). His Mini-Mental State Examination score was 22/30, the frontal lobe assessment battery score was 7/18, and the digit span retention score was 5 for forward and 2 for reverse recalls. On the Auditory Verbal Learning Test, his immediate recall scores were 3, 6, 4, 5, and 7 of 15, the delayed recall score was 6/15, and the recognition score was 10/15, while his Raven's colored progressive matrices score was 33/36.

Neuroradiological Examination

A CT at the onset of stroke revealed hematomas across the pons on both sides, but no obvious lesions in the cerebellum and cerebrum (fig. 1). A subsequent CT, obtained 1 month later, showed that the hematoma had been absorbed and localized. However, the single-photon emission computed tomography (SPECT) imaging performed at approximately the same time revealed reduced perfusion in the brain stem, bilateral basal ganglia, and frontal and parietal lobes in the left hemisphere (fig. 2a).

Activities of Daily Living and Clinical Course

The patient could not function without help because of various neurological deficits such as severe hemiplegia and sensory impairment in the right side, limb ataxia on the left side, dysarthria, and cognitive dysfunction. The overall functional independence measure (FIM) score was 20 (13 on motor items and 7 on cognitive items; fig. 3). We set a target of the patient requiring only moderate assistance at the time of discharge.

To treat his severe ataxia and paresis, the patient received physical therapy comprising exercises to improve balance while sitting/standing and mobility in movement. Cognitive rehabilitation in occupational therapy included memory training and attention process training, which resulted in general improvement of mental functions, including improvement of attention impairment. Dysarthria was treated by a speech pathologist using brief exercises for communication skills.

The patient was encouraged to get out of bed during the day. Two weeks after admission, he could stand up and move using knee-ankle-foot orthosis with moderate assistance.

Although the right hemiplegia (Brunnstrom stage upper 3, lower 4, finger 4) and ataxia symptoms on the left side showed slight improvement, the patient exhibited increased motivation for training and could perform stand-up exercises 100 times/day under supervision and undergo walking training in the parallel bars with mild assistance. Because the patient performed stand-up exercises 300 times/day, we could improve his goal to activities of daily living (ADL) independence at home after 2 months. Additionally, we instructed his family members to provide assistance while walking. After 3 months, the patient could dress and groom independently and also eat all three meals. After 4 months, muscle strength in the lower extremities and standing balance improved, and he could go to the toilet and transfer to bed independently. He could walk with the help of an ankle-foot orthosis and a side cane, under the supervision of his family. We prescribed a plastic ankle-foot orthosis for use in the bathroom.

The patient's family was extremely cooperative, and after completion of home modifications, the patient repeated sleep-overs to train himself. He was discharged 5 months after the onset of stroke because he could walk and perform ADL, such as grooming, dressing, and eating, independently. The patient required moderate help when walking outside, and for practical purposes, he used a walker for movement. The overall FIM score was 105 (72 on motor items and 33 on cognitive items) at the time of discharge. SPECT performed at discharge showed an improvement in cerebral blood flow in the posterior fossa and the cerebral hemispheres in the frontal and temporal lobes bilaterally (fig. 2b).

Discussion

Generally, pontine hemorrhages have a poor prognosis, with generally no improvement in ADL or rehabilitation. Prognosis is particularly poor in cases that exhibit loss of consciousness, hematomas extending beyond the pons into the midbrain and medulla, ventricle

rupture and hydrocephalus, or a hematoma volume of >6 ml [6, 7]. In the present case, the hematoma was localized on the left side of the pons, there was no ventricle rupture or hydrocephalus, and bleeding was nonfatal. However, the patient still exhibited severe right hemiplegia, ataxia on the left upper and lower limbs, dysarthria, dysphagia, and cognitive impairment, all of which greatly inhibited ADL. After hospitalization, the patient gained independence in movement and exhibited improvement in cognitive impairment, enhancing his ADL scores.

Cognitive impairment caused by pathological changes in the brain stem has been gaining attention recently. D'aes and Mariën [8] reviewed 75 patients who had experienced brain stem stroke and also examined 3 additional patients and reported that affected cognitive functions such as decline in general intellectual capacity, attention, executive functions, memory, visuospatial skills, language, and praxis were observed. Hoffmann and Watts [9] reported that cognitive impairment was found in the acute phase of brain stem stroke, along with a reduction of blood flow to the frontal and parietal lobes. We previously reported that patients with pontine hemorrhages who showed improved cognitive impairment also exhibited enhanced cerebral blood flow on the tent [10]. Based on these reports, it is suggested that impaired cerebral blood flow in the cerebral hemisphere occurs during the acute phase and causes cognitive impairment. However, in the present case, because there was no direct damage to the cerebral cortex, the functional prognosis of cognitive impairment was favorable. Anatomically, corticopontocerebellar tracts are present in the pons and form the largest fiber connection connecting it to the cerebral cortex [11]. Because approximately half of the nerve fibers connecting the cerebral cortex to the cerebellar hemisphere on the other side have nerve endings in the internuclear region of the pons [12], there is a high possibility of a pontine hemorrhage interrupting this connection [13] and causing cognitive impairment. Furthermore, because the pons is related to the brain stem reticular formation regulation system and hypothalamus regulation system [14], there is the added possibility of impairment causing network dysfunction in the cerebral hemisphere. Our findings also indicate that the pontine hemorrhage causes diaschisis, resulting in secondary reduction of activity in the cerebral hemisphere and occurrence of cortical symptoms.

Setting rehabilitation goals for pontine hemorrhage patients with severe neurological disorders is often difficult [15], and it is less common for these patients to be discharged from the hospital compared to other brain hemorrhage patients [16]. In the present case, the fact that cognitive impairment improved in the early stage helped in setting higher goals. We believe that improved ADL were observed because of the cognitive function test, increased motivation for training, and promotion of rehabilitation. Rehabilitation is necessary because patients with pontine hemorrhage sometimes show cognitive impairments, which can gradually improve. However, the patient still exhibited severe neurological impairment such as right hemiplegia, ataxia of the left upper and lower limbs, and dysarthria. Although discharging him appeared difficult, his family members encouraged him to start rehabilitation after 2 months. Discharging the patient becomes easier if family members living with the patient can acquire nursing skills necessary for the care at home [17, 18]. In the present case, because the patient could move and walk with the assistance of his wife and daughter, the necessity for active instructions for the family members was recognized in the rehabilitation ward.

Statement of Ethics

All study participants provided informed consent, and the study design was approved by the appropriate ethics review boards.

Disclosure Statement

The authors declare that they have no competing interests.

References

- 1 Dzięwas R, Kremer M, Lüdemann P, Nabavi DG, Dräger B, Ringelstein B: The prognostic impact of clinical and CT parameters in patients with pontine hemorrhage. *Cerebrovasc Dis* 2003;16:224–229.
- 2 Wessels T, Möller-Hartmann W, Noth J, Klötzsch C: CT findings and clinical features as markers for patient outcome in primary pontine hemorrhage. *Am J Neuroradiol* 2004;25:257–260.
- 3 Murata Y, Yamaguchi S, Kajikawa H, Yamamura K, Sumioka S, Nakamura S: Relationship between the clinical manifestations, computed tomographic findings and the outcome in 80 patients with primary pontine hemorrhage. *J Neurol Sci* 1999;167:107–111.
- 4 Wijdicks EF, St Louis E: Clinical profiles predictive of outcome in pontine hemorrhage. *Neurology* 1997;49:1342–1346.
- 5 Del-Brutto OH, Noboa CA, Barinagarrementeria F: Lateral pontine hemorrhage: reappraisal of benign cases. *Stroke* 1987;18:954–956.
- 6 Koga N, Ueki Y, Hosaka Y, Hatashita S, Takagi S: Primary pontine hemorrhage – clinical analysis. *Jpn J Stroke* 1991;13:151–158.
- 7 Arimoto H, Takasato Y, Masaoka H, Hayakawa T, Akimoto H, Yatsushige H, Morikawa K, Sugawara T, Komachi H, Homma M: Clinical analysis of the outcome of patients with brainstem hemorrhage. *Jpn J Stroke* 2008;30:38–44.
- 8 D’aes T, Mariën P: Cognitive and affective disturbances following focal brainstem lesions: a review and report of three cases. *Cerebellum* 2015;14:317–340.
- 9 Hoffmann M, Watts A: Cognitive dysfunction in isolated brainstem stroke: a neuropsychological and SPECT study. *J Stroke Cerebrovasc Dis* 1998;7:24–31.
- 10 Maeshima S, Osawa A, Kunishio K: Cognitive dysfunction in a patient with brainstem hemorrhage. *Neurol Sci* 2010;31:495–499.
- 11 Brodal A, Hoddevik GH: The pontocerebellar projection of the uvula in the cat. *Exp Brain Res* 1978;32:105–116.
- 12 Brodal A: Cerebellar pathways. Anatomical data and some functional implications. *Acta Neurol Scand* 1972;51:153–195.
- 13 Sturm W, de Simone A, Krause BJ, Specht K, Hesselmann V, Radermacher I, Herzog H, Tellmann L, Müller-Gärtner HW, Willmes K: Functional anatomy of intrinsic alertness: evidence for a fronto-parietal-thalamic-brainstem network in the right hemisphere. *Neuropsychologia* 1999;37:797–805.
- 14 Moruzzi G, Magoun HW: Brain stem reticular formation and activation of the EEG. *Electroencephalogr Clin Neurophysiol* 1949;1:455–473.
- 15 Kimura S, Koshin K, Obayashi S, Masuhara K, Matsumoto K, Tsuruzono K: Functional prognosis in patients with brainstem hemorrhage. *Surg Cereb Stroke (Jpn)* 2011;39:262–266.
- 16 Okuda Y, Suzuki T, Tane K, Ogawa R, Takase T, Inoue T: Characteristics and outcomes of intracerebral hemorrhage from a hospital in Osaka, Japan. *Neurosurg Emerg* 2008;13:63–71.
- 17 Maeshima S, Ueyoshi A, Osawa A, Ishida K, Kunimoto K, Shimamoto Y, Matsumoto T, Yoshida M: Mobility and muscle strength contralateral to hemiplegia from stroke: benefit from self-training with family support. *Am J Phys Med Rehabil* 2003;82:456–462.
- 18 Hirano Y, Maeshima S, Osawa A, Nishio D, Takeda K, Baba M, Kigawa H: The effect of voluntary training with family participation on early home discharge in patients with severe stroke at a convalescent rehabilitation ward. *Eur Neurol* 2012;68:221–228.

Table 1. Results of neurological tests

	Admission	1 month	Discharge (5 months)
Mini-Mental State Examination (out of 30)	22	29	30
Frontal Assessment Battery (out of 18)	7	15	17
Raven's Colored Progressive Matrices (out of 36)	33	34	35
Digit span (forward/backward)	5/2	6/4	6/4
Auditory Verbal Learning Test (out of 15)			
Immediate recall (1st-5th)	3-6-4-5-7	5-8-10-9-10	12-14-14-14-14
List B	3	6	6
6th	6	9	12
Recognition	10	12	12
Delayed recall	6	7	13
Wechsler Adult Intelligence Scale 3rd edition			
Verbal IQ		107	113
Performance IQ	83	92	113
Full scale		101	114

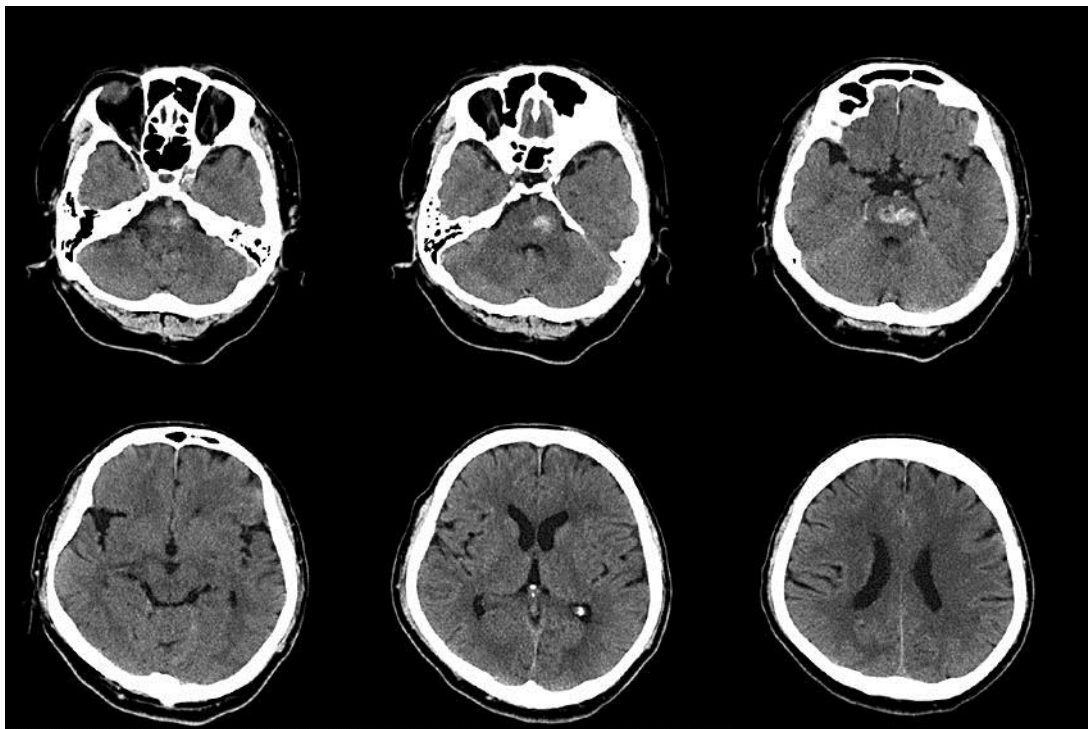


Fig. 1. CT on stroke onset. CT revealed hematomas across the pons on both sides but no obvious lesions in the cerebellum and cerebrum.

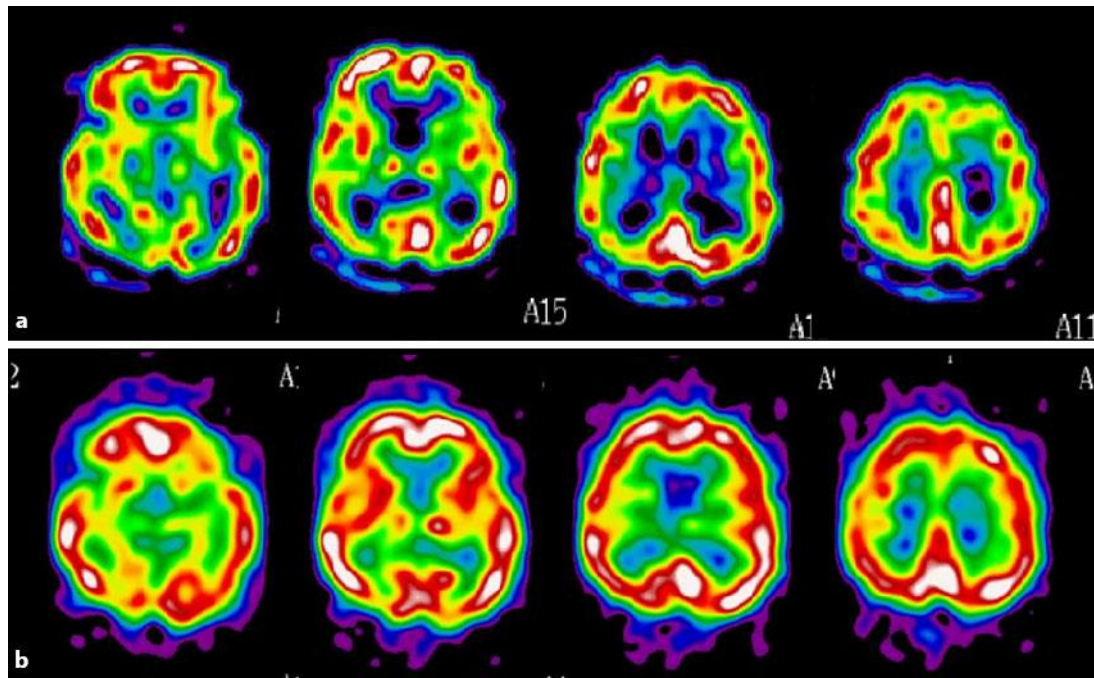


Fig. 2. SPECT 31 days (a) and 187 days (b) after stroke onset. SPECT 31 days after stroke onset revealed reduced perfusion in the brain stem, bilateral basal ganglia, and frontal and parietal lobes in the left hemisphere. SPECT 187 days after stroke onset showed an improvement in cerebral blood flow in the posterior fossa and the cerebral hemispheres in the frontal and temporal lobes bilaterally.

FIM scores

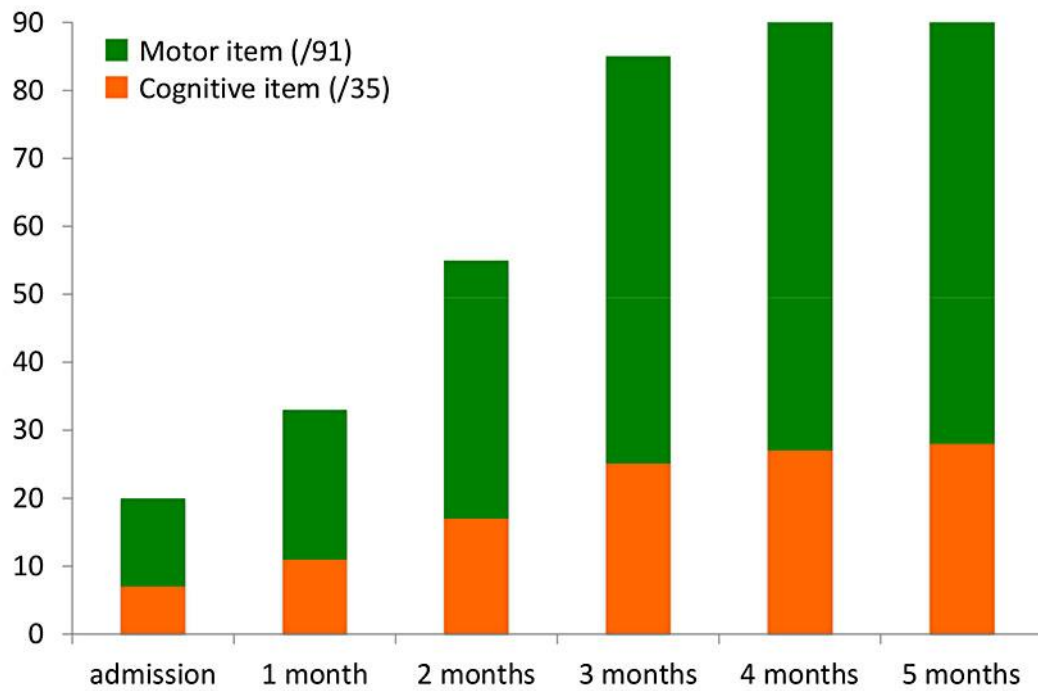


Fig. 3. Course of the FIM score. The overall FIM score was 20 (13 on motor items and 7 on cognitive items) on admission and 105 (72 on motor items and 33 on cognitive items) at the time of discharge.