

Successful Treatment of a Giant Emphysematous Bulla with an Endobronchial Valve in a Patient with Contralateral Lung Cancer

Chang-Seok Jeon, M.D.¹, Jhngook Kim, M.D.¹, Hojoong Kim, M.D.²

¹Department of Thoracic and Cardiovascular Surgery and ²Division of Pulmonary and Critical Care Medicine, Department of Medicine, Samsung Medical Center, Sungkyunkwan University School of Medicine

Patients with severe emphysema have a higher risk of developing lung cancer, and their surgical risk increases when emphysema is accompanied by a giant bulla. Here, we describe a patient who had an emphysematous giant bulla in the right upper lobe that was treated with an endobronchial valve placement. Subsequently, a cancerous lesion on the contralateral lung was successfully removed by lobectomy.

Key words: 1. Pulmonary Bullae
2. Endobronchial valve
3. Lung neoplasms

Case report

A 50-year-old man was admitted because of a left upper lobe mass. He was a current smoker with a 35 pack-year smoking history and a clinical history of pulmonary tuberculosis that had been diagnosed and treated 15 years ago. A chest computed tomography scan showed a 51-mm mass in the left upper lobe, which was strongly suggestive of lung cancer. Both of the upper lobes exhibited emphysematous changes. A giant bulla was observed in the right upper lobe, and it was large enough to fill the right upper lung zone (Fig. 1). His lung function was not a contraindication to lobectomy, with a forced expiratory volume in 1 second (FEV₁) of 2.21 (62% of predicted), a functional volume capacity (FVC) of 3.78 L (84% of predicted), and a diffusing capacity of the lung for

carbon monoxide of 67% of predicted. However, we determined that it would be too dangerous to perform one-lung ventilation surgery while leaving the giant bulla intact in the right upper lobe, so we placed an endobronchial valve (EBV) into the right upper lobar bronchus to eliminate the bullous lesion.

EBV placement was carried out under rigid bronchoscopy using the standard procedure described by Dumon [1]. Briefly, endotracheal intubation was performed using a rigid bronchoscope tube (Hopkins; Karl-Storz, Tuttlingen, Germany) under general anesthesia that was induced by intravenous propofol. Then, the initial exploration of the tracheobronchial tree was followed by a Flexible bronchoscope (EVIS BF 1T240; Olympus, Tokyo, Japan) through a rigid bronchoscope tube. After identification of the right upper lobe bronchus, three Zephyr EBVs (Pulmonx,

Received: October 24, 2016, Revised: November 14, 2016, Accepted: November 14, 2016, Published online: August 5, 2017

Corresponding author: Jhngook Kim, Department of Thoracic and Cardiovascular Surgery, Samsung Medical Center, Sungkyunkwan University School of Medicine, 81 Irwon-ro, Gangnam-gu, Seoul 06351, Korea
(Tel) 82-2-3410-3483 (Fax) 82-2-3410-0089 (E-mail) jhngookkim@gmail.com

Corresponding author: Hojoong Kim, Division of Pulmonary and Critical Care Medicine, Department of Medicine, Samsung Medical Center, Sungkyunkwan University School of Medicine, 81 Irwon-ro, Gangnam-gu, Seoul 06351, Korea
(Tel) 82-2-3410-3425 (Fax) 82-2-3410-3849 (E-mail) hjk3425@skku.edu

© The Korean Society for Thoracic and Cardiovascular Surgery. 2017. All right reserved.

© This is an open access article distributed under the terms of the Creative Commons Attribution Non-Commercial License (<http://creativecommons.org/licenses/by-nc/4.0>) which permits unrestricted non-commercial use, distribution, and reproduction in any medium, provided the original work is properly cited.

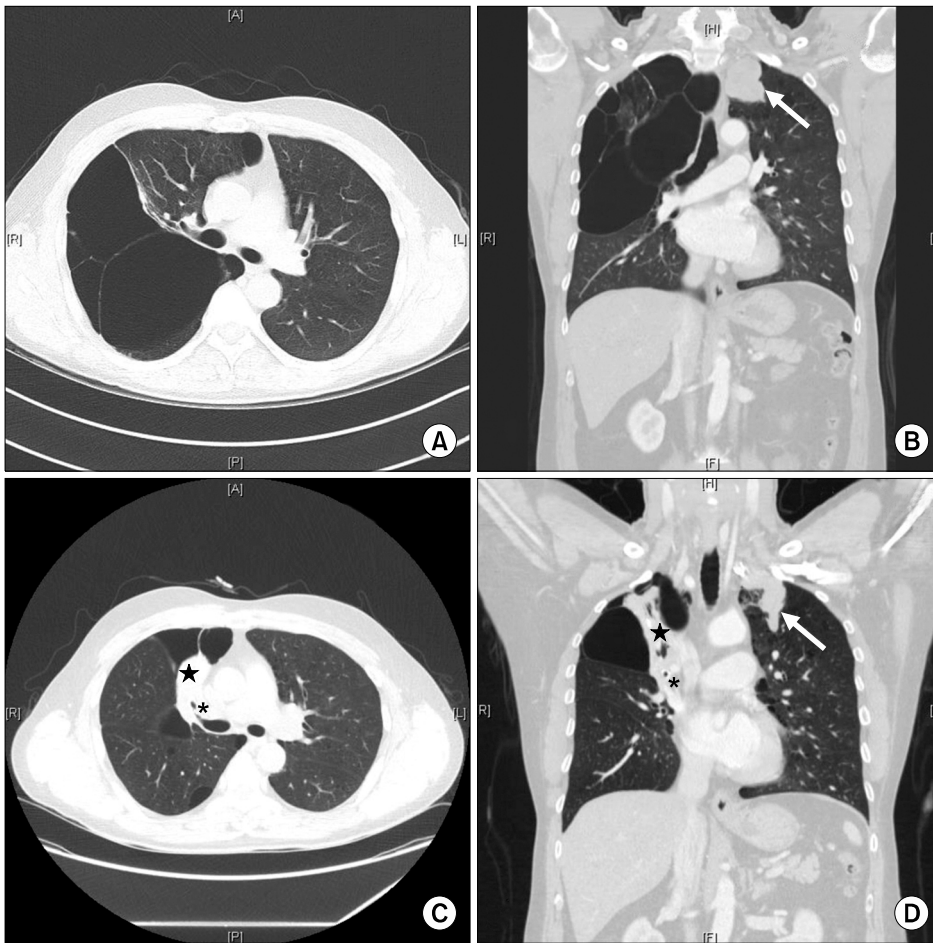


Fig. 1. A giant emphysematous bulla is shown filling the right upper lung zone, and a mass is visible in the left upper lobe (white arrow) (A, B). Placement of the endobronchial valve (*) into the right upper lobar bronchus caused atelectasis (black star) of the right upper lobe and a reduction in the size of the giant bulla (white arrow) (C, D).

Redwood City, CA, USA) were inserted into each segment of the right upper lobe bronchus. All valves showed good function when negative pressure was applied.

After EBV placement, we measured the FEV₁ and FVC, which were 2.62 L (73% of predicted) and 3.88 L (85% of predicted), respectively. Two weeks after the first EBV placement, we reinserted the EBV because of migration. Two weeks after reinsertion, a left upper lobectomy was performed.

After administering general anesthesia to the patient, a double-lumen endotracheal tube was placed on the left side. One-lung ventilation was performed in the right lateral decubitus position, and video-assisted thoracic surgery was used to perform left upper lobectomy and mediastinal lymph node dissection. Intraoperatively, a constant positive end-expiratory pressure of 5 cm H₂O was maintained, and the tidal volume remained constant at approximately

280 mL. A constant peak pressure of less than 25 cm H₂O was also maintained. No adverse events occurred intraoperatively. Results of the pathological examination confirmed the presence of stage T2bN0 (tumor 2b, node 0) squamous cell carcinoma.

The patient had an uneventful recovery, and he was discharged on the fifth postoperative day. After discharge, he underwent an outpatient lung function test, and the FVC and FEV₁ were 2.91 L (69% of predicted) and 2.06 L (62% of predicted), respectively.

Discussion

Severe emphysema is associated with a high risk of lung cancer. A person with an emphysematous giant bulla in the right lung and cancer in the left lung, like that of the described patient, has a high surgical risk. When conventional one-lung ventilation is performed, the dependent lung with the giant bul-

la may be easily distended due to positive ventilation, which may worsen ventilation-perfusion matching. Furthermore, the intraoperative rupture of a bulla may lead to life-threatening tension pneumothorax [2]. One surgical technique that can be used to avoid such risks is bullectomy [3,4]. However, it is an invasive procedure, and complications, such as persistent air leakage, are a concern. Alternatively, non-intubated thoracoscopic surgery can be used to treat such patients [5]. Yet, it is not easy to perform conversion from non-intubated anesthesia to intubated anesthesia in patients with bleeding or other unanticipated complications, and once conversion to intubation is complete, physicians are unable to protect the dependent lung from positive pressure.

As shown in the present case, another procedure that can be considered is EBV placement. The efficacy and safety of EBV placement have been investigated in a prospective, multi-center, randomized controlled trial (the Emphasys Bronchial Valve for Emphysema Palliation Trial study). Scirba et al. [6] conducted a study of 321 patients, 220 of whom were randomly assigned to receive EBVs (the EBV group) and 101 of whom were assigned to receive standard medical care (the control group). The EBV group showed modest improvements in lung function, exercise tolerance, and symptoms at the cost of more frequent exacerbations of chronic obstructive pulmonary disease, pneumonia, and hemoptysis after implantation. Furthermore, a few case reports have described performing EBV placement before lung resection surgery, but large-scale studies on this topic are lacking. Garzon et al. [7] performed EBV placement to treat emphysematous bullae in both lower lobes of a patient with a FEV₁ of 0.61 L (39% of predicted). They confirmed that the FEV₁ improved to 1.46 L (75% of predicted) and also reported that a left upper lobe nodule detected during follow-up was removed by wide wedge resection. Fiorelli et al. [8] described 2 patients in whom they performed wedge resection of contralateral lung cancer found during follow-up after EBV placement. In our case, the goal of the EBV was to minimize the effect of positive pressure ventilation by blocking the airway

into the bullae, rather than to improve lung function. As expected, no injury to the dependent lung or desaturation occurred.

To the best of our knowledge, this is the first English-language report to describe EBV placement in a patient with an emphysematous giant bulla before performing lobectomy on the contralateral side. In the future, large cohort studies investigating the efficacy and safety of this treatment option are needed to determine whether it is widely applicable to such patients.

Conflict of interest

No potential conflict of interest relevant to this article was reported.

References

1. Dumon JF. A dedicated tracheobronchial stent. *Chest* 1990;97:328-32.
2. Arai H, Tajiri M, Ebuchi K, et al. *Contralateral tension pneumothorax during video-assisted thoracoscopic surgery for lung cancer: a case report*. *Clin Respir J* 2016 Feb 16 [Epub]. <https://doi.org/10.1111/crj.12470>.
3. Harvey KP, Adair J, Basoor A, Just J. *Resection of lung cancer after contralateral bullectomy in a high risk patient*. *Am Surg* 2008;74:1116-7.
4. Johnson KT, Funahashi A. *Severe bullous emphysema and contralateral bronchogenic carcinoma: successful management with staged bilateral thoracotomy*. *Wis Med J* 1985;84:11-4.
5. Lu YF, Hung MH, Hsu HH, Chen JS. *Non-intubated thoracoscopic segmentectomy for second primary lung cancer in a patient with previous contralateral lobectomy and emphysematous bullae*. *J Cardiothorac Vasc Anesth* 2016;30:1639-40.
6. Scirba FC, Ernst A, Herth FJ, et al. *A randomized study of endobronchial valves for advanced emphysema*. *N Engl J Med* 2010;363:1233-44.
7. Garzon JC, Ng CS, Lee TW, Yim AP. *Video-assisted thoracic surgery lung resection after endobronchial valve placement*. *J Thorac Cardiovasc Surg* 2006;131:499-500.
8. Fiorelli A, Costanzo S, di Costanzo E, Santini M. *The early detection of lung cancer during follow-up of patients undergoing endobronchial one-way valve treatment for emphysema*. *Arch Bronconeumol* 2015;51:e13-5.