

Proximal Hypospadias Repair using the Koyanagi-Hayashi Technique. A Review of 15 Cases

Mouafo Tambo Faustin, A. S. Nwaha Makon, C. Kamadjou, G. Fossi, O. G. Andze, M. A. Sosso, P. Y. Mure

Department of Pediatric Surgery, Yaoundé Gynaeco-Obstetric and Paediatric Hospital, Yaoundé, Cameroon

Abstract

Background: Several surgical approaches or modifications of existing techniques have been described for the repair of hypospadias. In Sub-Saharan Africa, a two-stage approach is the preferred option in proximal cases with severe penile curvature. **Objective:** The authors describe their experience with one-stage repair of proximal hypospadias with severe penile curvature using the Koyanagi-Hayashi technique. **Methodology:** Three hundred and ten patients were seen at the outpatient clinic from November 2009 to November 2015. All patients aged between 2 and 17 years with a confirmed diagnosis of proximal hypospadias and operated according to the Koyanagi-Hayashi technique were included in the study. **Results:** The mean age at diagnosis was 6.7 ± 4.35 years (81 months). The level of the hypospadias was penile in 60%, scrotal 33.5%, and posterior in 6.6% of cases. The most common complications after primary repair were partial breakdown of the urethroplasty (44.8%), urethra-cutaneous fistula (3.3%), dehiscence of the glanuloplasty (22.2%), and recurrent penile curvature (11.1%). **Discussion:** The high psychological implication of this condition in children and adolescents at the time of diagnosis in our context was a major weakness of our study. However, it turned out to be an advantage as the patients could be involved in the decision-making in as much as the previous gender was taken into consideration. **Conclusion:** A one-stage repair approach as described by Koyanagi-Hayashi also provides good aesthetic and functional outcome. It thus stands out as an alternative even in our African setting.

Keywords: Cameroon, Koyanagi-Hayashi, proximal hypospadias

INTRODUCTION

Several surgical approaches or modifications of existing techniques have been described for the repair of hypospadias.^[1] This surgery is even more challenging in the most severe forms due to the important chordee associated. In Sub-Saharan Africa cytogenetic and molecular studies are not readily available, hence it is difficult to obtain a precise diagnosis. In addition, lack of delicate instruments for microsurgery and high infection rates due to the hot and humid tropical climate has led most authors such as Bankole *et al.*^[2] to recommend a two-stage repair approach. Analysing the results of a prospective cohort of 12 cases of severe hypospadias managed in the paediatric surgery unit of the Gynaeco-obstetric, and Paediatric Hospital, Yaoundé (YGOPH) reopened the debate on one-stage versus two-staged techniques. Given the absence of social security in our country and in selected cases presenting with an intact preputial foreskin, we carried out a one-stage repair as described by Koyanagi-Hayashi^[3]

with at least similar results as those previously reported in the literature.

The purpose of this study was thus to report our experience and assess the feasibility of one-stage repair technique for severe proximal hypospadias reconstruction in an African context.

METHODOLOGY

This was a retrospective case series, conducted at the Paediatric Surgery Department, YGOPH in collaboration with the University teaching hospitals of Geneva and Lyon and the non-governmental organization (NGO) 'Children Action' in Geneva. Weekly clinic days for genito-urinary

Address for correspondence: Prof. Mouafo Tambo Faustin, Department of Paediatric Surgery, Yaoundé Gynaeco-Obstetric and Paediatric Hospital, P.O. Box 4362, Yaoundé, Cameroon. E-mail: faustintambo@yahoo.fr

Received: 11-03-2015 Accepted: 12-08-2015 Available Online: 05-08-2020

Access this article online

Quick Response Code:



Website:
www.afrijpaedsurg.org

DOI:
10.4103/ajps.AJPS_16_15

This is an open access journal, and articles are distributed under the terms of the Creative Commons Attribution-NonCommercial-ShareAlike 4.0 License, which allows others to remix, tweak, and build upon the work non-commercially, as long as appropriate credit is given and the new creations are licensed under the identical terms.

For reprints contact: WKHLRPMedknow_reprints@wolterskluwer.com

How to cite this article: Faustin MT, Makon AS, Kamadjou C, Fossi G, Andze OG, Sosso MA, *et al.* Proximal hypospadias repair using the Koyanagi-Hayashi technique. A review of 15 cases. Afr J Paediatr Surg 2018;15:142-5.

malformations were started at the YGOPH. Over a period of 5 years (2009 to 2014), a total of 310 patients were referred to our clinic of which 100 were labelled as hypospadias. Selected patients were those aged between 2 and 17 years who had been operated upon according to the Koyanagi-Hayashi technique. All patients without a precise diagnosis were excluded.

The samples for genetic and molecular studies were sent to the biotechnology laboratories in Geneva and Lyon. All the expenses were covered by the NGO «Children Action», the parents paid only the ward fees.

The surgical procedures steps as described elsewhere. They were all performed under general anaesthesia associated with a caudal block. Patients with a micropenis received preoperative hormonal stimulation. The androgenic stimulation protocol performed was intramuscular testosterone at a dose of 100 mg/m². All patients received the same post-operative protocol, including ditropan, diazepam, and oral sulfamethoxazole-trimetropin cover until the catheter was removed.

The cosmetic outcome was measured in terms of the final site of meatal opening, the quality of healing (scar tissue). The straightening of the penis and good urinary stream at micturition were the criteria used to assess functional outcome.

Data were collected according to age, degree of penile curvature, level of the division of the corpus spongiosum, karyotype, the length of the urethroplasty, the anti-mullerian hormone levels, and the position of the neomeatus, occurrence of complications and the median follow-up.

The procedure was done following the steps as described by Koyanagi-Hayashi:

- Patient lying in supine position, skin preparation done
- Exposition of prepuce with four sutures as landmarks
- Incision lines drawn
- Catheter passed in the ectopic meatus
- Mobilisation of the dorsal skin of the glans freeing the flap till the pedicle
- Fully degloving of the penile skin shaft and freeing of all ventral tissues and the corpora cavernosa [Figure 1]
- Excision of the underlying urethra
- Freeing the urethral plate from the corpora cavernosa down to the normal urethra to archive penile rectitude
- Artificial erection test
- Urethroplasty
 - A long wide strip of mucosa is harvested from the penile shaft skin in continuity with the preputial hood
 - The strip is incised longitudinally to make it wide enough
 - The strip is then transferred ventrally and subsequently tubularised creating a neourethra [Figure 2]
 - Reconstruction of the ventral radius of the penis
- Covering the neourethra with healthy surrounding tissues (spongioplasty) or from subcutaneous scrotal, or dorsal penile tissues
- Reconstruction of the neo meatus (meatoplasty)

- Reconstruction of the ventral aspect of the glans (glanuloplasty)
- Creation of a mucosal collar around the glans
- Covering the penile skin with or without preservation of the foreskin [Figure 3]

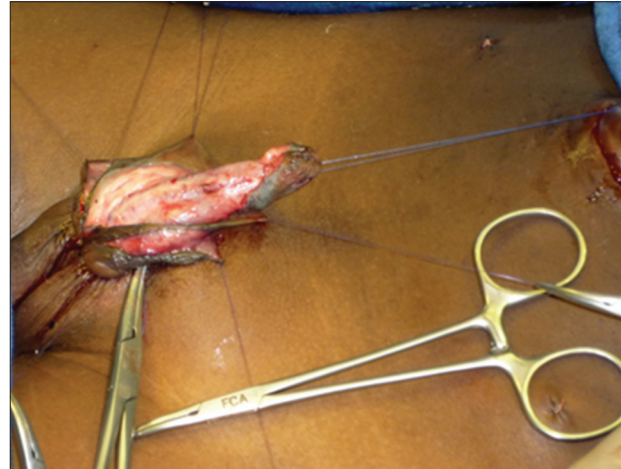


Figure 1: Degloving of the penile skin shaft, freeing all ventral skin

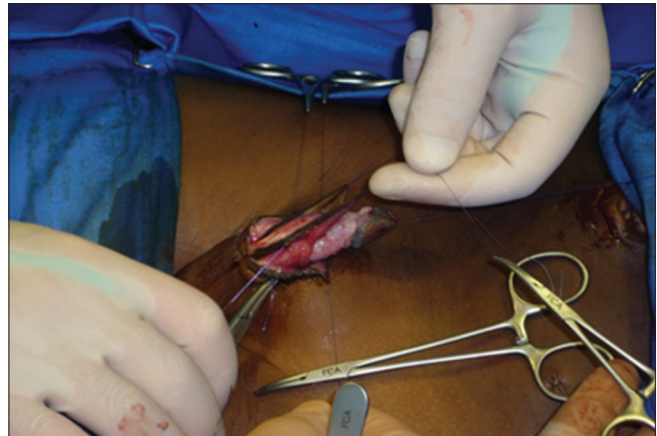


Figure 2: Tubularisation of the flap creating a neourethra

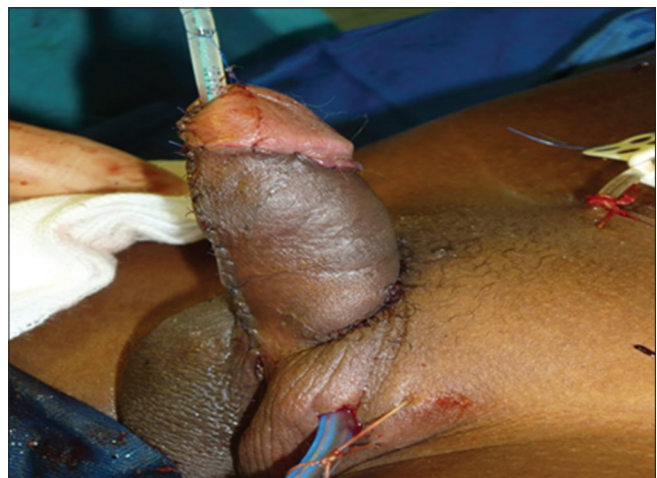

Figure 3: Immediate post-operative aspect

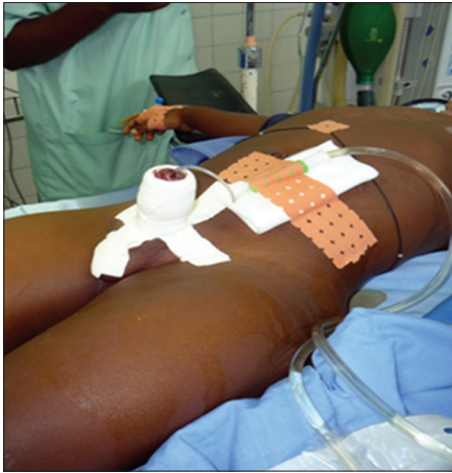

Figure 4: 'Marguerite' dressing

- Dressing using lalugen, a silicone mesh (Mepitel), and a 'Marguerite' bandage [Figure 4].

RESULTS

The outcome of 15 patients operated at our institution using the above technique from 2009 to 2014 was analysed.

The mean age at the first visit was 81 months (24–180 months), whereas mean age at surgery was 102 months (48–204 months). All 15 patients had severe chordee (>30). The ectopic meatus was perineal, peno-scrotal, and posterior in 60%, 33.3%, and 6.6%, respectively. Associated abnormalities were found in 80% of cases with cryptorchidism being the most frequent 66.7%, followed by the hypoplastic penis and scrotal transposition in 41.7% of cases. Cytogenetic studies revealed no abnormality, 13 karyotypes were 46, XY and 02 others 46, XX. These 2 patients had been brought up as boys. Four main complications were recorded in our series: the Partial breakdown of the urethroplasty (44.4%), urethrocutaneous fistula (33.3%), glanular dehiscence (22.2%), and residual chordee (11.1%). No surgical site infection was noted in our series. Most (75%) of the cases with breakdown were reported within 1-month of the procedure and repair by tubularisation following the Thiersch-Duplay procedure was successfully carried out in 1 patient. Regarding complications, urethrocutaneous fistulas occurred earliest within 11th–60th post-operative days, glanular dehiscence occurred within 1-month, and residual chordee was reported later within 3 months. Final functional and cosmetic results were satisfactory in 73% of cases. Eleven patients (73.1%) had no post-operative complications and the 4 patients with a partial breakdown are awaiting another operation. The median follow-up was 16.35 months (4.72–30.29 months) [Figure 5].

DISCUSSION

Delayed diagnosis is constant in most developing countries. Tertiary centres are scarce, and the cost of treatment is quite high. In some parts of Africa, this is complicated by

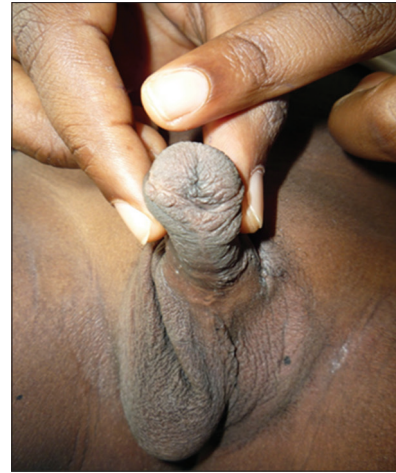

Figure 5: Follow-up after 2½ years

unawareness and some deleterious cultural and religious beliefs. Hence, the majority of hypospadias patients in Africa are referred late already circumcised or with signs of mutilation due to failed repair or cultural practices. The mean age at the time of diagnosis in our cohort is higher than those of Bankole *et al.*^[2] in Cote d'Ivoire (40 months) and Appeadu-Mensah and Hesse^[4] in Ghana (64.8 months). This difference can be explained by the time lapse required to obtain an accurate diagnosis by way of cytogenetics and molecular studies which were done in Geneva and Lyon. The 2 patients with a 46 XX karyotype had been raised as boys. As recommended by most authors in 2014,^[1,2,5-7] karyotyping and anti-mullerian hormone levels were seldom in all our patients. We used a multidisciplinary team approach and both the parents and the patient were involved in the decision-making process. This could thus be considered as an advantage of the late diagnosis since the sex of rearing, and the child's opinion was considered in the choice of the surgery. However, the marked psychological impact of this condition in the patients still constituted a major weakness in this study. The overall morbidity in our series was comparable to those reported by other authors^[1-3,7,8] who used a two-stage approach.

This led the authors to suggest that the one-stage proximal hypospadias repair technique stands as an adequate alternative in developing countries due to the lack of a health insurance system. However, the Koyanagi-Hayashi technique requires the presence of an intact preputial foreskin. We thus better understand why circumcision should not be a systematic practice.

CONCLUSION

Our report suggest that one-staged proximal hypospadias repair is feasible even in Africa, and the outcome is at least similar when compared to other two-staged approaches reported in the literature.

Financial support and sponsorship

Nil.

Conflicts of interest

There are no conflicts of interest.

REFERENCES

1. Baskin LS, Ebbers MB. Hypospadias: Anatomy, etiology, and technique. *J Pediatr Surg* 2006;41:463-72.
2. Bankole RS, Nandiolo R, Yao B, Tambo F, Vodi L, Mobiot L. Treatment of hypospadias after the Treichville teaching hospital (Abidjan). *Prog Urol* 2007;17:860-2.
3. Sugita Y, Tanikaze S, Yoshino K, Yamamichi F. Severe hypospadias repair with meatal based paracoronal skin flap: The modified Koyanagi repair. *J Urol* 2001;166:1051-3.
4. Appeadu-Mensah VV, Hesse AA. Hypospadias surgery at Korle-Bu teaching hospital, Ghana: A review of 36 patients. *Afr J Paediatr Surg* 2007;4:61-3.
5. Hinman F, Baskin LS. Hypospadias. *Hinman's Atlas of Pediatric Urologic Surgery*. 2nd ed. Philadelphia: Saunders Elsevier; 2008. p. 653-61.
6. Borea JG, Retik AB. Hypospadias. *Campbell-Walsh Urology*. 9th ed. Philadelphia: Saunders; 2007. p. 3703-10.
7. Kraft KH, Shukla AR, Canning DA. Hypospadias. *Urol Clin North Am* 2010;37:167-81.
8. Hayashi Y, Kojima Y. Current concepts in hypospadias surgery. *Int J Urol* 2008;15:651-64.