



OPEN ACCESS

Original research

Bi-allelic loss-of-function variants in *KIF21A* cause severe fetal akinesia with arthrogryposis multiplex

Ruth J Falb,¹ Amelie J Müller,¹ Wolfram Klein,² Mona Grimmel,¹ Ute Grasshoff,¹ Stephanie Spranger,³ Petra Stöbe,¹ Darja Gauck,¹ Alma Kuechler,⁴ Nicola Dikow,⁵ Eva M C Schwaibold,⁵ Christoph Schmidt,⁶ Luisa Averdunk,⁷ Rebecca Buchert,¹ Tilman Heinrich,¹ Natalia Prodan,⁸ Joohyun Park ,¹ Martin Kehrler,¹ Marc Sturm,¹ Olga Kelemen,¹ Silke Hartmann,⁶ Denise Horn,⁹ Dirk Emmerich,¹⁰ Nina Hirt,¹¹ Armin Neumann,¹² Glen Kristiansen,¹³ Ulrich Gembruch,¹⁴ Susanne Haen,¹⁵ Reiner Siebert,¹⁶ Sabine Hentze,¹⁷ Markus Hoopmann,⁸ Stephan Ossowski,¹ Stephan Waldmüller,¹ Stefanie Beck-Wödl,¹ Dieter Gläser,⁶ Ismail Tekesin,¹⁸ Felix Distelmaier ,⁷ Olaf Riess,^{1,19} Karl-Oliver Kagan,⁸ Andreas Dufke,^{1,19} Tobias B Haack ^{1,19}

► Additional supplemental material is published online only. To view, please visit the journal online (<http://dx.doi.org/10.1136/jmedgenet-2021-108064>).

For numbered affiliations see end of article.

Correspondence to

Dr Amelie J Müller;
Amelie.Mueller@med.uni-tuebingen.de

RJF and AJM contributed equally.

Received 27 June 2021
Accepted 14 October 2021
Published Online First 5 November 2021

ABSTRACT

Background Fetal akinesia (FA) results in variable clinical presentations and has been associated with more than 166 different disease loci. However, the underlying molecular cause remains unclear in many individuals. We aimed to further define the set of genes involved.

Methods We performed in-depth clinical characterisation and exome sequencing on a cohort of 23 FA index cases sharing arthrogryposis as a common feature.

Results We identified likely pathogenic or pathogenic variants in 12 different established disease genes explaining the disease phenotype in 13 index cases and report 12 novel variants. In the unsolved families, a search for recessive-type variants affecting the same gene was performed; and in five affected fetuses of two unrelated families, a homozygous loss-of-function variant in the *kinesin family member 21A* gene (*KIF21A*) was found.

Conclusion Our study underlines the broad locus heterogeneity of FA with well-established and atypical genotype–phenotype associations. We describe *KIF21A* as a new factor implicated in the pathogenesis of severe neurogenic FA sequence with arthrogryposis of multiple joints, pulmonary hypoplasia and facial dysmorphisms. This hypothesis is further corroborated by a recent report on overlapping phenotypes observed in *Kif21a* null piglets.

INTRODUCTION

Fetal akinesia (FA) comprises a clinically heterogeneous group of disorders characterised by absent or reduced fetal movements resulting in a variety of secondary deformations.¹ Associated clinical presentations range in severity from distal arthrogryposis, multiple pterygium syndrome and arthrogryposis multiplex congenita (AMC) to severe FA deformation sequence (FADS) or lethal congenital contracture syndrome.² Observed clinical features might overlap between these entities and depend

on the degree and time point of the movement impairment during pregnancy. Consistent findings include joint contractures, reduced skeletal muscle mass, subcutaneous oedema, fetal hydrops, pulmonary hypoplasia, intrauterine growth restriction and craniofacial dysmorphisms.^{3–4} Additional organ systems might be involved as part of a broad syndromic spectrum associated with the primary cause of FA. While many of these conditions are recognised in utero, others are not detected until birth.⁵

The causes of FA are diverse and include maternal or environmental causes as well as a rapidly growing number of genetic factors with at least 166 distinct loci being firmly associated with FA to date.⁶ Although individually rare, they collectively account for an incidence of multiple joint contractures in 1/2000–1/5000 live births.^{7,8}

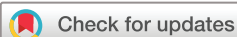Significant progress has been made over the last years to define the set of genes involved and substantially improve the diagnostic yield.^{6–9,10} However, despite the wide availability of exome sequencing even in a prenatal routine diagnostic setting, a relevant portion of affected individuals and their families remain without a firm diagnosis. This situation complicates genetic counselling of families regarding prognosis and risk of recurrence and prevents the development of targeted therapeutic approaches.

We report the results of an exome sequencing study in 23 index cases prenatally or perinatally diagnosed with FA. In addition to the diagnostic evaluation of known disease genes, an extended analysis to prioritise potential new disease genes was performed in a scientific context.

MATERIALS AND METHODS

Study cohort

Written informed consent was obtained from all probands or legal guardians. The affected individuals and their families were recruited in routine



© Author(s) (or their employer(s)) 2023. Re-use permitted under CC BY-NC. No commercial re-use. See rights and permissions. Published by BMJ.

To cite: Falb RJ, Müller AJ, Klein W, et al. *J Med Genet* 2023;**60**:48–56.

clinical care at different sites. Apart from family 22, which has been investigated at the genetikum Stuttgart, all other biosamples were submitted for exome-based prenatal or postnatal diagnostic testing to the Institute of Medical Genetics and Applied Genomics (Tübingen). All individuals had intrauterine or perinatal clinical presentations suggestive of FA and shared arthrogryposis with contractures of the joints in at least two different body parts as a common feature.⁴ In-depth phenotyping included evaluation of prenatal fetal organ abnormalities, whenever possible the clinical findings from follow-up examinations or the autopsy documentation from fetal pathologist in prenatally lethal FA or terminated pregnancies. Data and clinical reports were provided by the primary specialised healthcare provider of the patients.

Genetic studies

Exome sequencing was conducted on genomic DNA of at least one affected proband per family. Coding genomic regions were enriched using a SureSelect XT Human All Exon Kit V.6 or V.7 (Agilent Technologies, Santa Clara, California, USA) for subsequent sequencing as 2×125 or 2×100 bp paired-end reads on a HiSeq2500 or NovaSeq6000 system (Illumina, San Diego, California, USA). Generated sequences were analysed using the megSAP pipeline (<https://github.com/imgag/megSAP>). Clinical variant prioritisation included different filtering steps (eg, minor allele frequency (MAF) <0.1% in 1000g, ExAC or gnomAD (<https://gnomad.broadinstitute.org>; assessed June 2021), and an in-house database) and was conducted independently by two trained diagnostic molecular geneticists according to an in-house standard operating procedure. Trio exome analyses were performed as part of a fast track process established at the institute for prenatal investigations and paediatric intensive care patients. For these cases, a final diagnostic report was achieved within 9–23 days with a mean turnaround time of 14.7±4.8 days (median 15 days).

In patient F22:II.4, a Human Core Exome kit (Twist Bioscience, South San Francisco, California, USA) was used for enrichment of coding sequences and generated libraries were sequenced on a NextSeq 500 platform (Illumina, San Diego, California, USA). Generated bam files were transferred for secondary evaluation using the megSAP pipeline.

Subsequent variant validation and carrier testing of additional family members was performed by Sanger sequencing. Primer sequences and PCR conditions are available upon request.

Prioritised variants were classified following the recommendations of the American College of Medical Genetics and Genomics.¹¹ Affected individuals carrying likely pathogenic or pathogenic clinically relevant variants were considered to have a firm diagnosis. Patients harbouring a likely pathogenic variant compound heterozygous with a variant of uncertain significance were considered to be potentially solved.

For candidate disease gene prioritisation, a cohort analysis of the eight unsolved index cases was performed to identify potentially pathogenic variants in genes affected in more than one index case.

RESULTS

Phenotypical FA spectrum

Twenty-three index patients diagnosed with FA were recruited as part of the study. In addition, 5 further affected siblings were examined for a total of 28 patients. Of these, 14 were male and 14 were female. In 17 cases, the pregnancy was terminated, the child was stillborn or died shortly after birth. One patient died at the age of 2.5 months. Ten patients were alive with ages ranging

from 2 months to 9 years. Documented phenotypical features are summarised in [tables 1 and 2](#) as well as in online supplemental table S1.

Diagnostic yield in FA

In 13 of 23 (56%) of the index cases, the disease-causing variants were detected in 12 different known FA-associated genes. Apart from *TTN*, which was observed in two families, all other gene defects were identified only once ([table 1](#)). We observed a total of 17 unique variants of which 12 have not been reported previously. In 7 of 13 (54%) of the individuals with genetically confirmed FA, the pattern of inheritance was compatible with autosomal recessive inheritance. Of these, two of seven (29%) of the cases carried homozygous variants. A hemizygous change in X-chromosomal *GPC3* was inherited from a healthy heterozygous carrier mother. In 3 of 13 (23%) of the firm diagnoses de novo, dominant variants were identified as the likely cause of the disease. Of note, two heterozygous changes were maternally inherited with the mother being similarly affected (F9) or having a milder disease presentation associated with a mosaic state of the variant (F1). Two of 23 (9%) of the index cases remained unsolved with variants of uncertain significance in the OMIM FA disease genes *SLC6A9* and *BICD2* (a detailed discussion of the phenotypical and molecular findings is provided in the online supplemental data). In 8 of 23 (35%) of the cases, no suggestive variants in OMIM disease genes were prioritised and the molecular cause remained unclear in a diagnostic context.

Bi-allelic *KIF21A* loss-of-function variants in FA

In the eight unsolved index patients, an extended analysis was performed to investigate putative novel gene–disease associations. Pathogenic variants in known FA genes were absent in these eight families. DNA variant lists of the eight unsolved index cases were jointly investigated using strict filters for allele frequency, function and conservation. *KIF21A* was identified in a search for genes shared across these FA families carrying rare bi-allelic variants. The required filters were non-synonymous homozygous or putatively compound heterozygous variants, rare in gnomAD (MAF <0.001), and predicted to cause functional damage (combined annotation dependent depletion, >20). This filtering strategy left two index cases, individuals F22:II.4 and F23:II.1, carrying different homozygous predicted loss-of-function variants in *KIF21A* (NM_001173464.2): the stop variant c.1346T>A, (p.Leu449*) in exon 9 and the frameshift variant c.2371del, (p.Arg791Glufs*8) in exon 17 ([figure 1B](#)). The mutant transcripts are likely to be degraded by nonsense-mediated mRNA decay. Both changes were not observed in gnomAD and an in-house database containing exome and genome datasets of >15 000 individuals with unrelated phenotypes. No other bi-allelic protein-truncating variants (PTVs) in *KIF21A* were observed in these databases. Sanger sequencing confirmed a homozygous state of the familial *KIF21A* variants in all affected fetuses with the parents and a healthy sibling being heterozygous carriers.

Phenotypes associated with loss of *KIF21A*

The clinical features observed in a total of five similarly affected *KIF21A*-mutant fetuses from two families are summarised in [table 2](#) and listed in detail in online supplemental table S2. Pedigrees of families F22 and F23 as well as representative ultrasound findings are provided in [figure 1A and C–J](#). Both families originate from Turkey and consanguinity was reported for parents of family F22.

Table 1 List of genetic variants and clinical details of individuals with a likely diagnosis

Patient ID #	Family #	Gender/Age at inclusion or death* or termination of pregnancy (TOP)	Affected gene	Reference sequence ID	DNA change	Predicted AA change	Variant classification (ACMG)	Zygosity	Published (PMID)/not published	OMIM phenotype (mode of inheritance)	Aetiological classification (OMIM diseases)	Prenatal abnormalities	Joint contractures (prenatal or postnatal)	Dysmorphic features	Neurological abnormalities	Other features
F1:II.1	1	F/TOP (17 WGA)	ACTA1	NM_001100.4	c.[226G>C]n=	p.[(Gly76Arg)]:(=)	Likely pathogenic	Heterozygous (maternal mosaicism; mother with generalised, asymmetric structural myopathy but no contractures)	Not published to date	#616852 (AD), #253310, #161800 (AD +AR)	Myogenic (myopathy, nemaline myopathy 3)	RFM, ulnar deviation of the hands	Shoulders, elbows, wrists, fingers, hips, talipes equinovarus (bilateral)	Macrocephaly, hyperlordosis, telecanthus, protusio bulbi, micrognathia and retrognathia, short philtrum, cleft palate, low-set ears, microstomia, ptosis at axillae and elbows and camptodactyly	—	Amyploplasia of abdominal wall, spine muscles, and diaphragm, pulmonary hypoplasia, pectus carinatum, atropsoeal defect, anal ectopia, scoliosis
F2:II.1	2	M/O month (33 WGA)**	CHAT	NM_020984.3	c.[3G>A];[487C>T]	p.[(Met ?)];[(Arg163Trp)]	Likely pathogenic VUS	Compound heterozygous	Not published to date/not published to date	#254210 (AR)	Neuromuscular junction (congenital myasthenic syndrome 6)	RFM, polyhydramnios, pulmonary hypoplasia, hydrops fetalis	Multiple joint contractures, rocker-bottom feet	—	—	RI, pulmonary hypoplasia
F2:II.2	2	F/TOP (23 WGA)	CHAT	NM_020984.3	c.[3G>A];[487C>T]	p.[(Met ?)];[(Arg163Trp)]	Likely pathogenic VUS	Compound heterozygous	Not published to date/not published to date	#254210 (AR)	Neuromuscular junction (congenital myasthenic syndrome 6)	RFM, velamentous insertion, lymphoedema of the feet, scalp oedema	Wrists, rocker-bottom feet	Micrognathia and retrognathia, long philtrum	—	Pulmonary hypoplasia, flexion anomaly of both hands
F3:II.1	3	M/TOP (25 WGA)	GPC3	NM_004484.3	c.[1666G>C]n[0]	p.[(Gly556Arg)];[(0)]	Likely pathogenic	Hemizygous (maternal inherited)	Not published to date	#312870 (X-linked)	Syndromic malformation (Simpson-Golabi-Behme syndrome)	RFM	Wrists, knees, talipes equinovarus (bilateral)	—	—	Ectogenic areas in the myocardium of the ventricular septum and left ventricle
F4:II.1	4	F/9 years	MAGEL2	NM_019066.5	c.[1996dup]n=	p.[(Gln666Profs*47)];[(=)]	Pathogenic	Heterozygous (paternal allele affected), de novo	Published (PMID: 25473036, 27195816)	#615547 (AD, imprinting)	Syndromic malformation (Schaaf-Yang syndrome)	RFM, ND	Elbows, wrists, fingers, talipes equinovarus (bilateral)	Large ears, premature craniosynostosis, camptodactyly, clinodactyly	Intellectual disability, motor and speech developmental delay, muscular hypotonia, hypoprophy of shoulder muscles	Hydrocephalus (bilateral), anal stenosis, laryngomalacia, scoliosis, strabismus
F5:II.1	5	M/TOP (25 WGA)	MYH3	NM_002470.4	c.[2015G>A]n=	p.[(Arg672His)];[(=)]	Pathogenic	Heterozygous, de novo	Published (PMID: 16642020, 28584665, 26996280)	#193700, #178110 (AD)	Myogenic (distal arthropoysis 2A)	RFM	Wrists, knees, ankles	Abnormal facial profile with long philtrum	—	Bent lower leg bones (bilateral)
F6:II.1	6	M/8 months	MALCW	NM_052867.4	c.[3522A>T]n=	p.[(Arg1174Ser)];[(=)]	Likely pathogenic	Heterozygous, de novo	Not published to date, patient listed in DECIPHER (ID 388888)	#616266 (AD)	Syndromic malformation (congenital contractures of the limbs and face, hypotonia and developmental delay)	Polyhydramnios, insulin-dependent diabetes mellitus	Bilateral adducted thumbs and contracted third fingers (improved with age)	Round face, mild hyperlordism, short palpebral fissures, microstomia	Severe global developmental delay, at 3 years no unsupported sitting, crawling, standing or walking, no tachyypnoea, (inspiratory stridor); laryngomalacia as newborn, 2 times laser treatment; now all measurements low, especially short stature, at 3.8/12 years weight -2.3 SD, length -3.9 SD, Occipitofrontal circumference -2.5 SD	Normal birth measurements at birth (34-2), Aggar 9/99 but problems with respiratory adaptation with respiratory sitting, crawling, standing or walking, no tachyypnoea, (inspiratory stridor); laryngomalacia as newborn, 2 times laser treatment; now all measurements low, especially short stature, at 3.8/12 years weight -2.3 SD, length -3.9 SD, Occipitofrontal circumference -2.5 SD

Continued

Table 1 Continued

Patient ID #	Family #	Gender/age at inclusion or death* or termination of pregnancy	Affected gene	Reference sequence ID	DNA change	Predicted AA change	Variant classification (ACMG)	Zygoty	Published (PMID)/not published	OMIM phenotype (mode of inheritance)	Aetiological classification (OMIM diseases)	Prenatal abnormalities	Joint contractures (prenatal or postnatal)	Dysmorphic features	Neurological abnormalities	Other features
F7:II.1	7	M/10P (18 WGA)	MEB	NM_001271208.2	c.[3084C>G];[3726dup]	p.[(Tyr1028*)];[Ser1243Leu5*16]	Pathogenic, pathogenic	Compound heterozygous	Not published to date/not published to date	#256030, #619334 (AR)	Myogenic (arthrogypsis multiplex congenita, nermaline myopathy 2)	RFM, IUGR, cystic hygroma	Suspected multiple joint contractures	–	–	Short and single umbilical artery
F8:II.1	8	M/2.5 months*	MEK9	NM_033116.5	c.[874-2A>G];[1432delC]	p.[(Lys478Serfs*18)]	Likely pathogenic, pathogenic	Compound heterozygous	Not published to date	#614262, #617022 (AR)	Neurogenic (lethal congenital contracture syndrome 10)	RFM, polyhydramnios	Elbows, wrists, fingers, hips, knees, ankles	Retrogenia, macroglossia, camptodactyly	Seizures, muscular hypertonia	Pulmonary hypoplasia, RI, pulmonary stenosis, cardiomegaly, bilateral hydronephrosis unilateral inguinal hernia, anal prolapse
F9:II.1	9	F/2 months	PIE202	NM_022068.4	c.[8057G>A];[=]	p.[(Arg2686His)];[=]	Pathogenic	Heterozygous (inherited from similarly affected mother)	Published (PMID: 24726473, 27714920)	#114300, #108145 (AD), #617146 (AR)	Neurogenic (distal arthrogypsis 3)	RFM	Wrists, hips, knees, talipes equinovarus (bilateral)	Camptodactyly	–	–
F10:II.1	10	F/10P (21 WGA)	SLC6A9	NM_201649.3	c.[352G>A];[352G>A]	p.[(Val118Met)];[Val118Met]	Likely pathogenic	Homozygous	This case (PMID: 32712301)	#617301 (AR)	Neurogenic (glycine encephalopathy)	RFM, polyhydramnios, cystic structures in knees and elbows, increased nuchal translucency	Multiple joint contractures, talipes equinovarus (bilateral)	ND (autopsy not performed)	–	–
F10:II.2	10	M/10P (18 WGA)	SLC6A9	NM_201649.3	c.[352G>A];[352G>A]	p.[(Val118Met)];[Val118Met]	Likely pathogenic	Homozygous	This case (PMID: 32712301)	#617301 (AR)	Neurogenic (glycine encephalopathy)	RFM, polyhydramnios, increased nuchal translucency	Shoulders, elbows, wrists, fingers, hips, knees, talipes equinovarus (bilateral)	Micrognathia and retrognathia, talipes equinovarus (bilateral)	–	–
F11:II.1	11	M/2 months	SRD5A3	NM_024592.4	c.[829T>C];[829T>C]	p.[(Trp277Arg)];[Trp277Arg]	Likely pathogenic	Homozygous	Not published to date	#612379, #612713 (AR)	Neurogenic (congenital disorder of glycosylation type Iq, Kahriizi syndrome)	RFM, IUGR, human tail, hypertrichosis	Elbows, wrists, fingers, hips, knees	Micrognathia and retrognathia, dysplastic low-set ears, thin upper lip, sacral human tail, left palate, camptodactyly	Muscular hypertonia, wide cisterna magna, pathological oculomotor function and otoacoustic emissions	RI, NIV, laryngomalacia, retinal coloboma, myocardial hypertrophy, myocardial infarction, thymic hypoplasia, hyperglycaemia, insulin resistance, ichthyosis, cryptorchidism
F12:II.1	12	F/2 months	TTN	NM_001267550.2	c.[31034_31035del];[39974-111>G]	p.[(Tyr10245*)];[?]	Pathogenic, pathogenic	Compound heterozygous	Not published to date/ published (PMID: 31660661)	#604145 (AD), #617105 (AR)	Myogenic (Salih myopathy)	RFM	Multiple joint contractures	Yes, not specified	Delayed motor development, muscular hypotonia	Not specified
F13:II.1	13	F/7 months	TTN	NM_001267550.2	c.[26764C>T];[39974-111>G]	p.[(Arg892*)];[?]	Likely pathogenic, pathogenic	Compound heterozygous	Not published to date/ published (PMID: 31660661)	#604145 (AD), #617105 (AR)	Myogenic (Salih myopathy)	RFM, IUGR, oligohydramnios	Multiple joint contractures	Yes, not specified	Muscular hypotonia, generalised decreased muscle bulk	RI, NIV (post partum for 2 weeks)
Individuals carrying variants of unknown significance																
F14:II.1	14	F/10P (27 WGA)	SLC6A9	NM_201649.3	c.[167C>G];[245C>G]	p.[(Ser56Cys)];[(Ala82Gly)]	VUS/VUS	Father carries only the C.245C>G variant; mother not available	Not published to date/not published to date	#617301 (AR)	Neurogenic (glycine encephalopathy)	RFM, retrognathia	Elbows, wrists, crossed fingers, hips, knees, talipes equinovarus (bilateral)	Retrognathia	Signs of congenital myasthenic syndrome	–

Continued

Table 1 Continued

Patient ID #	Family #	Gender/age at inclusion or death* or termination of pregnancy (TOP)	Affected gene	Reference sequence ID	DNA change	Predicted AA change	Variant classification (ACMG)	Zygosity	Published (PMID)/not published	OMIM phenotype (mode of inheritance)	Aetiological classification (OMIM diseases)	Prenatal abnormalities	Joint contractures (prenatal or postnatal)	Dysmorphic features	Neurological abnormalities	Other features
F15:II.1	15	F/8 years	<i>BICD2</i>	NM_001003800.2	c.[2105A>G]i[=]	p.[(Gln702Arg)]i[=]	VUS	Parents not tested	Not published to date but listed in ClinVar (likely pathogenic)	#615290 (AD), #618231 (AD)	Neurogenic (spinal muscular atrophy 2)	RFM	Hips, knees, ankles, talipes equinovarus (left), sickle foot (right)	Prominent forehead, finger furrow, crossed 2nd and 3rd toe	Atonic seizures, cognitive impairment, psychomotor developmental delay, global muscular hypotonia, atrophy of leg muscles, reduced muscle reflexes of the lower extremity, positive Babinsky sign (bilateral)	Bilateral hip dislocation, short stature, two café au lait spots

List of genetic variants and clinical details of the cohort sorted by disease-causal genetic defects in known FA-associated genes and cases with variants of unknown significance. Provided information includes patient ID, family ID, gender, age at inclusion or death in months and years or termination of pregnancy in WGA. Age 0 denotes children dying <1 month after birth. Additionally, provided data include the affected gene, RefSeq ID, DNA change, AA change, variant classification (ACMG scores), gene-associated OMIM phenotypes, mode of inheritance and zygosity. Furthermore, it is indicated whether variants have already been published independently (with corresponding PMID) or not. The variant nomenclature is in accordance with Human Genome Variation Society standards.

*Death.

AA, amino acid; ACMG, American College of Medical Genetics and Genomics; AD, autosomal dominant; AR, autosomal recessive; F, female; FA, fetal akinesia; IUGR, intrauterine growth restriction; M, male; ND, no data; NIV, non-invasive ventilation; PMID, PubMed ID; RFM, reduced fetal movements; R1, respiratory insufficiency; VUS, variant of uncertain significance in the ACMG classification system; WGA, weeks of gestational age.

In all fetuses, first abnormalities were recognised by high-resolution fetal ultrasonography between the 19th and 26th week of gestation. In five of five fetuses, reduced fetal movements were documented associated with multiple joint contractures. These included clenched fingers (four of five), fixed extension or flexion of the wrists (three of five), elbows (two of five) and knees (four of five) as well as talipes equinovarus (five of five). Marked thoracic hypoplasia was observed in five of five fetuses and polyhydramnios in four of five fetuses. Facial dysmorphisms were micrognathia (four of five) and/or retrognathia (four of five) combined with inconsistent variable additional features including brachycephaly (one of five), hypertelorism (one of five, autopsy), low-set ears (two of five, autopsy), flat broad nose (one of five, autopsy), scalp oedema (four of five), and prenasal and/or neck oedema (two of five). Skeletal deformations were documented in ultrasonography or autopsy in two of five fetuses with thoracic kyphoscoliosis, straight ribs and slender tubular bones. Other ultrasonographic or autopsy findings included gastrointestinal abnormalities (three of five) such as diaphragmatic hernia with protrusions (two of five) as well as cerebral ventriculomegaly (one of five), dextrocardia (one of five), clinodactyly (one of five) and urogenital abnormalities with bilateral tortuous ureters (one of five). All pregnancies were terminated between the 21st and 29th week of gestation. The ultrasonographic findings were mostly congruent with documentations of autopsies conducted on fetuses F22:II.1, F22:II.2 and F23:II.1. The lung weight to body weight ratio was determined in individuals F22:II.1 (0.009; 23+1 weeks of gestation; normal >0.015) and F23:II.1 (0.009; 28+5 weeks of gestation; normal >0.012) and suggested severe lung hypoplasia.

Together, these molecular and phenotypical data are in line with bi-allelic *KIF21A* PTVs being implicated in the pathogenesis of a severe form of autosomal recessive FA characterised by arthrogryposis multiplex, pulmonary hypoplasia and variable facial dysmorphisms.

DISCUSSION

The aim of this study was to further define the molecular bases underlying FA using exome sequencing. Our results confirm the diagnostic yield and broad genetic heterogeneity in FA reported in previous studies including myogenic, neuromuscular junction, neurogenic as well as syndromic malformation aetiologies.⁶ Individuals with less severe prenatal findings surviving the first months and years of life were largely diagnosed with myopathies or syndromic malformations. On the molecular level, our findings underline the importance of variant-specific or transcript-specific mechanisms and genotype–phenotype correlations.^{6,9} Illustrative examples include the identification of variants in *GPC3* (OMIM *300037) and *TTN* (OMIM *188840), two genes mostly known for their association with Simpson-Golabi-Behmel syndrome (OMIM #312870) and (cardio-)myopathies (OMIM #604145, #613765, #608807, #603689, #611705), respectively. The *GPC3* variant c.1666G>C, (p.Gly556Arg) observed in patient F3:II:1 alters the same residue affected by different variants [c.1667G>T, (p.Gly556Val) and c.1666G>A, (p.Gly556Arg)] detected in patients with Simpson-Golabi-Behmel syndrome. Of note, the latter one predicts the same alteration on amino acid level.^{12–15} This residue is located in a region critical for *GPC3* cleavage during the process of plasma membrane anchoring. Functional studies demonstrated for the change c.1666G>A, (p.Gly556Arg), that the protein was not glycanated and stayed in the cytoplasm instead of being attached to the cell surface.¹²

Table 2 Identified *KIF21A* (NM_001173464.2) variants and associated clinical features

Patient ID #	Family #	Gender/age at TOP	Affected gene	DNA change	Predicted AA change	Variant classification (ACMG)	Zygoty	OMIM phenotype (mode of inheritance)	Aetiological classification (OMIM diseases)	Prenatal abnormalities	Joint contractures	Dysmorphic features	Neurological abnormalities	Other features
F22-II.1	22	M/TOP (24 WGA)	<i>KIF21A</i>	c.(1346T>A);(1346T>A)	p.(Leu449*)	Candidate gene, likely pathogenic	Homozygous	#135700 (AD), novel for AR pending	Likely neurogenic (disease name to be determined)	RFM, polyhydramnios, scalp oedema, pulmonary hypoplasia, missing stomach filling, diaphragmatic protrusion, thoracic kyphoscoliosis	Elbows, wrists, fingers, knees, ankles, talipes equinovarus (bilateral)	Hypertelorism, retrognathia, cleft palate, flat broad nose, low-set ears	Hypotrophy of lower leg muscles	Internally rotated shoulders, straight ribs, narrow long tubular bones
F22-II.2	22	F/TOP (26 WGA)	<i>KIF21A</i>	c.(1346T>A);(1346T>A)	p.(Leu449*)	Candidate gene, likely pathogenic	Homozygous	#135700 (AD), novel for AR pending	Likely neurogenic (disease name to be determined)	RFM, polyhydramnios, IUGR, scalp oedema, thoracic hypoplasia, hydrothorax, ascites, missing stomach filling, diaphragmatic protrusion	Elbows, fingers, knees, talipes equinovarus (bilateral)	Microglossia, micrognathia and retrognathia, cleft palate, high-arched palate, low-set ears	–	Jejunal perforation, dilated tortuous ureter (bilateral), internally rotated shoulders, thoracic scoliosis, additional cervical rib, straight ribs, narrow long tubular bones, femoral anteversion (bilateral), genu recurvatum (bilateral)
F22-II.4	22	M/TOP (21 WGA)	<i>KIF21A</i>	c.(1346T>A);(1346T>A)	p.(Leu449*)	Candidate gene, likely pathogenic	Homozygous	#135700 (AD), novel for AR pending	Likely neurogenic (disease name to be determined)	RFM, micrognathia, prenasal oedema, neck oedema, pulmonary hypoplasia	Knees, talipes equinovarus (bilateral)	ND (autopsy not performed)	–	–
F23-II.1	23	M/TOP (29 WGA)	<i>KIF21A</i>	c.(2371del);(2371del)	p.(Arg791Glufs*8)	Candidate gene, likely pathogenic	Homozygous	#135700 (AD), novel for AR pending	Likely neurogenic (disease name to be determined)	RFM, polyhydramnios, brachycephaly, scalp oedema, prenasal oedema, neck oedema, pulmonary hypoplasia, dextrocardia, gastrointestinal abnormalities	Fingers, wrists, talipes equinovarus (bilateral), rocker-bottom feet	Skull deformation with protruding skull bones, micrognathia and retrognathia, clinodactyly of 2nd digit (bilateral)	Cerebral ventriculomegaly	Severe pulmonary hypoplasia, dextrocardia, clenched hands with crossing fingers (bilateral)
F23-II.2	23	F/TOP (28 WGA)	<i>KIF21A</i>	c.(2371del);(2371del)	p.(Arg791Glufs*8)	Candidate gene, likely pathogenic	Homozygous	#135700 (AD), novel for AR pending	Likely neurogenic (disease name to be determined)	RFM, polyhydramnios, scalp oedema, prenasal oedema, pulmonary hypoplasia	Fingers, wrists, talipes equinovarus (bilateral)	Micrognathia and retrognathia (autopsy not performed)	–	–

List of genetic variants and clinical details of individuals carrying bi-allelic variants in the candidate gene *KIF21A*. Provided information includes patient ID, family ID, gender, age at termination of pregnancy in WGA. Additionally, provided data include the affected gene, RefSeq ID, DNA change, AA change, variant classification (ACMG scores), gene-associated OMIM phenotype, mode of inheritance and zygosity. The variant nomenclature is in accordance with Human Genome Variation Society standards. AA, amino acid; ACMG, American College of Medical Genetics and Genomics; AD, autosomal dominant; AR, autosomal recessive; F, female; IUGR, intrauterine growth restriction; M, male; ND, no data; RFM, reduced fetal movements; TDP, termination of pregnancy; WGA, weeks of gestational age.

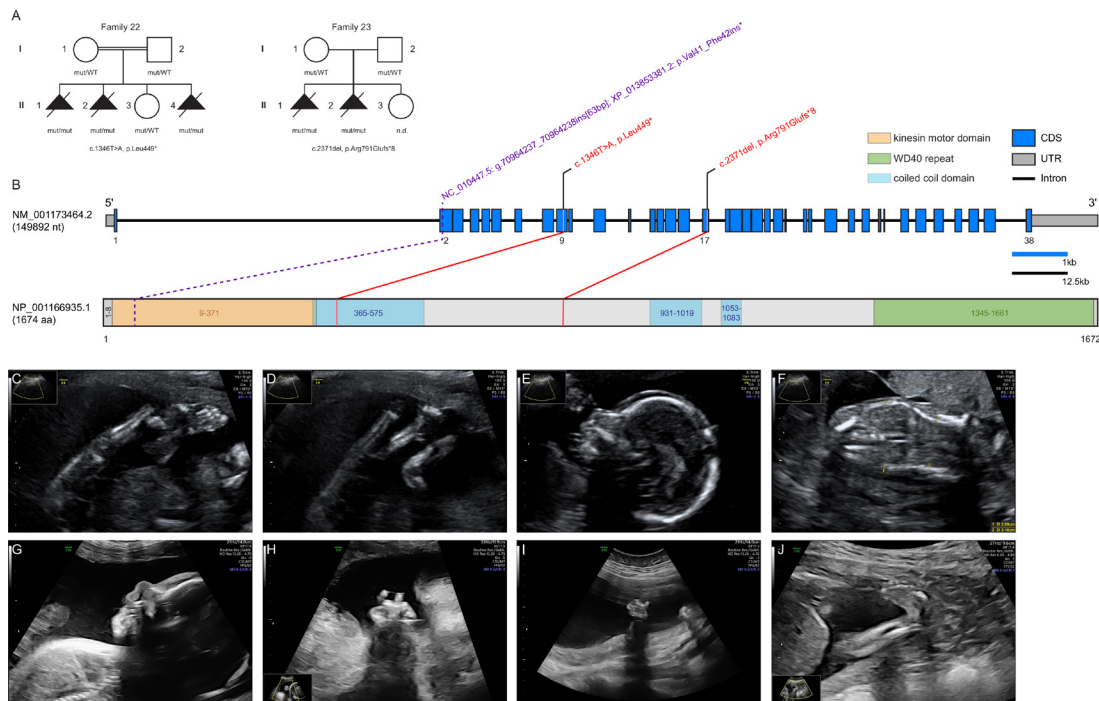


Figure 1 Pedigrees of investigated *KIF21A* families, structure of *KIF21A* and prenatal ultrasound scans. (A) Pedigrees of two families with pathogenic variants in *KIF21A*, illustrating the variant carrier status of affected (closed symbols) and healthy (open symbols) family members. Identified variants are provided below the pedigrees. (B) Gene structure of *KIF21A* with known protein domains and motifs of the gene product and localisation of the identified variants (red). The change reported in the *Kif21a* orthologue in *Sus scrofa* is shown in purple. Intronic regions are not drawn to scale (black scale bar indicates 12.5 kb of intronic regions, blue scale bar indicates 1 kb of exonic regions). (C–F) Representative ultrasound scans of individual F22:II.4 at 19+0 weeks of gestation: (C) lower extremity with persistently extended and crossed legs with clubfoot; (D) both knee joints fixed in extension; (E) micrognathia and slight prenasal oedema; (F) coronal ultrasound through the thorax and abdomen shows thoracic hypoplasia. (G,H) Ultrasound scans of individual F23:II.1 at 25+5 weeks of gestation: (G) facial profile with micrognathia and prenasal oedema; (H) right hand with crossed fingers. (I,J) Ultrasound scans of individual F23:II.2 at 21+0 weeks of gestation: (I) left clenched hand; (J) lower extremity with clubfoot. CDS, coding sequence; mut, mutated allele; n.d., not determined; UTR, untranslated region; WT, wildtype allele.

In two unrelated individuals, the recurrent nearsplice variant c.39974–11T>G, (p.?) affecting the metatranscript of *TTN* (NM_001267550.2) was observed in compound heterozygosity with two different loss-of-function alleles. This change has been recently reported in 10 individuals from 8 families diagnosed with AMC and is postulated to alter the expression of a *TTN* isoform predominantly expressed during fetal skeletal muscle development.^{16 17} This observation exemplifies the possibility that transcript-specific alterations may cause distinct clinical presentations via interference with early prenatal and postnatal processes.

Noteworthy, our study provides further evidence of two loci being associated with FA, namely *NEK9* and *KIF21A*. *NEK9* encodes a serine-threonine protein kinase that interacts with the chromatin structure modulating FACT (Facilitates Chromatin Transcription) complex and is essential for interphase progression.¹⁸ In addition, *NEK9* plays a role in regulating chromosome alignment and segregation during mitosis.¹⁹ Casey *et al* first associated a homozygous nonsense variant in *NEK9* c.1489C>T, (p.Arg497*) with lethal skeletal dysplasia in two Irish traveller families. Their results suggested nonsense-mediated decay of mutant *NEK9* mRNA to result in delayed cell cycle progression and reduced proliferation. Furthermore, patient-derived fibroblasts exhibited a defect in ciliary function.²⁰ However, to our knowledge, only one additional individual with FADS harbouring another homozygous PTV variant [c.1498del, p.(Glu500Lysfs*33)] has been published thereafter.²¹ Our report on compound heterozygous predicted loss-of-function variants

in an additional similarly affected unrelated proband provides important additional evidence of bi-allelic *NEK9* variants to be associated with FA.

Apart from methodological advantages to detect certain types of genetic variation, a key advantage of exome and full genome sequencing over panel-based approaches targeting a predefined set of genes is the perspective to establish new disease genes. A combined filtering strategy tailored to prioritise new factors associated with FA led us to identify bi-allelic PTVs in the *kinesin family member 21A* gene (*KIF21A*), a member of the kinesin-4 family, in several affected fetuses from two families. Kinesins (KIFs) are molecular motor proteins that constitute 15 kinesin families with 44 members in the human genome. They directionally transport multiple cargos such as organelles, protein complexes, vesicles, mRNA or virus particles along microtubule tracks, using ATP to drive conformational changes that generate motile force.²² Owing to their molecular function, they play an essential role in various cellular processes, including cell-cycle dynamics and progression, ciliogenesis and cilia function as well as organisation of polar cells during organogenesis.²³ Pathogenic variants in several kinesin superfamily proteins (KIF5C, KIF14, KIF26B) have been associated with different disease entities, including FA.^{24–26}

KIF21A is highly conserved in bilateria with, for example, 96.23% identity of the amino acid sequence in *Sus scrofa* (online supplemental data) and 54.07% in *Caenorhabditis elegans*. It is highly enriched in axons, dendrites and muscle, and inhibits microtubule growth at the cell cortex.^{27–29} Gain-of-function

variants in *KIF21A* have been associated with autosomal-dominant congenital fibrosis of extraocular muscles (CFEOM1, OMIM #135700). The protein consists of an amino terminal motor domain, central stalk domain and carboxy terminal domain containing WD40 repeats.³⁰ In its inactive state, the third coiled-coil stalk domain binds the motor domain, inhibiting its interaction with microtubules. When *KIF21A* is activated, this motor domain is released and can bind to microtubules.³⁰ Of note, all variants associated with CFEOM1 so far are clustering in the third coiled-coil stalk and motor domain, suggesting that these changes disrupt interaction of the two domains, leaving *KIF21A* in a constitutively active state.³⁰

To our knowledge, recessive-type variants compatible with a loss of *KIF21A* function have so far not been associated with clinical phenotypes in human. However, Fang *et al* identified a 63 bp insertion in exon 2 of the porcine *Kif21a* gene predicted to result in a truncated protein lacking the complete motor domain.^{31–32} Piglets with a homozygous insertion were either stillborn or died shortly after birth with congenital malformations resembling arthrogryposis multiplex congenita. Of note, eye movements of heterozygous pigs have not been investigated in this study.³¹

The extreme genetic heterogeneity underlying FA translates into a broad spectrum of biological functions of affected proteins and disease mechanisms. These include ion channels or pumps, receptors or modulators, inborn errors of metabolism, factors involved in transcription and translation, cell cycle, cell signalling/secretion as well as motor proteins or protein trafficking.⁶ From an organelle perspective, a postulated mechanism underlying FA is impaired ciliogenesis,³³ which is interesting, as KIFs are known to fulfil an essential role in ciliogenesis and cilia function.²³ In addition, primary cilia-driven signalling regulates growth cone dynamics and axonal tract development,³⁴ and several genes linked to arthrogryposis, such as *AUTS2*, *CBL*, *DNM2*, *IGHMBP2*, *KIF5C*, *SETX*, *SNAP25* and *TOR1A* function in growth cone regulation.³⁵ It has been demonstrated that relief of *KIF21A* autoinhibition causes accumulation of the protein in axonal growth cones and results in aberrant axon morphology,²⁹ which is consistent with a role of *KIF21A* in axonal growth cone regulation. As post-translational modification of tubulin is essential for regulation of primary cilia length and *KIF21A* inhibits microtubule growth at the cell cortex, disturbance of this pathway may be a cellular consequence of *KIF21A* deficiency and functional link to the phenotype of FA.

In summary, our clinical and genetic data from two FA families together with previous observations in *S. scrofa* provide firm evidence that while heterozygous gain-of-function variants in *KIF21A* cause CFEOM1, bi-allelic PTVs are associated with a severe form of FA in human. The observation of two independent events in a cohort of 23 index cases is compatible with pathogenic *KIF21A* variants representing a more common cause of FA. However, the rather small cohort size is a limitation of this study and genetic (re-)evaluation of larger FA cohorts is needed to estimate the contribution of this new disease locus to this collectively common disease entity and its relevance in the context of prenatal testing and the evolving diagnostic option of preconception carrier screening.

Author affiliations

¹Institute of Medical Genetics and Applied Genomics, University of Tuebingen, Tuebingen, Germany

²genetikum Stuttgart, Stuttgart, Germany

³Practice of Human Genetics, Bremen, Germany

⁴Institute of Human Genetics, University Hospital Essen, Essen, Germany

⁵Institute of Human Genetics, Heidelberg University, Heidelberg, Germany

⁶genetikum Neu-Ulm, Neu-Ulm, Germany

⁷Department of General Pediatrics, Neonatology and Pediatric Cardiology, Heinrich-Heine-University Dusseldorf, Dusseldorf, Germany

⁸Department of Women's Health, University Women's Hospital, Tuebingen, Germany

⁹Institute of Medical and Human Genetics, Charité - Universitätsmedizin Berlin, Berlin, Germany

¹⁰Practice for Ultrasound and Prenatal Medicine, Freiburg, Germany

¹¹Institute of Human Genetics, University Medical Center Freiburg, Freiburg, Germany

¹²Practice for Prenatal Medicine, Bremen, Germany

¹³Institute of Pathology, Center for Integrated Oncology, University of Bonn, Bonn, Germany

¹⁴Department of Obstetrics and Prenatal Medicine, University Hospital Bonn, Bonn, Germany

¹⁵Institute of Pathology and Neuropathology, University of Tuebingen, Tuebingen, Germany

¹⁶Institute of Human Genetics, Ulm University and Ulm University Medical Center, Ulm, Germany

¹⁷Practice for Human Genetics, Heidelberg, Germany

¹⁸Prenatal Medicine Stuttgart, Stuttgart, Germany

¹⁹Centre for Rare Diseases, University of Tuebingen, Tuebingen, Germany

Acknowledgements We thank the patients and their families contributing to this study. Furthermore, we thank Beate Kootz, Karin Hamann and Claudia Bauer for excellent technical support.

Contributors Conceptualisation—RF, AM and TBH. Data curation—RF, AM, MG and MS. Investigation—RF, AM, WK, MG, SS, PS, DG, AK, ND, EMCS, LA, UGR, RB, TH, NP, JP, MK, SH, DH, DE, NH, AN, GK, UGe, SHa, RS, SHe, MH, SO, SW, SB-W, DG, IT, OR, FD, KK, AD and TBH. Methodology—CS and OK. Software—MS and SO. Supervision—TBH. Visualisation—RF and MG. Writing (original draft)—RF, AM and TBH. Writing (review and editing)—RF, AM, MG and TBH. TBH is responsible for the overall content as guarantor.

Funding TBH was supported by the Deutsche Forschungsgemeinschaft (DFG, German Research Foundation: 418081722, 433158657).

Competing interests None declared.

Patient consent for publication Parental/guardian consent obtained.

Ethics approval The research project was approved by the Ethics Committee of the Medical Faculty of the University of Tübingen (number 066/2021B02). All families provided consent according to the respective research protocols including patient photographs, approved by each of the institutional review boards (IRBs).

Provenance and peer review Not commissioned; externally peer reviewed.

Data availability statement Data are available upon reasonable request. All variants have been deposited into ClinVar (<https://www.ncbi.nlm.nih.gov/clinvar/>) under Institute of Medical Genetics and Applied Genomics, University of Tübingen, including VCV... through VCV....

Supplemental material This content has been supplied by the author(s). It has not been vetted by BMJ Publishing Group Limited (BMJ) and may not have been peer-reviewed. Any opinions or recommendations discussed are solely those of the author(s) and are not endorsed by BMJ. BMJ disclaims all liability and responsibility arising from any reliance placed on the content. Where the content includes any translated material, BMJ does not warrant the accuracy and reliability of the translations (including but not limited to local regulations, clinical guidelines, terminology, drug names and drug dosages), and is not responsible for any error and/or omissions arising from translation and adaptation or otherwise.

Open access This is an open access article distributed in accordance with the Creative Commons Attribution Non Commercial (CC BY-NC 4.0) license, which permits others to distribute, remix, adapt, build upon this work non-commercially, and license their derivative works on different terms, provided the original work is properly cited, appropriate credit is given, any changes made indicated, and the use is non-commercial. See: <http://creativecommons.org/licenses/by-nc/4.0/>.

ORCID iDs

Joohyun Park <http://orcid.org/0000-0001-7996-5283>

Felix Distelmaier <http://orcid.org/0000-0003-4304-7848>

Tobias B Haack <http://orcid.org/0000-0001-6033-4836>

REFERENCES

- Hall JG. Pena-Shokeir phenotype (fetal akinesia deformation sequence) revisited. *Birth Defects Res A Clin Mol Teratol* 2009;85:677–94.
- Beecroft SJ, Lombard M, Mowat D, McLean C, Cairns A, Davis M, Laing NG, Ravenscroft G. Genetics of neuromuscular fetal akinesia in the genomics era. *J Med Genet* 2018;55:505–14.
- Ravenscroft G, Sollis E, Charles AK, North KN, Baynam G, Laing NG. Fetal akinesia: review of the genetics of the neuromuscular causes. *J Med Genet* 2011;48:793–801.

- 4 Hall JG. Arthrogryposis (multiple congenital contractures): diagnostic approach to etiology, classification, genetics, and general principles. *Eur J Med Genet* 2014;57:464–72.
- 5 Filges I, Hall JG. Failure to identify antenatal multiple congenital contractures and fetal akinesia—proposal of guidelines to improve diagnosis. *Prenat Diagn* 2013;33:61–74.
- 6 Pergande M, Motameny S, Özdemir Özkan, Kreutzer M, Wang H, Daimagüler H-S, Becker K, Karakaya M, Ehrhardt H, Elcioglu N, Stojsic S, Chao C-M, Kawalia A, Duman Özgür, Koy A, Hahn A, Reimann J, Schoner K, Schänzer A, Westhoff JH, Schwaibold EMC, Cossee M, Imbert-Bouteille M, von Pein H, Haliloglu G, Topaloglu H, Altmüller J, Nürnberg P, Thiele H, Heller R, Cirak S. The genomic and clinical landscape of fetal akinesia. *Genet Med* 2020;22:511–23.
- 7 Lowry RB, Sibbald B, Bedard T, Hall JG. Prevalence of multiple congenital contractures including arthrogryposis multiplex congenita in Alberta, Canada, and a strategy for classification and coding. *Birth Defects Res A Clin Mol Teratol* 2010;88:1057–61.
- 8 Navti OB, Kinning E, Vasudevan P, Barrow M, Porter H, Howarth E, Konje J, Khare M. Review of perinatal management of arthrogryposis at a large UK teaching hospital serving a multiethnic population. *Prenat Diagn* 2010;30:49–56.
- 9 Ravenscroft G, Clayton JS, Faiz F, Sivadorai P, Milnes D, Cincotta R, Moon P, Kamien B, Edwards M, Delatycki M, Lamont PJ, Chan SH, Colley A, Ma A, Collins F, Hennington L, Zhao T, McGillivray G, Ghedia S, Chao K, O'Donnell-Luria A, Laing NG, Davis MR. Neurogenetic fetal akinesia and arthrogryposis: genetics, expanding genotype-phenotypes and functional genomics. *J Med Genet* 2021;58:609–18.
- 10 Pehlivan D, Bayram Y, Gunes N, Coban Akdemir Z, Shukla A, Bierhals T, Tabacki B, Sahin Y, Gezdirici A, Fatih JM, Gulec EY, Yesil G, Punetha J, Ocak Z, Grochowski CM, Karaca E, Albayrak HM, Radhakrishnan P, Erdem HB, Sahin I, Yildirim T, Bayhan IA, Bursalci A, Elmas M, Yuksel Z, Ozdemir O, Silan F, Yildiz O, Yesilbas O, Isikay S, Balta B, Gu S, Jhangiani SN, Doddapaneni H, Hu J, Muzny DM, Boerwinkle E, Gibbs RA, Tsiakas K, Hempel M, Girisha KM, Gul D, Posey JE, Elcioglu NH, Tuysuz B, Lupski JR, Baylor-Hopkins Center for Mendelian Genomics. The genomics of arthrogryposis, a complex trait: candidate genes and further evidence for oligogenic inheritance. *Am J Hum Genet* 2019;105:132–50.
- 11 Richards S, Aziz N, Bale S, Bick D, Das S, Gastier-Foster J, Grody WW, Hegde M, Lyon E, Spector E, Voelkerding K, Rehms HL, ACMG Laboratory Quality Assurance Committee. Standards and guidelines for the interpretation of sequence variants: a joint consensus recommendation of the American College of medical genetics and genomics and the association for molecular pathology. *Genet Med* 2015;17:405–23.
- 12 Shi W, Filmus J. A patient with the Simpson-Golabi-Behmel syndrome displays a loss-of-function point mutation in GPC3 that inhibits the attachment of this proteoglycan to the cell surface. *Am J Med Genet A* 2009;149A:552–4.
- 13 Pénisson-Besnier I, Lebouvier T, Moizard M-P, Ferré M, Barth M, Marc G, Raynaud M, Bonneau D. Carotid artery dissection in an adult with the Simpson-Golabi-Behmel syndrome. *Am J Med Genet A* 2008;146A:464–7.
- 14 Vuillaume M-L, Moizard M-P, Rossignol S, Cottureau E, Vonwill S, Alessandri J-L, Busa T, Colin E, Gérard M, Giuliano F, Lambert L, Lefevre M, Kotecha U, Nampoothiri S, Netchine I, Raynaud M, Brioude F, Toutain A. Mutation update for the GPC3 gene involved in Simpson-Golabi-Behmel syndrome and review of the literature. *Hum Mutat* 2018;39:2110–2.
- 15 Cottureau E, Mortemousque I, Moizard M-P, Bürglen L, Lacombe D, Gilbert-Dussardier B, Sigaudy S, Boute O, David A, Faivre L, Amiel J, Robertson R, Viana Ramos F, Bieth E, Odent S, Demeer B, Mathieu M, Gaillard D, Van Maldergem L, Baujat G, Maystadt I, Héron D, Verloes A, Philip N, Cormier-Daire V, Frouit M-F, Pinson L, Blanchet P, Sarda P, Willems M, Jacquinet A, Ratbi I, Van Den Ende J, Lackmy-Port Lis M, Goldenberg A, Bonneau D, Rossignol S, Toutain A. Phenotypic spectrum of Simpson-Golabi-Behmel syndrome in a series of 42 cases with a mutation in GPC3 and review of the literature. *Am J Med Genet C Semin Med Genet* 2013;163C:92–105.
- 16 Bryn SJ, Ewans LJ, Pinner J, MacLennan SC, Donkervoort S, Castro D, Töpf A, O'Grady G, Cummings B, Chao KR, Weisburd B, Francioli L, Faiz F, Bournazos AM, Hu Y, Grosman C, Malicki DM, Doyle H, Witting N, Vissing J, Claeys KG, Urankar K, Belezza-Meireles A, Baptista J, Ellard S, Savarese M, Johari M, Vihola A, Udd B, Majumdar A, Straub V, Bönnemann CG, MacArthur DG, Davis MR, Cooper ST. Recurrent TTN metatranscript-only c.39974-11T>G splice variant associated with autosomal recessive arthrogryposis multiplex congenita and myopathy. *Hum Mutat* 2020;41:403–11.
- 17 Savarese M, Vihola A, Oates EC, Barresi R, Fiorillo C, Tasca G, Jokela M, Sarkozy A, Luo S, Diaz-Manera J, Ehrstedt C, Rojas-García R, Sáenz A, Muelas N, Lonardo F, Fodstad H, Qureshi T, Johari M, Välipakka S, Luque H, Petiot P, de Munain AL, Pane M, Mercuri E, Torella A, Nigro V, Astrea G, Santorelli FM, Bruno C, Kuntzer T, Illa I, Vilchez JJ, Julien C, Ferreira A, Malandrini A, Zhao C-B, Casar-Borota O, Davis M, Muntoni F, Hackman P, Udd B. Genotype-phenotype correlations in recessive titinopathies. *Genet Med* 2020;22:2029–40.
- 18 Tan BC-M, Lee S-C. Nek9, a novel FACT-associated protein, modulates interphase progression. *J Biol Chem* 2004;279:9321–30.
- 19 Roig J, Mikhailov A, Belham C, Avruch J. Nerc1, a mammalian NIMA-family kinase, binds the Ran GTPase and regulates mitotic progression. *Genes Dev* 2002;16:1640–58.
- 20 Casey JP, Brennan K, Scheidel N, McGettigan P, Lavin PT, Carter S, Ennis S, Dorkins H, Ghali N, Blacque OE, Mc Gee MM, Murphy H, Lynch SA. Recessive NEK9 mutation causes a lethal skeletal dysplasia with evidence of cell cycle and ciliary defects. *Hum Mol Genet* 2016;25:1824–35.
- 21 Stals KL, Wakeling M, Baptista J, Caswell R, Parrish A, Rankin J, Tysoc C, Jones G, Gunning AC, Lango Allen H, Bradley L, Brady AF, Carley H, Carmichael J, Castle B, Cilliers D, Cox H, Deshpande C, Dixit A, Eason J, Elmslie F, Fry AE, Fryer A, Holder M, Homfray T, Kivuva E, McKay V, Newbury-Ecob R, Parker M, Savarirayan R, Searle C, Shannon N, Shears D, Smithson S, Thomas E, Turnpenny PD, Varghese V, Vasudevan P, Wakeling E, Baple EL, Ellard S. Diagnosis of lethal or prenatal-onset autosomal recessive disorders by parental exome sequencing. *Prenat Diagn* 2018;38:33–43.
- 22 Hirokawa N, Noda Y, Tanaka Y, Niwa S. Kinesin superfamily motor proteins and intracellular transport. *Nat Rev Mol Cell Biol* 2009;10:682–96.
- 23 Kalantari S, Filges I. 'Kinesinopathies': emerging role of the kinesin family member genes in birth defects. *J Med Genet* 2020;57:797–807.
- 24 Poirier K, Lebrun N, Broix L, Tian G, Saillour Y, Boscheron C, Parrini E, Valence S, Pierre BS, Oger M, Lacombe D, Geneviève D, Fontana E, Darra F, Cancès C, Barth M, Bonneau D, Bernadina BD, N'guyen S, Gitiaux C, Parent P, des Portes V, Pedespan JM, Legrez V, Castelnau-Ptakine L, Nitschke P, Hieu T, Masson C, Zelenika D, Andrieux A, Francis F, Guerrini R, Cowan NJ, Bahi-Buisson N, Chelly J. Mutations in TUBG1, DYNC1H1, KIF5C and KIF2A cause malformations of cortical development and microcephaly. *Nat Genet* 2013;45:639–47.
- 25 Alsabban AH, Morikawa M, Tanaka Y, Takei Y, Hirokawa N. Kinesin KIF3B mutation reduces NMDAR subunit NR2A trafficking and causes schizophrenia-like phenotypes in mice. *Embo J* 2020;39:e101090.
- 26 Wojcik MH, Okada K, Prabhu SP, Nowakowski DW, Ramsey K, Balak C, Rangasamy S, Brownstein CA, Schmitz-Abe K, Cohen JS, Fatemi A, Shi J, Grant EP, Narayanan V, Ho H-YH, Agrawal PB. De novo variant in KIF26B is associated with pontocerebellar hypoplasia with infantile spinal muscular atrophy. *Am J Med Genet A* 2018;176:2623–9.
- 27 Marszałek JR, Weiner JA, Farlow SJ, Chun J, Goldstein LS. Novel dendritic kinesin sorting identified by different process targeting of two related kinesins: KIF21A and KIF21B. *J Cell Biol* 1999;145:469–79.
- 28 Desai J, Velo MPR, Yamada K, Overman LM, Engle EC. Spatiotemporal expression pattern of KIF21A during normal embryonic development and in congenital fibrosis of the extraocular muscles type 1 (CFEOM1). *Gene Expr Patterns* 2012;12:180–8.
- 29 van der Vaart B, van Riel WE, Doodhi H, Kevenaar JT, Katrukha EA, Gummy L, Bouchet BP, Grigoriev I, Spangler SA, Yu KL, Wulff PS, Wu J, Lansbergen G, van Battum EY, Pasterkamp RJ, Mimori-Kiyosue Y, Demmers J, Olieric N, Maly IV, Hoogenraad CC, Akhmanova A. CFEOM1-associated kinesin KIF21A is a cortical microtubule growth inhibitor. *Dev Cell* 2013;27:145–60.
- 30 Cheng L, Desai J, Miranda CJ, Duncan JS, Qiu W, Nugent AA, Kolpak AL, Wu CC, Drokhlyansky E, Delisle MM, Chan W-M, Wei Y, Propst F, Reck-Peterson SL, Fritzsche B, Engle EC. Human CFEOM1 mutations attenuate KIF21A autoinhibition and cause oculomotor axon stalling. *Neuron* 2014;82:334–49.
- 31 Fang Z-H, Nosková A, Crysanto D, Neuenschwander S, Vögeli P, Pausch H. A 63-bp insertion in exon 2 of the porcine KIF21A gene is associated with arthrogryposis multiplex congenita. *Anim Genet* 2020;51:820–3.
- 32 Yamada K, Andrews C, Chan W-M, McKeown CA, Magli A, de Berardinis T, Loewenstein A, Lazar M, O'Keefe M, Letson R, London A, Ruttum M, Matsumoto N, Saito N, Morris L, Del Monte M, Johnson RH, Uyama E, Houtman WA, de Vries B, Carlow TJ, Hart BL, Krawiecki N, Shoffner J, Vogel MC, Katowitz J, Goldstein SM, Levin AV, Sener EC, Ozturk BT, Akarsu AN, Brodsky MC, Hanisch F, Cruse RP, Zubcov AA, Robb RM, Roggenkämper P, Gottlob I, Kowal L, Battu R, Traboulsi EI, Franceschini P, Newlin A, Demer JL, Engle EC. Heterozygous mutations of the kinesin KIF21A in congenital fibrosis of the extraocular muscles type 1 (CFEOM1). *Nat Genet* 2003;35:318–21.
- 33 Jühlen R, Martinelli V, Vinci C, Breckpot J, Fahrenkrog B. Centrosome and ciliary abnormalities in fetal akinesia deformation sequence human fibroblasts. *Sci Rep* 2020;10:19301.
- 34 Guo J, Otis JM, Suci SK, Catalano C, Xing L, Constable S, Wachten D, Gupton S, Lee J, Lee A, Blackley KH, Ptacek T, Simon JM, Schurmans S, Stuber GD, Caspari T, Anton ES. Primary cilia signaling promotes axonal tract development and is disrupted in Joubert syndrome-related disorders models. *Dev Cell* 2019;51:759–74.
- 35 Kiefer J, Hall JG. Gene ontology analysis of arthrogryposis (multiple congenital contractures). *Am J Med Genet C Semin Med Genet* 2019;181:310–26.