

# A comparison of the outcomes following intra-articular steroid injection alone or arthrocentesis alone in the management of internal derangement of the temporomandibular joint

## ABSTRACT

**Context:** One of the main causes of chronic facial pain is temporomandibular disorders (TMDs) which may turn out to be a major cause for disability. The two types of treatment strategies may be undertaken to counter temporomandibular joint (TMJ) disorders, namely conservative management and surgical intervention. Surgical management can be classified into invasive open methods and minimally invasive procedures such as arthrocentesis, intra-articular steroid injection, and arthroscopy.

**Aims:** The aim of this study is to compare the efficacy of Kenacort (Triamcinolone) as an intra-articular corticosteroid injection and arthrocentesis for lysis and lavage, for the treatment of the temporomandibular joint disorders.

**Subjects and Methods:** Twenty patients with internal derangement of temporomandibular joint (IDTMJ) not responding to conservative management and meeting the inclusion criteria randomly underwent either intra-articular steroid injection or arthrocentesis and the results of the two procedures were evaluated and compared.

**Statistical Analysis Used:** Unpaired *t*-test, repeated-measures ANOVA. A value of  $P < 0.05$  is considered to be statistically significant.

**Results and Conclusion:** Both procedures turned out to be successful in reducing pain and improving mouth opening, both in a short-term and a long-term use. Upon comparison in our series of patients, arthrocentesis was noted to be a better treatment modality in the long term for the management of IDTMJ.

**Keywords:** Arthrocentesis, comparative, intra-articular steroid, internal derangement, temporomandibular joint

## INTRODUCTION

The temporomandibular joint (TMJ) is a synovial, diarthroidal joint that has the ability to move the mandible against the base of the skull. Temporomandibular disorders are a major cause for orofacial pain leading to disabilities.<sup>[1]</sup> The symptoms characteristics of TMJ disorders are changes in lower jaw mobility (hypermobility or hypomobility), pain, and sound phenomena (grinding/clicking). Internal derangement of TMJ (IDTMJ) is a disorder characterized by intra-articular disc displacement which may occur with reduction or without reduction.<sup>[2,3]</sup> The frequent causes include trauma or chronic parafunction besides occlusal trauma, sleep disorders, and deleterious psychological

**SURYA UDAI SINGH, RAJENDRA B. PRASAD, ROHIT PUNGA<sup>1</sup>, RAHUL DATTA<sup>2</sup>, NEERAJ SINGH<sup>3</sup>**

Department of Oral and Maxillofacial Surgery, AB Shetty Memorial Institute of Dental Sciences, Nitte University, Mangalore, Karnataka, <sup>1</sup>Department of Oral and Maxillofacial Surgery, Sharda University, Noida, Uttar Pradesh, <sup>2</sup>Private Practice, Consultant Oral and Maxillofacial Surgeon, Cheema Hospital, Chandigarh, <sup>3</sup>Private Practice, Consultant Oral and Maxillofacial Surgeon, Delhi, India

**Address for correspondence:** Dr. Surya Udai Singh, H NO, 1456 Sector 42 B, Chandigarh, India.  
E-mail: dr.suryaudaisingh@gmail.com


**Received:** 04 January 2021, **Revised:** 28 June 2021, **Accepted:** 31 July 2021, **Published:** 20 August 2022

This is an open access journal, and articles are distributed under the terms of the Creative Commons Attribution-NonCommercial-ShareAlike 4.0 License, which allows others to remix, tweak, and build upon the work non-commercially, as long as appropriate credit is given and the new creations are licensed under the identical terms.

**For reprints contact:** WKHLRPMedknow\_reprints@wolterskluwer.com

**How to cite this article:** Singh SU, Prasad RB, Punga R, Datta R, Singh N. A comparison of the outcomes following intra-articular steroid injection alone or arthrocentesis alone in the management of internal derangement of the temporomandibular joint. *Natl J Maxillofac Surg* 2022;13:S80-4.

### Access this article online

<b>Website:</b> www.njms.in	<b>Quick Response Code</b> 
<b>DOI:</b> 10.4103/njms.njms_291_21	

conditions. The prevalence of IDTMJ is approximately 25% of the population.<sup>[4]</sup>

Its management includes conservative therapy or surgical intervention where minimally invasive techniques such as arthroscopy, arthrocentesis, and intra-articular steroid injection have been used.

The following study was undertaken to evaluate the efficacy of intra-articular steroid injection or arthrocentesis in patients with IDTMJ who did not respond favorably to conservative management and to compare and infer which among the two procedures is more satisfactory.

## SUBJECTS AND METHODS

The present study was approved by the ethics committee of the university in which the study was conducted. Ethical Clearance was obtained from Ethical Committee with Ref no ABSM/EC35/2016 dated 17.10.2016.

Patients diagnosed with IDTMJ with pain, clicking, and limited mouth opening underwent conservative therapy with physiotherapy and splints. The patients who failed to receive any relief after 3 months of conservative therapy were recruited for this study. All such patients in the age range of 18 – 45 years who gave their consent for participation were included.

The exclusion criteria were as follows: (1) Patients having pain or reduced mouth opening due to fracture of the condyle; (2) patients having reduced mouth opening as a post-operative complication following the removal of 3<sup>rd</sup> molar; (3) patients having other systemic diseases such as polyarthritis; (4) patients having any neurological disorders; (5) patients having any degenerative changes in the TMJ; (6) Pregnant and lactating women; and (7) patients unwilling to participate in the study.

The patients were randomly distributed into two groups – 10 patients in Group A (Intra-articular steroid injection) and 10 patients in Group B (Arthrocentesis). Patients falling under the Wilke's category II and III based upon the clinical findings only were included. Imaging with MRI was not performed for our patients as it is reserved for patients with advanced stages of temporomandibular disorders.

The parameters noted for each patient were mouth opening (in millimetres), pain (through the Visual Analog Scale [VAS]), and presence or absence of clicking and these were evaluated before and after therapy for review of patients and comparison of the treatment outcomes.

## Procedure

All the patients in both the groups were operated upon by the same surgeon under local anesthesia with appropriate aseptic precautions. Anatomical landmarks of the TMJ were identified by a line drawn from the lateral canthus to the most posterior and central point on the tragus (Holmund-Helsing line as described by D. W. Nitzan.<sup>[5]</sup>) [Figure 1].

### Group A: Intra-articular steroid injection

Using the anatomical landmarks, the joint space was identified and 0.5 ml of local anesthetic (2% Lignocaine with 1:80000 Adrenaline) was injected approximately 20 mm beneath the skin surface into the superior joint space while the patient's mouth was kept wide open, via a sterile 2-ml syringe with a disposable 23G needle. The needle was retained in the joint space and the syringe was then detached and another syringe containing Kenacort (Triamcinolone acetonide 10 mg/ml, Abbott Healthcare Pvt. Ltd.) was attached and 0.5 ml of the drug was injected [Figure 2]. The needle then was removed and pressure maintained with a gauze over the injection site for 1–2 min. Patient's jaw was gently manipulated in the vertical, protrusive and lateral excursions and the patients were given written and verbal postoperative instructions [Table 1].

### Group B: Arthrocentesis

Using the same anatomical landmarks, Nitzan's two-needle Arthrocentesis technique<sup>[5]</sup> was followed, and the posterior and the anterior points of entry of needle were marked. The posterior point of entry was located along the canthotragal line 10 mm from the middle of the tragus and 2 mm below the canthotragal line. The distance was about 20 mm from the skin to the center of the superior joint space. The anterior point of entry was placed 10 mm further along the canthotragal line and 10 mm below it [Figure 3].

Local anesthetic (2% lignocaine with 1:80,000 adrenaline) was injected at the planned entrance points using a 23G needle.

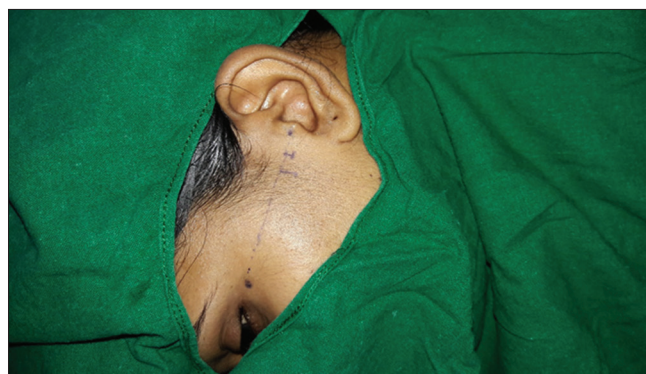

Figure 1: Holmund-Helsing line

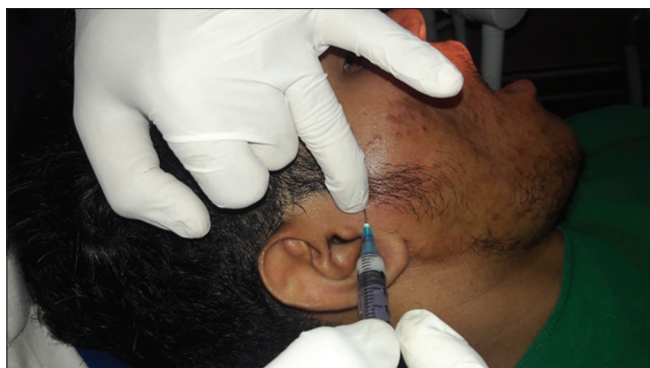

Figure 2: Intra-articular steroid injection

Following this, two 20G needles were then inserted into the superior joint cavity through the points marked. Through one needle, Ringer's lactate solution was injected and the second needle provided an outflow for the solution. A total of 100 ml of solution was used for lavage. After completion of the lavage, the needles were removed and the patient's jaw gently manipulated in the vertical, protrusive, and lateral excursions. The patients were given written and verbal postoperative instructions [Table 1].

Tools of assessment:

1. Pain

VAS was used.

2. Maximal mouth opening – Interincisal distance

Using a sterilized metal scale, mouth opening was measured in millimetres from the mesio-incisal angle of the upper right central incisor to that of the lower right central incisor.

3. The disappearance or persistence of the clicking sound was noted.

These values were recorded preoperatively, right after the procedure, at 3 days and at 3 months postoperatively.

## RESULTS

All patients recruited in this study had unilateral internal derangement of the TMJ and they participated in the study until completion of the 3 month follow-up period without loss to follow-up. A total of 20 patients were recruited for this study, the age and the sex distribution between the two groups was comparable.

The comparison of VAS pain scale, mouth opening and clicking between intra-articular steroid and arthrocentesis group at various points of time is represented in Table 2. The mean VAS 3 months postoperatively in both the groups differed significantly ( $P = 0.002$ ). However, there was no significant difference in the amount of mouth opening achieved upon comparison of both the groups at different points in time. Reduction or disappearance of clicking in

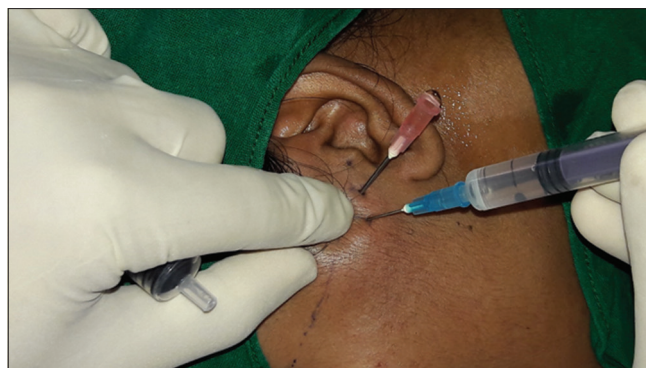

Figure 3: Arthrocentesis

Table 1: Postoperative instructions

Postoperative instructions
Soft diet for 2-3 weeks
Heat application over the joint thrice a day for a duration of 5 min each time
Gentle mouth opening exercises including protruding and lateral excursions
Not to sleep on the side of the joint treated

the joint also did not differ significantly when a comparison between the two groups was done.

Intragroup analysis depicted insignificant difference in clicking at various point of time from preoperative day, day of procedure, 3 days postoperative, and 3 months postoperative in both the groups [Table 3]. The VAS overall differed significantly from preoperative to 3 months postoperative in intra-articular steroid group ( $P < 0.001$ ). In the arthrocentesis group, the VAS overall differed significantly from preoperative to 3 months ( $P < 0.001$ ). The mouth opening overall differed significantly from the preoperative day to 3 months postoperatively in the intra-articular steroid group ( $P = 0.002$ ), whereas in the arthrocentesis group, the mouth opening overall differed significantly from preoperative to 3 months postoperative ( $P < 0.001$ ).

## Statistical analysis

Descriptive statistics such as mean and standard deviation were calculated for the continuous variables. Unpaired *t*-test was used to calculate mean age, VAS and mouth opening values between the two groups. The repeated-measures ANOVA was used to compare the mean values of VAS pain scale and mouth opening preoperative, day of procedure, postoperative 3 days and postoperative 3 months within the groups. Fisher's exact test was used to calculate clicking between the groups and Cochran Q within the groups. A value of  $P < 0.05$  is considered to be statistically significant. Microsoft Excel and IBM SPSS Statistics for Windows, Version 22.0. Armonk, NY, USA: IBM Corp was used for statistical analysis.

**Table 2: Comparison of Visual Analog Scale Pain Scale, mouth opening, and clicking between intra-articular steroid and arthrocentesis group at various points of time**

	Preoperative	Day of procedure	3 days postoperative	3 months postoperative
VAS scores				
Group A	6.40±1.51	3.10±1.52	4.20±1.39	3.90±1.10
Group B	6.10±1.85	3.20±1.99	3.30±1.64	2.00±1.25
P	0.696	0.901	0.203	0.002*
Mouth opening				
Group A	30.10±8.97	32.80±7.55	33.00±7.97	32.50±8.01
Group B	29.20±7.714	34.90±5.76	35.30±5.90	37.20±5.63
P	0.813	0.494	0.473	0.147
Clicking**				
Group A	4	2	2	2
Group B	2	2	2	2

\*P<0.05 is considered statistically significant, \*\*The number of patients having clicking is represented. VAS: Visual Analog Scale

**Table 3: Visual Analog Scale Pain Scale, mouth opening, and clicking in intra-articular steroid and arthrocentesis group at various points of time**

	Group A		Group B	
	Mean±SD	P	Mean±SD	P
VAS scores				
Preoperative	6.40±1.50	<0.001*	6.10±1.85	<0.001*
Day of procedure	3.10±1.52		3.20±1.98	
3 days postoperative	4.20±1.39		3.30±1.63	
3 months postoperative	3.90±1.10		2.00±1.24	
Mouth opening				
Preoperative	30.10±8.97	0.002*	29.20±7.71	<0.001*
Day of procedure	32.80±7.55		34.90±5.76	
3 days postoperative	33.00±7.97		35.30±5.90	
3 months postoperative	32.50±8.01		37.20±5.63	
Clicking**				
Preoperative	4	-	2	-
Day of procedure	2		2	
3 days postoperative	2		2	
3 months postoperative	2		2	

\*P<0.05 is considered statistically significant, \*\*The number of patients having clicking is represented. SD: Standard deviation, VAS: Visual Analog Scale

## DISCUSSION

Temporomandibular disorders comprise a wide range of pathological conditions and functional changes which can affect the muscles of mastication or the joint itself.<sup>[6]</sup>

The management of such patients includes conservative and surgical modalities. Surgery is considered when conservative treatment (analgesics, surgical splints, heat therapy, and soft diet) fail.

Patients recruited in this study underwent conservative management. If the symptoms persisted, minimally invasive methods (arthrocentesis or intra-articular injection of corticosteroids) are undertaken.

Studies of injections into the TMJ have shown reduction in pain and improvement in mouth opening after an

intra-articular steroid injection in patients with restricted mouth opening and pain.<sup>[1,7-9]</sup> Pain is reduced due to decrease in the synthesis of prostaglandin E as the corticosteroids are known to inhibit the production of arachidonic acid.<sup>[9]</sup> Despite being an intermediate acting agent, Triamcinolone acetonide (Kenacort) has a very low solubility and long duration which favors its use as an intra-articular agent.<sup>[10]</sup> Due to the administration of a single steroid injection into the TMJ instead of multiple injections, the well-documented local side effects of corticosteroids including infections, destruction of the articular cartilage, chemical condylolysis, and the aggravation of an already existing TMJ disease<sup>[11]</sup> were not experienced by any of the patients included in our study.

Numerous studies and reviews have proven that arthrocentesis (first described by D. W. Nitzan), a highly successful, relatively simple, and minimally invasive procedure is a safe and

simple method for IDTMJ both in short-term and a long-term follow-up period.<sup>[3,4,12-15]</sup>

A study to compare the efficacy of arthrocentesis and intra-articular steroid injection for the management of temporomandibular disorders, to the best of our knowledge has not been published in literature as substantiated by a PubMed search of the keywords “Arthrocentesis,” “Intra-articular steroid injection,” “comparison,” “TMJ.”

Our aim was to evaluate the efficacy of intra-articular steroid injection and arthrocentesis in patients with IDTMJ and to compare and infer which among the two procedures is more satisfactory. The results of our study, in accordance with numerous other studies, imply that both the treatment modalities are effective in reducing the signs and symptoms of the patients with IDTMJ with Arthrocentesis providing slightly better relief from pain along with improvement in mouth opening when compared to intra-articular injection with corticosteroid over a period of 3 months which in our study was a time frame considered for understanding the long-term effects of the procedures. Besides this, both the treatment modalities proved to be economical.

## CONCLUSION

This study has demonstrated that both the techniques show improvement in the symptoms of IDTMJ, but with better improvements in pain and mouth opening the authors would suggest that arthrocentesis is the superior technique.

## Acknowledgments

1. Ethics approval: Approved by the ethics committee of NITTE University, AB Shetty Memorial Institute of Dental Science
2. Consent to participate: All patients included in the study have their consent for participation
3. All authors have viewed and agreed to the submission.

## Declaration of patient consent

The authors declare that they have obtained consent from patients. Patients have given their consent for their images and other clinical information to be reported in the journal. Patients understand that their names will not be published

and due efforts will be made to conceal their identity but anonymity cannot be guaranteed.

## Financial support and sponsorship

Nil.

## Conflicts of interest

There are no conflicts of interest.

## REFERENCES

1. Mountziaris PM, Kramer PR, Mikos AG. Emerging intra-articular drug delivery systems for the temporomandibular joint. *Methods* 2009;47:134-40.
2. Adams JC, Hamblen DL. *Outline of Orthopaedics*. 13<sup>th</sup> ed. London: Churchill Livingstone; 2001. p. 135.
3. Malik AH, Shah AA. Efficacy of temporomandibular joint arthrocentesis on mouth opening and pain in the treatment of internal derangement of TMJ-A clinical study. *J Maxillofac Oral Surg* 2014;13:244-8.
4. Neeli AS, Umarani M, Kotrashetti SM, Baliga S. Arthrocentesis for the treatment of internal derangement of the temporomandibular joint. *J Maxillofac Oral Surg* 2010;9:350-4.
5. Tozoglu S, Al-Belasy FA, Dolwick MF. A review of techniques of lysis and lavage of the TMJ. *Br J Oral Maxillofac Surg* 2011;49:302-9.
6. Tvrdy P, Heinz P, Pink R. Arthrocentesis of the temporomandibular joint: A review. *Biomed Pap Med Fac Univ Palacky Olomouc Czech Repub* 2015;159:31-4.
7. Toller PA. Use and misuse of intra-articular corticosteroids in treatment of temporomandibular joint pain. *Proc R Soc Med* 1977;70:461-3.
8. Samiee A, Sabzerou D, Edalatpajouh F, Clark GT, Ram S. Temporomandibular joint injection with corticosteroid and local anesthetic for limited mouth opening. *J Oral Sci* 2011;53:321-5.
9. Zandi M. The role of corticosteroids in today's oral and maxillofacial surgery. In: *Glucocorticoids-New Recognition of Our Familiar Friend*. USA: InTech; 2012.
10. Laskin DM, Greene CS, Hylander WL, editors. *Temporomandibular Disorders: An Evidence-Based Approach to Diagnosis and Treatment*. USA: Quintessence Publishing Company; 2006.
11. Schindler C, Paessler L, Eckelt U, Kirch W. Severe temporomandibular dysfunction and joint destruction after intra-articular injection of triamcinolone. *J Oral Pathol Med* 2005;34:184-6.
12. Nitzan DW, Dolwick MF, Martinez GA. Temporomandibular joint arthrocentesis: A simplified treatment for severe, limited mouth opening. *J Oral Maxillofac Surg* 1991;49:1163-7.
13. Monje-Gil F, Nitzan D, González-García R. Temporomandibular joint arthrocentesis. Review of the literature. *Med Oral Patol Oral Cir Bucal* 2012;17:e575-81.
14. Dimitroulis G, Dolwick MF, Martinez A. Temporomandibular joint arthrocentesis and lavage for the treatment of closed lock: A follow-up study. *Br J Oral Maxillofac Surg* 1995;33:23-6.
15. Carvajal WA, Laskin DM. Long-term evaluation of arthrocentesis for the treatment of internal derangements of the temporomandibular joint. *J Oral Maxillofac Surg* 2000;58:852-5.