

Short-term Effects of Date Palm Extract (*Phoenix dactylifera*) on Ischemia/Reperfusion Injury Induced by Testicular Torsion/Detorsion in Rats

Alireza Raayat Jahromi, Rokhsana Rasooli¹, Younes Kamali¹, Nasrollah Ahmadi², Ehsan Sattari¹

Departments of Clinical Sciences, ¹Basic Sciences and ²Pathobiology, School of Veterinary Medicine, Shiraz University, Shiraz, Iran

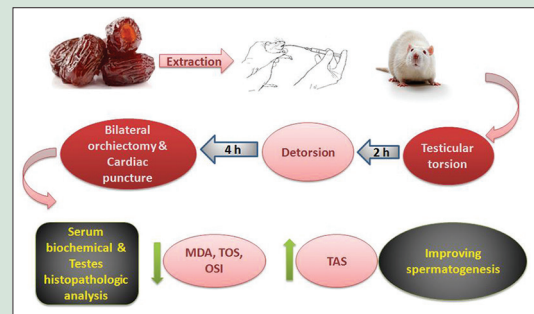
ABSTRACT

Background: Antioxidants are potent scavengers of free radicals and have beneficial effects on human health. **Objective:** The aim of this study was to investigate the potential protective antioxidant activity of the edible portion of date fruit extract in an experimental testicular torsion/detorsion (T/D) model in rats. **Materials and Methods:** To investigate the potential protective effects of date palm (DP), 30 male Sprague-Dawley rats were divided into three groups: sham-operated, T/D, and T/D + DP-treated (500 mg/kg, PO) groups. Testicular ischemia was induced via keeping the left testis under 720° clockwise torsion for 2 h (h), afterward, detorsion was performed. All rats were sacrificed 4 h after detorsion. Serum malondialdehyde (MDA) concentration, total oxidative status (TOS), total antioxidant status (TAS), oxidative stress index (OSI), and histopathological damage score were evaluated. **Results:** Serum MDA, TOS, and OSI levels rose significantly in the T/D group. These values were lower in the T/D + DP group. TAS values decreased significantly in T/D group and rose in T/D + DP group. Severe injury was seen in the twisted testes of T/D group. In contrast, ipsilateral-twisted testicular tissue in the DP-treated group showed moderate-to-mild changes. Contralateral testicular tissue in the T/D group had a mild-to-moderate tissue injury; meanwhile, treated group revealed normal-to-mild changes. Spermatogenesis was significantly improved in DP-treated group when compared with the T/D group. **Conclusion:** The findings suggest a possible protective effect of DP against testicular oxidative damage induced by T/D; however, more detailed studies are warranted.

Key words: Antioxidant markers, histopathology, ischemia/reperfusion, *Phoenix dactylifera*, testis

SUMMARY

Given the presence of several phenolic compounds possessing high antioxidant activity in DP, it could potentially be used to reduce testis ischemia/reperfusion-induced damage.



Abbreviations Used: TAS: Total antioxidant status, TOS: Total oxidative status; OSI: Oxidative stress index; MDA: Malondialdehyde; C: Congestion; H: Hemorrhage, E: Edema; SG: Sloughed germinal cells; SA: Spermatogenesis arrest; STD: Seminiferous tubules disorganization; STA: Seminiferous tubules atrophy; G: Giant cells; T/D: Torsion/detorsion; DP: Date palm

Correspondence:

Dr. Younes Kamali,
Department of Anatomical Sciences, Division of
Anatomy and Embryology, School of Veterinary
Medicine, Shiraz University, Shiraz, Iran.
E-mail: youn.kamali@gmail.com
DOI: 10.4103/0974-8490.199769

Access this article online

Website: www.phcogres.com

Quick Response Code:



INTRODUCTION

Testicular torsion is a genitourinary emergency that requires an immediate surgical correction. This condition causes ischemic reperfusion which damages the testicular tissue and affects the quality of sperm.^[1] It usually happens following the rotation of testis around the axis of the spermatic cord, and it is frequently observed in newborns, children, and adolescents.^[2] Long-time torsion results in necrosis of the germinal cells. This may lead to subfertility or infertility.^[3,4] Testicular tissue blood flow subsequent to the reperfusion exposes the tissue to the produced reactive oxygen species (ROS) and consequently an ischemia/reperfusion (I/R) injury.^[5,6] The mechanism involved in testicular injury is not completely understood; however, oxidative stress is considered to be the main nocent in I/R injury.^[7-9] Oxidative stress is the result of an imbalance between excessive ROS production and antioxidant mechanisms.^[10]

It is demonstrated that ipsilateral testicular torsion could affect the contralateral testis too.^[11-13] Under normal conditions, free radicals are produced and their effects are counterbalanced by the endogenous antioxidant system.^[14] When ROS generation exceeds the defense

mechanism's capacity to control, oxidative stress makes many reversible or irreversible cell injuries.^[15] Antioxidants either synthetic or natural are potent scavengers of free radicals and have beneficial effects on human health and disease prevention.^[16] Previous studies suggest that pretreatment with antioxidants can protect the testis against ROS insult.^[16,17] Date palm (DP) is an excellent antioxidant agent due to the high concentrations of phenolic compounds, flavonoids (luteolin, methyl luteolin, quercetin, and epicatechin), and anthocyanins as well as the presence of selenoproteins, coumaric acid, and ferulic acid.^[17] It is also scientifically proved to possess anti-inflammatory, immunomodulatory, vascular protective, and sex

This is an open access article distributed under the terms of the Creative Commons Attribution-NonCommercial-ShareAlike 3.0 License, which allows others to remix, tweak, and build upon the work non-commercially, as long as the author is credited and the new creations are licensed under the identical terms.

For reprints contact: reprints@medknow.com

Cite this article as: Jahromi AR, Rasooli R, Kamali Y, Ahmadi N, Sattari E. Short-term effects of date palm extract (*Phoenix dactylifera*) on ischemia/reperfusion injury induced by testicular torsion/detorsion in rats. *Phcog Res* 2017;9:69-73.

hormone modulator effects.^[18-20] *In vitro* antioxidant activity of the aqueous extract of date fruit is demonstrated in many studies based on its phenolic compounds with potent free radical scavenging activity.^[21,22] The aim of this study was to investigate the potential protective antioxidant activity of the edible portion of date fruit extract *in vivo*, in an experimental testicular torsion/detorsion (T/D) model in rats.

MATERIALS AND METHODS

Preparation of extracts

Fresh date fruits (*Phoenix dactylifera* L., *Palmae*) were provided from a local market in Bam (Kerman Province, Iran), dried at room temperature, and were manually separated from the pits. The flesh of the dried *P. dactylifera* fruits was grinded and pulverized into powder. About 650 g of the powder was soaked in 2 L of cold distilled water. After 24 h, the solution was filtered and evaporated under vacuum and dried to a constant weight using a freeze-drier. The dry extract of the fruit was dissolved in distilled water instantaneously before giving to rats.

Animals

This experiment was accomplished under the approval of the State Committee on Animal Ethics, Shiraz University, Shiraz, Iran. In addition, the recommendations of the European Council Directive (86/609/EC) of November 24, 1986, were used regarding the standards in the protection of animals used for experimental purposes. Thirty male Sprague-Dawley rats weighing 240–270 g were housed two per cage; maintained on a balanced diet and water *ad libitum* with 12/12 h light-dark cycle. Animals were divided into three groups and pretreated orally for 10 days as follows: Group 1 (500 mg/kg DP extract), Group 2 (1 ml saline), and Group 3 (sham-operated with no oral administration). The selected dose of DP was based on our previous pilot study. All groups received their treatment by oral force fed with a special gavage needle. After 10 days, rats were anesthetized using intraperitoneal administration of a combination of ketamine (80 mg/kg BW) and xylazine (5 mg/kg BW). Torsion, detorsion, and sham operation were performed through the standard ilioinguinal incisions following routine surgical preparations. Unilateral testicular torsion was performed by rotating the left testis clockwise along its longitudinal axis to 720° of its initial position. Torsion was maintained in position by fixing the testis tunica albuginea to the scrotum via a simple interrupted nylon suture (4-0). Ilioinguinal incision was closed, and the rats were transferred to the clean cages for recovery. The sham-operated control rats underwent similar operation; manipulation of testis was done without any torsion. After 2 h, detorsion was performed through releasing the testis and replacing into the scrotum. After 4 h of detorsion, animals were sacrificed by cervical vertebra dislocation.

Biochemical analysis

Cardiac puncture was performed, and blood samples were collected in chilled nonheparinized tubes, kept in room temperature for 2 h, and centrifuged at 1500 ×g for 15 min at 4°C. Separated sera evaluated for biochemical indicators included serum malondialdehyde (MDA), total antioxidant status (TAS), and total oxidant status (TOS).

Measurement of total antioxidant status

TAS level was determined using the method developed by Erel.^[23] Serum TAS levels were calculated in mmol Trolox equivalent/L.

Measurement of total oxidant status

TOS levels were determined using a novel automated and colorimetric measurement method as previously described by Erel.^[24] Serum TOS levels were calculated in μmol H₂O₂ equivalent/L.

Calculation of oxidative stress index

TOS: TAS ratio was used as the oxidative stress index (OSI). To perform the calculation, the unit of TAS, mmol Trolox equivalent/L, was converted to μmol Trolox equivalent/L, and OSI was calculated as follows: $OSI = ([TOS, \mu\text{mol H}_2\text{O}_2 \text{ equivalent/L}]/[TAS, \mu\text{mol Trolox equivalent/L}] \times 100)$.^[25]

Serum malondialdehyde activity assay

Lipid peroxidation in rat serum samples was determined as MDA concentration using the method described by Yagi.^[26] Tetramethoxypropane was used as a standard, and MDA levels were given as nmol/mL.

Histopathological analysis

Bilateral orchietomy was performed. The testes were immersed in 10% buffered formalin. Testes tissues were processed by routine histological methods and embedded in paraffin blocks that were placed in a rotary microtome. Sections of 5 μm thickness were obtained with disposable metal microtome blades. After deparaffinization and rehydration, all sections were stained with hematoxylin and eosin. Testicular injury was determined based on certain characteristics including hemorrhage/congestion, edema, degeneration, sloughing of germ cell layers, spermatogenesis arrest, seminiferous tubule disorganization, seminiferous tubule atrophy, presence of giant cells, and polymorphonuclear cells infiltration.

Mid-testis cross-sections were given a score from normal to severe on the basis of classification of Cosentino *et al.*^[27] as follows: Grade 1 (normal), Grade 2 (mild), Grade 3 (moderate), and Grade 4 (severe). Normal injury: Normal seminiferous tubules with a regular array of germinal cells; mild injury: Disturbances of seminiferous epithelium in a few tubules; and moderate injury: Disruption of seminiferous epithelium in many tubules. Disruptions are largely limited to the loss of spermatids and spermatozoa, but sloughed germinal cells might be seen in some tubules. Finally, severe injury: Disturbances of seminiferous epithelium in the majority of tubules and complete loss of germinal layers.

The mean testicular biopsy score was graded by using Johnsen's score.^[28] A total of 100 tubules with a ×40 magnification were assessed, and a score of 1–10 was given to each tubule, according to the maturity of the germ cells. Complete loss of seminiferous epithelial cells was considered as score 1 and the tubules having the maximum activity scored as 10.

Statistical analysis

Data were presented as the mean ± standard deviation. One-way ANOVA was used for statistical analysis of data between the different groups. Multiple comparisons were made using Tukey's procedure. $P < 0.05$ was considered statistically significant.

RESULTS

Histopathology and testicular injury scoring

Severe injuries were seen in the twisted testis of T/D group [Figure 1b-f]. In contrast, ipsilateral-twisted testicular tissue in DP-treated group showed mild-to-moderate changes [Figure 1g]. Contralateral testicular tissue had mild injury in T/D group, and also slight changes were seen in the treated group. Detailed histopathological results are shown in Table 1.

The testes epithelial maturation score based on the Johnsen's score is shown in Table 2. The ipsilateral testes of T/D group displayed a lower Johnsen's score ($P < 0.001$) when compared with the sham operation group. The mean Johnsen's scores of treatment group in ipsilateral testes showed higher scores when compared with T/D group. In contralateral

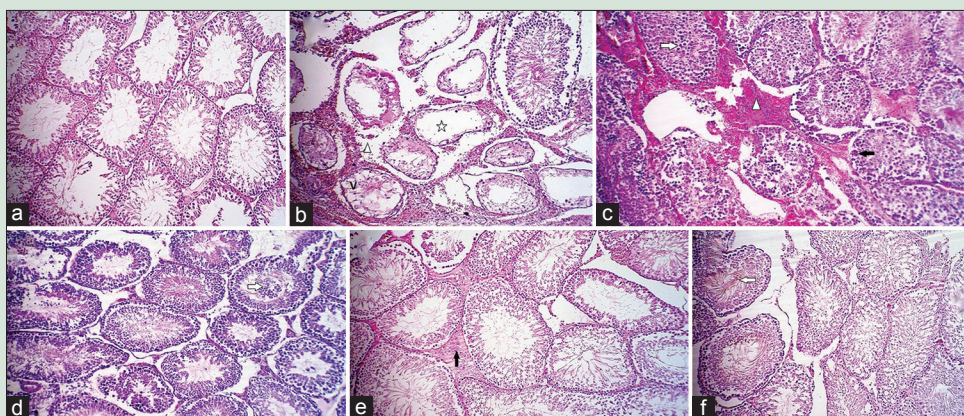


Figure 1: (a) The bilateral testes in sham group and the contralateral testes in date palm-treated group indicated normal seminiferous tubules. (b and c) the ipsilateral testes in testicular torsion/detorsion group showed seminiferous tubular atrophy and spermatogenesis arrest (star), severe hemorrhage, and edema (Δ) between the seminiferous tubules, increased vacuolization between epithelial cells (v), disordered, sloughed germinal cells within the seminiferous tubules (white arrowhead), and giant cell (black arrowhead). (d and e) (The ipsilateral testes of the date palm-treated group); seminiferous tubule architecture was more regular and normal, but showed moderate sloughed germinal cells (white arrowhead). Vacuolization and spermatogenesis arrest observed in the torsion/detorsion group were not seen in this group. Hemorrhage and edema were also mild (black arrow). (f) The contralateral testes in testicular torsion/detorsion group displayed immature germinal cells in the lumen (white arrowhead) (H and E, $\times 40$)

Table 1: Mean \pm standard deviation of histological scoring of the testicular tissue in sham and experimental groups

Testes direction	Groups	C	H	Different		SA	STD	STA	G
				E	SG				
Left	Sham	1.1 \pm 0.32 ^b	1.1 \pm 0.32 ^b	1.3 \pm 0.48 ^b	1 \pm 0.00 ^b	1 \pm 0.00 ^b	1 \pm 0.00 ^b	1 \pm 0.00 ^b	1 \pm 0.00 ^b
	T/D	3.7 \pm 0.48 ^a	3.7 \pm 0.48 ^a	3.7 \pm 0.48 ^a	3.7 \pm 0.48 ^a	3.7 \pm 0.48 ^a	3.5 \pm 0.53 ^a	3.6 \pm 0.52 ^a	3.7 \pm 0.48 ^a
	T/D + DP	1.6 \pm 0.70 ^c	2 \pm 0.67 ^c	2.4 \pm 0.84 ^c	2.1 \pm 0.74 ^c	2 \pm 0.47 ^c	2.2 \pm 0.42 ^c	2 \pm 0.47 ^c	2.4 \pm 0.51 ^c
Right	Sham	1.0 \pm 0.00 ^b	1 \pm 0.00 ^b	1 \pm 0.00 ^b	1 \pm 0.00 ^b	1 \pm 0.00 ^b	1 \pm 0.00 ^b	1 \pm 0.00 ^b	1 \pm 0.00 ^b
	T/D	1.4 \pm 0.52 ^b	1.3 \pm 0.48 ^b	1.7 \pm 0.48 ^d	1.2 \pm 0.42 ^b	1.1 \pm 0.32 ^b	1.1 \pm 0.32 ^b	1.3 \pm 0.48 ^b	1 \pm 0.00 ^b
	T/D + DP	1.2 \pm 0.42 ^b	1.1 \pm 0.32 ^b	1.4 \pm 0.52 ^{b,d}	1 \pm 0.00 ^b	1 \pm 0.00 ^b	1 \pm 0.00 ^b	1 \pm 0.00 ^b	1 \pm 0.00 ^b

^{a,b,c}At each column, different superscript alphabets show a significant difference ($P < 0.05$). C: Congestion; H: Hemorrhage; E: Edema; SG: Sloughed germinal cells; SA: Spermatogenesis arrest; STD: Seminiferous tubules disorganization; STA: Seminiferous tubules atrophy; G: Giant cells; T/D: Torsion/detorsion; DP: Date palm

Table 2: Mean \pm standard deviation of Johnsen's score in sham operation, torsion/detorsion, and torsion/detorsion+date palm groups

Testis direction	Sham	Experimental groups	
		T/D	T/D + DP
Left	9.1 \pm 0.87 ^a	3.1 \pm 0.87 ^d	7.4 \pm 0.84 ^b
Right	9.5 \pm 0.71 ^a	7.2 \pm 0.63 ^b	9.1 \pm 0.57 ^a

^{a,b,c}At each column, different superscript alphabets show a significant difference ($P < 0.05$). T/D: Torsion/detorsion; DP: Date palm

testes, spermatogenesis in treated group significantly improved compared with T/D group.

Biochemical results

Biochemical results of the T/D, sham, and treated groups are shown in Table 3. TAS values decreased significantly in T/D group. Although it increased in T/D + DP-treated group compared to the T/D group, it was not significant. OSI and TOS values were significantly higher and lower in T/D and T/D + DP-treated groups, respectively ($P \leq 0.05$). In addition, MDA levels decreased significantly in DP pretreated group.

DISCUSSION

Oxidative stress is known as the most important guilt in testicular I/R injury,^[7,15] and antioxidant agents are proved to be able to control it. Obviously, oxidative stress manifests with an increase in oxidants as well as a decrease in antioxidants. Sporadic assessment of antioxidant

enzymes is time-consuming and expensive. Therefore, measuring all antioxidant levels is proposed to oxidant status evaluation. TOS and TAS as a combination of oxidant and antioxidant parameters, i.e. MDA, glutathione peroxidase, and catalase, are, therefore, valuable in terms of definition the body's net stress. In the present study, TAS and TOS, the novel techniques developed by Erel in full determination of oxidant and antioxidant status, were used. The TOS to TAS ratio represents the OSI.^[29] The OSI reflects an increased oxidant status or a decreased antioxidant status.^[7]

In our study, TOS and OSI values were significantly higher in T/D group, but TAS values decreased. Lowered TOS and elevated TAS values in the treated group suggest a protective effect of palm date against testicular T/D. Oxygen free radicals, formed during the reperfusion period, cause the oxidation of genetic materials, proteins, and membrane lipids.^[30]

MDA, another marker of oxidative stress, can impair a few physiological mechanisms in human body because of its ability to react with molecules such as deoxyribonucleic acid and proteins. These molecules can thus be considered to be something more than merely a lipid peroxidation product.^[31] As a result, MDA level in T/D group elevated significantly compared to the sham group. In the DP-treated group, plasma MDA level reduced compared to the T/D group. Previous studies have emphasized that DP fruit is an excellent source of phenolics and therefore, possesses an extremely high antioxidant capacity.^[17] Our findings support this, which would be translated to the alimentation of serum antioxidant power in treated groups.

Table 3: Profile of plasma antioxidant in sham and experimental groups

Biochemical parameters	T/D	T/D + DP	Sham
TAS (mmol Trolox equivalent/L)	1.01±0.19	1.12±0.06	1.31±0.18
TOS (µmol H ₂ O ₂ equivalent/L)	12.99±0.58 ^a	10.79±0.36 ^a	11±0.21
OSI H ₂ O ₂ /Trolox	1286.13	963.39	839.69
Plasma MDA (nmol/mL)	0.29±0.04 ^a	0.19±0.04 ^a	0.11±0.07

TAS: Total antioxidant status; TOS: Total oxidative status; OSI: Oxidative stress index; MDA: Malondialdehyde; T/D: Torsion/detorsion; DP: Date palm

Consistent with the serological findings, histological analysis in ipsilateral-twisted testicular tissues revealed mild-to-moderate injury in pretreated rats and severe injury in T/D group. The difference between the severity of lesions at the microscopic level may seem rather arbitrary and not reproducible. However, the scoring system from a semi-quantitative perspective of histological feature showed a trend toward the protective effect by palm date [Table 1 and Figure 1].

Spermatogenesis and fertility can be significantly affected by testicular I/R injury.^[17] Based on the Johnsen tubular score, spermatogenesis significantly damaged in the I/R group. However, the Johnsen tubular score was significantly higher in DP-treated group than in the I/R group. This finding indicates that DP administration rescues spermatogenesis damage and may also prevent testicular I/R injury-induced infertility.

The degree and duration of torsion have been shown to be important in testicular injuries development. In our study, after 2 h torsion and 4 h detorsion, the seminiferous tubule germinal epithelium was detached and spermatogenesis stopped. These findings were in accordance to Turkmen *et al.*'s study^[32] that reported following 2 h torsion and 4 h detorsion, germinal epithelial cells were present in the lumen of the seminiferous tubule in the T/D group. As already demonstrated, the testis injury prospers as the detorsion period extends after the torsion. Furthermore, in accordance with other assertions, contralateral testis was affected when ipsilateral testis was subjected to T/D. Decreasing testicular blood flow and subsequent tissue hypoxia are the reasons for contralateral testicular injury after T/D;^[33] however, the exact pathogenesis of contralateral abnormalities in patients with unilateral testicular torsion is not understood. Furthermore, it has been hypothesized that increased apoptosis in contralateral testis cells after ipsilateral testicular torsion is related to the breakdown of the blood-testis barrier of the twisted testis, which may increase the risk of infertility,^[34] whereas the extent of apoptosis and necrotic changes within the twisted testicle is directly correlated with the duration of torsion.

As mentioned above, the antioxidant activity of DP has been attributed to phenolic compounds, flavonoids, and anthocyanins as well as the presence of selenoproteins.^[34] The effect of DP on brain I/R injury is proved too. The results have revealed that this extract has a substantial neuroprotective impact against cerebral ischemia and consequent reperfusion.^[35,36] In another study, it was demonstrated that DP aqueous extract improves the plasma lipid profiles of the diet induced hypercholesterolemic rabbits through the augmentation of specific biosynthesis of antioxidant enzymes.^[37] Consistent with these studies, our study showed that *P. dactylifera* is able to mitigate I/R injury induced by T/D in rat testis.

CONCLUSION

Inhibitors of oxidative stress provide a significant beneficial effect on testicular I/R injury. DP is a powerful radical scavenger, and its free radical scavenging ability should be considered to a greater extent.

Financial support and sponsorship

This research was financially supported by grants of the Shiraz University Research Council.

Conflicts of interest

There are no conflicts of interest.

REFERENCES

- Uyeturk U, Terzi EH, Gucuk A, Kemahli E, Ozturk H, Tosun M. Prevention of torsion-induced testicular injury by *Rhodiola rosea*. *Urology* 2013;82:254.e1-6.
- Dundar O, Yoruk P, Tutuncu L, Erikci AA, Muhcu M, Ergur AR, *et al.* Longitudinal study of platelet size changes in gestation and predictive power of elevated MPV in development of pre-eclampsia. *Prenat Diagn* 2008;28:1052-6.
- Wei SM, Yan ZZ, Zhou J. *Psoralea corylifolia* protects against testicular torsion/detorsion-induced ischemia/reperfusion injury. *J Ethnopharmacol* 2011;137:568-74.
- Gezici A, Ozturk H, Buyukbayram H, Ozturk H, Okur H. Effects of gabexate mesilate on ischemia-reperfusion-induced testicular injury in rats. *Pediatr Surg Int* 2006;22:435-41.
- Aktas BK, Bulut S, Bulut S, Baykam MM, Ozden C, Senes M, *et al.* The effects of N-acetylcysteine on testicular damage in experimental testicular ischemia/reperfusion injury. *Pediatr Surg Int* 2010;26:293-8.
- Wei SM, Yan ZZ, Zhou J. Beneficial effect of taurine on testicular ischemia-reperfusion injury in rats. *Urology* 2007;70:1237-42.
- Yulug E, Türedi S, Karagüzel E, Kutlu O, Mentese A, Alver A. The short term effects of resveratrol on ischemia-reperfusion injury in rat testis. *J Pediatr Surg* 2014;49:484-9.
- Hoori F, Ehsanpour AA, Mostajeran A. Comparison of somatic embryogenesis in *Medicago sativa* and *Medicago truncatula*. *Pak J Biol Sci* 2007;10:481-5.
- Yang S, Shih HJ, Chow YC, Wang TY, Tsai PS, Huang CJ. Simvastatin attenuates testicular injury induced by torsion-detorsion. *J Urol* 2010;184:750-6.
- Akgür FM, Kiliç K, Aktug T. Reperfusion injury after detorsion of unilateral testicular torsion. *Urol Res* 1993;21:395-9.
- Kosar A, Sarica K, Küpeli B, Alçigir G, Süzer O, Küpeli S. Testicular torsion: Evaluation of contralateral testicular histology. *Int Urol Nephrol* 1997;29:351-6.
- Heindel RM, Pakyz RE, Cosentino MJ. Spermatic cord torsion. Contralateral testicular degeneration at various ages in the rat. *J Androl* 1990;11:506-13.
- Ciftci AO, Müftüoğlu S, Cakar N, Tanyel FC. Histological evidence of decreased contralateral testicular blood flow during ipsilateral testicular torsion. *Br J Urol* 1997;80:783-6.
- Salmasi AH, Beheshtian A, Payabvash S, Demehri S, Ebrahimkhani MR, Karimzadegan M, *et al.* Effect of morphine on ischemia-reperfusion injury: Experimental study in testicular torsion rat model. *Urology* 2005;66:1338-42.
- Akondi BR, Challa SR, Akula A. Protective effects of rutin and naringin in testicular ischemia-reperfusion induced oxidative stress in rats. *J Reprod Infertil* 2011;12:209-14.
- Bagchi D, Bagchi M, Stohs SJ, Das DK, Ray SD, Kuszynski CA, *et al.* Free radicals and grape seed proanthocyanidin extract: Importance in human health and disease prevention. *Toxicology* 2000;148:187-97.
- Aktoz T, Kanter M, Aktas C. Protective effects of quercetin on testicular torsion/detorsion-induced ischaemia-reperfusion injury in rats. *Andrologia* 2010;42:376-83.
- Chaira N, Smaali MI, Martinez-Tomé M, Mrabet A, Murcia MA, Ferhichi A. Simple phenolic composition, flavonoid contents and antioxidant capacities in water-methanol extracts of Tunisian common date cultivars (*Phoenix dactylifera* L.). *Int J Food Sci Nutr* 2009;60 Suppl 7:316-29.
- Rahmani AH, Aly SM, Ali H, Babiker AY, Srikar S, Khan AA. Therapeutic effects of date fruits (*Phoenix dactylifera*) in the prevention of diseases via modulation of anti-inflammatory, anti-oxidant and anti-tumour activity. *Int J Clin Exp Med* 2014;7:483-91.
- Wittenborg A, Petersen G, Lorkowski G, Brabant T. Effectiveness of Vitamin E in comparison with diclofenac sodium in treatment of patients with chronic polyarthritis. *Z Rheumatol* 1998;57:215-21.
- Vayalil PK. Antioxidant and antimutagenic properties of aqueous extract of date fruit (*Phoenix dactylifera* L. Arecaceae). *J Agric Food Chem* 2002;50:610-7.
- Pagliano P, Attanasio V, Fusco U, Mohamed DA, Rossi M, Faella FS. Does etanercept monotherapy enhance the risk of *Listeria monocytogenes* meningitis? *Ann Rheum Dis* 2004;63:462-3.
- Erel O. A novel automated direct measurement method for total antioxidant capacity using a new generation, more stable ABTS radical cation. *Clin Biochem* 2004;37:277-85.
- Erel O. A new automated colorimetric method for measuring total oxidant status. *Clin Biochem* 2005;38:1103-11.
- Aycicek A, Erel O, Kocyigit A. Decreased total antioxidant capacity and increased oxidative stress in passive smoker infants and their mothers. *Pediatr Int* 2005;47:635-9.

26. Yagi K. Lipid peroxides and related radicals in clinical medicine. *Adv Exp Med Biol* 1994;366:1-15.
27. Cosentino MJ, Nishida M, Rabinowitz R, Cockett AT. Histopathology of prepubertal rat testes subjected to various durations of spermatic cord torsion. *J Androl* 1986;7:23-31.
28. Johnsen SG. Testicular biopsy score count – A method for registration of spermatogenesis in human testes: Normal values and results in 335 hypogonadal males. *Hormones* 1970;1:2-25.
29. Feng JF, Lu L, Zeng P, Yang YH, Luo J, Yang YW, *et al.* Serum total oxidant/antioxidant status and trace element levels in breast cancer patients. *Int J Clin Oncol* 2012;17:575-83.
30. Filho DW, Torres MA, Bordin AL, Crezcynski-Pasa TB, Boveris A. Spermatic cord torsion, reactive oxygen and nitrogen species and ischemia-reperfusion injury. *Mol Aspects Med* 2004;25:199-210.
31. Del Rio D, Stewart AJ, Pellegrini N. A review of recent studies on malondialdehyde as toxic molecule and biological marker of oxidative stress. *Nutr Metab Cardiovasc Dis* 2005;15:316-28.
32. Turkmen S, Mentese A, Karaguzel E, Karaca Y, Kucuk A, Uzun A, *et al.* A comparison of the effects of N-acetylcysteine and ethyl pyruvate on experimental testicular ischemia-reperfusion injury. *Fertil Steril* 2012;98:626-31.
33. Hadziselimovic F, Geneto R, Emmons LR. Increased apoptosis in the contralateral testes of patients with testicular torsion as a factor for infertility. *J Urol* 1998;160(3 Pt 2):1158-60.
34. Baliga MS, Baliga BR, Kandathil SM, Bhat HP, Vayalil PK. A review of the chemistry and pharmacology of the date fruits (*Phoenix dactylifera* L.). *Food Res Int* 2011;44:1812-22.
35. Pujari RR, Vyawahare NS, Kagathara VG. Evaluation of antioxidant and neuroprotective effect of date palm (*Phoenix dactylifera* L.) against bilateral common carotid artery occlusion in rats. *Indian J Exp Biol* 2011;49:627-33.
36. Majid AS, Marzieh P, Shahriar D, Zahed SK, Pari KT. Neuroprotective effects of aqueous date fruit extract on focal cerebral ischemia in rats. *Pak J Med Sci* 2008;24:661-5.
37. Hasan NS, Amom ZH, Nor A, Arapoc DJ, Azlan A. The role of dates (*Phoenix dactylifera*) aqueous extract in improving the plasma lipid profiles of diet-induced hypercholesterolemic rabbits. *Res J Biol Sci* 2010;5:632-7.



Younes Kamali

ABOUT AUTHOR

Younes Kamali He received his degree in veterinary medicine from Shahid Bahonar University of Kerman and recently graduated as a philosophy doctor (PhD) from the school of veterinary medicine, Shiraz University, Iran. He is interesting studies in the field of comparative anatomy, clinical anatomy, and embryology with ultimate goal of understanding male external genitalia development and disorders. Current work is mainly focused on development of testicular descent.