


# 46 XX male syndrome with hypogonadotropic hypogonadism: A case report

 Mehmet M Yalcin,<sup>1</sup>  Cigdem Ozkan,<sup>1</sup>  Mujde Akturk,<sup>1</sup>  Ferda Emriye Percin,<sup>2</sup>  
 Alev Altinova,<sup>1</sup>  Ayhan Karakoc,<sup>1</sup>  Goksun Ayvaz,<sup>1</sup>  Nuri Cakir<sup>1</sup>

<sup>1</sup>Department of Endocrinology and Metabolism, Gazi University Faculty of Medicine, Ankara, Turkey

<sup>2</sup>Department of Medical Genetics, Gazi University Faculty of Medicine, Ankara, Turkey

## ABSTRACT

We report a 46 XX male syndrome diagnosed after failure of gonadotropin therapy taken for hypogonadotropic hypogonadism due to a pituitary macroadenoma. A 39-year-old man with a non-functioning pituitary macroadenoma was admitted to our clinic due to vision loss and infertility. After pituitary surgery, vision loss improved while infertility still existed. Low testosterone levels without elevated gonadotropins were established suggesting hypogonadotropic hypogonadism due to pituitary adenoma. Gonadotropin treatment was initiated. There was no response to treatment after 12 months. A karyotype analysis was ordered to investigate other causes of infertility. Karyotype analysis showed a 46 XX male syndrome that can explain the failure of gonadotropin therapy. Testosterone therapy was started instead of gonadotropin therapy. 46 XX male syndrome usually presents with hypergonadotropic hypogonadism. However, in our case, it presented with hypogonadotropic hypogonadism due to pituitary mass not responding to gonadotropin therapy. It is important to keep in mind to obtain a genetic analysis of patients whose gonadotropin therapy failed, even if their gonadotropin levels are not elevated.

*Keywords:* Hypogonadism; infertility; 46 XX male.

**Cite this article as:** Yalcin MM, Ozkan C, Akturk M, Percin FE, Altinova A, Karakoc A, et al. 46 XX male syndrome with hypogonadotropic hypogonadism: A case report. *North Clin Istanbul* 2019;6(3):308–311.

Infertility is defined as the inability of achieving pregnancy without contraception in a couple regularly having intercourse for 1 year [1]. It may occur due to male factors (30%), female factors (45%), or both (25%). Male factors can be categorized as sexual disorders, primary testicular defect in sperm production, endocrinopathies that affect spermatogenesis, and defects in sperm transportation. According to Jungwirth et al., 10.1% of infertile males have hypogonadism that can be defined as the inability of the testicles to produce testosterone [2]. Hypogonadism is divided into two categories according to gonadotropin levels: hypergonadotropic hypogonadism (primary hypogonadism) and hypogonadotropic hypogonadism (secondary hypogonadism). Differential diagnosis of hypogonadism is crucial for the treatment of fertility. Gonadotropin therapy could achieve pregnancy in

patients with hypogonadotropic hypogonadism, which is different from hypergonadotropic hypogonadism. It can be hard to diagnose or treat a patient with different causes of hypogonadism.

Here, we report a case with 46 XX male syndrome presenting with hypogonadotropic hypogonadism due to coexisting non-functioning pituitary adenoma.

## CASE REPORT

A 39-year-old man was referred to our clinic with a pituitary mass. He had right-sided vision loss that occurred suddenly. A 45×28×40 mm pituitary adenoma was detected while evaluating vision loss. Hormonal analyses showed hypogonadotropic hypogonadism without any excess or deficient hormone levels as shown in Table 1.



Received: November 26, 2017 Accepted: April 12, 2018 Online: September 05, 2018

Correspondence: Dr. Mehmet M. YALCIN. Dr. Ersin Arslan Egitim ve Arastirma Hastanesi, Sahinbey, Gaziantep Turkey.  
Phone: +90 505 525 25 48 e-mail: yalcin.muhtin@gmail.com

© Copyright 2019 by Istanbul Provincial Directorate of Health - Available online at www.northclinist.com

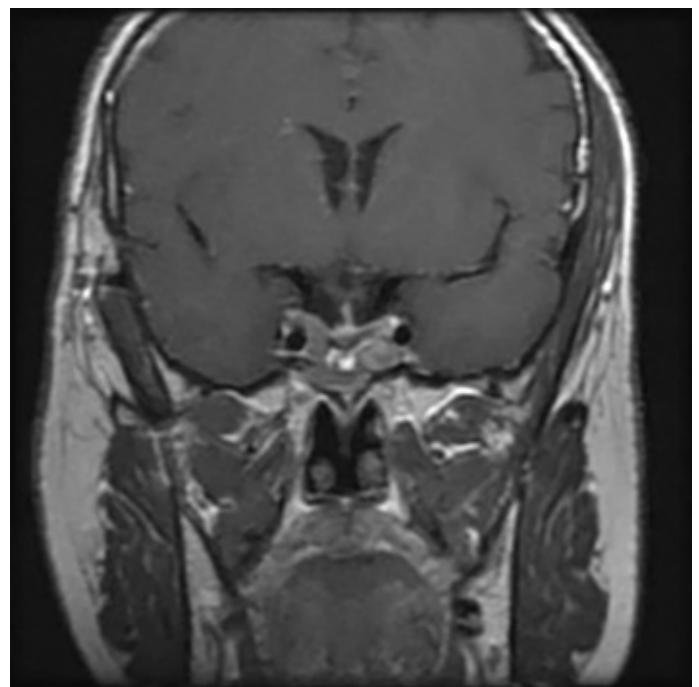
**TABLE 1.** Testosterone, FSH, LH, prolactin, and estradiol levels; testicular volume; and semen analysis before and after treatment

	Before the first operation	Before the second operation	Before gonadotropin treatment	After 1 years of gonadotropin treatment
Total testosterone (ng/dL) (262–1593)	23.8	36.0	32.0	76.0
FSH (mIU/mL) (0.70–11.0)	6.5	4.6	4.1	5.5
LH (mIU/mL) (0.80–7.60)	1.97	1.50	1.71	1.64
Prolactin (mg/mL) (2.50–17.0)	14.0	12.4	7.7	18.7
Estradiol (pg/mL) (11–44)	NA	24	14	<10
Testicular volume	(-)	(-)	R: 1.6 mL R:1.4 mL	L: 1.4 mL L: 1.5 mL
Semen analysis	No sperm	No sperm	No sperm	No sperm

Normal ranges for analyses were given in the paranthesis. FSH: Follicle stimulating hormone; LH: Luteinizing hormone; NA: Not available.

A transcranial pituitary adenectomy was performed. The pathology of the surgical specimen was considered as an adenoma that had no immunostaining for thyroid-stimulating hormone (TSH), adrenocorticotrophic hormone (ACTH), growth hormone (GH), and prolactin. After the operation, his vision loss improved.

When he was readmitted to our clinic, he was suffering from loss of libido, infertility, headaches, and relapsing of vision loss on the right side of the eye that started 4 years after his pituitary operation. He had no child. His height and weight were 161 cm and 71 kg, respectively, with a body mass index of 27.4 kg/m<sup>2</sup>. His physical examination was normal, except for bilateral gynecomastia and small testicles. Hormonal analyses showed hypogonadotropic hypogonadism as shown in Table 1. Magnetic resonance imaging of the pituitary gland revealed a 37×32×28 mm residual pituitary mass. Second pituitary adenectomy was performed, but there was still a residual pituitary mass of 24×25×20 mm after the second operation (Fig. 1). Histopathology of the specimen revealed pituitary adenoma without immunostaining for TSH, ACTH, GH, and prolactin. Although the patient had no headaches and vision problems after the operation, he was still suffering from loss of libido and infertility. According to his laboratory results, hypogonadotropic hypogonadism still existed, and there was no any disturbance of other pituitary hormones (Table 1). Ultrasonography of the testicles revealed that both testicles were small as shown in Table 1. His semen analysis showed no sperm since the patient and his wife desired to have a child. Initially, human chorionic gonadotropin (hCG) (1500 units, 3 days/week) treatment was started.



**FIGURE 1.** Pituitary magnetic resonance imaging after the second operation.

After 3 months, as testicular volume was still too small and there was no improvement on testosterone levels, hCG dose was increased to 3000 units for 3 days/week, and human menopausal gonadotropin (hMG) 75 µg for 3 days/week was added to hCG treatment. Then, hMG treatment was increased up to 150 µg for 3 days/week while he was on hCG (3000 units, 3 days/week). After 12 months, because of no improvement on both testosterone levels, sperm production, and testicular size, a

chromosomal analysis was performed to investigate other causes of infertility. As a result of the analysis, GTG banding procedure was performed on metaphase chromosomes obtained from peripheral blood lymphocytes of the patient. The karyotype 46 XX was observed on 100 metaphases to exclude mosaicism and chimerism. Diagnostic testing of deletions of the sex-determining region Y (SRY), ZFY genes, and AZF region located on the long arm of the Y chromosome was performed by real-time polymerase chain reaction (PCR) amplification. The set of PCR primers that was used in multiplex PCRs for the diagnosis of microdeletion of these regions included: sY14 (SRY), ZFX/ZFY, sY84, sY86, sY127, sY134, sY254, and sY255. Molecular analysis revealed that ZFY and SRY genes were intact, but AZF region was deleted. Therefore, SRY+ 46 XX male sex reversal was diagnosed.

Since no treatment could induce spermatogenesis in 46 XX males, testosterone therapy was started instead of gonadotropin therapy. A genetic consultation and alternative ways of having a child (e.g., adoption) were recommended to the couple. In addition, the couple was advised to have psychological support if they needed it.

## DISCUSSION

We presented an infertile patient with hypogonadotropic hypogonadism due to a pituitary adenoma in whom fertility treatment with hCG and hMG failed. Underlying 46 XX male syndrome was diagnosed after chromosomal analysis.

Hypergonadotropic hypogonadism can be defined as elevated gonadotropin levels in a male with hypogonadism. Testicular diseases should be investigated for the etiology of hypergonadotropic hypogonadism.

Gonadotropin treatment is considered for sperm induction in males with hypogonadotropic hypogonadism. Although hypogonadotropic hypogonadism is the cause of only 2%–3% of male infertility, fertility and sperm production can be achieved with gonadotropin treatment only in this group [3]. Congenital factors, such as Kallmann syndrome and idiopathic hypogonadotropic hypogonadism, or acquired forms, such as hypothalamic-pituitary tumors, granulomatous diseases, empty sella syndrome, obesity, and the use of anabolic steroids, can cause hypogonadotropic hypogonadism. Non-functioning pituitary adenomas may lead to hypogonadotropic hypogonadism, because of the mass effect of the adenoma or complication of pituitary surgery. After removing the adenoma—the underlying cause of hypogonadism—, fer-

tility can be achieved spontaneously in some cases. Fertility can be achieved by gonadotropin treatment (hCG and hMG) in patients with persistent hypogonadism despite surgical treatment. hCG treatment can induce sperm production by increasing intratesticular testosterone levels [3, 4]. hMG can be added to hCG therapy, if adequate sperm production could not be achieved after 3–6 months of therapy with hCG [5–9]. Pregnancy has been shown to be achieved in 40%–53% of patients with gonadotropin replacement therapy in 24–36 months [4, 5]. If there is no improvement in fertility despite using gonadotropin treatment, the clinician should investigate for other diseases that lead to male infertility etiologies.

According to the algorithm for infertile men published by Anawalt et al., a chromosomal analysis is recommended if gonadotropin treatment fails in a man with hypogonadotropic hypogonadism [5]. Actually, genetic analysis is recommended for patients with hypergonadotropic hypogonadism, whereas it is not a routine investigation for patients with hypogonadotropic hypogonadism [5, 10]. The prevalence of chromosomal abnormalities in infertile men has been reported as 3%–19% in different studies [11]. Although Klinefelter syndrome is the most frequent genetic disorder causing infertility, 46 XX male syndrome can be found in 0.3% of infertile men who ordered for chromosomal analysis [12].

Sex reversal syndromes consist of 46 XY females and 46 XX males [13]. 46 XX male syndrome is a rare disorder, and it was first described by De la Chapelle et al. in 1964 [14]. It can be seen in 1 of 20,000–25,000 births [15]. It is characterized by a male phenotype with a 46 XX karyotype. 46 XX male syndrome is divided into the sex-determining region Y (SRY)+ (80%) and SRY– (20%) according to the presence of the SRY region on the X chromosome. SRY– 46 XX males often have genital anomalies and loss of masculinization as they are almost always diagnosed at early childhood [16]. SRY+ 46 XX males often have normal puberty, whereas some of them have cryptorchidism [16]. They are often diagnosed while evaluating for infertility or gynecomastia in early adulthood. They have normal secondary sexual characters, but they do not produce sperm. Elevated gonadotropin levels are often determined while testosterone levels can be low, normal, or even high [16]. None of the infertility treatments induce sperm production.

In our case, FSH level was inappropriately in normal range, whereas LH level was low. Gonadotropin levels cannot be elevated despite low testosterone levels in hypogonadotropic hypogonadism. However, FSH levels,

which were in normal range in our case, could be related with 46 XX male syndrome, because highly elevated FSH levels were reported in case reports with 46 XX male syndrome [17–22]. In addition, FSH levels were almost always higher than other causes affecting the Y chromosome according to the literature [20].

We suggest that if gonadotropin therapy fails to provide a sufficient amount of testosterone level and/or an amount of sperm, which are needed in fertility, in a man with hypogonadotropic hypogonadism, other diseases that cause infertility, such as 46 XX male syndrome, should be investigated by genetic analysis. Early diagnosis for 46 XX male syndrome may be useful to provide early genetic consultation, to prevent using unnecessary painful and expensive gonadotrophin therapy, and to contribute to the early initiation of the adoption process.

We report a case of 46 XX male syndrome with inappropriately normal FSH and low LH levels, in spite of there was too low testosterone levels. He was diagnosed after failure of gonadotropin therapy for hypogonadism with low levels of gonadotropins, because of pituitary adenoma. The presence of pituitary adenoma was a confounding factor and delayed the diagnosis in our case. It is important to keep in mind to obtain a genetic analysis in patients whose gonadotropin therapy failed, even if their gonadotropin levels are not elevated. To the best of our knowledge, this is the first case of 46 XX male syndrome presenting with hypogonadotropic hypogonadism due to pituitary adenoma in adults.

**Informed Consent:** Written informed consent was obtained from the patient for the publication of the case report and the accompanying images.

**Conflict of Interest:** The authors declare that they have no conflict of interest.

**Financial Disclosure:** The authors declared that this study has received no financial support.

**Authorship contributions:** All the authors participated in the clinical follow-up of the patient, F. E. P.; performed the genetic analysis including karyotype analysis and PCR analysis, M. M. Y., M. A. and A. A. wrote the manuscript, M. M. Y. and M. A. edited the manuscript.

## REFERENCES

- Gnoth C, Godehardt E, Frank-Herrmann P, Friol K, Tigges J, Freundl G. Definition and prevalence of subfertility and infertility. *Hum Reprod* 2005;20:1144–7.
- Jungwirth A, Giwercman A, Tournaye H, Diemer T, Kopa Z, Dohle G, et al; European Association of Urology Working Group on Male Infertility. European Association of Urology guidelines on Male Infertility: the 2012 update. *Eur Urol* 2012;62:324–32.
- Roth MY, Page ST, Lin K, Anawalt BD, Matsumoto AM, Snyder CN, et al. Dose-dependent increase in intratesticular testosterone by very low-dose human chorionic gonadotropin in normal men with experimental gonadotropin deficiency. *J Clin Endocrinol Metab* 2010;95:3806–13.
- Coviello AD, Matsumoto AM, Bremner WJ, Herbst KL, Amory JK, Anawalt BD, et al. Low-dose human chorionic gonadotropin maintains intratesticular testosterone in normal men with testosterone-induced gonadotropin suppression. *J Clin Endocrinol Metab* 2005;90:2595–602.
- Anawalt BD. Approach to male infertility and induction of spermatogenesis. *J Clin Endocrinol Metab* 2013;98:3532–42.
- Fraietta R, Zylberstein DS, Esteves SC. Hypogonadotropic hypogonadism revisited. *Clinics (Sao Paulo)* 2013;68 Suppl 1:81–8.
- Zacharin M, Sabin MA, Nair VV, Dabadhghao P. Addition of recombinant follicle-stimulating hormone to human chorionic gonadotropin treatment in adolescents and young adults with hypogonadotropic hypogonadism promotes normal testicular growth and may promote early spermatogenesis. *Fertil Steril* 2012;98:836–42.
- Barrio R, de Luis D, Alonso M, Lamas A, Moreno JC. Induction of puberty with human chorionic gonadotropin and follicle-stimulating hormone in adolescent males with hypogonadotropic hypogonadism. *Fertil Steril* 1999;71:244–8.
- Oldereid NB, Abyholm T, Tanbo TG. Spermatogenesis and fertility outcome in male hypogonadotropic hypogonadism. *Hum Fertil (Camb)* 2010;13:83–9.
- Layman LC. Hypogonadotropic hypogonadism. *Endocrinol Metab Clin North Am* 2007;36:283–96.
- Martin RH. Cytogenetic determinants of male fertility. *Hum Reprod Update* 2008;14:379–90.
- Hofherr SE, Wiktor AE, Kipp BR, Dawson DB, Van Dyke DL. Clinical diagnostic testing for the cytogenetic and molecular causes of male infertility: the Mayo Clinic experience. *J Assist Reprod Genet* 2011;28:1091–8.
- Wang T, Liu JH, Yang J, Chen J, Ye ZQ. 46, XX male sex reversal syndrome: a case report and review of the genetic basis. *Andrologia* 2009;41:59–62.
- de la Chapelle A. The etiology of maleness in XX men. *Hum Genet* 1981;58:105–16.
- Rajender S, Rajani V, Gupta NJ, Chakravarty B, Singh L, Thangaraj K. SRY-negative 46,XX male with normal genitals, complete masculinization and infertility. *Mol Hum Reprod* 2006;12:341–6.
- Frühmesser A, Kotzot D. Chromosomal variants in klinefelter syndrome. *Sex Dev* 2011;5:109–23.
- Gunes S, Asci R, Okten G, Atac F, Onat OE, Ogur G, et al. Two males with SRY-positive 46,XX testicular disorder of sex development. *Syst Biol Reprod Med* 2013;59:42–7.
- Agrawala RK, Choudhury AK, Mohanty BK, Baliarsinha AK. All males do not have 46 xy karyotype: A rare case report. *Indian J Endocrinol Metab* 2013;17:S271–3.
- Anık A, Çatlı G, Abacı A, Böber E. 46,XX male disorder of sexual development: a case report. *J Clin Res Pediatr Endocrinol* 2013;5:258–60.
- Chiang HS, Wu YN, Wu CC, Hwang JL. Cytogenic and molecular analyses of 46,XX male syndrome with clinical comparison to other groups with testicular azoospermia of genetic origin. *J Formos Med Assoc* 2013;112:72–8.
- Gao X, Chen G, Huang J, Bai Q, Zhao N, Shao M, et al. Clinical, cytogenetic, and molecular analysis with 46,XX male sex reversal syndrome: case reports. *J Assist Reprod Genet* 2013;30:431–5.
- Jain M, V V, Chaudhary I, Halder A. The Sertoli Cell Only Syndrome and Glaucoma in a Sex - Determining Region Y (SRY) Positive XX Infertile Male. *J Clin Diagn Res* 2013;7:1457–9.