

Bilateral Radicular Cyst in Mandible: An Unusual Case Report

Fareed Ahmed Bava¹, Dilshad Umar², Bahija Bahseer³, Kusai Baroudi³

Contributors:

¹Senior Lecturer, Department of Oral Surgery, Century Dental College, Kasaragod, Kerala, India; ²Senior Lecturer, Department of Orthodontics, Al Farabi College of Dentistry, Riyadh, Saudi Arabia; ³Faculty, Department of Pedodontics, Al Farabi College of Dentistry, Riyadh, Saudi Arabia.

Correspondence:

Dr. Umar D. Department of Orthodontics, Al Farabi College of Dentistry, Riyadh, Saudi Arabia. Phone: +(0)-9886611166. Email: dilshadu@yahoo.com

How to cite the article:

Bava FA, Umar D, Bahseer B, Baroudi K. Bilateral Radicular Cyst in Mandible: An Unusual Case Report. J Int Oral Health 2015;7(2):61-63.

Abstract:

A radicular cyst is one of the furthestmost everyday odontogenic cysts of the anterior maxilla, not regularly comprehended in youth. They are found mostly at the apices of the tooth (periapical cyst), lateral surface of the roots (lateral radicular cyst) and remains in the jaw after removal of the offending tooth (residual cyst). The radicular cyst has been catalogued as an inflammatory cyst, as an outcome to pulpal necrosis succeeding caries, with a linked periapical inflammatory reaction. They advance sluggishly and asymptomatic lest infected. Because of this they can extent to big dimensions. Many times it is perplexing to segregate radicular cysts from the obligatory pre-existing chronic periapical periodontitis lesions radiographically. Here, we present a rare case with bilateral radicular cyst in relation to first molar of the mandible in a 19-year-old. Orthopantomograph showed a large unilocular radiolucency with a well-defined border in the periapical region of the first molar on the left side extending from the root of the second premolar to the mesial root of the second molar. Correspondingly another well-defined unilocular radiolucency with a well-defined border was seen on the right side of the mandible. Several treatment possibilities are presented for a radicular cyst such as surgical endodontic treatment, extraction of the transgressing tooth, enucleation with primary closure, and marsupialization trailed by enucleation. The patient management comprised surgical enucleation of cystic sac followed by rehabilitation of the same area.

Key Words: Bilateral mandibular radicular cysts, rehabilitation, surgical enucleation

Introduction

Odontogenic and non-odontogenic cysts of the jaws can exhibit a biologically aggressive course and sometimes difficult to diagnose. Radicular cysts are utmost collective inflammatory cysts developing from the epithelial deposits in the periodontal space or following pulpal necrosis. The lesion is not clinically detectable when it is small but most often is discovered as

incidental finding on radiographic examination. Though radicular cysts are one of the most common lesions of the mouths, manifold radicular lesions are rather exceptional. Their incidence is highest in third and fourth decade of lifespan with male dominance. Anatomically the periapical cysts transpire in all tooth bearing positions of the jaws, however, are more repeated in the maxillary than the mandibular region.¹

Therefore, we present a rare case with bilateral radicular cyst in relation to first molar of the mandible.

Case Report

A 19-year-old male patient related to the Department of Oral and Maxillofacial Surgery with a chief complaint of mild swelling in the left region of the mandible for the past 6 months. Patient had consulted a dentist for the same complaint 3 months back and was on antibiotic coverage for 5 days. There was no change in the size of the swelling. Subsequently, the patient had been recalled for extraction of the aberrant tooth. Conversely, he did not endure the treatment.

The patient had no other associated symptoms with the swelling. On examination, extra-orally there was a mild swelling on the left side of his face, the skin over the swelling appeared normal. On palpation, the swelling was hard, mild tender with the expansion of buccal cortical plate and egg shell crackling on palpation. Intraorally a well-defined swelling was present on the buccal vestibule in relation to the left mandibular first molar root stumps of 2 cm × 2 cm size (Figure 1).

A definite radiolucency was seen in the intraoral periapical radiographic view of the left first molar root stumps. The orthopantomograph showed a large unilocular radiolucency with a well-defined border in the periapical region of the first molar on the left side extending from the root of the second premolar to the mesial root of the second molar (Figure 2).

Similarly, another well-defined unilocular radiolucency with a well-defined border was seen on the right side of the mandible in relation to the root stump of first molar of 1 cm × 1 cm size.

Aspiration revealed straw colored fluid, which was sent for cytological examination. On the basis of clinical and radiographical findings and fine-needle aspiration cytology report, the provisional diagnosis of bilateral mandibular radicular cysts was made.

Enucleation of the bilateral cyst with offending root stump extraction was planned and performed under general anesthesia.

The mandibular left second molar, second premolar and right second premolar were subjected to endodontic treatment prior to cyst enucleation.

Crevicular incision was placed from distal aspect of first premolar to the distal aspect of the second molar with releasing incision on either side and raising a trapezoidal mucoperiosteal flap followed by extraction of the root stump and then cyst were enucleated bilaterally. Apicoectomy of the endodontically treated teeth (both second premolars and left second molar's mesial root) were performed before the closure of the flaps. The tissue specimens were sent for histopathological examination.

The surgically excised lesion of the left side was about 2 cm × 2 cm in size and of right side was 1 cm × 1 cm in size (Figure 3).

Histopathological examination of the surgical specimen showed non-keratinized stratified squamous epithelial lining with inflammatory cell infiltration, reporting as radicular cysts.

Discussion

Radicular cyst commonly occurs in maxillary anterior region in between 30th and 50th year of age frequently in men (Figure 4). They may be a slow growing bony swelling and also asymptomatic, and this lesion can be determined unpredictably on periapical radiographs as in our case.² One of the main clinical feature in the conclusion of a radicular cyst is the existence of a tooth with non-vital pulp, and sometime a sinus may lead from the cystic cavity.³

These cyst can occur in periapical section of any teeth, at any period but infrequently seen linked with primary dentition.⁴ Few studies in UK and South African population have seen shown that radicular cyst occur more regularly concerning the third and fifth decades of lifespan, more commonly in males than females and more frequently seen in the anterior maxilla. In our case, it was in mandible and also bilateral.

The pathogenesis of radicular cyst has been portrayed as encompassing of three definite phases; phase of Initiation, cyst formation and the enlargement.⁵ The preliminary swelling of these radicular cyst are usually bony rigid, but as they proliferate in magnitude, the covering bone may develop extremely slender notwithstanding sub-periosteal bone deposition. Decisively, with advanced bone resorption, the enlargement exhibit "springiness" or egg shell crackling. The concomitant teeth are permanently non-vital and could express discoloration. Associated root typically display no root resorption; there may be even resorption of root apices. While cyst are integral, cyst spaces could be occupied with brown or

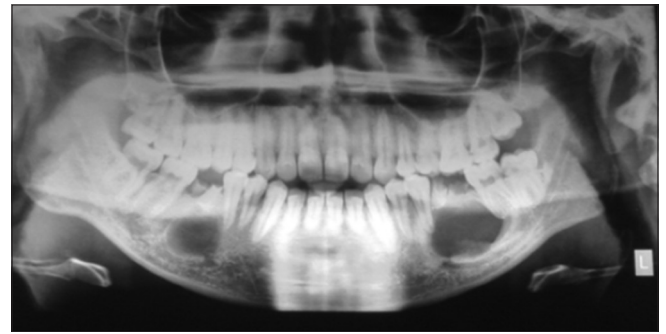


Figure 1: Pre-operative orthopantomograph is showing periapical unilocular radiolucencies in the mandibular right and left first molar regions.

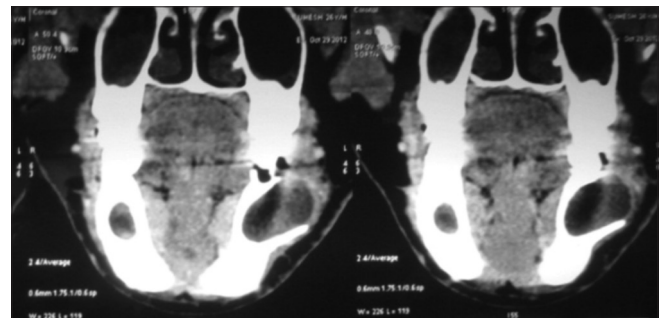


Figure 2: Pre-operative computed tomography scan is showing periapical unilocular radiolucencies and expansion of buccal cortical plate on left side.

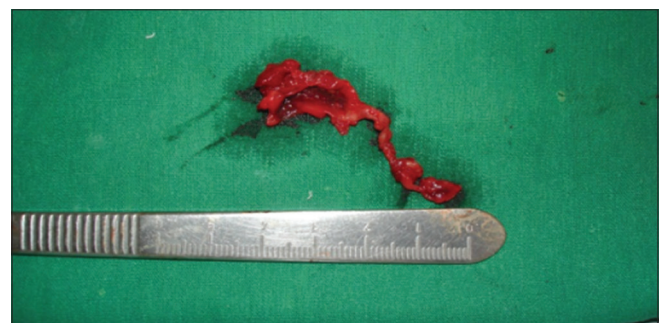

Figure 3: Specimen of enucleated cyst.

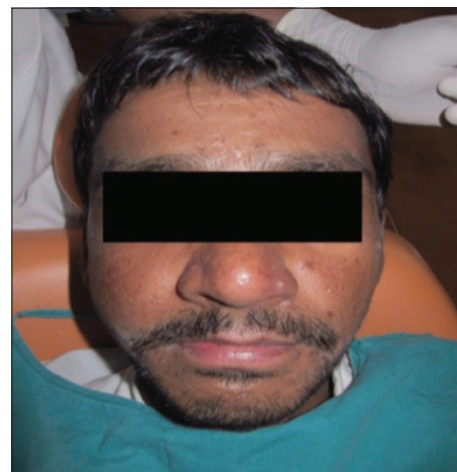

Figure 4: Pre-operative extra oral photograph.

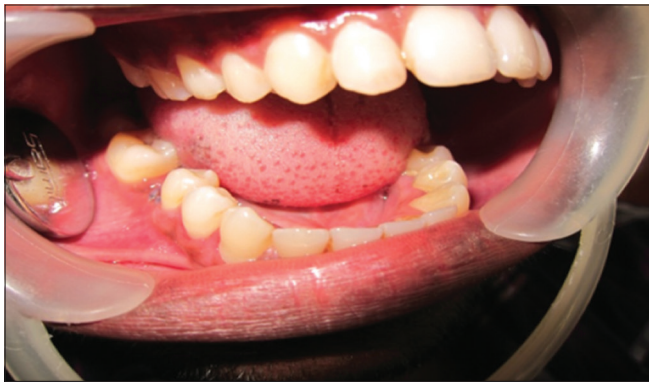

Figure 5: Post-operative intraoral picture after 1-month.

straw colored fluid while the cyst fluid may have shimmering gold appearance when light pass through it.⁶

Cyst is assumed to be produced by multiplying of the epithelial cell rest of malassez in inflamed periradicular tissues. Its magnitude seldom surpasses 1cm and is habitually realized in patient between 30 and 50 years old with greater prevalence in the maxillary anterior region.⁷

Nearly all radicular cysts are lined completely or in the fragment by non-keratinized stratified squamous epithelium. The lining may be, intermittent in quantity and vary in depth from one to 50 cell strata. The preponderance is between six and 20 cell stratum thick. The epithelial linings could be thriving and arcading with a severe connected inflammatory progression or is sluggish and moderately methodical with a certain mark of differentiation. The inflammatory cell penetrates in the thriving epithelial linings comprising largely of polymorphonuclear leukocytes. Whereas adjoining fibrous capsule is penetrated principally by enduring inflammatory cells.⁸

It's quite unusual to see this lesion in a bilaterally symmetric fashion, as was seen in our case.

Several treatment modalities are available for radicular cyst such as surgical endodontic management, extraction of the aberrant tooth, enucleation with initial resolution, and marsupialization shadowed by enucleation. In this case, surgical enucleation was desired and was implemented on both side.^{9,10} Crevicular incision was placed from distal aspect of first premolar to the distal aspect of the second molar with releasing incision on either side and raising a trapezoidal

mucoperiosteal flap, followed by extraction of the root stump and then cyst were enucleated bilaterally. Apicoectomy of the endodontically treated teeth (both second premolars and left second molar's mesial root) were performed before the closure of the flaps (Figure 5).

Conclusion

Radicular cyst is an everyday disorder unearthed in the oral cavity which is asymptomatic when small and diagnosed incidentally on radiographic examination. This report highlights on the occurrence of symmetrical bilateral radicular cyst, which is rare of its entity and shows the importance of radiographic examination prior to the removal of teeth. Moreover, coarse radicular cyst can lead to major rate of morbidity.

References

1. Joshi NS, Sujan SG, Rachappa MM. An unusual case report of bilateral mandibular radicular cysts. *Contemp Clin Dent* 2011;2(1):59-62.
2. Holla VA, Chatra L, Shenai P, Rao PK, Veena K, Prabhu RV. Bilateral inflammatory cysts of the jaw: Report of an unusual case. *Imaging Sci Dent* 2012;42(2):105-9.
3. Gaynor WN. Bilateral radicular cysts of mandibular deciduous teeth: A case report. *N Z Dent J* 2012;108(3):106-9.
4. Brave D, Madhusudan AS, Ramesh G, Brave VR. Radicular cyst of anterior maxilla. *Int J Dent Clin* 2010;2(4):49-51.
5. Jansson L, Ehnevid H, Lindskog S, Blomlöf L. Development of periapical lesions. *Swed Dent J* 1993;17:85-93.
6. Lustmann J, Shear M. Radicular cysts arising from deciduous teeth. Review of the literature and report of 23 cases. *Int J Oral Surg* 1985;14(2):153-61.
7. Asokan GS, Jeelani S, Parthiban J, Prabhu Shankar K, Prakash CA, Shankar K. Keracystic odontogenic tumor – A case report. *Int J Dent Case Rep* 2012;2(1):353-9.
8. Shamsudeen SM, Selvakumar T, Uma Magesh DP, Srinivasa Prasad T, Nalin Kumar S. Radicular cyst – A case report with an overview on pathogenesis. *Indian J Multidiscip Dent* 2012;3(4):45-51.
9. Gonzalez SM, Spalding PM, Payne JB, Giannini PJ. A dentigerous cyst associated with bilaterally impacted mandibular canines in a girl: A case report. *J Med Case Rep* 2011;5:230.
10. Mihailova H, Nikolov VL, Slavkov SV. Diagnostic imaging dentigerous cyst of mandible. *J IMAB - Annual Proceeding (Scientific Papers)*, 2008.