



Contents lists available at ScienceDirect

## Journal of Ginseng Research

journal homepage: <http://www.ginsengres.org>

## Research Article

## The effect of Korean Red Ginseng on full-thickness skin wound healing in rats

Ki-Soo Park, Dae-Hwan Park\*

Department of Plastic and Reconstructive Surgery, College of Medicine, Daegu Catholic University, Daegu, Republic of Korea

## ARTICLE INFO

## Article history:

Received 4 February 2017

Received in Revised form

5 December 2017

Accepted 7 December 2017

Available online 10 January 2018

## Keywords:

Korean Red Ginseng

*Panax ginseng*

Skin regeneration

Wound healing

## ABSTRACT

**Background:** *Panax ginseng* is regarded as one of the best compounds for promoting health, and it has been used traditionally as a medicinal herb. Recently, Korean Red Ginseng (RG) has been shown to protect skin from aging and wrinkling; it can also relieve atopic dermatitis and allergy symptoms. This study aimed to evaluate RG's effects on the regeneration of the full-thickness skin wounds in rat.

**Methods:** Full-thickness skin wounds were generated in rats, and then RG was administered either orally or topically. The wound-healing effects of RG were investigated by assessing wound size, mRNA expression patterns of genes related to wound healing, histological staining, and measurements of lipid, moisture, and elasticity in skin tissues.

**Results:** The wound size was smaller, and tissue regeneration rate was faster in the RG-treated group than that in the control group on days 15 and 20 after initiating treatment. On postoperative day 20, skin lipid and moisture content had increased significantly in the RG-treated group. Significant increases in the gene expression levels of transforming growth factor- $\beta$ 1 and vascular endothelial growth factor were found in the RG group during the early stages of wound healing. Matrix metalloproteinase-1 and matrix metalloproteinase-9 showed significant increases in gene expression levels on day 20.

**Conclusion:** The results suggested that RG may promote healing of full-thickness skin wounds in rats. They also provided basic insights into the effects of RG on skin regeneration, supporting its use as a dressing material for wound treatment and its development as a functional food.

© 2018 The Korean Society of Ginseng, Published by Elsevier Korea LLC. This is an open access article under the CC BY-NC-ND license (<http://creativecommons.org/licenses/by-nc-nd/4.0/>).

## 1. Introduction

*Panax ginseng* is regarded as the one of the best compounds for promoting health, and it has been used traditionally as a medicinal herb in Korea, Japan, China, and other countries for thousands of years [1]. Recent studies have shown that Korean Red Ginseng (RG) protects skin from aging and wrinkling, and it can also relieve atopic dermatitis and allergy symptoms. In an animal model, locally administered ginseng radix rubra stimulated the reversal of diabetes and aging in rats [2–4].

Wound healing involves complex biological mechanisms, and it is controlled by growth factors, transforming growth factor (TGF)- $\beta$  and vascular endothelial growth factor (VEGF), and inflammatory cells [5,6]. Skin cells, such as keratinocytes, endothelial cells, and fibroblasts, are considered migratory cells. Fibroblasts play important roles in the formation of granulation tissue and in the secretion

of growth factors, such as TGF- $\beta$  and insulin-like growth factor. Endothelial cells play a significant part in angiogenesis, such as VEGF and platelet-derived growth factor. Secreted growth factors promote wound healing and angiogenesis, including neovascularization [7].

Matrix metalloproteinases (MMPs) degrade and modify the extracellular matrix (ECM) [8]. Stemming from fibroblasts, MMP-1 begins the degradation of fibrillar collagen molecules, and together with MMP-9, MMP-1 plays an important role in wound healing through a list of actions, including causing inflammation, ECM remodeling, angiogenesis, and epithelial regeneration [9]. Skin wound healing can be categorized into three phases, as follows: the inflammatory reaction, reepithelialization and granulation tissue formation, and tissue remodeling [10].

For wound healing, the correlations between the cells and tissues that are included in the three phases are important [11].

\* Corresponding author. Department of Plastic and Reconstructive Surgery, College of Medicine, Daegu Catholic University, 3056-6 Daemyung 4-dong Namgu, Daegu, 42472, Republic of Korea.

E-mail address: [dhpark@cu.ac.kr](mailto:dhpark@cu.ac.kr) (D.-H. Park).

Monocytes reach wound sites in 2 days and differentiate into macrophages to perform phagocytic functions; to secrete TGF- $\alpha$ , TGF- $\beta$ , and b-fibroblast growth factor; and to manage the wound-healing process [12]. Therefore, we assessed the gene expression patterns of TGF- $\alpha$ , TGF- $\beta$ , VEGF, b-fibroblast growth factor, and MMPs during the wound-healing process in animals after RG administration. In addition, the healing process of full-thickness wounds was studied using histology. Examination of wound size and molecular and histological analyses were used to confirm RG's wound-healing effects. Lipid and moisture in the skin were calculated with a lipid, moisture, and elasticity meter, which is often used in studies of functional cosmetics. Cosmetics use has a similar goal to wound healing in that cosmetics aim to rehabilitate damaged skin; therefore, we used this measuring device to confirm that RG has a wound-healing effect. Therefore, we evaluated RG's effects on the regeneration of lipid and moisture content in the skin.

In the present study, a measuring device was used to confirm that RG has a wound-healing effect. In animal experiments, RG not only promoted wound healing but also reduced the appearance of wrinkles and aging of the skin. The aim of this study was to contribute to the development of a new dressing material for wound treatment and functional food by providing basic information on the effect of RG on lipid and moisture content in the skin and on skin regeneration.

## 2. Materials and methods

### 2.1. Preparation of materials

Korean RG powder (RGp) and RG extract (RGe) were made by the Korea Ginseng Corporation (Seoul, Korea) from roots of a 6-year-old RG plant, *P. ginseng* Meyer, grown in the Republic of Korea. Korean RG was manufactured by steaming fresh ginseng at 90–100°C for 3 h and drying it at 50–80°C. Powdered RG capsules and placebo capsules from the Korea Ginseng Corporation were used for this study. The RGe was prepared from RG that was extracted at 85–90°C, three times for 8 h, in circulating hot water. The water content of the pooled extract was 36% of its total weight. RGp was prepared from ground RG (500 mg of RG/capsule). The RG content was measured using HPLC. Of a total weight of 16.75 mg/g (moisture content: 4.66%), it was found to contain 5.61 mg/g of major ginsenoside-Rb1, 2.03 mg/g of major ginsenoside-Rb2, 2.20 mg/g of major ginsenoside-Rc, 0.39 mg/g of major ginsenoside-Rd, 1.88 mg/g of major ginsenoside-Re, 0.89 mg/g of major ginsenoside-Rf, 3.06 mg/g of major ginsenoside-Rg1, 0.15 mg/g of major ginsenoside-Rg2s, 0.17 mg/g of major ginsenoside-Rg3s, and 0.08 mg/g of major ginsenoside-Rg3r. Placebo and RGp capsules were suspended in purified water and administered orally to rats.

### 2.2. Experimental animals

Experimental animals were allowed to adapt to the laboratory conditions for 7 days before experimentation. Male 6-week-old Sprague–Dawley rats, weighing 200–250 g, were housed individually in polycarbonate cages maintained at  $23 \pm 3^\circ\text{C}$  in  $50 \pm 10\%$  humidity with a 12-h/12-h light/dark cycle. The rats had free access to food and water. All surgical and experimental procedures used in the present study were conformed to the US National Institutes of Health guidelines for the care and use of laboratory animals (2012-0220-CU-AEC-6-Y). All surgical and experimental procedures used in the present study were approved by the Institutional Animal Care and Use Committee at our medical center and were conformed to the US National Institutes of Health guidelines for the care and use of laboratory animals.

### 2.3. Animal model of full-thickness skin wound and sample intake methods

#### 2.3.1. Oral administration of RGp

To investigate the effects of Korean RGp on skin regeneration, the rats were orally administered 2.5 g/kg of RGp for 20 days [13].

The rats ( $n = 20$ ) were anesthetized via an intramuscular injection of Zoletil 50 (50 mg/kg; Virbac, France) and Rompun (10 mg/kg; Bayer, Germany). To test *in vivo* toxicity of these drugs, we checked the weight of the animals after injections, and they did not change the weight significantly. Following this, the rats' dorsal hairs were removed with NiCLEAN (Seoul, Korea), and penetrating wounds of 2 cm in diameter were made using a 20-mm biopsy punch and tissue scissors. For each experiment, ginseng powder dissolved in purified water was administered to the rats orally.

#### 2.3.2. Topical application of RGe

After shaving the skin over the dorsal area, two round, full-thickness skin wounds (biopsy punch diameter, 2 cm) were made on each rat's back to the level of the panniculus carnosus. The rats ( $n = 20$ ) were anesthetized as described previously. RGe was applied to one of the wounds, and the other wound was covered with Vaseline as a control. The wounds were dressed every 3 days after the wounds were created. Five rats were sacrificed on each day at 5, 10, 15, and 20 days after the procedure to obtain skin tissue. Dressing materials were placed on the wounds, which were then wrapped with sterilized Tegaderm (3M, USA). Movement of the dressing material was minimized by applying Peha-haft (Paul Hartmann AG, Germany). Nylon 4-0 was used to stitch the Peha-haft to the front and back of each rat's torso.

### 2.4. Gross assessment and wound size measurement

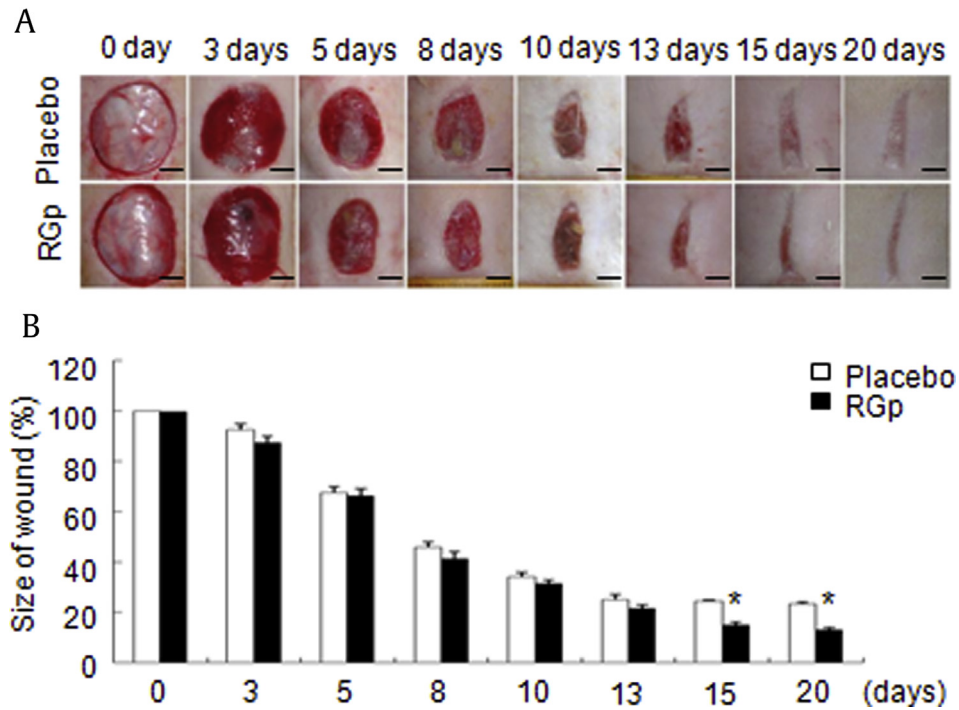
Anesthetized rats were administered ginseng on days 5, 10, 15, and 20 postwounding, and the wounds were photographed using a digital camera and a high-power camera to record the degree of healing. Transparent overhead projector film was used to calculate the wound area. After tracing each full-thickness skin wound onto sterilized overhead projector film, the film was scanned, and the wound size was measured using an image analysis program (the National Institute of Health (NIH) image analysis system was used with Bio-Optics 4, USA). The area of the created wound was measured at different timepoints postwounding, and the wound percentage area was calculated by comparing changes in wound size relative to the original wound.

### 2.5. Lipid, moisture, and elasticity measurements

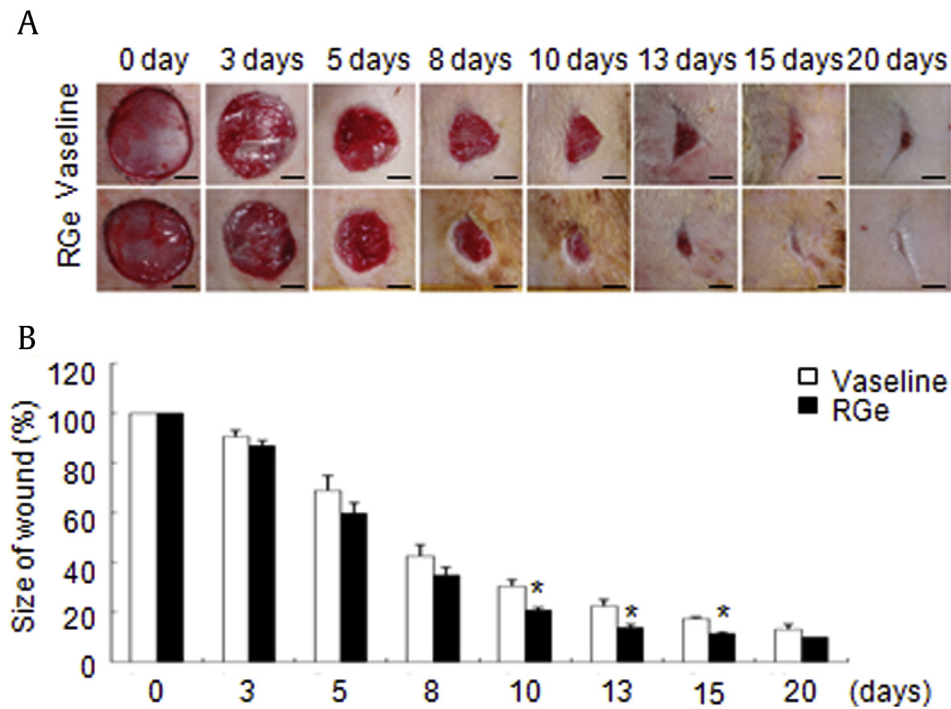
Skin lipid and moisture content, as well as resilience, were measured using a Lipid, Moisture and Elasticity meter (TripleSense, Moritex Co, Japan) in both the RG-treated group and the untreated group at locations containing normal skin and wounded skin. Dressing room conditions were maintained at a constant temperature and humidity for accurate measurements of skin condition. Measurements were performed after removal of the dressing wipe from the upper and normal skin using sterile phosphate-buffered saline, 30 min after anesthesia administration.

### 2.6. Histological analysis

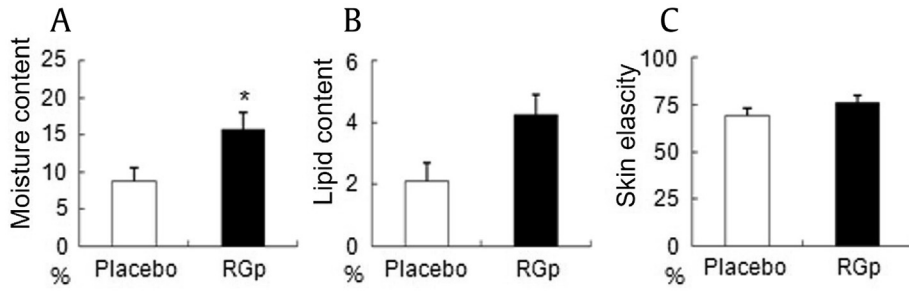
For the histological evaluation of wound healing, wounded tissues were obtained on days 5, 10, 15, and 20 postwounding and fixed in 10% formalin at room temperature for at least 24 h. After fixation, sections perpendicular to the anterior–posterior axis of the wound were dehydrated in graded ethanol, cleaned in xylene,



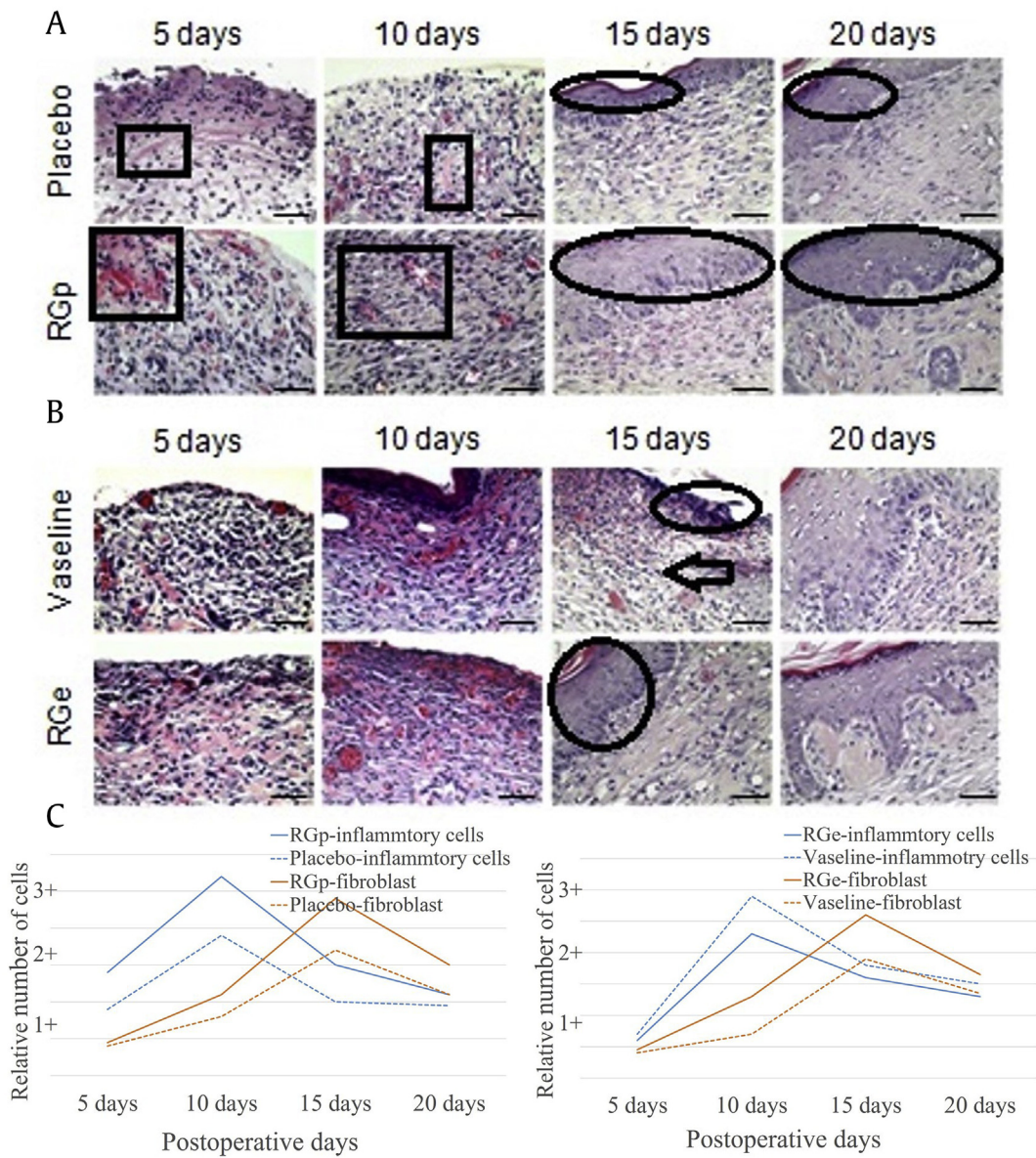
**Fig. 1.** Time course of gross wound healing after the oral administration of red ginseng (RG) powder. (A) Differences in dermal wound sizes between the placebo and RG groups. Scale bar: 5 mm. (B) Time course of wound-healing percentage after the oral administration of RG powder. These results were based on morphometric analyses of wound tissues from the placebo and RG groups. Each bar represents the mean  $\pm$  standard error of the mean (SEM). \* $p < 0.05$ : significantly different from the control group. RGp, red ginseng powder.



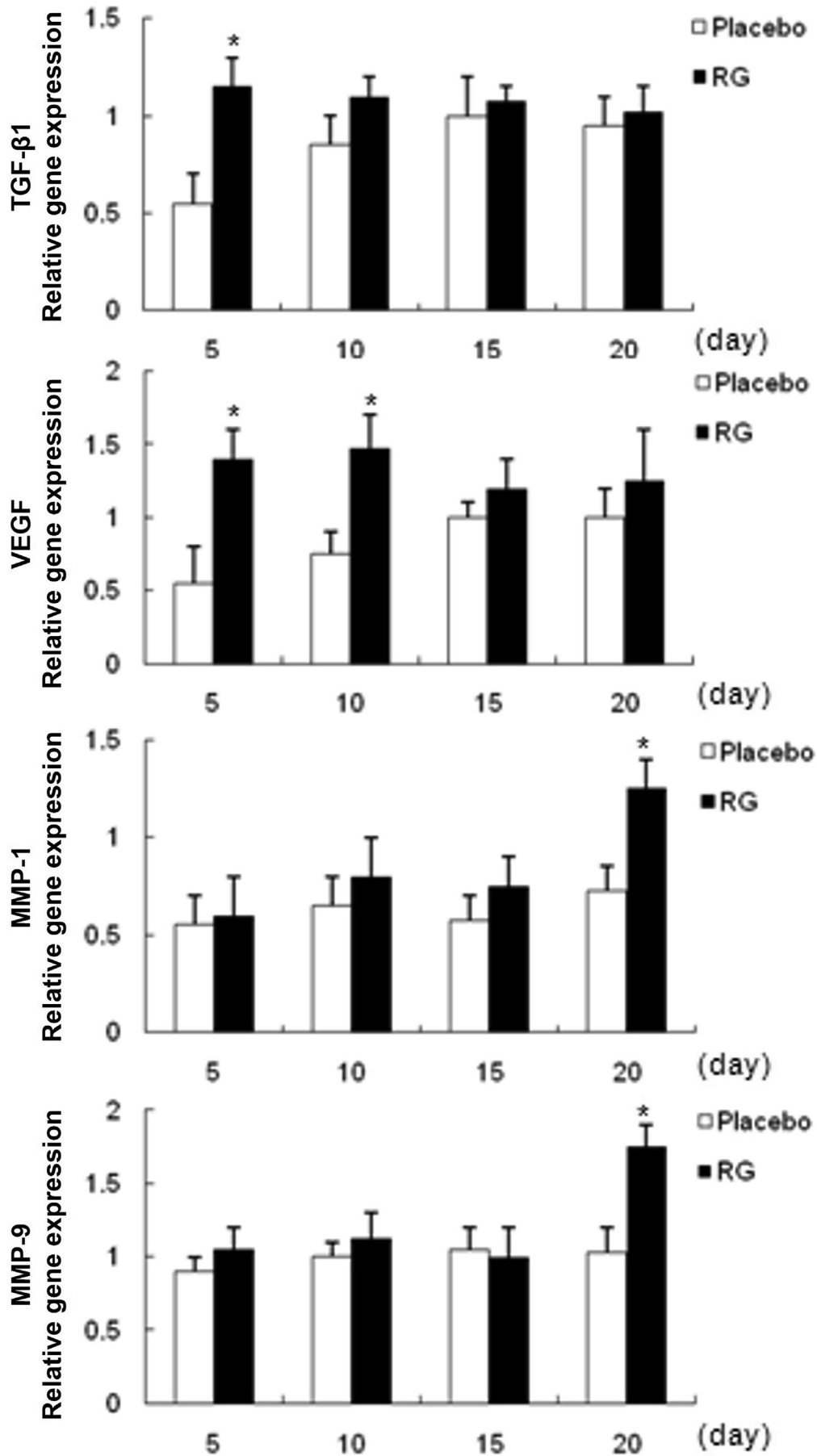
**Fig. 2.** Time course of gross wound healing after the dermal application of ginseng extract. (A) Differences in dermal wound sizes between the Vaseline and red ginseng (RG) groups. Scale bar: 5 mm. (B) Time course of wound-healing percentage after the topical application of RG extract. These results were based on morphometric analysis of wound tissues from the Vaseline and RG groups. Each bar represents the mean  $\pm$  standard error of the mean (SEM). \* $p < 0.05$ : significantly different from the control group. RGe, red ginseng extract.



**Fig. 3.** Changes in lipid and moisture skin content and skin elasticity in normal skin after the oral administration of red ginseng (RG). A lipid, moisture, and elasticity meter was used for the measurements. (A) Moisture content. (B) Lipid content. (C) Elasticity. Each bar represents the mean  $\pm$  standard error of the mean (SEM). \* $p < 0.05$ : significantly different from the control group. RGp, red ginseng powder.



**Fig. 4.** Differences between the control and red ginseng (RG) groups in inflammatory cell recruitment as determined by hematoxylin and eosin (H&E) staining ( $\times 400$ ). (A) Oral administration of RG powder (RGp) or placebo. (B) Topical application of RG extract (RGe) or Vaseline. Scale bar: 50  $\mu$ m. Inflammatory cells in the RG group were increased from days 5–10 (square), and collagen deposits did from days 15–20 (circle) compared with those in the control wound tissue. On day 15 after surgery, the number of inflammatory cells was higher in the Vaseline group than that in the RG group (arrow). Fibroblast activity was higher in the RG group than that in the Vaseline group (circle). (C) Graphs of the relative number of inflammatory cells and fibroblasts.



and embedded in paraffin. The paraffin-embedded sections (6  $\mu$ m in thickness) were then deparaffinized with xylene, dehydrated in decreasing concentrations of ethanol, and stained with hematoxylin and eosin (H&E). Healing was assessed using the following four measures: numbers of neutrophils, numbers of fibroblasts, neovascularization, and degree of epithelialization.

### 2.7. Biochemical study by real-time polymerase chain reaction

The gene expression patterns of TGF- $\beta$ 1, VEGF, MMP-1, and MMP-9 were assessed using real-time polymerase chain reaction (PCR). Total RNA was isolated from tissue using TRIzol (Takara Bio Inc., Japan), and 1  $\mu$ g of total RNA per sample was reverse-transcribed using a Maxime RT premixed kit (iNtRON Biotechnology, Daejeon, Korea) according to the manufacturer's instruction. cDNA synthesis was performed at 45°C for 60 min, followed by reverse transcriptase inactivation at 95°C for 5 min. Real-time PCR was performed with a MJ Mini Thermal Cycler real-time system (Brio-Rad, USA) using SYBR Premix Ex Taq (Takara Bio Inc.). The reaction was performed before PCR amplification, and the mixture was incubated at 95°C for 10 min. The amplification step consisted of 45 cycles of denaturation (10 s at 95°C), annealing (5 s at the primer-appropriate temperature), and extension (10 s at 72°C), with fluorescence detection at 72°C after each cycle. Relative quantification of each gene was assessed by normalizing against glyceraldehyde 3-phosphate dehydrogenase expression levels [14].

### 2.8. Statistical analysis

All experimental results are expressed as the means  $\pm$  standard error of the mean. SPSS for Windows 11.0 (SPSS, Chicago, USA) was used, along with unpaired *t* tests and one-way analysis of variance for statistical verification. The significance level was set at  $p < 0.05$ .

## 3. Results

The wound size was smaller, and the tissue regeneration rate was faster in the RG-treated group than that in the control group on days 15 and 20 after initiating treatment. On postoperative day 20, skin lipid and moisture content had increased significantly in the RG-treated group.

### 3.1. Gross findings and measurements of wound size

Visual assessment of wound healing indicated that the wound tissue was in good condition in both the orally administered RGp group and the topically applied RGe group; no inflammation or other problems appeared during the healing period. In addition, a large amount of exudate and small amount of bleeding were observed 1 week after surgery; both gradually decreased.

On postoperative day 3, tissue granulation began to increase in the placebo group (control group) relative to the orally administered RGp group, and scar formation was reduced toward the end of RGp administration in comparison with that in the control group. During early wound healing, no significant differences were observed between the two groups. However, wound healing seemed to accelerate at later stages in the RGp group. The mean wound sizes on days 15 and 20 in the RG-treated group were much

smaller than those in the placebo group. In the measurements of the percentage of wound healing, RG administration resulted in a statistically significant improvement by the final stages of healing (Fig. 1).

On postoperative day 3, granulation tissue had increased in the topically applied RGe group, and such tissue appeared in the Vaseline group on postoperative day 5. In addition, scar formation in the RGe group was reduced in comparison with that in the control group. At the early stages in wound healing, no significant differences were found between the two groups. However, RGe had a statistically significant effect on wound-healing percentage at the later healing stages. The wound size percentages were smaller on days 10, 13, and 15 in the RGe group than those in the Vaseline group (Fig. 2).

### 3.2. Lipid, moisture, and elasticity measurement results

Alterations in skin lipid and moisture content and elasticity were measured using a Lipid, Moisture and Elasticity meter after the oral administration of RGp and topical application of RGe. In the orally administered RGp group, at 20 days after skin wounding, there was significantly increased moisture and lipid content in the skin compared with that in the placebo group (Figs. 3A, 3B). About twofold greater lipid and moisture content in the skin was observed after RGp treatment; however, skin elasticity decreased slightly (Fig. 3C) [15]. In the topically applied RGe group, at 20 days post skin wounding, neither lipid and moisture content nor elasticity significantly differed relative to those of the Vaseline group (data not shown).

### 3.3. Histological study

Histological examination showed that the oral administration of RGp resulted in rapid angiogenesis. However, on postoperative day 10 in the orally administered RGp group, a vigorous inflammatory response in the skin was found compared with that in the placebo group. On the exterior of the skin, inflammatory cells and fibroblasts were observed. Epithelialization was more rapid in the RGp group 15 days after surgery, and all wounds were healed by day 20 (Fig. 4A). The Vaseline group had greater initial inflammation and less neovascularization than those in the topically applied RGe group. There were a greater number of inflammatory cells on the exterior of the skin in the Vaseline group than those in the RGe group on postoperative day 10. By 15 days after surgery, the Vaseline group showed little wound epithelialization, whereas in the RGe group, the wounds were completely healed. In addition, on postoperative day 15, the Vaseline group showed remaining inflammatory cells and few fibroblasts, whereas the RGe group had highly active fibroblasts and a low number of inflammatory cells (Fig. 4B). The number of inflammatory cells was highest on postoperative day 10, and the number of fibroblasts was highest on postoperative day 15. The inflammatory reaction is more vigorous in the RGp and Vaseline groups. Increased numbers of fibroblasts were observed in the RGp and RGe groups (Fig. 4C). In both the RGp and RGe groups, active neovascularization, collagen accumulation, and epithelialization were greater than those in the placebo group, leading to a shortened regeneration time.

**Fig. 5.** TGF- $\beta$ 1, VEGF, MMP-1, and MMP-9 gene expressions in rats orally administered red ginseng. To measure gene expression, wounded tissues were collected on postoperative days 5, 10, 15, and 20. Gene expression was measured using real-time PCR. GAPDH was used as a control. Each bar represents the mean  $\pm$  standard error of the mean (SEM). \* $p < 0.05$ ; significantly different from the control group. GAPDH, glyceraldehyde 3-phosphate dehydrogenase; MMP, matrix metalloproteinase; PCR, polymerase chain reaction; RG, red ginseng; TGF, transforming growth factor; VEGF, vascular endothelial growth factor.

### 3.4. Biochemical findings by real-time PCR

To investigate the effects of RG on gene expression patterns, we performed real-time PCR. After the oral administration of RGp, increased expression of TGF- $\beta$ 1 and VEGF was commonly observed during the early stages of wound healing. TGF- $\beta$ 1 and VEGF gene expression significantly increased in the RG group compared with that in the placebo group on days 5 and 10 after skin excision. On days 15 and 20 after skin wounding, no differences in TGF- $\beta$ 1 or VEGF gene expression were observed among the groups. MMP-1 and MMP-9 gene expression did not significantly differ on postoperative days 5 or 10. However, 20 days after skin wounding, the MMP-1 and MMP-9 genes showed significantly increased expression in the RG group compared with that in the control group (Fig. 5).

After the topical application of RGe, TGF- $\beta$ 1 gene expression was significantly higher than that in the Vaseline group on postoperative day 5. However, TGF- $\beta$ 1 gene expression did not significantly differ between the groups on days 10, 15, or 20 postwounding. In addition, MMP-1 and MMP-9 gene expressions did not significantly differ between the groups on days 5, 10, or 15 postwounding. However, MMP-1 and MMP-9 gene expressions were significantly higher in the RGe group than those in the Vaseline group on postoperative day 20 (Fig. 6).

## 4. Discussion

*P. ginseng* and RG are widely used health supplements. Ginseng has been proven effective in preventing skin aging due to exposure to ultraviolet light, and it has been reported to prevent wrinkles and improve atopic dermatitis, chronic skin damage, and diabetes [16–18]. Therefore, in this study, the effects of RG on the regeneration of skin lipid and moisture content were investigated, with the purpose of providing evidence concerning its use as a dressing material for wound treatment and its development as a functional food.

Wound healing is an important process in which bleeding from a wound is stopped, damaged tissues are regenerated, moisture is vaporized around the wound, and a functional defense membrane is formed [10]. In this study, to investigate microchanges in the wound sites, histological analysis was conducted using H&E-stained tissue sections. Rats treated with RG showed faster rates of reepithelialization and new blood vessel formation. During the process of wound healing, collagen deposition was also observed, which increased over time. RG has been confirmed to accelerate reepithelialization of the epidermis, stimulate increased migration of various cells, and enhance neovascularization and collagen deposition. H&E staining revealed that cells involved in the wound-healing process appeared faster in the RG groups than those in the control groups. Therefore, based on visual inspection, the RG groups showed faster recovery.

Previous research has shown that ginseng is beneficial for human fibroblast synthesis [15]. We conducted experiments with rats, confirming that ginseng increased lipid and moisture content in skin. In the orally administered RGp group, lipid and moisture content was higher than that in the control group, and the differences were statistically significant. In addition, by comparing wounded skin tissue with normal skin tissue, we could conclude that lipid and moisture content and skin elasticity in wounded tissue were comparable with those in normal skin on postoperative day 20. In contrast, there were no significant differences in skin lipid and moisture content or resilience in the topically applied RGe group compared with those in the Vaseline group. The rapid effects that RG treatment had on wound healing are thought to have increased the moisture ratio.

In this study, the wound-healing rates in the RG groups progressed faster than those in the control groups as there was less neutrophil infiltration. In the RG groups, the wound areas shrank, and the rate of keratinocyte migration appeared to be higher than that in the control groups at all timepoints tested. In addition, we found a faster rate of keratinocyte migration and subsequent reepithelialization in the RG groups than that in the control groups. Kim et al [19] reported that saponin from RG enhanced the proliferation of epidermal cells by upregulating Bcl-2 (B-cell lymphoma 2) expression in keratinocytes. Therefore, it is suggested that RG increases epidermal cell proliferation and keratinocyte migration (Fig. 7).

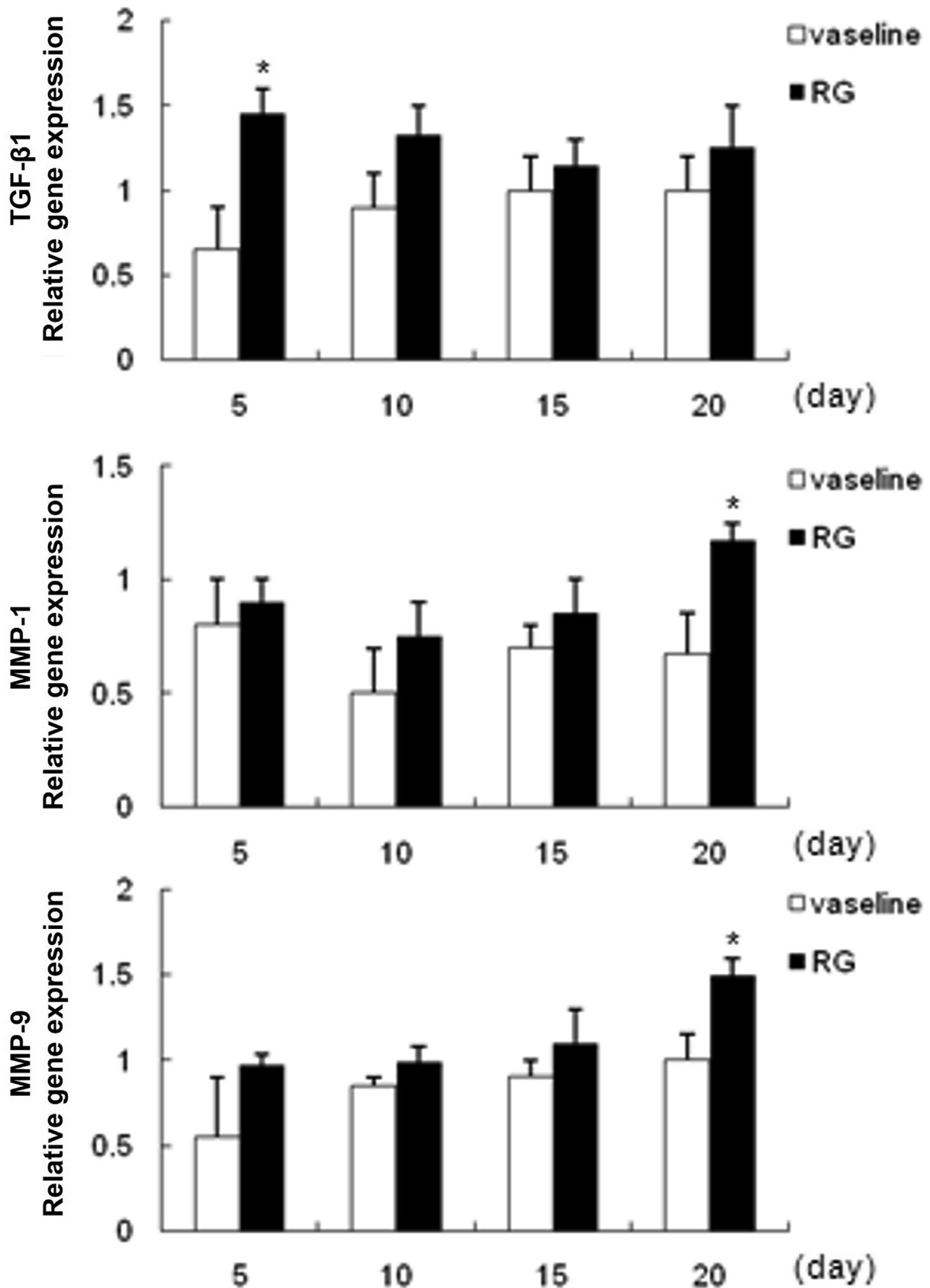
We measured TGF- $\beta$ , VEGF, MMP-1, and MMP-9 levels in wound tissue using real-time PCR. The early migration of fibroblasts to a wound is extremely important in wound healing as these cells synthesize collagen, which becomes the foundation for tissue rehabilitation [20]. Collagen synthesis is directly related to fibroblast presence and markedly increases 2–3 days after wounding, continuing to gradually increase for 2 weeks. In this period, TGF- $\beta$  has the most influential effect [21]. In the present study, TGF- $\beta$  expression was higher on the fifth postoperative day in the RG group than that in the control group, and the difference was statistically significant. Kanzaki et al [20] reported that saponin from Korean RG activates and increases the synthesis of TGF- $\beta$ 1, while it modifies the TGF- $\beta$  receptor in fibroblasts, and saponin facilitates the TGF- $\beta$  pathway in the mechanism of wound healing [20]. Accordingly, it is assumed that RG increases the synthesis of TGF- $\beta$ 1, which accelerates the fibroblast functions in making fibronectin in skin regeneration. Therefore, RG facilitates skin wound healing in the early stages of injury (Fig. 7).

Previous studies have shown that Vaseline can help with wound healing [22,23]. Despite being in the same control group, the Vaseline group had healing properties such as Petroleum jelly, petrolatum and white petrolatum, which resulted in different gene expression times. In a future work, we will experiment with the same control group.

Angiogenesis has an essential role in providing oxygen and nutrients for wound healing. It occurs in response to the movement of nutrients to endothelial cells and capillaries [24,25]. In this study, VEGF expression was higher on the 5<sup>th</sup> and 10<sup>th</sup> postoperative days in the RG groups than that in the control groups, and the difference was statistically significant. Kimura et al [27] revealed that ginsenoside-Rb1 isolated from ginseng saponins stimulated VEGF production due to increased Hypoxia-inducible factors-1 $\alpha$  and interleukin-1 $\beta$  in keratinocytes and macrophage, respectively. In addition, the saponin component of RG promotes the phosphorylation of protein kinase B, also known as Akt and extracellular-regulated kinase and activation of the Akt and extracellular-regulated kinase signaling pathways. This activation promotes the proliferation and migration of fibroblasts and increases the protein expression of collagen (Fig. 7) [26]. In addition, Kimura found that Korean RGe downregulated the expression of miR (microRNA)-377, thereby enhancing the expression of the angiogenic protein VEGF. Therefore, it is assumed that RG promotes angiogenesis by stimulating VEGF in skin wounds [27].

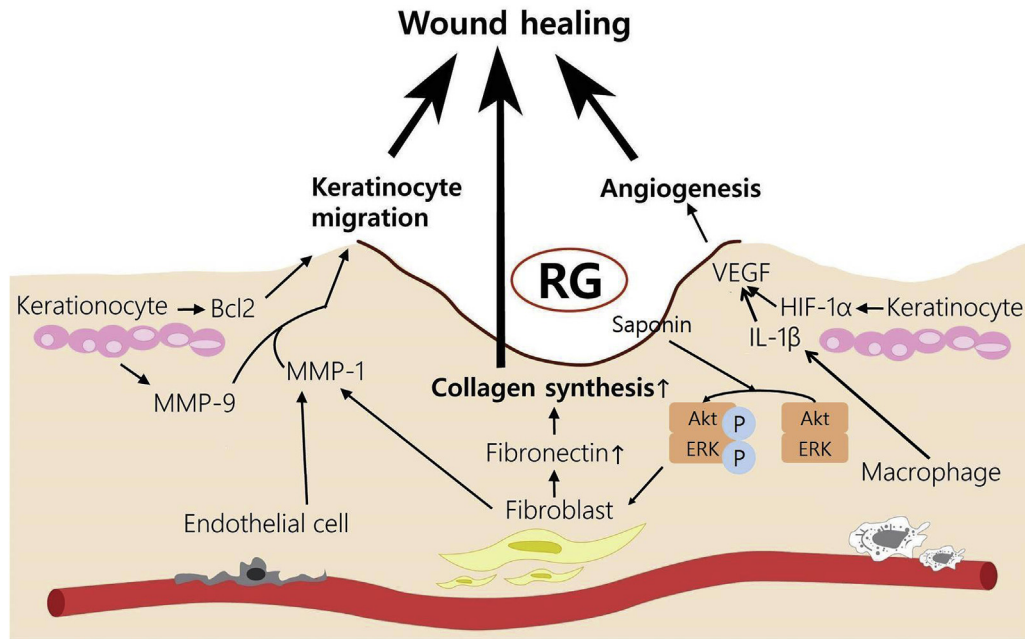
As discussed previously, the growth factor TGF- $\beta$  is secreted by fibroblasts. In pathohistological examination, we observed more fibroblasts in the RG group than in the placebo group. In addition, on the 10<sup>th</sup> day of the experiment, we observed many new blood vessels containing numerous red blood cells.

MMPs are zinc-dependent endopeptidases capable of degrading all types of ECM proteins [28]. MMP-1 breaks down collagen types 1, 2, 3, 10, and 13. MMP-9 breaks down all types of collagen, except types 5 and 11. MMP-1, similar to MMP-2 and MMP-9, causes partial denaturation [29–32]. From 20 days postwounding, a tissue remodeling phase begins; in this phase, a state of equilibrium is reached between collagen synthesis and destruction. Collagen



**Fig. 6.** Transforming growth factor (TGF)- $\beta$ 1, matrix metalloproteinase (MMP)-1, and MMP-9 gene expression in rats after the topical application of red ginseng (RG). To measure gene expression, wounded tissues were collected on postoperative days 5, 10, 15, and 20. Gene expression was measured using real-time polymerase chain reaction (PCR). Glyceraldehyde 3-phosphate dehydrogenase (GAPDH) was used as a comparative control. Each bar represents the mean  $\pm$  standard error of the mean (SEM). \* $p < 0.05$ : significantly different from the control group.





**Fig. 7.** Proposed mechanisms of the effects of red ginseng (RG) on promoting wound healing. RG facilitates matrix metalloproteinase (MMP)-1 and MMP-9 secretion produced by fibroblast/endothelial cells and keratinocytes, respectively. MMP-1 and MMP-9 could allow keratinocytes to migrate better to enhance the remodeling of the extracellular matrix (ECM). RG increases epidermal cells by upregulating Bcl-2 expression in keratinocytes; it also increases synthesis of transforming growth factor (TGF)- $\beta$ 1, which accelerates the functions of fibroblasts in making fibronectin for skin regeneration. RG stimulates vascular endothelial growth factor (VEGF) production due to increased Hypoxia-inducible factors (HIF)-1 $\alpha$  and interleukin-1 $\beta$  in keratinocytes and macrophages, respectively. In addition, the saponin component of RG promotes phosphorylation of protein kinase B (PKB), also known as Akt and extracellular-regulated kinase (ERK) and activation of the Akt and ERK signaling pathways. This activation promotes proliferation and migration of fibroblasts, thereby increasing the protein expression of collagen. Bcl, B-cell lymphoma; IL, interleukin.

destruction is completed by MMPs. In the early stages of wound healing, the actions of TGF- $\beta$  and VEGF are important, whereas in the later stages, the actions of MMPs become more significant. David [32] revealed that MMP-1 produced by fibroblast and endothelial cells and MMP-9 secreted by keratinocytes, prevalent in later stages of wound healing, could allow keratinocytes to migrate better to enhance remodeling of the ECM (Fig. 7).

In this study, MMP expression was higher on the 20<sup>th</sup> post-operative day in the RG group than that in the control group, and the difference was statistically significant. This could suggest that Korean RG facilitates MMP-1 and MMP-9 secretion, which detaches keratinocytes from the basement membranes and improves epithelization in the later stage of wound healing (Fig. 7).

In summary, the results of the present study indicate that RG accelerates the wound-healing process. Based on visual inspection, wound size was statistically significantly reduced after treatment with RG, and the wound-healing process was rapid. As determined by genetic analysis, wound healing was accelerated after treatment with RG because TGF- $\beta$  and VEGF expression increased during early stages of healing, whereas MMP-1 and MMP-9 expression increased during the later stages (Fig. 7).

In this study, we tried to demonstrate the effects of RG on wound healing with data on TGF- $\beta$ 1, VEGF, MMP-1, and MMP-9 gene expressions in rats. However, for a more accurate result, the amount of actual protein expression should be determined, rather than gene expression as determined by immunohistochemistry. Therefore, in future experiments, Western blot analysis should be carried out, and additional immunohistochemistry markers should be considered.

Our experiment was done with groups consisting of 20 rats, but it cannot represent all. In future work, we will need experiment with more diverse treatment groups. Moreover, in this study, we overlooked the primer sequences as we designed the study without

primer sequence data. Consequently, the results of this experiment may be slightly less accurate [33].

After RG treatment, lipid and moisture content in wounded skin showed little difference compared with that in normal tissue. Therefore, this study provided basic insights into the effects of RG on skin regeneration, supporting its use as a dressing material for wound treatment and its development as a functional food.

#### Conflicts of interest

There was no conflict of interest.

#### Acknowledgments

This work was supported by a 2012 grant from the Korean Society of Ginseng.

#### References

- [1] Yamamoto M. Current status ginseng research in Japan. In: Ha H, Yamamoto M, Joo CN, Kuo SC, editors. Life Medical Research Institute. Proceedings of the International Symposium on Ginseng Research. Taichung: China Medical College; 1988. p. 12–26.
- [2] Morisaki N, Watanabe S, Tezuka M, Zenibayashi M, Shiina R, Koyama N, Kanzaki T, Saito Y. Mechanism of angiogenic effects of saponin from ginseng radix rubra in human umbilical vein endothelial cells. *Br J Pharmacol* 1995;115:1188–93.
- [3] Bae SH, Lee HS, Kim MR, Kim SY, Kim JM, Suh HJ. Changes of ginsenoside content by mushroom mycelial fermentation in red ginseng extract. *J Ginseng Res* 2011;35:235–42.
- [4] Kim YS, Cho IH, Jeong MJ, Jeong SJ, Nah SY, Cho YS, Kim SH, Go A, Kim SE, Kang SS, et al. Therapeutic effect of total ginseng saponin on skin wound healing. *J Ginseng Res* 2011;35:360–7.
- [5] Stephens P, Thomas DW. The cellular proliferative phase of the wound repair process. *J Wound Care* 2002;11:253–61.
- [6] Werner S, Krieg T, Smola H. Keratinocyte-fibroblast interactions in wound healing. *J Invest Dermatol* 2007;127:998–1008.

- [7] Mansbridge JN, Liu K, Pinney RE, Patch R, Ratcliffe A, Naughton GK. Growth factors secreted by fibroblasts: role in healing diabetic foot ulcers. *Diabetes Obes Metab* 1999;1(5):265–79.
- [8] Krishnaswamy VR, Mintz D, Sagi I. Matrix metalloproteinases: the sculptors of chronic cutaneous wounds. *Biochim Biophys Acta* 2017. S0167–4889(17) 30208–30212.
- [9] Page-McCaw A, Ewald AJ, Werb Z. Matrix metalloproteinases and the regulation of tissue remodelling. *Nat Rev Mol Cell Biol* 2007;8:221–33.
- [10] Clark RA. Biology of dermal wound repair. *Dermatol Clin* 1993;11:647–66.
- [11] Toriseva M, Kähäri V. Proteinases in cutaneous wound healing. *Cell Mol Life Sci* 2009;66:203–24.
- [12] Eming SA, Krieg T, Davidson JM. Inflammation in wound repair: molecular and cellular mechanisms. *J Invest Dermatol* 2007;127:514–25.
- [13] Kim HY, Nam WS, Kim SH, Jang HR, Lee MK, Kim TW, Lee SK. Modulatory effects of Korean Red ginseng extract (*Panax ginseng* C.A. Meyer) on cytochrome P450 after oral administration to mice for 14 days. *J Life Sci* 2012;22(8):991–8.
- [14] Pham QL, Jang HJ, Kim KB. Anti-wrinkle effect of fermented black ginseng on human fibroblasts. *Int J Mol Med* 2017;39(3):681–6.
- [15] Song KC, Chang TS, Lee H, Kim J, Park JH, Hwang GS. Processed *Panax ginseng*, sun ginseng increases type I collagen by regulating MMP-1 and TIMP-1 expression in human dermal fibroblasts. *J Ginseng Res* 2012;36:61–7.
- [16] Kim K, Kim HY. Korean Red ginseng stimulates insulin release from isolated rat pancreatic islets. *J Ethnopharmacol* 2008;120:190–5.
- [17] Vuksan V, Sung M, Sievenpiper JL, Stavro PM, Jenkins AL, Di Buono M, Lee K, Leiter LA, Nam KY, Arnason JT. Korean Red ginseng (*Panax ginseng*) improves glucose and insulin regulation in well-controlled, type 2 diabetes: results of a randomized, double-blind, placebo-controlled study of efficacy and safety. *Nutr Metab Cardiovasc Dis* 2008;18:46–56.
- [18] Lee HJ, Kim JS, Song MS, Seo HS, Moon C, Kim JC, Jo SK, Jang JS, Kim SH. Photoprotective effect of red ginseng against ultraviolet radiation-induced chronic skin damage in the hairless mouse. *Phytother Res* 2009;23:399–403.
- [19] Kim YG, Sumiyoshi M, Sakanaka M, Kimura Y. Effects of ginseng saponins isolated from red ginseng on ultraviolet B-induced skin aging in hairless mice. *Eur J Pharmacol* 2009;602:148–56.
- [20] Kanzaki T, Morisaki N, Shiina R, Saito Y. Role of transforming growth factor- $\beta$  pathway in the mechanism of wound healing by saponin from ginseng radix rubra. *Br J Pharmacol* 1998;125:255–62.
- [21] Roberts AB, Heine UI, Flanders KC, Sporn MB. Transforming growth factor- $\beta$ . *Ann N Y Acad Sci* 1990;580:225–32.
- [22] Livak KJ, Schmittgen TD. Analysis of relative gene expression data using real-time quantitative PCR and the 2(-delta delta C(T)) method. *Methods* 2001;25(4):402–8.
- [23] Schaffer G. The effect of Vaseline on wound healing. *Acta Derm Venereol* 1948;28(1):27–34.
- [24] Bates DO, Harper SJ. Regulation of vascular permeability by vascular endothelial growth factors. *Vascul Pharmacol* 2002;39:225–37.
- [25] Tonnesen MG, Feng X, Clark RA. Angiogenesis in wound healing. *J Invest Dermatol Symp Proc* 2000;5:40–6.
- [26] Lu Y, Jingwei X, Na X, Zhanyou W. *Panax notoginseng* saponins promote wound repair of anterior cruciate ligament through phosphorylation of PI3K, AKT and ERK. *Int J Chin Exp Pathol* 2015;8(1):441–9.
- [27] Kimura Y, Sumiyoshi M, Kawahira K, Sakanaka M. Effects of ginseng saponins isolated from red ginseng roots on burn wound healing in mice. *Br J Pharmacol* 2006;148:860–70.
- [28] Van Lint P, Libert C. Chemokine and cytokine processing by matrix metalloproteinases and its effect on leukocyte migration and inflammation. *J Leukoc Biol* 2007;82:1375–81.
- [29] McCawley LJ, Matrisian LM. Matrix metalloproteinases: they're not just for matrix anymore! *Curr Opin Cell Biol* 2001;13:534–40.
- [30] Cho S, Won CH, Lee DH, Lee MJ, Lee S, So SH, Lee SK, Koo BS, Kim NM, Chung JH. Red ginseng root extract mixed with *Torilus fructus* and *Corni fructus* improves facial wrinkles and increases type I procollagen synthesis in human skin: a randomized, double-blind, placebo-controlled study. *J Med Food* 2009;12:1252–9.
- [31] Kang TH, Park HM, Kim YB, Kim H, Kim N, Do JH, Kang C, Cho Y, Kim SY. Effects of red ginseng extract on UVB irradiation-induced skin aging in hairless mice. *J Ethnopharmacol* 2009;123:446–51.
- [32] David GA, Edward BJ. The role of matrix metalloproteinases in wound healing. *J Am Podiatr Med Assoc* 2002;92:12–8.
- [33] Lun FMF, Jin YY, Sun H, Leung TY, Lau TK, Chiu RWK, Lo YMD. Primer sequence disclosure: a clarification of the MIQE guidelines. *Clin Chem* 2011;57:6.