



Vertebral Body Anterior Translation, a Novel Technique for Delayed Myelopathy Due to Osteoporotic Spine Fractures

Jung Soo Lee, MD, Dong Ki Ahn, MD, Won Shick Shin, MD, Kyung Jun Cho, MD,
Young Rok Ko, MD, Il Chan Whang, MD

Department of Orthopedic Surgery, Seoul Sacred Heart General Hospital, Seoul, Korea

Background: Osteoporotic vertebral compression fractures (OVCFs) are often associated with delayed myelopathy. Surgical treatment of delayed myelopathy following an OVCF comprises spinal canal decompression and stable fixation of the vertebral column with an acceptable sagittal alignment. However, such surgical methods are not usually feasible because of medical comorbidities and osteoporosis. We devised a novel, simple technique to decompress the spinal canal and reconstruct the middle column by translating the fractured vertebral body anteriorly through a posterior approach and verified the validity of the new technique.

Methods: We conducted a single-center, retrospective study. Patients who underwent vertebral body anterior translation (VBaT) between 2014 and 2017 due to delayed myelopathy after OVCFs were included. Through a posterior approach, discs between the fractured vertebra and the adjacent vertebrae were released. The fractured vertebra was translated anteriorly with pedicle screws and rods to realign the middle column. Radiological and functional improvement was analyzed.

Results: There were 12 consecutive patients. The mean age was 70.3 ± 9.4 years. There were 8 female and 4 male patients. Follow-up period was 35.9 ± 13.1 months. Nine patients had pedicle screw augmentation with polymethyl methacrylate. The mean number of fusion segments was 3.4 (range, 2–4). There were 3 types of spinal canal invasion. Five patients had vertebral body vacuum clefts with posterior wall fractures. Five patients had vertebral body angulation with endplate protrusion. Two patients had 3 column fractures. In radiological analysis, the regional kyphotic angle was $35.1^\circ \pm 9.1^\circ$ preoperatively and improved to $8.8^\circ \pm 6.8^\circ$ postoperatively and $9.8^\circ \pm 6.1^\circ$ at the final follow-up ($p < 0.001$). The anterior vertebral body height ratio was $27.6\% \pm 7.0\%$ preoperatively and improved to $80.5\% \pm 13.7\%$ postoperatively and $83.7\% \pm 12.5\%$ at the final follow-up ($p < 0.001$). The spinal canal invasion ratio was $52.6\% \pm 9.1\%$ preoperatively and improved to $25.2\% \pm 10.4\%$ postoperatively ($p < 0.001$). Neurological deficit was improved in all patients by 1–3 grades according to Nurick's grading system.

Conclusions: In delayed myelopathy following an OVCF, although the posterior cortex invades the spinal canal, it is usually already in the union state. Therefore, it can bear compression force as a middle column if realigned to be in line with the adjoining vertebrae. VBaT demonstrated satisfactory reduction of kyphosis and maintenance of stability until the last follow-up.

Keywords: *Vertebral body anterior translation, Delayed myelopathy, Osteoporotic vertebral compression fracture*

Received February 6, 2020; Accepted March 17, 2020

Correspondence to: Dong Ki Ahn, MD

Department of Orthopedic Surgery, Seoul Sacred Heart General Hospital,
180 Wangsan-ro, Dongdaemun-gu, Seoul 02559, Korea

Tel: +82-2-966-1616, Fax: +82-2-967-2394

E-mail: adk0208@hanmail.net

In osteoporotic vertebral compression fractures (OVCFs), acute myelopathy develops very rarely due to a preexisting condition such as ossification of the ligamentum flavum.¹⁾ Delayed myelopathy (DM), however, does not occur infrequently.²⁻⁴⁾ It is more common in the elderly population. OVCFs are no longer considered a benign entity because they are often associated with secondary collapse and

pseudarthrosis that eventually result in DM.⁵⁾ However, there has been no agreement on the optimal type and strategy for surgical treatment of DM following an OVCF. It is usually treated by anterior decompression with anterior fixation or anterior decompression with posterior fixation. However, anterior fixation is not feasible due to surgical invasiveness and difficulty in fixation in patients with osteoporosis.⁶⁻⁸⁾ Posterior fixation is often not pragmatic due to its extensiveness (dual incision and long instrumentation).⁹⁾ In the case of DM following an OVCF, the middle column, which is extruded to the spinal canal, is already in the union state. We devised a novel method to decompress the spinal canal and at the same time reconstruct the middle column of the spine with the patient's own posterior wall by pushing it anteriorly with pedicle screws. We named it as vertebral body anterior translation (VBaT). The degree of radiological and neurological improvement was analyzed to assess the validity of this method.

METHODS

We conducted this study in compliance with the principles of the declaration of Helsinki. The protocol of this study was reviewed and approved by the Public Institutional Review Board (IRB No. P01-202006-21-002). Informed consent was waived.

Materials

Twelve consecutive patients who underwent vertebral body translation through a posterior approach from 2014

to 2017 were included in this study. Of the total 12 patients, those who were followed up for more than 2 years were included in the final radiological and functional analysis. Those who were lost before postoperative 2 years were included only in the initial and immediate postoperative radiological analysis. Fractures below L2, the cauda equina level, were excluded. Demographic data, the pattern of spinal canal invasion, fracture level, number of instrumented segments, and T score in dual-energy X-ray absorptiometry (DEXA) were reviewed. The lowest score among the T scores of more than 2 consecutive vertebrae was taken as a bone mineral density score. As radiological parameters, the preoperative, postoperative, and final regional kyphotic angle (RKA), anterior vertebral height ratio (AVHr), and spinal canal invasion ratio (SCIr) were measured. The RKA was defined as the angle between the superior endplate of the upper vertebra and the inferior endplate of the lower vertebra (Fig. 1). The AVHr was defined as the ratio of the anterior vertebral height of the fractured vertebra to the average value of the anterior vertebral height of the adjacent upper and lower vertebrae (Fig. 1). If there was a previous fracture at the adjacent vertebrae, the ratio of the anterior height of the fractured vertebra to the anterior height of the unfractured adjacent vertebra was measured. The SCIr was defined as the ratio of 2-dimensional spinal canal invasion to the normal spinal canal length in the anteroposterior axis (Fig. 1). The RKA and AVHr were measured on the simple standing radiographs and the SCIr was assessed on T2 sagittal magnetic resonance images (MRIs). All measurements were done with picture archiving communication system (PACS; INFINTT, Seoul, Korea). The neurological functional status was assessed with Nurick's grading system¹⁰⁾ (Table 1).

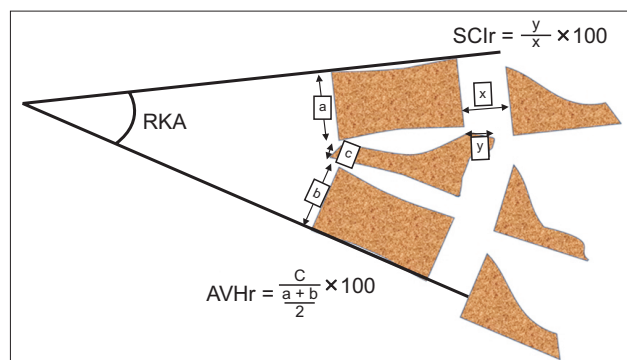


Fig. 1. The regional kyphotic angle (RKA) was defined as the angle between the superior endplate of the upper vertebra and the inferior endplate of the lower vertebra. The anterior vertebral height ratio (AVHr) was defined as the ratio of the anterior vertebral height of the fractured vertebra to the average value of the anterior vertebral height of the adjacent upper and lower vertebrae. The spinal canal invasion ratio (SCIr) was defined as the ratio of 2-dimensional spinal canal invasion to the normal spinal canal length in the anteroposterior axis.

Table 1. Nurick Grade

Grade	Neurological sign
0	Signs or symptoms of root involvement without evidence of spinal cord disease
1	Signs of spinal cord disease but no difficulty in walking
2	Slight difficulty in walking, which does not prevent full-time employment
3	Difficulty in walking, which prevents full-time employment or the ability to do all housework but is not so severe as to require someone else's help for walking
4	Able to walk only with someone else's help or with the aid of a frame
5	Chairbound or bedridden

Operation Methods

A conventional midline approach was used. Pedicle screws were inserted at 1 or 2 upper and lower vertebrae. Screws were augmented with polymethyl methacrylate (PMMA; Biomet, Plateau de Lautagne, France) if the insertion torque was not enough. Polyaxial fenestrated screws that have 4 fenestrations at the distal one-third of the screw shaft were used (Medyssey, Seoul, Korea). The vertebral body vacuum cleft was filled with PMMA through fenestrations of screws. Laminectomy was done at the compression site. The disc between the fractured vertebra and the adjacent upper or lower vertebra or both were released according to the pattern of spinal canal invasion. While assembling both side rods, the fractured vertebra was pushed anteriorly using the difference of the screw head position (Fig. 2). Anterior translation of the retropulsed posterior wall was assessed by direct palpation of its sinking down beneath the posterior wall of the adjacent vertebral body. Interbody bone graft was done if there was a large gap between the adjacent 2 vertebrae after VBaT. Bone graft was done with auto-local bone and allogeneic bone on the

posterolateral side.

Statistical Analysis

A paired *t*-test was used to compare differences between preoperative and postoperative and postoperative and final radiological parameters. The preoperative and postoperative neurological status was compared using the Wilcoxon signed-rank test. IBM SPSS ver. 21 (IBM Corp., Armonk, NY, USA) was used for all statistical analyses.

RESULTS

There were 12 patients who underwent VBaT and 11 of them were followed up for more than 2 years. Demographic, radiological, and functional data are presented in Table 2. There were 4 male and 8 female patients with a mean age of 70.3 years (range, 52–83 years). The T score ranged from -0.7 to -3.9 (average, -2.5). The fracture site was T12 in 5 patients, L1 in 6 patients, and L1–2 (double segmental fracture) in 1 patient. The number of fusion segments was 2 in 1 patient, 3 in 5 patients, and 4 in 6 pa-

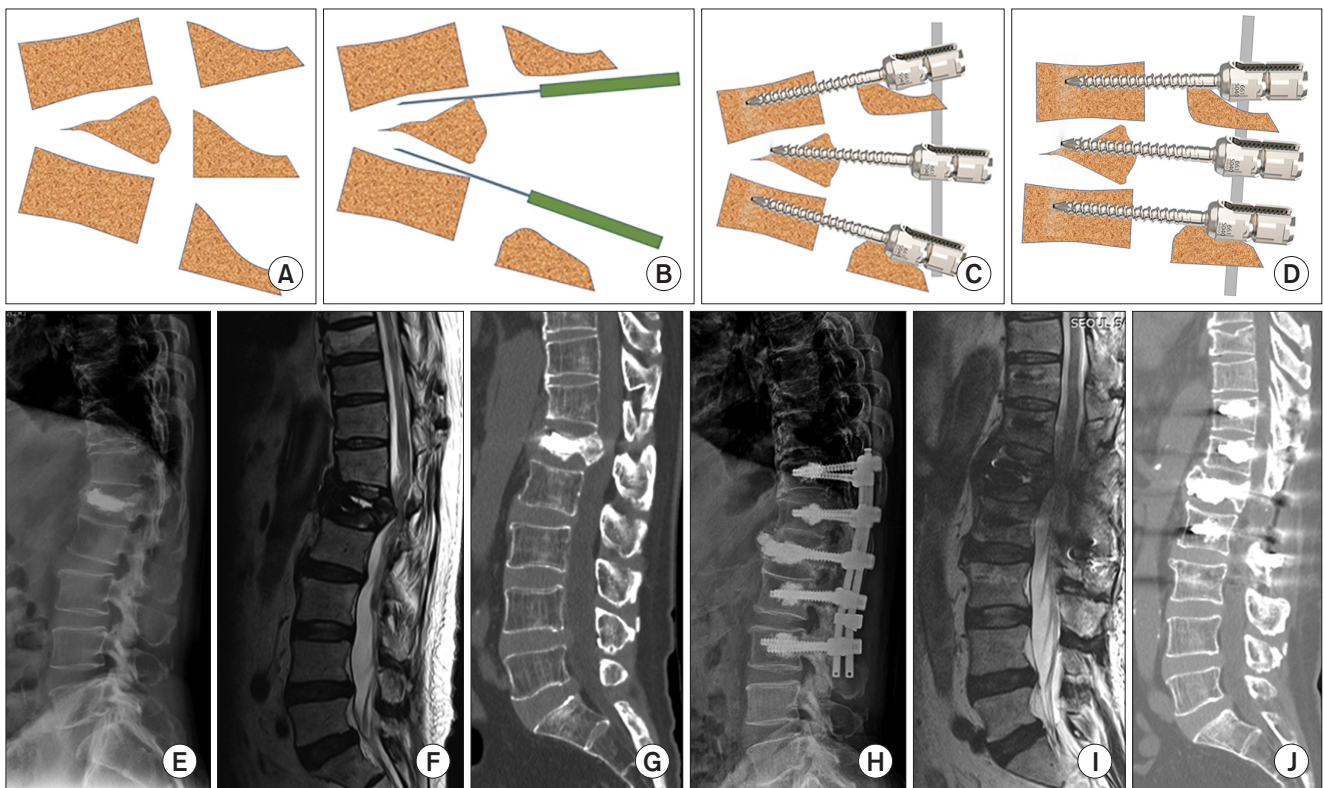


Fig. 2. (A) The anterior part of the vertebral body is severely compressed and the posterior wall is extruded into the spinal canal with kyphotic deformity. (B) Posterior laminectomy is performed and adjoining discs are released. (C) Pedicle screws with different screw head heights are inserted. (D) While assembling a rod, the posterior cortex is pushed anteriorly to bear the compression force as the middle column and kyphosis is reduced. Preoperative plain radiograph (E), T2 sagittal magnetic resonance image (F), and computed tomography (G). Postoperative plain radiographs (H), T2 sagittal magnetic resonance image (I), and computed tomography (J) of the same patient.

Table 2. Patients' Demographic Data

No	Age (yr)	Sex	Type	Fracture site	No. of fusion segments	BDM	PMMA augmentation	Fracture onset (mo)	Follow-up (mo)
1	69	F	Posterior wall fracture with vacuum cleft	L1	3	-3.2	+	28	60
2	77	F	Posterior wall fracture with vacuum cleft	L1	4	-2.4	+	Unknown	24
3	71	M	Angulation with endplate protrusion	L1,2	3	-2.5	+	3	55
4	82	F	Angulation with endplate protrusion	L1	4	-2.3	+	Unknown	40
5	74	F	Angulation with spinal canal impingement	L1	3	-2.0	+	Unknown	38
6	72	M	With posterior column fracture	L1	4	-1.9	+	6	42
7	52	F	With posterior column fracture	T12	3	-3.1	+	Unknown	24
8	83	F	Angulation with endplate protrusion	T12	3	-2.6	+	Unknown	40
9	64	M	Posterior wall fracture with vacuum cleft	T12	4	-2.6	-	Unknown	24
10	68	M	Angulation with endplate protrusion	T12	4	-0.7	-	7	24
11	76	F	Posterior wall fracture with vacuum cleft	L1	2	-3.9	+	6	24
12	56	F	Posterior wall fracture with vacuum cleft	T12	4	-2.3	-	Unknown	
Average 70.3 ± 9.4					3.4 ± 6.7	-2.5 ± 0.8			35.9 ± 13.1

Values are presented as mean ± standard deviation.

BDM: bone mineral density, PMMA: polymethyl methacrylate.

Table 3. Patients' Radiological and Functional Data

No	Regional Kyphotic angle (°)			Anterior vertebral body height ratio (%)			Spinal canal invasion ratio (%)		Nurick grade	
	Preop	Postop	Final	Preop	Postop	Final	Preop	Final	Preop	Final
1	51	23	22	23	73	61	55	30	4	1
2	25	8	9	35	92	96	67	29	4	2
3	43	7	6	38	85	90	60	20	4	3
4	22	3	3	34	92	100	44	0	3	1
5	35	8	11	26	76	82	61	36	5	2
6	36	9	10	32	77	82	55	28	4	2
7	39	14	15	30	92	92	38	21	2	0
8	23	0	0	28	83	86	47	31	3	1
9	33	3	7	14	81	72	48	19	4	1
10	35	3	10	19	65	67	43	25	3	1
11	33	9	15	29	100	93	60	38	3	1
12	47	19		23	50		58		5	
Average	35.1 ± 9.1	8.8 ± 6.8	9.8 ± 6.1	27.6 ± 7.0	80.5 ± 13.7	83.7 ± 12.5	52.6 ± 9.1	25.2 ± 10.4		
<i>p</i> -value*	< 0.001	0.043	0.001	< 0.001	0.827	< 0.001	< 0.001	0.003		

Values are presented as mean ± standard deviation.

Preop: preoperative, Postop: postoperative.

*Statistically significant.

tients. Nine patients showed insufficient insertion torque and their pedicle screws were augmented with PMMA. There were 3 types of spinal canal invasion. Five patients had vertebral body vacuum clefts with posterior wall fractures. Two patients had 3 column fractures. Five patients had vertebral body angulation with endplate protrusion.

Radiological and functional data are presented in Table 3. The mean RKA was 35.1° preoperatively, 8.8° postoperatively, and 9.8° at the final follow-up. Postoperative reduction (26.3°) was statistically significant ($p > 0.001$). Although the final reduction loss from the postoperative state was only 1°, it was also statistically significant ($p = 0.043$). Final reduction (25.3°) was statistically significant when compared to the preoperative state ($p > 0.001$) (Fig. 3).

The AVHr was 27.6% preoperatively, 80.5% postoperatively, and 83.7% at the final follow-up. The postoperative increase (52.9%) was statistically significant ($p <$

0.001). Although the final AVHr was increased by 3.2% from the postoperative state, the change was not statistically significant. The final increase in AVHr from the preoperative state (56.1%) was statistically significant ($p < 0.001$) (Fig. 4).

The SCIr was 52.6% preoperatively and 25.2% at the final follow-up; the decrease (27.4%) was statistically significant ($p < 0.001$) (Fig. 5). The Nurick's grade was improved in all patients by 1 to 3 grades ($p = 0.003$) (Fig. 6). The mean blood loss was 808 mL (range, 500–1,800 mL) and the mean operation time was 222 minutes (range, 160–310 minutes).

Regarding complications, 2 patients had adjacent OVCFs in the follow-up period. There was 1 case of PMMA leakage into the spinal canal, but it did not exhibit neurological symptoms. There was no pedicle screw loosening and rod breakage.

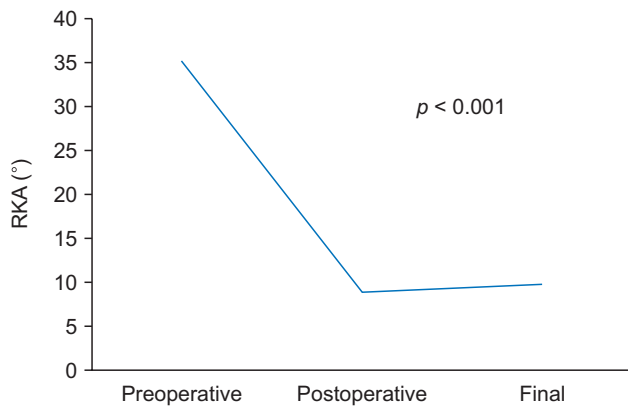


Fig. 3. Preoperative, postoperative, and final follow-up mean regional kyphotic angle (RKA) was 35.1°, 8.8°, and 9.8°, respectively. The reduction of RKA was significant ($p < 0.001$).

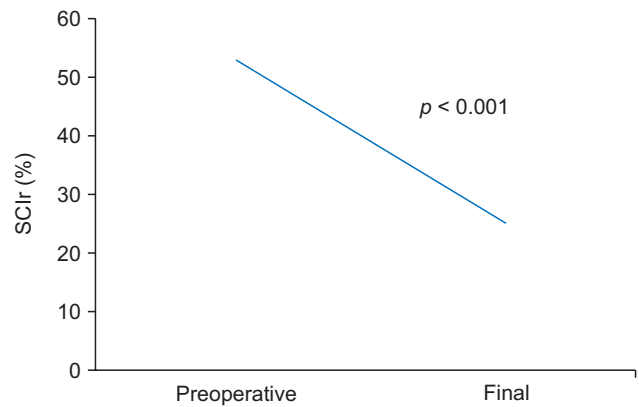


Fig. 5. Preoperative and final follow-up spinal canal invasion ratio (SCIr) was 52.6% and 25.2%, respectively. The decrease (27.4%) was significant ($p < 0.001$).

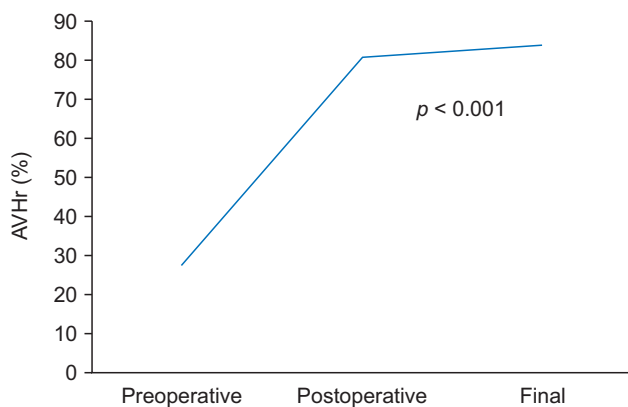


Fig. 4. Preoperative, postoperative, and final follow-up anterior vertebral height ratio (AVHr) was 27.6%, 80.5%, and 83.7%, respectively. Reduction of AVHr (52.9%) was significant ($p < 0.001$).

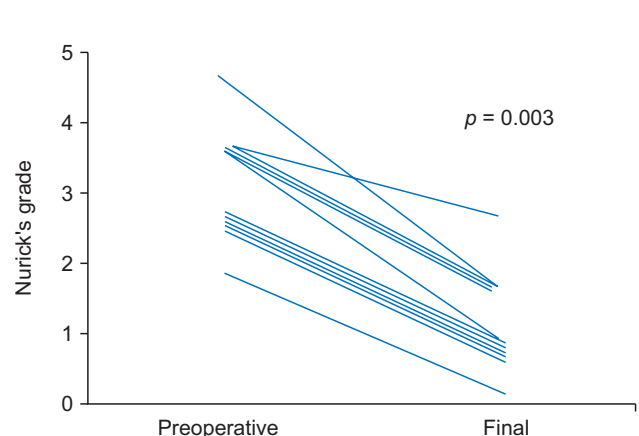


Fig. 6. The Nurick's grade was improved in all patients by 1 to 3 grades ($p = 0.003$).

DISCUSSION

Most OVCFs can be treated successfully with conservative management. Development of DM in vertebral fractures is attributable to inappropriate initial treatment or delayed collapse of OVCFs. The most common pathological progression is pseudoarthrosis followed by retropulsion of bony fragments with or without progression of kyphosis or instability.^{5,11} The onset time of OVCF was identified in only 5 patients, which was between 3 and 28 months. Seven patients did not recognize their OVCFs and visited our hospital with gait disturbance. Among the total patients who were included in this study, 5 patients had vacuum clefts with delayed collapse of the middle column, and another 5 patients had spinal canal invasion due to angular deformity associated with endplate invasion into the spinal canal. The middle column protects the spinal canal and maintains structural stability, which is why middle column-preserved compression fractures are not indicated for surgical stabilization.^{12,13} Morbidity according to the approach and difficulty in stabilization are the major concerns in the osteoporotic elderly population.⁴ In case of a bursting fracture with spinal canal encroachment, posterior fixation with pedicle screw system is often not strong enough to give proper stability. It consequently results in reduction loss, screw or rod fracture, and screw pullout. On the other hand, delayed collapse of the middle column after a compression fracture that caused spinal cord impingement almost always shows the middle column in the union state at the time of diagnosis. The purposes of surgical treatment of DM in OVCF are decompression of the spinal canal, correction of deformity, and restoration of permanent stability without loss of correction. Besides, we thought reduction of the number of fixation segments would be beneficial for preserving mobile segments, thereby preventing adjacent fractures. In previous studies, surgical modalities were classified as anterior decompression and anterior instrumentation,^{11,14} anterior decompression and posterior instrumentation,^{9,15-17} posterior decompression and instrumentation including posterior shortening osteotomy,^{6,18-22} and short-segment posterior spinal fusion with vertebroplasty.^{8,23}

Anterior procedures have advantages of direct resection of the retropulsed bone fragment and stable anterior column reconstruction.¹⁴ However, if a fractured vertebral body is removed to decompress a spinal canal, extensive anterior reconstruction involving a vertebral body and adjacent disc space will be necessary, which is not easy to perform in patients with medical comorbidities and osteoporosis. As a result, additional posterior instrumentation

was necessary in 19% of OVCF patients who underwent anterior instrumentation in a study by Kanayama et al.¹⁴ Sometimes, posterior decompression and reduction of kyphosis is enough for decompression; however, it is difficult to maintain the sagittal alignment with posterior fixation only because the posterior cortex of the vertebral body is usually displaced posteriorly and thus cannot bear the compression force. Posterior shortening osteotomy has a risk of neurological damage and copious bleeding.⁹ Anterior augmentation with vertebroplasty is not applicable if there is no vacuum cleft with apparent instability. Although neurological recovery was similarly considerable after all of the above methods, there was remarkable correction loss of kyphotic deformity (54% in anterior instrumentation, 43% in posterior instrumentation, and 88% in vertebroplasty with short posterior instrumentation) even though there was no association of neurological recovery and reduction of RKA.^{24,25} The causes of correction loss were mainly subsidence of anterior support, pedicle screw loosening, and disc space collapse between fused vertebrae.⁸ With posterior shortening osteotomy, the reduction loss of RKA was decreased; however, the procedure can be relatively invasive for elderly patients in terms of operation time and blood loss.^{9,20}

We devised a novel but simple technique to reconstruct the middle column with posterior cortex that was already united. By simply translating the fractured vertebra anteriorly, the posterior cortex could be realigned to meet the posterior cortex of the adjacent vertebral body and bear compression force. Intravertebral vacuum clefts were filled with PMMA. The disc space of the severely collapsed anterior column could be reconstructed with interbody bone graft, but it was not considered a mandatory procedure. Most patients in our study had osteoporosis. So, we augmented screws with PMMA in 9 patients to reinforce pullout force of the pedicle screw. PMMA augmentation can increase pullout force without significant complications.²⁶⁻²⁸ We used fenestrated screws for PMMA augmentation because it was reported that this type of augmentation exhibits better pullout strength than augmented solid screws.²⁹ We tried to preserve more mobile segments by performing short segment fixation with this technique to prevent subsequent fractures. Although the fixation segments were not so long (average, 3.4 segments), AVHr restoration and RKA correction were excellent and loss of correction at the final follow-up was minimal compared to most previous studies.^{3,8,20,22-24} We strongly believe that the excellent maintenance of correction was largely attributable to the middle column realignment performed to bear compression force. Nurick's grading system was used to

evaluate the neurological function. Most of the patients showed neurological aggravation while walking and had better function in recumbent state because of instability of the fractured segment. We thought Nurick's grade system can represent dynamic neurological deficits better than do other evaluation tools. All patients had neurological improvement and SCIr decreased remarkably. Operation time and blood loss were considerable because screw augmentation with PMMA required additional time, but there was no bleeding-related complications and surgical site infections.

There were 2 cases of posterior column, spinous process fractures. We were not able to ensure whether the spinous process fractures were present from the outset or developed lately. We had the initial examination images of one of them, which did not show any injury at the posterior column. Thus, we conjectured that continuous angular force caused the delayed avulsion fractures of the posterior column structures. We did not experience any screw pull-out or loosening. It may be attributable to PMMA augmentation of screws. We had a few cases of rod or screw neck fracture with the PMMA augmented screw technique for acute fractures or deformity correction; however, there was no such complication after the VBaT technique. We presumed load bearing through the realigned middle column decreased stress concentration on the instrument.

There are several limitations of this study. First, it is an observational study and the number of cases was not enough to determine the exact validity of our novel method. Although we compared our results with historical cohorts to prove non-inferiority, there was no statistical analysis comparing it to other methods. Second, although we presented radiological data based on more than 2 years of follow-up, radiological union of the interbody or on the

posterolateral side was not investigated. Since computed tomography-based confirmation of radiological union is not trustworthy, we thought that maintenance of sagittal alignment after the passage of sufficient time would be more important. Third, although the SCIr was measured on MRI, the postoperative MRI examination period was not consistent (we tried to examine at approximately 12 months postoperatively). Fourth, blood loss and operation time were greater than expectation. It was attributed to PMMA augmentation of screws, which lasted for approximately 30 minutes.

The most distinguished aspect of our method was stable middle column reconstruction and direct decompression of the spinal canal performed simultaneously without anterior structural bone grafts or implants. Most previous studies reported good neurological recovery, but there was considerable loss of reduction over time. By contrast, VBaT was beneficial for the maintenance of reduction.

In DM after an OVCF, although the posterior cortex invades the spinal canal, it is usually already in the union state. Therefore, it can bear compression force as a middle column if realigned to be in line with the adjoining vertebrae. VBaT showed satisfactory reduction and excellent maintenance at the last follow-up without significant complications. This method can be safer than anterior strut bone graft and posterior fixation or posterior shortening osteotomy and more effective for stable fixation than posterior decompression and fixation technique.

CONFLICT OF INTEREST

No potential conflict of interest relevant to this article was reported.

REFERENCES

1. Kasukawa Y, Miyakoshi N, Hongo M, et al. Surgical results of patients with myelopathy due to ossification of the ligamentum flavum with ossification of the posterior longitudinal ligament or a vertebral fracture at the same level of the thoracic spine: a retrospective comparative study. *Asian Spine J.* 2019;13(5):832-41.
2. Heggeness MH. Spine fracture with neurological deficit in osteoporosis. *Osteoporos Int.* 1993;3(4):215-21.
3. Kim KT, Suk KS, Kim JM, Lee SH. Delayed vertebral collapse with neurological deficits secondary to osteoporosis. *Int Orthop.* 2003;27(2):65-9.
4. Picazo DR, Villaescusa JR, Martinez EP, Perez FD. Late collapse osteoporotic vertebral fracture in an elderly patient with neurological compromise. *Eur Spine J.* 2014;23(12):2696-702.
5. Steel HH. Kummell's disease. *Am J Surg.* 1951;81(2):161-7.
6. Ataka H, Tanno T, Yamazaki M. Posterior instrumented fusion without neural decompression for incomplete neurological deficits following vertebral collapse in the osteoporotic thoracolumbar spine. *Eur Spine J.* 2009;18(1):69-76.
7. Matsuyama Y, Goto M, Yoshihara H, et al. Vertebral reconstruction with biodegradable calcium phosphate cement in the treatment of osteoporotic vertebral compression fracture using instrumentation. *J Spinal Disord Tech.*

- 2004;17(4):291-6.
8. Uchida K, Nakajima H, Yayama T, et al. Vertebroplasty-augmented short-segment posterior fixation of osteoporotic vertebral collapse with neurological deficit in the thoracolumbar spine: comparisons with posterior surgery without vertebroplasty and anterior surgery. *J Neurosurg Spine*. 2010;13(5):612-21.
 9. Suk SI, Kim JH, Lee SM, Chung ER, Lee JH. Anterior-posterior surgery versus posterior closing wedge osteotomy in posttraumatic kyphosis with neurologic compromised osteoporotic fracture. *Spine (Phila Pa 1976)*. 2003;28(18):2170-5.
 10. Nurick S. The pathogenesis of the spinal cord disorder associated with cervical spondylosis. *Brain*. 1972;95(1):87-100.
 11. Kaneda K, Asano S, Hashimoto T, Satoh S, Fujiya M. The treatment of osteoporotic-posttraumatic vertebral collapse using the Kaneda device and a bioactive ceramic vertebral prosthesis. *Spine (Phila Pa 1976)*. 1992;17(8 Suppl):S295-303.
 12. Panjabi MM, Oxland TR, Kifune M, Arand M, Wen L, Chen A. Validity of the three-column theory of thoracolumbar fractures: a biomechanic investigation. *Spine (Phila Pa 1976)*. 1995;20(10):1122-7.
 13. Denis F. Spinal instability as defined by the three-column spine concept in acute spinal trauma. *Clin Orthop Relat Res*. 1984;(189):65-76.
 14. Kanayama M, Ishida T, Hashimoto T, et al. Role of major spine surgery using Kaneda anterior instrumentation for osteoporotic vertebral collapse. *J Spinal Disord Tech*. 2010;23(1):53-6.
 15. Mei L, Sang W, Chen Z, et al. Titanium mesh bone grafting combined with pedicle screw internal fixation for treatment of Ku[Combining Diaeresis]mmell disease with cord compression: a case report and literature review. *Medicine (Baltimore)*. 2018;97(36):e12183.
 16. Nakashima H, Yukawa Y, Ito K, Horie Y, Machino M, Kato F. Combined posteroanterior surgery for osteoporotic delayed vertebral fracture and neural deficit in patients with Parkinson's disease. *Orthopedics*. 2009;32(10).
 17. Sudo H, Ito M, Kaneda K, et al. Anterior decompression and strut graft versus posterior decompression and pedicle screw fixation with vertebroplasty for osteoporotic thoracolumbar vertebral collapse with neurologic deficits. *Spine J*. 2013;13(12):1726-32.
 18. Dreimann M, Hempfing A, Stangenberg M, et al. Posterior vertebral column resection with 360-degree osteosynthesis in osteoporotic kyphotic deformity and spinal cord compression. *Neurosurg Rev*. 2018;41(1):221-8.
 19. Nakano A, Ryu C, Baba I, Fujishiro T, Nakaya Y, Neo M. Posterior short fusion without neural decompression using pedicle screws and spinous process plates: a simple and effective treatment for neurological deficits following osteoporotic vertebral collapse. *J Orthop Sci*. 2017;22(4):622-9.
 20. Saita K, Hoshino Y, Higashi T, Yamamuro K. Posterior spinal shortening for paraparesis following vertebral collapse due to osteoporosis. *Spinal Cord*. 2008;46(1):16-20.
 21. Saita K, Hoshino Y, Kikkawa I, Nakamura H. Posterior spinal shortening for paraplegia after vertebral collapse caused by osteoporosis. *Spine (Phila Pa 1976)*. 2000;25(21):2832-5.
 22. Sudo H, Ito M, Abumi K, et al. One-stage posterior instrumentation surgery for the treatment of osteoporotic vertebral collapse with neurological deficits. *Eur Spine J*. 2010;19(6):907-15.
 23. Lee SH, Kim ES, Eoh W. Cement augmented anterior reconstruction with short posterior instrumentation: a less invasive surgical option for Kummell's disease with cord compression. *J Clin Neurosci*. 2011;18(4):509-14.
 24. Kashii M, Yamazaki R, Yamashita T, et al. Surgical treatment for osteoporotic vertebral collapse with neurological deficits: retrospective comparative study of three procedures-anterior surgery versus posterior spinal shorting osteotomy versus posterior spinal fusion using vertebroplasty. *Eur Spine J*. 2013;22(7):1633-42.
 25. Sheng X, Ren S. Surgical techniques for osteoporotic vertebral collapse with delayed neurological deficits: a systematic review. *Int J Surg*. 2016;33 Pt A:42-8.
 26. Christodoulou E, Chinthakunta S, Reddy D, et al. Axial pullout strength comparison of different screw designs: fenestrated screw, dual outer diameter screw and standard pedicle screw. *Scoliosis*. 2015;10:15.
 27. Liu D, Wu ZX, Pan XM, et al. Biomechanical comparison of different techniques in primary spinal surgery in osteoporotic cadaveric lumbar vertebrae: expansive pedicle screw versus polymethylmethacrylate-augmented pedicle screw. *Arch Orthop Trauma Surg*. 2011;131(9):1227-32.
 28. Wittenberg RH, Lee KS, Shea M, White AA 3rd, Hayes WC. Effect of screw diameter, insertion technique, and bone cement augmentation of pedicular screw fixation strength. *Clin Orthop Relat Res*. 1993;(296):278-87.
 29. Leichtle CI, Lorenz A, Rothstock S, et al. Pull-out strength of cemented solid versus fenestrated pedicle screws in osteoporotic vertebrae. *Bone Joint Res*. 2016;5(9):419-26.