

# Nursemaid’s Elbow – Supination-flexion Technique Versus Hyperpronation/forced Pronation: Randomized Clinical Study

## Abstract

**Background:** Nursemaid’s elbow (NE) represents the most common pathology met in the pediatric orthopedics ambulatory. There are two techniques of reducing the NE: the supination-flexion technique and the hyperpronation or forced pronation technique. **Materials and Methods:** In this randomized clinical study, we aim to compare the two reduction techniques of the NE, by measuring the effectiveness of each and scaling the pain felt by the child, by using the Faces Pain Scale. The study included 116 patients with typical presentation for NE with age under 7 years old (mean age ~3 years old), 45% of males and 55% of females. **Results:** Hyperpronation was found to be more successful than supination-flexion technique as a first attempt (85% vs. 53%), second attempt (50% vs. 28%), and as a crossover technique (100% vs. 50%) when supination-flexion failed. **Conclusions:** This study concludes that hyperpronation technique should be used as a first maneuver reduction in treating NE, a simple one-movement technique.

**Keywords:** Nursemaid’s elbow, pediatric orthopedics, pulled elbow, radial head subluxation

**Alexandru Ulici,  
Alexandru Herdea,  
Madalina Carp,  
Catalin Alexandru  
Nahoi,  
Iulia Tevanov**

*Department of Pediatric  
Orthopedic Surgery, Emergency  
Hospital for Children  
“Grigore Alexandrescu,”  
Bucharest, Romania*

## Introduction

Nursemaid’s elbow (NE) or radial head subluxation represents the most common pediatric pathology met in pediatric orthopedic ambulatory under the age of six,<sup>1</sup> representing about 20% of upper-extremity conditions.<sup>2</sup>

The typical mechanism of injury includes axial traction on a pronated forearm that occurs during play or during common activities.<sup>3</sup> Following this traction, radial head subluxation occurs and the annular ligament is entrapped in the radiohumeral joint.<sup>4,5</sup> The typical clinical presentation includes pain of the forearm, limited movement of the elbow/forearm, the superior limb hangs near the body with the elbow slightly flexed, and forearm blocked in pronation.<sup>6,7</sup>

There are two techniques of reducing the NE: the supination-flexion technique and the hyperpronation or forced pronation technique.

The hyperpronation technique was first described by Hutchinson in 1886<sup>8,9</sup> and it is believed to be less painful and more successful if used as the first reduction

attempt,<sup>10-14</sup> although a recent Cochrane review<sup>15</sup> found low-quality evidence to sustain the benefits of this reduction method. The hyperpronation maneuver is depicted in Figure 1. The hyperpronation technique is performed as follows: the patient stays on the parent’s lap facing the examiner; grabbing the elbow with one hand, the examiner’s opposite hand firmly grabs the distal forearm as shown in Figure 2 and applies the hyperpronation as shown in Figure 3. During these maneuvers, a clank will be felt, a sign that the radial head has reentered into the annular ligament.<sup>10,16</sup>

Most pediatric and orthopedic textbooks recommend the supination-flexion technique.<sup>6,7,17,18</sup> The supination maneuver is shown in Figure 4. The technique is performed as follows: the patient stays on the parent’s lap facing the examiner; grabbing the elbow with one hand, the examiner’s opposite hand firmly grabs the distal forearm as shown in Figure 5 and applies the supination of the forearm as shown in Figure 6 followed by the flexion as shown in Figure 7. During these maneuvers, a clank will be felt, a sign of the radial head’s entry back into the annular ligament.<sup>7,10-12</sup>

### Address for correspondence:

*Dr. Alexandru Herdea,  
Department of Pediatric  
Orthopedic Surgery, Emergency  
Hospital for Children  
“Grigore Alexandrescu,”  
Bucharest, Romania.  
E-mail: alexherdea@yahoo.com*

### Access this article online

**Website:** www.ijoonline.com

**DOI:**  
10.4103/ortho.IJOrtho\_442\_17

### Quick Response Code:



**How to cite this article:** Ulici A, Herdea A, Carp M, Nahoi CA, Tevanov I. Nursemaid’s elbow – Supination-flexion technique versus hyperpronation/forced pronation: Randomized clinical study. Indian J Orthop 2019;53:117-21.

This is an open access journal, and articles are distributed under the terms of the Creative Commons Attribution-NonCommercial-ShareAlike 4.0 License, which allows others to remix, tweak, and build upon the work non-commercially, as long as appropriate credit is given and the new creations are licensed under the identical terms.

For reprints contact: reprints@medknow.com

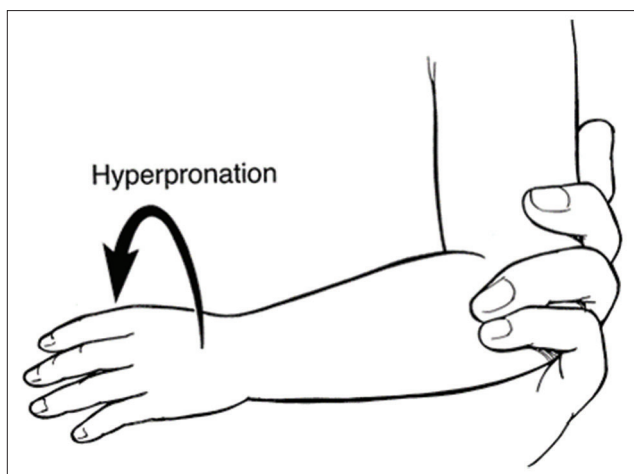


Figure 1: Hyperpronation maneuver



Figure 2: Hyperpronation maneuver – step 1



Figure 3: Hyperpronation maneuver – step 2

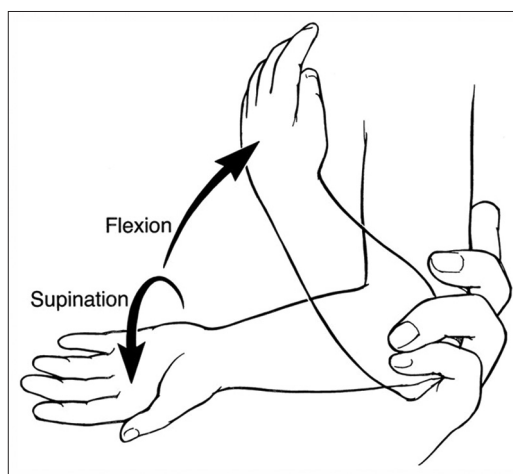


Figure 4: Supination-flexion maneuver

## Objectives

In this randomized clinical study, we aim to compare the two reduction techniques of the NE, by measuring the effectiveness of each one and scaling the pain felt by the child, by using the Faces Pain Scale.<sup>19,20</sup>

## Materials and Methods

The study was done at the pediatric orthopedic emergency department of an emergency hospital located in an urban area between February 2016 and February 2017.

We chose to conduct a prospective, unblinded, interventional, randomized controlled study. The study included children with age under 7 years old with typical clinical presentation and case history for NE (pain experienced in the forearm, limited movement of the elbow/forearm, the upper limb hanging near the body with the elbow slightly flexed, and pronated forearm, usually with a history of someone who pulled/lifted/swung/caught the child by the hand). Patients that had any traumatic injury such as falls, hits, or any other signs of trauma and fractures (soft-tissue swelling, redness, and local deformity) were excluded from the study.

A local ethical committee approved this study. An informed consent was obtained from the parents of all

the participants. The reduction was performed by a pediatric orthopedist, in the emergency room. All the doctors in the department were previously trained in order to follow the same reduction protocol. Patients were asked if they received pain killers at home, but none received any.

The patients were randomized by odd and even numbers. Every odd-numbered patient received the supination-flexion technique (Group A), while the even-numbered patient received the hyperpronation technique (Group B).

The patients were reevaluated after 10 min. The initial procedure was repeated if the first attempt failed. Then, we waited for another 10 min. If the second attempt failed, it resulted in a crossover to the alternate method for the third attempt. If the patient failed both techniques, plain X-ray of the forearm and elbow was performed [Figure 8]. If the radiography showed no abnormality, but the patient refused to move his elbow, then the patient was immobilized in a long-arm cast for 1 week. The flowchart of the randomization process is shown in Figure 9.

The pain was evaluated using the Faces Pain Scale, after the reduction. A different pediatric orthopedist doctor (not the one who performed the reduction) did the evaluation.



Figure 5: Supination-flexion maneuver – step 1



Figure 6: Supination-flexion maneuver – step 2

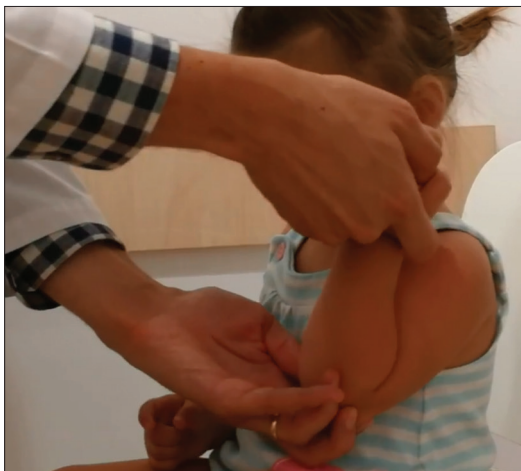

Figure 7: Supination-flexion maneuver – step 3

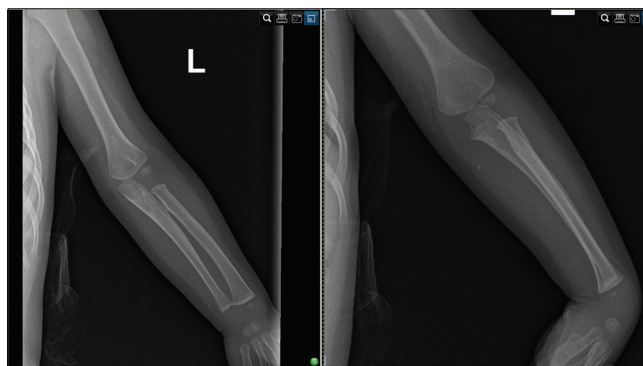

Figure 8: X-ray of a Nursemaid's elbow, before the reduction

Demographic data, technique success, and pain levels were analyzed statistically. Gender was analyzed using the Chi-square test. The efficacy of the techniques was analyzed using Fisher's exact test. The comparisons of pain levels were analyzed using the average score. Statistical significance was determined using  $P < 0.05$  at a 95% confidence interval. Analyses were performed with the SPSS 18.0 software (IBM Corporation, USA).

## Results

Among the 155 patients that presented with suggestive clinical signs for NE, 116 were selected for the study. Fifteen patients were excluded for having suspicious case history and local edema; eight patients were older than 7 years old and did not meet the inclusion criteria and 16 patients declined participation to the study and refused written consent.

The median age was 34 months, ranging from 6 to 83 months (~6.9 years). Fifty three (45.68%) patients were males, while 63 (54.31%) were females. Among the 116 patients, 114 were treated with one of the reduction techniques; two patients complained of persistent pain after the reduction and a long-arm cast was used for 1 week. After this period, the cast was removed and the range of motion of the elbow/forearm was evaluated and found to be painless and normal. The demographic data of the patients is summarized in Table 1.

A total of eighty patients (68.96%) were successfully reduced after the first attempt, using one of the two techniques.

We divided the study into two groups: a group with patients under 3 years of age and the other group with patients older than 3 years of age. The results after reduction were compared in order to establish if the success of the methods is age related, but these results were not statistically significant [Table 1].

Thirty one percent (25) of the patients had, based on memory, recurrent episodes of pulled elbow. Having a positive history for NE did not influence the success of the reduction, as summarized in Table 1.

The supination-flexion technique was used as the first choice of reduction for sixty patients (51.72%) (Group A). Thirty two patients (53.33%) were properly reduced after the first attempt, using this technique. Eight patients (13.33%) were reduced after the second attempt. Twenty patients (33.33%) were reduced using the alternative method, when the first two reduction attempts had failed.

The hyperpronation technique was used as the first choice of reduction for 56 patients (48.27%) (Group B). Forty eight (85.71%) patients were reduced in the first attempt using this technique. Four patients (7.14%) were reduced in the second attempt and four patients (7.14%) underwent the alternative method in a third attempt. Two patients needed cast immobilization because of persistence of pain.

The supination-flexion technique was applied to 42 out of 64 patients, while the hyperpronation technique was applied to 72 out of 76 patients. Table 2 summarizes the success rates of both techniques.

Evaluation of pain levels was done for 95 patients, older than 1 year. This evaluation was performed after the first attempt of reduction only.

Using the Faces Pain Scale, we noticed an average score of 5.9 for supination-flexion technique, while the hyperpronation technique achieved a score of 5.3. The results were not statistically significant.

### Discussion

In medical textbooks, the supination-flexion technique is suggested to be the main reduction maneuver for NE.<sup>6,7,21,22</sup> However, there are studies that consider hyperpronation to be more effective not only as a first attempt, but also as a crossover technique when supination-flexion failed.<sup>10,11,13</sup>

One of the studies reports a 95% success rate for hyperpronation method from the first attempt versus 77% for the supination method and concluded that the hyperpronation method was more successful as a crossover maneuver, enrolling a total of ninety patients.<sup>10</sup> Another study that enrolled 148 patients reported 80% success rate for hyperpronation and 69% for the supination maneuver and concluded that hyperpronation may be less painful if used as a first attempt technique.<sup>11</sup> In their randomized study on 66 patients, Bek *et al.* achieved a success rate of 94% for hyperpronation and 69% for the supination maneuver. The authors stated that the hyperpronation maneuver is easier to be performed by the physicians and less painful for the children.<sup>13</sup> In our study, we noticed that hyperpronation was more successful in comparison with supination-flexion method, as a first attempt and as a crossover technique.

We choose the Faces Pain Scale to evaluate the pain after the reducing maneuver. Other studies used different pain scales such as Wong-Baker Pain Scale,<sup>11</sup> mCHEOPS,<sup>23</sup> the standard Visual Analog Pain Scale,<sup>12</sup> and the Faces Pain Scale.<sup>19,20</sup>

Referring to the pain scale, McDonald *et al.* noted the score provided by the parents and physicians using the Wong-Baker scale,<sup>11</sup> which is prone to be subjective. Gunaydin *et al.*, using the mCHEOPS scale, had another physician who recorded the pain level in order to obtain more conclusive results.<sup>23</sup> In their study, Green *et al.* had recorded the pain level using a standard Visual Analog Pain Scale from parents, nurses, and physicians before, during, and 1 min after the reduction.<sup>12</sup> The scores reported by the physicians were similar for the two maneuvers, but nurses and parents recorded better scores with hyperpronation hence being perceived less painful. In our study, the pain felt by the child while using the hyperpronation technique was lower than that using the supination technique, but the difference was not statistically significant. Some studies reported better results using the hyperpronation method and noticed that this maneuver was less painful as reported by nurses and parents.<sup>12,22,24</sup>

Pain monitoring in children is difficult and the quantification is often subjective.<sup>23</sup> Hyperpronation technique of the forearm requires lesser steps than supination-flexion method. This could be a possible explanation for the reduction success, with less pain cited in many studies. Parents could be educated on how to safely perform the maneuver if the situation repeats.

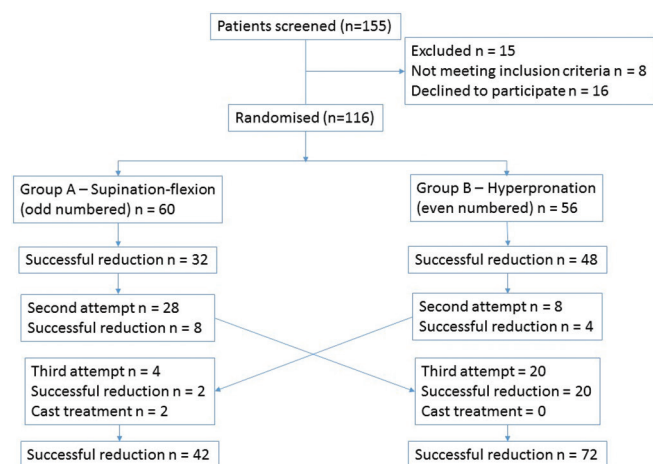


Figure 9: Flowchart of patients

Table 1: Demographic data

Patients	Supination-flexion	Hyperpronation	P
Male	28	25	0.826
Female	32	31	
Under 3 years	23	33	0.765
Over 3 years	9	15	
Recurrent	8	17	0.969
New cases	24	31	

Table 2: The efficacy of the reduction techniques based on the number of attempts

Attempts	Reduction maneuver				Total	χ <sup>2</sup>	P
	Supination-flexion (n=60), n (%)		Hyperpronation (n=56), n (%)				
	Successful	Unsuccessful	Successful	Unsuccessful			
First attempt	32/60 (53.33)	28/60 (46.66)	48/56 (85.71)	8/56 (14.18)	116	19.548	0.00001
Second attempt	8/28 (28.57)	20/28 (71.42)	4/8 (50)	4/8 (50)	36	-	0.25
Third attempt	2/4 (50)	2/4 (50)	20/20 (100)	-	24	-	-
Total	42/92		72/76		116		0.00

Some study limitations can be observed. For example, just by comparing the pain felt by a 1-year-old child with a 5-year-old child cannot be correctly assessed by this score, mostly because the level of understanding is better at 5 years old than at 1 year old. In addition, patients under 1 year of age were excluded as not being part of the Faces Pain Scale inclusion criteria.

A limitation of the study consists of the randomization criteria. A randomization in a same age population could be done in a power study, which has a more clear impact on the success rate of the technique and the amount of pain at the first reduction attempt.

Another limitation of the study is that we could not quantify the time that passed by since the radial head subluxation occurred until the reduction maneuver was performed, and what was the impact of this on the amount of pain and the success of the reduction. We noticed that delayed cases, as far as 2 or 3 days old, are harder to be reduced and the patient experiences more pain after the reduction.

## Conclusions

Hyperpronation was found more successful than supination-flexion technique as a first attempt (85% vs. 53%), second attempt (50% vs. 28%), and as a crossover technique.

Even if the pain scores are not statistically significant, in our opinion, hyperpronation was less painful for the patient, but further studies should be done comparing same-age patients in order to obtain a power study.

This study concludes that hyperpronation technique should be used as a first reduction maneuver in treating NE, a simple one-movement technique.

## Declaration of patient consent

The authors certify that they have obtained all appropriate patient consent forms. In the form, the patients have given their consent for their images and other clinical information to be reported in the journal. The patients understand that their names and initials will not be published and due efforts will be made to conceal their identity, but anonymity cannot be guaranteed.

## Financial support and sponsorship

Nil.

## Conflicts of interest

There are no conflicts of interest.

## References

- Schutzman SA, Teach S. Upper-extremity impairment in young children. *Ann Emerg Med* 1995;26:474-9.
- Egol KA, Strauss EJ. *Emergency Room Orthopaedic Procedures: An Illustrative Guide for the House Officer*. New Delhi, JP Medical Ltd.; 2012.
- Green NE, Van Zeeland NL. Fractures and dislocations about the elbow. In: Green NE, Swiontkowski MF, editors. *Skeletal Trauma in Children*. 4<sup>th</sup> ed. Philadelphia: Saunders Elsevier; 2008. p. 207-82.
- Salter RB, Zaltz C. Anatomic investigations of the mechanism of injury and pathologic anatomy of "pulled elbow" in young children. *Clin Orthop Relat Res* 1971;77:134-43.
- Joffe MD, Loiselle JM. Annular ligament displacement (radial head subluxation). In: Fleisher GR, Ludwig S, editors. *Textbook of Pediatric Emergency Medicine*. 6<sup>th</sup> ed. Philadelphia, PA: Lippincott Williams & Wilkins; 2010. p. 1574-5.
- Morrissy RT, Weinstein SL. Lovell & Winter's *Pediatric Orthopaedics*. 6<sup>th</sup> ed. Philadelphia, PA: Lippincott Williams & Wilkins; 2005. p. 1463-4.
- Beatty JH, Kasser JR. *Rockwood and Wilkins Fractures in Children*. 7<sup>th</sup> ed. Philadelphia: Lippincott Williams & Wilkins; 2009. p. 614-9.
- Hutchinson JJ. On certain obscure sprains of the elbow occurring in young children. *Ann Surg* 1885;2:91.b2-97.
- Hutchinson J. Partial dislocation of the head of the radius peculiar to children. *Br Med J* 1886;1:9-10.
- Macias CG, Bothner J, Wiebe R. A comparison of supination/flexion to hyperpronation in the reduction of radial head subluxations. *Pediatrics* 1998;102:e10.
- McDonald J, Whitelaw C, Goldsmith LJ. Radial head subluxation: Comparing two methods of reduction. *Acad Emerg Med* 1999;6:715-8.
- Green DA, Linares MY, Garcia Peña BM, Greenberg B, Baker RL. Randomized comparison of pain perception during radial head subluxation reduction using supination-flexion or forced pronation. *Pediatr Emerg Care* 2006;22:235-8.
- Bek D, Yildiz C, Köse O, Sehirlioglu A, Başbozkurt M. Pronation versus supination maneuvers for the reduction of 'pulled elbow': A randomized clinical trial. *Eur J Emerg Med* 2009;16:135-8.
- García-Mata S, Hidalgo-Ovejero A. Efficacy of reduction maneuvers for "pulled elbow" in children: A prospective study of 115 cases. *J Pediatr Orthop* 2014;34:432-6.
- Krull M, van der Wouden JC, Kruithof EJ, van Suijlekom-Smit LW, Koes BW. Manipulative interventions for reducing pulled elbow in young children. *Cochrane Database Syst Rev* 2017;7:CD007759.
- Quan L, Marcuse EK. The epidemiology and treatment of radial head subluxation. *Am J Dis Child* 1985;139:1194-7.
- Teach SJ, Schutzman SA. Prospective study of recurrent radial head subluxation. *Arch Pediatr Adolesc Med* 1996;150:164-6.
- Taha AM. The treatment of pulled elbow: A prospective randomized study. *Arch Orthop Trauma Surg* 2000;120:336-7.
- Hunter M, McDowell L, Hennessy R, Cassey J. An evaluation of the faces pain scale with young children. *J Pain Symptom Manage* 2000;20:122-9.
- Chambers CT, Giesbrecht K, Craig KD, Bennett SM, Huntsman E. A comparison of faces scales for the measurement of pediatric pain: Children's and parents' ratings. *Pain* 1999;83:25-35.
- Carlson D, Digiulio G, Gewitz MH, Silverman, Fred M. *Henretting. Procedures*. In: Fleisher GR, Ludwig S, editors. *Textbook of Pediatric Emergency Medicine*. 4<sup>th</sup> ed. Philadelphia: Lippincott Williams & Wilkins; 2000. p. 1892-3.
- Joffe M. Upper extremity injuries. In: Barkin RM, editor. *Pediatric Emergency Medicine. Concept and Clinical Practice*. St. Louis, MO: Mosby; 1997. p. 414-5.
- Gunaydin YK, Katirci Y, Duymaz H, Vural K, Halhalli HC, Akcil M, *et al.* Comparison of success and pain levels of supination-flexion and hyperpronation maneuvers in childhood nursemaid's elbow cases. *Am J Emerg Med* 2013;31:1078-81.
- Lyver MB. Radial head subluxation. *J Emerg Med* 1991;9:154-6.