

# Vascular Reconstruction for Radiation-induced Bilateral Internal Carotid Artery Occlusion and Unilateral External Carotid Artery Stenosis by a Combination of Surgical and Endovascular Method: Case Report

Junya Taki, Tomoo Tokime, Atsuhito Matsumoto, and Yoshinori Akiyama

We present a case of a 63-year-old male presenting with right hemiparesis and diagnosed as cerebral infarction. He had a previous history of left pharyngeal carcinoma, which was treated by radical dissection and radiation therapy 10 years before. Magnetic resonance imaging (MRI) showed multiple cerebral infarction in the bilateral cerebral hemisphere, predominantly on the left. Cerebral angiography showed occlusion of bilateral internal carotid arteries and severe stenosis at the orifice of the left external carotid artery (ECA). Single photon emission tomography (SPECT) showed reduced cerebral blood flow and decreased cerebral vascular reserve in the bilateral anterior cerebral artery and left middle cerebral artery territories. He was successfully treated by a combination of carotid stenting for the left ECA and left superficial temporal artery–middle cerebral artery (STA-MCA) anastomosis. He did not have further ischemic symptom for more than 2 years. Radiation-induced carotid vasculopathy often involves multiple arteries and treatment is often complex and difficult. Safer and less invasive treatment strategy should be considered using both endovascular and direct surgery.

**Keywords:** radiation-induced vasculopathy, external carotid artery stenting, superficial temporal artery–middle cerebral artery anastomosis

## Introduction

Radiation-induced carotid stenosis/occlusion (RICS/O) was thought to develop late after irradiation for neck and head cancer. We encounter, more often recently, as the prognosis of patients with malignant tumor gets improved with more efficient treatments including radiation therapy (RT). Treatment for RICS/O is complex and difficult, because it involves multiple arteries within the field of RT, and because RT is often undergone after radical neck dissection which makes difficult to manipulate surgically at the same region.

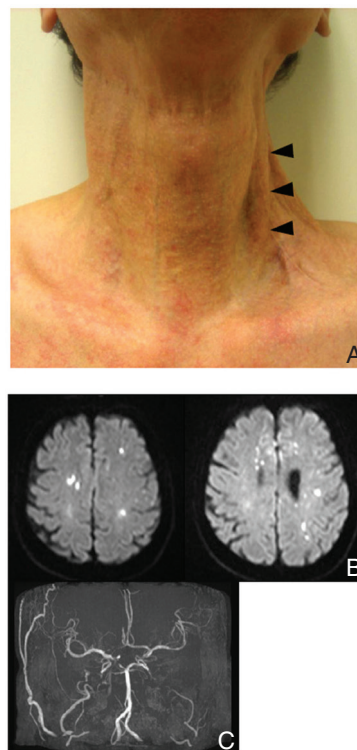
We present a patient who suffered from multiple cerebral infarction due to radiation-induced bilateral internal carotid artery occlusion (ICAO) and unilateral external carotid artery (ECA) stenosis. He was successfully treated using a combination of endovascular and bypass surgery.

Department of Neurosurgery, Tenri Hospital, Tenri, Nara

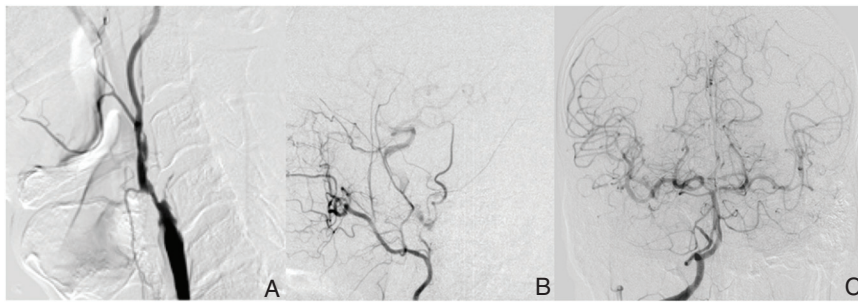
Received: April 27, 2014; Accepted: July 9, 2014

## Case Report

A 63-year-old man was admitted to the Department of Neurology of Tenri Hospital at the end of March 2011. He was suffering from gradually worsening right hemiparesis including the right face about 10 days ago and was being diagnosed as cerebral infarction. He had a previous history of pharyngeal carcinoma, which was treated by the left neck radical dissection, followed by RT with a total dose of 60 Gy 10 years before this event. The scar was seen on his left neck. The surface of the skin was hard and thin, and carotid artery was seen just beneath it (Fig. 1A). He had no episode of cardiac arrhythmia and electrocardiogram (ECG) showed normal sinus rhythm on admission. Magnetic resonance imaging (MRI) of the brain showed multiple hyperintense spot on diffusion weighted image (DWI) in the bilateral cerebral hemisphere, predominantly in the left (Fig. 1B). Cerebral infarctions in the right hemisphere were distributed



**Fig. 1** A: The skin of the neck is thin and hard due to the radical neck dissection and irradiation, especially in the left side. Pulsation of the left carotid artery is seen just beneath the skin (arrowhead). B: Diffusion weighted magnetic resonance imaging (MRI) shows multiple infarction in the bilateral anterior cerebral artery (ACA) territories and the left middle cerebral artery (MCA) territory. C: MR angiogram shows occlusion of the bilateral internal carotid arteries (ICAs). Peripheral branches of the bilateral ICAs are revealed by collateral circulation. Distal segments of the bilateral ACAs are filled mainly by the left ICA. The signal of the left superficial temporal artery (STA) is unclear as compared to the right STA.



**Fig. 2** A: The left common carotid angiogram (CAG) shows occlusion at the orifice of the left internal carotid artery (ICA). Severe stenosis is also observed at the orifice of the left external carotid artery (ECA). B: The left external CAG shows decreased flow of the superficial temporal artery (STA) due to the stenosis at the orifice of the ECA. Collateral flow to the left distal ICA through the ophthalmic artery is observed. C: The right vertebral angiogram shows collateral flow to the bilateral ICA territories through posterior communicating arteries (Pcoms).

within and along the border zone of the anterior cerebral artery (ACA) territory. Magnetic resonance angiography (MRA) of the intracranial vessels revealed occlusion of the bilateral internal carotid arteries (ICAs) (Fig. 1C). Signals of the left superficial temporal artery were diminished on MRA, as compared to the opposite side (Fig. 1C).

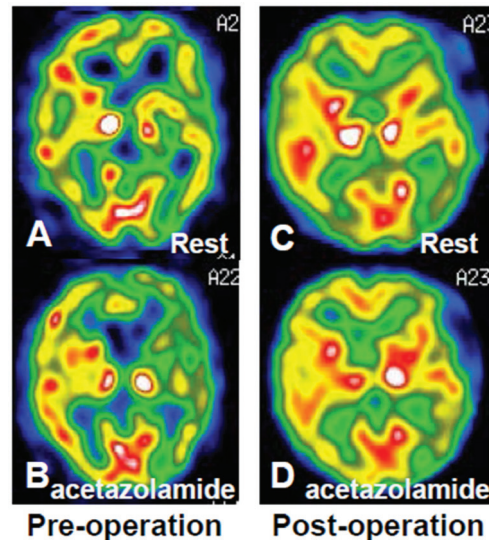
He was treated conservatively, administered aspirin and argatroban, and symptoms were gradually resolved. He was consulted to the Department of Neurosurgery for surgical intervention to prevent recurrence of the cerebral infarction.

Cerebral angiogram showed occlusion at the orifice of the ICAs bilaterally. Bilateral intracranial ICAs were filled mainly by vertebral angiogram (VAG) through posterior communicating arteries (Pcoms) (Fig. 2C) and also by carotid angiogram (CAG) through ophthalmic arteries (OAs) (Fig. 2B). Bilateral ACAs were predominantly supplied by left A1, as suggested also in MRA (Fig. 1C). In addition, left CAG showed severe stenosis of the ECA at the orifice (Fig. 2A) and left superficial temporal artery (STA) was poorly revealed (Fig. 2B). These obstructive lesions involving multiple cervical arteries (bilateral ICAs and the left ECA) were included in the field of the previous RT and were diagnosed as radiation-induced vasculopathy. Plaque at the orifice of the left ECA was evaluated as unstable by plaque imaging MRI.

The result of pre-operative single photon emission tomography (SPECT) using N-isopropyl-I-123-p-iodoamphetamine (<sup>123</sup>I-IMP) evaluating cerebral blood flow (CBF) is shown in Fig. 3A and B, and quantitative values are shown in Table 1. The CBF in the resting state showed hypoperfusion in the bilateral cerebral hemisphere, predominantly in the left hemisphere and the right ACA territory. In acetazolamide challenge, markedly decreased cerebral vascular reserve (CVR) was revealed in the left middle cerebral artery (MCA) and the bilateral ACA territories, which showed steal phenomenon. These results suggested Power's stage II misery perfusion in the left MCA and the bilateral ACA territories.

We decided to do vascular reconstruction to restore CBF in the left ICA territory. This is because the essential problem for multiple infarction in the bilateral hemisphere in this patient was thought to be misery perfusion of the left ICA territory, including the right ACA territory which was also supplied mainly by the left A1.

The patient was administered on aspirin and cilostazol since the onset of the stroke. First, carotid artery stenting (CAS, Precise 9 × 40 mm, Cordis, Bridgewater, New Jersey,



**Fig. 3** A, B: Pre-operative single photon emission tomography (SPECT) shows reduced cerebral blood flow (CBF) at rest (A) and decreased cerebral vascular reserve (CVR) at the acetazolamide challenge (B) in the left hemisphere and also in the right anterior cerebral artery territory. C, D: One week after bypass surgery, CBF at rest (C) and CVR (D) recovered showing no laterality.

USA ) for the orifice of the left ECA was performed (Fig. 4B). The left STA was clearly revealed immediately after the procedure, suggesting recovery of the blood flow (Fig. 5A). Argatroban was administered 60 mg for 2 days and 20 mg for 5 days after CAS. One week later, by follow-up angiography, plaque protrusion or thrombus was identified in the stent (Fig. 4C). We decided to deploy another stent (Carotid Wallstent 10 × 24 mm, Boston Scientific, Natick, Massachusetts, USA) (Fig. 4D). After the second procedure, argatroban was administered in the same way and heparin 10,000 units a day was continued to prevent further thrombus formation in the stent. One more week later, plaque protrusion or thrombus was observed again by angiography (Fig. 4E), which was treated by balloon angioplasty (Fig. 4F).

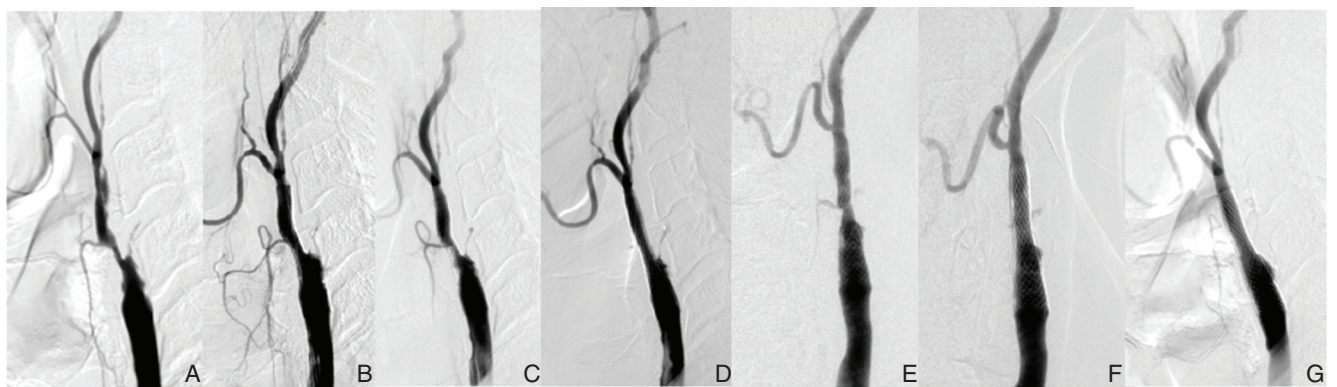
Finally, we performed STA-MCA anastomosis after discontinuation of heparin on the day of the surgery.

The post-operative course was favorable with no episode of transient ischemic attack (TIA) or stroke. Angiography performed on 6 days after surgery revealed patency of the bypass (Fig. 5B and 5C). Although small plaque was identified in the stent placed at the ECA orifice in this

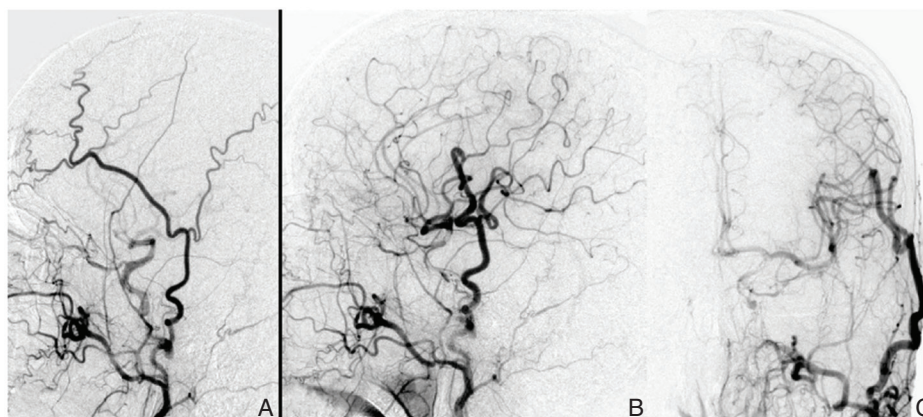
**Table 1** Quantitative analysis of pre- and post-operative CBF studies

Pre-operative CBF							
Right hemisphere				Left hemisphere			
	Rest (ml/100 g/min)	acetazolamide (ml/100 g/min)	CVR (%)		Rest (ml/100 g/min)	acetazolamide (ml/100 g/min)	CVR (%)
ACA	25.681	25.736	0.214	ACA	23.278	18.223	-21.716
MCA	27.479	33.414	21.598	MCA	25.058	21.94	-12.443
PCA	28.23	32.468	15.012	PCA	25.814	30.435	17.901
Cerebellum	31.479	35.515	12.821	Cerebellum	31.702	37.428	18.056
Post-operative CBF							
Right hemisphere				Left hemisphere			
	Rest (ml/100 g/min)	acetazolamide (ml/100 g/min)	CVR (%)		Rest (ml/100 g/min)	acetazolamide (ml/100 g/min)	CVR (%)
ACA	32.047	42.594	32.911	ACA	29.514	38.238	29.559
MCA	34.954	41.639	19.125	MCA	30.239	37.852	25.176
PCA	30.223	36.656	21.285	PCA	30.777	37.262	21.071
Cerebellum	32.722	35.732	9.199	Cerebellum	35.454	44.653	25.946

CBF: cerebral blood flow, CVR: cerebral vascular reserve, ACA: anterior cerebral artery, MCA: middle cerebral artery, PCA: posterior cerebral artery.



**Fig. 4** A–G: The left carotid angiogram shows occlusion at the orifice of the internal carotid artery (ICA), and severe stenosis at the orifice of the external carotid artery (A). Stenting was performed and the stenosis was resolved (B). One week later, re-stenosis was observed caused by plaque protrusion or acute in-stent thrombosis (C). Another stent is placed, which resulted in successful dilatation of the lesion (D). Another week later, signal defect caused by in-stent thrombus was observed (E), which was resolved by balloon angioplasty (F). Three months after bypass surgery, the flow in the stent is smooth and re-stenosis is no longer observed (G).



**Fig. 5** A: After stenting for the stenosis of the left external carotid artery (ECA), the left carotid angiogram reveals the left superficial temporal artery (STA) much better than before stenting (Fig. 2B). B, C: After bypass surgery, intracranial internal carotid artery (ICA) territory is clearly revealed through STA bypass graft.

angiography, it spontaneously disappeared in the 3 month later (Fig. 4G). CBF and CVR were clearly improved in the left MCA and bilateral ACA territories (Fig. 3C, D and Table 1) and steal phenomenon was resolved. The patient continued dual anti-platelet therapy in the chronic stage after surgery until now and did not have any stroke episodes more than 2 years.

## Discussion

Previous histories of irradiation to treat malignant tumor of the head and neck were reported to correlate higher incidence of carotid stenosis as compared to non-irradiated atherosclerotic diseases.<sup>1-7)</sup> Elerding et al. retrospectively reviewed 910 patients who had cervical irradiation and revealed 6.3% of the incidence of stroke during a mean follow-up period of 9 years.<sup>8)</sup> Plummer et al. analyzed previous 99 studies and concluded that irradiation for the neck and head cancers at least doubled the relative risk of TIA and ischemic stroke.<sup>9)</sup>

Some studies reported favorable results by direct surgical repair for RICS/O.<sup>10-12)</sup> However previous history of radical neck dissection before RT increases the incidence of wound complication and cranial nerve injury.<sup>13)</sup> In our case, the patient had a history of radical neck dissection before irradiation. The skin of his neck was hard due to severe scarring and fibrosis, and pulsation of the left carotid artery was seen just beneath the thin skin. Therefore, direct surgical manipulation of the neck had better be avoided.

In addition to the method described in this article, we initially discussed two other strategies. One was high flow bypass using radial artery (RA) graft from the left common carotid artery (CCA) to the intracranial artery (the left MCA). The other was so-called "Bonnet" bypass using STA or RA free graft from the contralateral (right) STA to the left MCA through under the skin of the head.<sup>14,15)</sup> We chose neither one. In the former strategy, we had to directly manipulate the left cervical region which was damaged by previous surgical dissection and irradiation. Disadvantages of the latter Bonnet bypass were that the method itself was complex and that it would become difficult to reconstruct blood supply of the right hemisphere in case that CBF of the right hemisphere would become worse in the future. In addition, considering the etiology of multiple infarctions in this patient, thrombus might come from unstable plaque at the orifice of the left ECA through the OA. In such case, treatment to the stenosis of the ECA would be necessary.

Therefore, we chose the method described in this article, a combination of endovascular reconstruction to the stenosis of the left ECA within the irradiated field and surgical bypass between the left STA and the left MCA, which was performed outside the irradiated field. This strategy was essentially the same as done by Oku et al. in a patient with atherosclerotic ICA occlusion and ipsilateral ECA severe stenosis.<sup>16)</sup> It was rather simple and safe by methods used in usual clinical practice. They performed CAS for ECA severe stenosis before STA-MCA anastomosis because the stenotic lesion of the ECA was high (C2 level) for carotid

endarterectomy (CEA). In the present case, it was also advantage to choose endovascular reconstruction for ECA in terms that it did not require surgical manipulation to the irradiated field.

Long-term result for stenting to the artery within the irradiated field or to the ECA remained unknown. There are studies revealing usefulness of CAS in the treatment of RICS.<sup>17-20)</sup> Some studies reported restenosis is more frequently observed in RICS than non-irradiated carotid stenosis.<sup>18,21,22)</sup> On the other hand, there is a report showing no significant difference of restenosis between CAS and CEA within patients with RICS.<sup>13)</sup> As for CAS for ECA stenosis, there are only case reports or studies including small number of patients.<sup>23-26)</sup> Kouvelos et al. reviewed previous 21 reports including 56 patients (58 arteries) describing endovascular treatment of the ECA and identified low rate of perioperative (during the first 30 days) stroke (1.8%) or death (0%) but a high rate of TIAs (8.9%).<sup>27)</sup> In their study, there were no delayed cerebrovascular events during the follow-up period of an average of 23.8 months. Restenosis was found in 3.4% and stent occlusion was found 1.7%. Their study included old case reports in which only percutaneous transluminal angioplasties (PTAs) without stent were performed.

In our case, stenting to the orifice of the ECA finally restored flow of the left STA, and then STA-MCA anastomosis was performed. These treatments resulted in favorable improvement of the CBF of the left internal carotid territory, and led to more than 2 years freedom from further ischemic event.

In conclusion, as RICS/O is complex, the treatment strategy should be considered case-by-case basis more safely and less invasively by combining endovascular technique and direct surgery.

## Conflicts of Interest Disclosure

The authors report no conflict of interest concerning the case presented in this article.

## References

- 1) Brown PD, Foote RL, McLaughlin MP, Halyard MY, Ballman KV, Collie AC, Miller RC, Flemming KD, Hallett JW: A historical prospective cohort study of carotid artery stenosis after radiotherapy for head and neck malignancies. *Int J Radiat Oncol Biol Phys* 63: 1361-1367, 2005
- 2) Carmody BJ, Arora S, Avena R, Curry KM, Simpkins J, Cosby K, Sidway AN: Accelerated carotid artery disease after high-dose head and neck radiotherapy: is there a role for routine carotid duplex surveillance? *J Vasc Surg* 30: 1045-1051, 1999
- 3) Cheng SW, Ting AC, Lam LK, Wei WI: Carotid stenosis after radiotherapy for nasopharyngeal carcinoma. *Arch Otolaryngol Head Neck Surg* 126: 517-521, 2000
- 4) Cheng SW, Ting AC, Ho P, Wu LL: Accelerated progression of carotid stenosis in patients with previous external neck irradiation. *J Vasc Surg* 39: 409-415, 2004
- 5) Greco A, Gallo A, De Virgilio A, Marinelli C, Macri GF, Fusconi M, Pagliuca G, de Vincentiis M: Carotid stenosis after adjuvant cervical radiotherapy in patients with head and neck cancers: a prospective controlled study. *Clin Otolaryngol* 37: 376-381, 2012
- 6) Moritz MW, Higgins RF, Jacobs JR: Duplex imaging and incidence of carotid radiation injury after high-dose radiotherapy for tumors of the head and neck. *Arch Surg* 125: 1181-1183, 1990

- 7) Lam WW, Leung SF, So NM, Wong KS, Liu KH, Ku PK, Yuen HY, Metreweli C: Incidence of carotid stenosis in nasopharyngeal carcinoma patients after radiotherapy. *Cancer* 92: 2357–2363, 2001
- 8) Elerding SC, Fernandez RN, Grotta JC, Lindberg RD, Causay LC, McMurtrey MJ: Carotid artery disease following external cervical irradiation. *Ann Surg* 194: 609–615, 1981
- 9) Plummer C, Henderson RD, O'Sullivan JD, Read SJ: Ischemic stroke and transient ischemic attack after head and neck radiotherapy: a review. *Stroke* 42: 2410–2418, 2011
- 10) Kashyap VS, Moore WS, Quinones-Baldrich WJ: Carotid artery repair for radiation-associated atherosclerosis is a safe and durable procedure. *J Vasc Surg* 29: 90–96; discussion 97–99, 1999
- 11) Kasivisvanathan V, Thapar A, Davies KJ, Dharmarajah B, Shalhoub J, Davies AH: Periprocedural outcomes after surgical revascularization and stenting for postradiotherapy carotid stenosis. *J Vasc Surg* 56: 1143–1152.e2, 2012
- 12) Lesèche G, Castier Y, Chataigner O, Francis F, Besnard M, Thabut G, Abdalla E, Cerceau O: Carotid artery revascularization through a radiated field. *J Vasc Surg* 38: 244–250, 2003
- 13) Tallarita T, Oderich GS, Lanzino G, Cloft H, Kallmes D, Bower TC, Duncan AA, Głowiczki P: Outcomes of carotid artery stenting versus historical surgical controls for radiation-induced carotid stenosis. *J Vasc Surg* 53: 629–636.e1–e5, 2011
- 14) Sanada Y, Kamiyama H, Iwaisako K, Yoshimine T, Kato A: “Bonnet” bypass to proximal trunk of middle cerebral artery with a radial artery interposition graft: technical note. *Minim Invasive Neurosurg* 53: 203–206, 2010
- 15) Spetzler RF, Roski RA, Rhodes RS, Modic MT: The “bonnet bypass.” *J Neurosurg* 53: 707–709, 1980
- 16) Oku T, Nogami K, Koizumi H, Ishihara H, Kato S, Fujisawa H, Suzuki M: External carotid artery stenting and superficial temporal artery to middle cerebral artery anastomosis for internal carotid artery occlusion with external carotid artery severe stenosis: case report. *Neurol Med Chir (Tokyo)* 52: 906–909, 2012
- 17) Dorresteijn LD, Vogels OJ, de Leeuw FE, Vos JA, Christiaans MH, Ackerstaff RG, Kappelle AC: Outcome of carotid artery stenting for radiation-induced stenosis. *Int J Radiat Oncol Biol Phys* 77: 1386–1390, 2010
- 18) Favre JP, Nourissat A, Duprey A, Nourissat G, Albertini JN, Becquemin JP; Association Universitaire de Recherche en Chirurgie Vasculaire: Endovascular treatment for carotid artery stenosis after neck irradiation. *J Vasc Surg* 48: 852–858, 2008
- 19) Al-Mubarak N, Roubin GS, Iyer SS, Gomez CR, Liu MW, Vitek JJ: Carotid stenting for severe radiation-induced extracranial carotid artery occlusive disease. *J Endovasc Ther* 7: 36–40, 2000
- 20) Ting AC, Cheng SW, Yeung KM, Cheng PW, Lui WM, Ho P, Tso WK: Carotid stenting for radiation-induced extracranial carotid artery occlusive disease: efficacy and midterm outcomes. *J Endovasc Ther* 11: 53–59, 2004
- 21) Protack CD, Bakken AM, Saad WE, Illig KA, Waldman DL, Davies MG: Radiation arteritis: a contraindication to carotid stenting? *J Vasc Surg* 45: 110–117, 2007
- 22) Shin SH, Stout CL, Richardson AI, DeMasi RJ, Shah RM, Panneton JM: Carotid angioplasty and stenting in anatomically high-risk patients: Safe and durable except for radiation-induced stenosis. *J Vasc Surg* 50: 762–767; discussion 767–768, 2009.
- 23) Weber JF, Kirsch E, Radü EW, Steck AJ, Kaiser HJ, Lyrer PA: Angioplasty in a patient with ocular ischemia due to occlusion of the internal and stenosis of the external carotid artery. *Cerebrovasc Dis* 16: 436–439, 2003
- 24) Nussbaumer-Ochsner Y, Eberli FR, Baumgartner RW, Landau K, Roffi M: Sirolimus-eluting stenting of the external carotid artery for the treatment of ocular ischemia. *J Endovasc Ther* 13: 672–675, 2006
- 25) Xu DS, Abruzzo TA, Albuquerque FC, Dabus G, Eskandari MK, Guterma LR, Hage ZA, Hurley MC, Hanel RA, Levy EI, Nichols CW, Ringer AJ, Batjer HH, Bendok BR: External carotid artery stenting to treat patients with symptomatic ipsilateral internal carotid artery occlusion: a multicenter case series. *Neurosurgery* 67: 314–321, 2010
- 26) Yamagata T, Mitsuhashi Y, Nishio A, Kawakami T, Yoshimura M, Urano Y, Yamagata K, Ohata K: Protection of anastomotic pathways to the vertebral artery during stenting of external carotid artery stenosis. *Neurol Med Chir (Tokyo)* 50: 1001–1005, 2010
- 27) Kouvelos GN, Koutsoumpelis AC, Klonaris C, Matsagkas MI: Endovascular repair of external carotid artery disease. *J Endovasc Ther* 19: 504–511, 2012

Corresponding author:

Junya Taki, MD, Department of Neurosurgery, Tenri Hospital, 200 Mishima-cho, Tenri, Nara 632-8552, Japan.

✉ jtaki6@gmail.com