

Accuracy of Pedicle Screw Placement Comparing an Electronic Conductivity Device and a Multi-axis Angiography Unit with C-arm Fluoroscopy in Lumbar Fixation Surgery for Safety

Hiroto KAGEYAMA,¹ Shinichi YOSHIMURA,¹ Kotaro TATEBAYASHI,¹
Tomoko IIDA,¹ and Kiyofumi YAMADA²

¹Department of Neurosurgery, Hyogo College of Medicine, Nishinomiya, Hyogo, Japan

²Department of Neurosurgery, Kyoto University, Kyoto, Kyoto, Japan

Abstract

The aim of this study was to compare the accuracy, safety, and usefulness of percutaneous pedicle screw (PPS) placement for lumbar fixation using a multi-axis angiography unit (MAU) and an electronic conductivity device (ECD) with a cannulated Jamshidi needle with that using a conventional C-arm. Of 65 cases that underwent lumbar fixation (region between L1–S1) during April 2013 to March 2019, 57 cases that could be followed-up for more than 12 months after the procedure were included. Among them, 31 patients (150 screws) received treatment with MAU and ECD (MAU+ECD group) and 26 (117 screws) were treated with the conventional C-arm. We performed a retrospective study of the surgical techniques used in each group at our institute by assessing the accuracy of PPS using Gertzbin–Robbins classification and the Japanese Orthopedic Association (JOA) score for recovery. There was no significant difference in surgery outcome based on the JOA recovery rate. There was a significant difference between the two groups in terms of Accuracy-1 (Group A indicating accuracy and Groups B–E indicating inaccuracy), where the rates were 85.3% and 72.0% in the MAU+ECD group and C-arm group, respectively ($P = 0.008$). There was also a significant difference between the two groups in terms of Accuracy-2 (Groups A–B indicating accuracy; Groups C–E indicate inaccuracy), where the rates were 98.0% and 92.4% in the MAU+ECD and C-arm groups, respectively ($P = 0.036$). A combination of MAU and ECD is a safe and accurate method for inserting screws into the pedicle.

Keywords: multi-axis angiography unit, electronic conductivity device, lumbar fixation surgery, percutaneous pedicle screw, accuracy rate

Introduction

Posterior lumbar interbody fusion (PLIF), transforaminal lumbar interbody fusion (TLIF), and lateral interbody fusion (LIF) with percutaneous pedicle screw (PPS) placement are widely performed for lumbar fixation, as this method is minimally invasive and PPS is easy to handle.^{1,2)} PPS placement is usually conducted under fluoroscopic guidance, using a C-arm imaging device, which is widely

available.³⁾ Recently, to insert screws accurately, safely, and less invasively, various supporting devices have been developed and used in different medical institutions. These include a mobile C-arm that can capture three-dimensional (3D) images, such as the Arcadis Orbic Isocentric C-arm (Siemens Healthineers, Erlangen, Germany),^{4–6)} a device that combines the O-arm (Medtronic, Minneapolis, MN, USA) and a navigation system,^{7–11)} a device such as the AIRO (Brainlab AG, Munich, Germany) that combines mobile computed tomography (CT) and a navigation system,^{5,10,11)} and a device that utilizes a robotic-assisted navigational system.^{12,13)}

In the present study, we used two different types of information-guided intraoperative supporting devices: a multi-axis angiography unit (MAU) (Artis

Received October 27, 2020; Accepted December 22, 2020

Copyright© 2021 by The Japan Neurosurgical Society This work is licensed under a Creative Commons Attribution-NonCommercial-NoDerivatives International License.

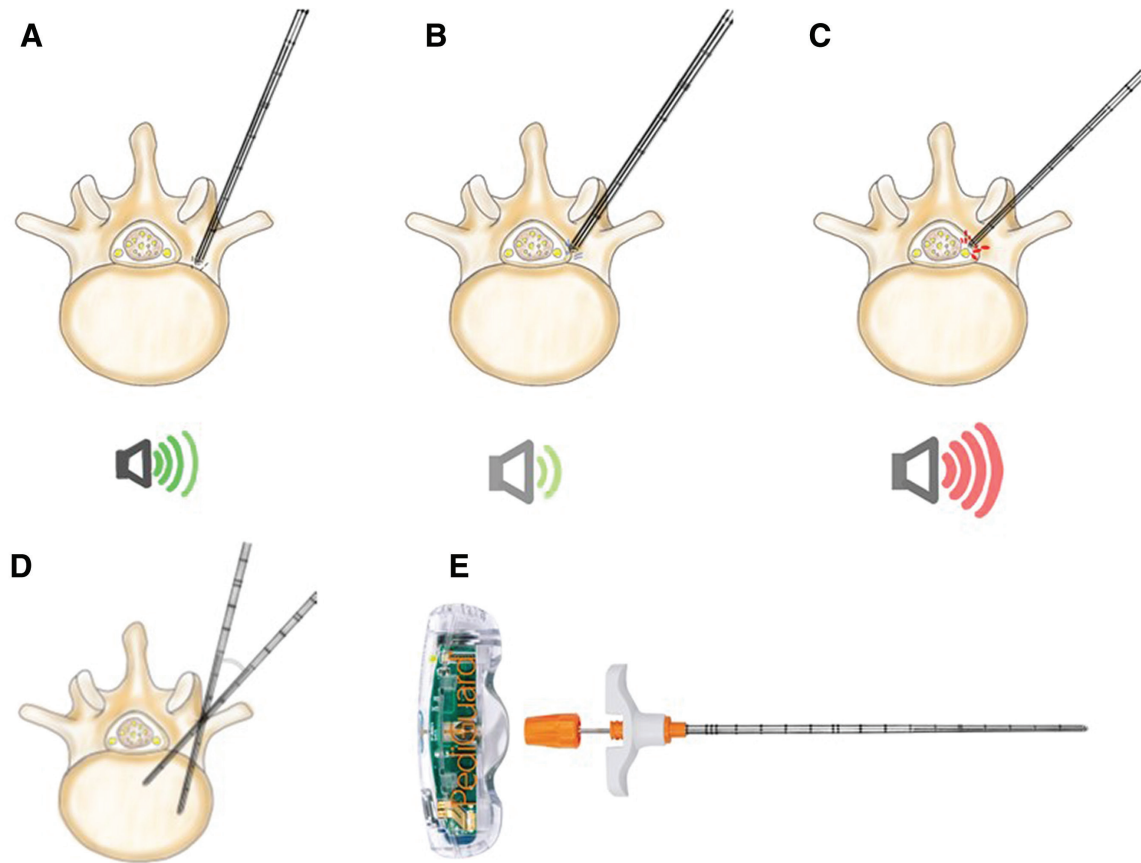


Fig. 1 (A) The ECD is carefully inserted into the cancellous bone of the pedicle while listening to the normal sound and pitch emitted from the device. (B) When the sound from the device disappears, it indicates that it is touching the cortical wall around the pedicle. (C) When the ECD is advanced, it emits a high pitch and frequency as an alert sound, indicating penetration of the pedicle wall. (D) Schema shows the safety angle for placing the ECD. The normal sound and pitch emitted from the device helps to guide the ECD into the appropriate position. (E) An ECD with a cannulated Jamshidi needle (PediGuard; Spine Guard, Paris, France). ECD: electronic conductivity device.

Zeego, VC21-B, Siemens Healthineers) that can capture wide-range, high-resolution, fluoroscopic images and 3D images (which allows creation of CT-like images intraoperatively),^{14,15)} and an electronic conductivity device (ECD) with a cannulated Jamshidi needle (PediGuard; Spine Guard, Paris, France).^{16–18)} (Fig. 1E). Electrical conductivity is measured at the tip of the probe, capturing the relative difference in tissue conductivities (measured at five samples per second), after which the information is converted to sound in real time. The normal sound and pitch indicating cancellous bone will disappear as the probe comes close to cortical bone. Furthermore, the ECD emits sound with a high frequency and pitch as a warning when the probe makes contact with soft tissue or a blood component slightly outside of the cortical bone¹⁶⁾ (Figs. 1A–C).

Our facility's MAU is not coupled with a navigation system. We predicted that accurate and safe surgery can be performed using an auditory-assisted ECD

combined with the visually assisted MAU. We compared the effectiveness and the safety of this MAU+ECD system with those of the conventional C-arm system in lumbar fixation performed in our facility.

Materials and Methods

Of 65 patients who underwent lumbar fixation (in the region between L1 and S1) for lumbar spondylolisthesis during the period between April 2013 and March 2019, we included 57 patients who were followed for more than 12 months after the procedure. Among these, 31 patients (total screw number: 150) received treatment with the MAU and ECD (MAU+ECD group) and 26 (total screw number: 118) were treated using the conventional C-arm device (Veradius Unity, Release 1-1, Philips, Best, The Netherlands) (C-arm group). The MAU was introduced in our institution in 2014, and we started lumbar fixation surgery with this equipment in

2016. And also, the ECD was introduced in 2016. Almost C-arm cases and MAU-ECD were performed from 2013 to 2016 and 2016 to 2019, respectively. We conducted a retrospective study of the surgical techniques of each group at our institute by assessing the accuracy of PPS placement and the Japanese Orthopedic Association (JOA) score for recovery for each of these methods.

Surgical technique

All surgeries were performed by a single surgeon, using either the CDH SOLERA SEXTANT or CDH SOLELA VOYAGER (Medtronic) PPS after interbody fusion under general anesthesia. The fluoroscopic device position was adjusted in the anteroposterior (AP) orientation as much as possible. The rotation angle and left-right balance of the vertebral pedicles were also adjusted, taking into consideration the fluoroscopic angle.¹⁹⁾ The fluoroscopic device was operated by a radiology technician in the MAU+ECD group, and by a physician in the C-arm group. PLIF, TLIF, and LIF methods were used for lumbar interbody fusion.

A skin incision was made for PPS placement. For the MAU+ECD group, auditory information was obtained using the ECD, and the MAU was positioned in the AP view. First, the Jamshidi needle was used to penetrate the cortical bone, and thereafter, the ECD was inserted into the medial area of the pedicle, and lateral view images were taken to verify that the tip of the ECD was positioned inside the vertebral body (Fig. 1A–1C). Then, the ECD was removed after guidewire insertion. A screw was then inserted over the guidewire under fluoroscopic guidance provided by the MAU. For the C-arm group, a normal Jamshidi needle (PAKneedle, Medtronic) was used, and the same fluoroscopic method was applied. The size of the screw inserted into the pedicle was chosen depending on the depth and the angle; screw sizes of 5.5–7.5 mm were selected using the preoperative CT. For the MAU+ECD group, CT-like images in the axial, sagittal, and coronal views were captured by cone-beam imaging using the MAU. Oblique images were captured using fluoroscopy in the C-arm group to confirm the screw position. Once screw positions were ascertained, the rod was fastened.

Evaluation of screw position

Screw accuracy was evaluated in both groups using postoperative CT imaging in axial, sagittal, and coronal views, based on the Gertzbin–Robbins classification²⁰⁾ as follows: Group A: screw position is within the pedicle, Group B: cortical breach of less than 2 mm, Group C: cortical breach of 2 mm or more but less than 4 mm, Group D: cortical breach of 4 mm or more but less than 6 mm, and Group E:

cortical breach of 6 mm or more. In this study (Fig. 2A–2D), we defined only Group A as accurate and Groups B–E as inaccurate for the first analysis (Accuracy-1), and Groups A–B as accurate and Groups C–E as inaccurate in the second analysis (Accuracy-2).

A written approval consent was obtained from all the participant patients enrolled. This study was conducted under the approval of the Hyogo College of Medicine Ethics Committee (202004-410).

Statistical analysis

Student's *t*-test was applied for comparison of characteristics between the two groups, and the chi-square test was applied to assess PPS placement accuracy. The significance threshold was $P < 0.05$. The statistical software JMP Pro 13 (SAS Institute, Cary, NC, USA) was used for the analysis.

Results

In terms of the baseline characteristics, there was no difference between the two groups in terms of gender ratio, age, body mass index, and preoperative JOA score. However, there was a significant difference in the insertion angle of the screw between the two groups. The insertion angle was $27.8 \pm 7.1^\circ$ in the MAU+ECD group and $24.9 \pm 8.0^\circ$ in the C-arm group, respectively. The insertion angle of the MAU+ECD group was significantly larger than that of the C-arm group ($P = 0.002$). The size of the screw was also significantly larger in the MAU+ECD group, where the screw diameter was 6.64 ± 0.79 mm, than in the C-arm group, where it was 6.35 ± 0.66 mm (Table 1).

There was no significant difference in the outcomes of the surgery based on the JOA recovery rate; the JOA recovery rate in the MAU+ECD group was 0.69 ± 0.19 , and that of the C-arm group was 0.67 ± 0.19 ($P = 0.71$).

The numbers of screws judged as Groups A, B, C, D, and E were 126, 21, 2, 1, and 0 in the MAU + ECD groups, and 89, 22, 6, 1, and 0 in the C-arm group, respectively. There was a significant difference between the two groups in terms of Accuracy-1, where that in the MAU+ECD group was 85.3%, and that in the C-arm group was 72.0% ($P = 0.008$). There was also a significant difference between the two groups in Accuracy-2, where that in the MAU+ECD group was 98.0%, and that in the C-arm group was 92.4% ($P = 0.036$) (Table 2).

Discussion

In the present study, we investigated a combination of ECD and MAU as a surgery-support device during PPS insertion in lumbar fixation surgery. To the

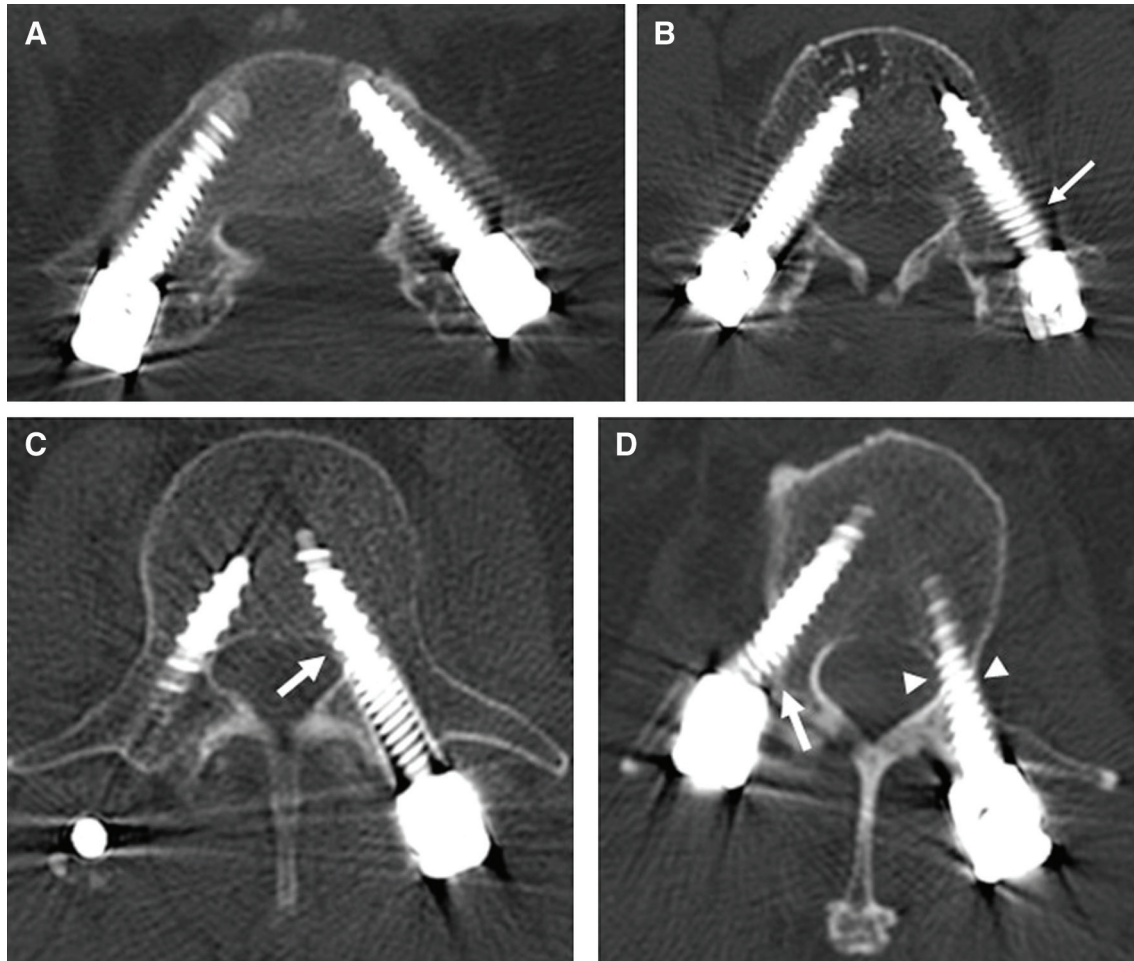


Fig. 2 Postoperative axial images. (A) Pedicle screws of Group A, bilaterally (screw position is within the pedicle). (B) Left-side pedicle screw of Group B (cortical breach of less than 2 mm) (arrow). (C) Left pedicle screw of Group C (cortical breach of 2 mm or more but less than 4 mm) (arrow). (D) Right pedicle screw of Group D (cortical breach of 4 mm or more but less than 6 mm) (arrow); left screw of Group B. Although the screw diameter is the same as that of the pedicle, the screw is placed at ideal position (arrowheads).

best of our knowledge, no previous study has investigated the accuracy of lumbar screw positions when using these surgical supporting devices together. Our results suggest that the combination of MAU+ECD is clinically effective (accuracy rate of 98.0%, yielding a high success rate) and provides a safe surgical procedure with a screw position deviation of less than 2 mm from the cortex.

Pedicle screws have become the mainstay of posterolateral fusion in the lumbar region, and PPS placement is a safe method and is now considered minimally invasive.^{1,21)} On the other hand, problems may arise during insertion of the pedicle screw. If the screw deviates medially, it may damage the dural theca and the transverse root. If the screw deviates laterally or downwards, it may damage the exiting root, and if the screw deviates beyond the anterior margin of the vertebral body, it may injure

the aorta or intestinal canal.²²⁾ Moreover, if the screw deviates and penetrates the cortical bone, the bone could be weakened, which may cause a decrease in fusion rate and adjacent segmental diseases. Thus, there is some disagreement within the literature regarding the necessity of accurate pedicle screw placement within a given vertebral body.^{1,2,22)}

In the present study, an ECD was used as Jamshidi needle, which was applied at the placement of the PPS to provide auditory information to the operators. Electrical conductivity is measured at the tip of the probe, detecting relative differentiation of tissue conductivity, which is sampled five times per second, and then the information is converted into sound in real time. Bolger et al. reported that the detection of pedicle breaches during actual pedicle drilling with an ECD is superior to the sensation by surgeons only.¹⁸⁾ Additionally, Guillen et al. reported the accuracy of

Table 1 Demographic characteristics

	C-arm	MAU + ECD	<i>P</i>
Pt. No. (Screw no.)	26 (118)	31 (150)	
Men (%)	46.2	71.0	0.057
Age	66.9 ± 8.6	68.0 ± 10.8	0.68
BMI (kg/m ²)	24.2 ± 3.0	23.0 ± 3.7	0.18
JOA (pre-OP)	17.2 ± 4.4	16.2 ± 5.6	0.46
Screw angle (°)	24.9 ± 8.0	27.8 ± 7.1	0.0015*
Screw diameter (mm)	6.4 ± 0.66	6.6 ± 0.79	0.0019*

BMI: body mass index, ECD: electronic conductivity device, JOA: Japanese Orthopedic Association, MAU: multi-axis angiography unit, No: number, OP: operation, Pt: patient.

Table 2 JOA recovery and accuracy rate

	C-arm	MAU + ECD	<i>P</i>
JOA recovery	0.67 ± 0.19	0.69 ± 0.19	0.71
Accuracy (1) (%)	72.0	85.3	0.0076*
Accuracy (2) (%)	92.4	98.0	0.036*

ECD: electronic conductivity device, JOA: Japanese Orthopedic Association, MAU: multi-axis angiography unit.

pedicle screw placement in a study using a cadaver.¹⁶⁾ Chaput et al. reported that pedicle screw placement with ECD guidance was accurate and decreased irradiation levels in clinical practice.¹⁷⁾ Other studies have also shown the accuracy of screw placement, even for the placement of cervical pedicle screws in children,²³⁾ C1 lateral mass screws,²⁴⁾ and S2 alar iliac screws.²⁵⁾ Thus, since 2005, when the ECD was released, many studies have reported the efficiency of screw insertion using ECD in spinal surgery.

As the resolution of fluoroscopic images obtained with the MAU is markedly higher than that of the conventional C-arm, the MAU can greatly support the surgeon by providing visual information. Although the MAU in our institution is not coupled to a navigation system, image resolution of the MAU is markedly higher than that of the C-arm, allowing clear visualization of the shape or margin of the pedicle and the tip of the guidewire, facilitating more accurate screw insertion than that achieved with the C-arm.¹⁵⁾ In the present study, we found that the accuracy of screw insertion in the MAU+ECD group (98.0%) was higher than that in the C-arm group (92.4%). Richter et al. reported a high accuracy by combining the MAU and a navigation system during surgery for orthopedic diseases, including spinal disorders.¹⁴⁾ Furthermore, Bohoun et al. reported a high accuracy (97.4%) of screw insertion

using cone-beam CT in a hybrid operating room without a coupled navigation system.²⁶⁾

In the present study, the screw size and insertion angle in the MAU+ECD group were larger than those in the C-arm group, suggesting that screw placement in the MAU+ECD group was more difficult; however, the accuracy was higher. We speculate that the combined usage of both auditory and visual information could have improved accuracy of PPS placement in the MAU+ECD group. Evaluation of the accuracy of the insertion was performed using a stricter method; instead of using the more general categorization of Gertzbin–Robbins classification Group B and Group C, Group A and Group B were defined as Accuracy-1. Despite using this stricter evaluation method, the MAU+ECD group had a significantly higher accuracy than the C-arm group. We speculate that this high accuracy rate was possible due to the sound information conveyed by the ECD, and this information made the ideal probing near the midline (Fig. 1D).

On the other hand, Gertzbin–Robbins classification Group D screw deviation was experienced even with MAU+ECD for the right-side screw (Fig. 2D). When a Jamshidi needle was inserted into the vertebral body immediately after penetrating the transverse process, it was difficult to detect malpositioning of the point of the screw because no alerting sound was provided by the ECD when it was inserted through the cancellous bone in the vertebral body, and penetration had to be detected using real-time fluoroscopy with the MAU.

At present, the gold-standard surgery-supporting device is the C-arm fluoroscopy device.¹⁹⁾ However, other surgery-support devices and approaches have been developed that can provide navigational guidance during surgery; these include preoperative CT images,²⁶⁾ a C-arm that can be obtaining cone-beam 3D images,^{4,5)} an O-arm, and an AIRO that uses intraoperative

mobile CT imaging.^{7,8,11} In addition, a robot-assisted technique has recently been developed.

Although the C-arm device is highly versatile and its use for fluoroscopy is widespread, the accuracy rate achieved with this system remains low (74.4–91.2%).^{4,7,19} The use of an O-arm as a support device designated for spinal surgery has spread in the past 10 years, as there are numerous advantages to this approach, including the ability to obtain intraoperative CT images after positioning the patient. Fluoroscopy is not necessary during screw insertion. The navigation system assists in reducing radiation exposure and achieving a higher accuracy rate (83.9–98.9%).^{8–11} In comparison, our MAU+ECD method is not coupled with a navigation system, and thus, it is impossible to avoid radiation exposure during surgery. On the other hand, pedicle screw placement is performed in a “virtual reality” setting, as long as the images are obtained preoperatively (using a conventional preoperative CT + navigation method) or immediately before screw placement (with intraoperative CT images obtained with the O-arm and AIRO with navigation). Thus, misalignment with the image taken before the procedure and the actual position could occur because the load is applied during puncture with the Jamshidi needle; this may be a factor in inaccurate screw placement.

Recently, a robotic surgical system that can perform screw insertion has been developed, and these robot systems can perform insertions with high accuracy. However, for the reasons mentioned above, a perfect operation remains impossible. Implementation of artificial intelligence (AI) that could correct positioning may resolve this problem. Furthermore, devices such as the O-arm, AIRO, or other robotic systems involve substantial cost, and it is difficult for many facilities to introduce such systems. In this respect, a hybrid operation room with a MAU, such as the one we use, allows the performance of a broad range of surgeries, including cardiovascular surgery, neurosurgical vascular or endovascular surgery, and orthopedic surgery, without substantial added cost.^{14,15} Additionally, screw placement can be performed using real-time sound and visual data provided from the ECD and MAU, and taking intraoperative CT-like images immediately after screw placement is also possible so that the screw position and the accuracy of the screw position are determined timeously.^{14,15,18} Our results provide evidence of the efficiency of this method.

Considering this evidence, intraoperative CT imaging for navigation, real-time MAU fluoroscopy with auditory information from an ECD, and robot support with AI revision managing all of these data, would allow efficient insertion of PPSs.

This study had some limitations. This was a single-center retrospective study with a small number of cases. The number of the patients was smaller in the C-arm group after introducing the MAU and ECD, which may be due the operator’s impression in terms of accuracy in screw placement. So, MAU and ECD were used preferentially if the room was available. Selection of surgical methods was chronologically different as a result; therefore, our results need to be interpreted carefully. Further study is necessary to examine the effectiveness of the procedure in prospective, multi-center studies with a larger number of cases and a longer follow-up period.

Conclusion

The present study suggested that significantly more accurate PPS placement in the lumbar spine can be attained when combining MAU and ECD than when using conventional C-arm fluoroscopy. Furthermore, using the MAU and ECD together, performance levels could improve to the same level as that achieved with O-arm navigation and robotic-assisted surgery. The combination of a MAU and ECD might be a safe and accurate method for inserting screws into the pedicle in lumbar fixation surgery.

Conflicts of Interest Disclosure

All authors have no conflict of interest.

References

- 1) Herren C, Reijnen M, Pishnamaz M, et al.: Incidence and risk factors for facet joint violation in open versus minimally invasive procedures during pedicle screw placement in patients with trauma. *World Neurosurg* 112: e711–e718, 2018
- 2) Archavlis E, Amr N, Kantelhardt SR, Giese A: Rates of upper facet joint violation in minimally invasive percutaneous and open instrumentation: a comparative cohort study of different insertion techniques. *J Neurol Surg A Cent Eur Neurosurg* 79: 1–8, 2018
- 3) Heo DH, Jang JW, Lee JK, Park CK: Slippage reduction of lumbar spondylolisthesis using percutaneous pedicle screw with reduction fixation system after interbody fusion: A comparison with traditional open fusion and pedicle screw fixation. *J Clin Neurosci* 67: 156–162, 2019
- 4) Nottmeier EW, Crosby T: Timing of vertebral registration in three-dimensional, fluoroscopy-based, image-guided spinal surgery. *J Spinal Disord Tech* 22: 358–360, 2009
- 5) Hecht N, Yassin H, Czabanka M, et al.: Intraoperative computed tomography versus 3D C-arm imaging for navigated spinal instrumentation. *Spine (Phila Pa 1976)* 43: 370–377, 2018

- 6) Chang CJ, Lin GL, Tse A, Chu HY, Tseng CS: Registration of 2D C-arm and 3D CT images for a C-arm image-assisted navigation system for spinal surgery. *Appl Bionics Biomech* 2015: 478062, 2015
- 7) Feng W, Wang W, Chen S, Wu K, Wang H: O-arm navigation versus C-arm guidance for pedicle screw placement in spine surgery: a systematic review and meta-analysis. *Int Orthop* 44: 919–926, 2020
- 8) Santos ER, Ledonio CG, Castro CA, Truong WH, Sembrano JN: The accuracy of intraoperative O-arm images for the assessment of pedicle screw position. *Spine (Phila Pa 1976)* 37: E119–125, 2012
- 9) Pitteloud N, Gamulin A, Barea C, Damet J, Racloz G, Sans-Merce M: Radiation exposure using the O-arm® surgical imaging system. *Eur Spine J* 26: 651–657, 2017
- 10) Scarone P, Vincenzo G, Distefano D, et al.: Use of the Airo mobile intraoperative CT system versus the O-arm for transpedicular screw fixation in the thoracic and lumbar spine: a retrospective cohort study of 263 patients. *J Neurosurg Spine* 29: 397–406, 2018
- 11) Farah K, Coudert P, Graillon T, et al.: Prospective comparative study in spine surgery between O-arm and airo systems: efficacy and radiation exposure. *World Neurosurg* 118: e175–e184, 2018
- 12) Li HM, Zhang RJ, Shen CL: Accuracy of pedicle screw placement and clinical outcomes of robot-assisted technique versus conventional freehand technique in spine surgery from nine randomized controlled trials: a meta-analysis. *Spine (Phila Pa 1976)* 45: E111–E119, 2020
- 13) Siddiqui MI, Wallace DJ, Salazar LM, Vardiman AB: Robot-assisted pedicle screw placement: learning curve experience. *World Neurosurg* 130: e417–e422, 2019
- 14) Richter PH, Yarboro S, Kraus M, Gebhard F: One year orthopaedic trauma experience using an advanced interdisciplinary hybrid operating room. *Injury* 46: S129–S134, 2015
- 15) Kageyama H, Yoshimura S, Uchida K, Iida T: Advantages and disadvantages of multi-axis intraoperative angiography unit for percutaneous pedicle screw placement in the lumbar spine. *Neurol Med Chir (Tokyo)* 57: 481–488, 2017
- 16) Guillen PT, Knopper RG, Kroger J, Wycliffe ND, Danisa OA, Cheng WK: Independent assessment of a new pedicle probe and its ability to detect pedicle breach: a cadaveric study. *J Neurosurg Spine* 21: 821–825, 2014
- 17) Chaput CD, George K, Samdani AF, Williams JI, Gaughan J, Betz RR: Reduction in radiation (fluoroscopy) while maintaining safe placement of pedicle screws during lumbar spine fusion. *Spine (Phila Pa 1976)* 37: E1305–1309, 2012
- 18) Bolger C, Kelleher MO, McEvoy L, et al.: Electrical conductivity measurement: a new technique to detect iatrogenic initial pedicle perforation. *Eur Spine J* 16: 1919–1924, 2007
- 19) Nakahara M, Yasuhara T, Inoue T, et al.: Accuracy of percutaneous pedicle screw insertion technique with conventional dual fluoroscopy units and a retrospective comparative study based on surgeon experience. *Global Spine J* 6: 322–328, 2016
- 20) Gertzbein SD, Robbins SE: Accuracy of pedicular screw placement in vivo. *Spine (Phila Pa 1976)* 15: 11–14, 1990
- 21) Koktekir E, Ceylan D, Tatarli N, Karabagli H, Reber F, Akdemir G: Accuracy of fluoroscopically-assisted pedicle screw placement: analysis of 1,218 screws in 198 patients. *Spine J* 14: 1702–1708, 2014
- 22) Açıkbay SC, Arslan FY, Tuncer MR: The effect of transpedicular screw misplacement on late spinal stability. *Acta Neurochir (Wien)* 145: 949–954; discussion 954–955, 2003
- 23) Zeller R, Canavese F, Kulkarni AV, Drake J: Technique for drilling instrument monitoring electrical conductivity in pediatric cervical spine screw insertion: a preliminary report. *J Pediatr Orthop* 29: 760–764, 2009
- 24) Kageyama H, Yoshimura S, Matsuda K, Yoshida Y, Matsukawa H, Yamada K: Usefulness of a new electronic conductivity device with a pedicle probe and a multi-axis angiography unit for inserting a C1 lateral mass screw safely and tightly: a technical note. *Neurol Med Chir* 59: 523–528, 2019
- 25) Sandhu FA, McGowan JE, Felbaum DR, Syed HR, Mueller KB: S2-AI screw placement with the aide of electronic conductivity device monitoring: a retrospective analysis. *Eur Spine J* 26: 2941–2950, 2017
- 26) Bohoun CA, Naito K, Yamagata T, Tamrakar S, Ohata K, Takami T: Safety and accuracy of spinal instrumentation surgery in a hybrid operating room with an intraoperative cone-beam computed tomography. *Neurosurg Rev* 42: 417–426, 2019

Corresponding author: Shinichi Yoshimura, MD, PhD
 Department of Neurosurgery, Hyogo College of Medicine, 1-1 Mukogawacho Nishinomiya, Hyogo, Japan.
e-mail: hyogoneuro@yahoo.co.jp