

Microfracture in Hip Arthroscopy. Keep It Simple!



David R. Maldonado, M.D., Jeffrey W. Chen, B.A., Ajay C. Lall, M.D., M.S.,
Cynthia Kyin, B.A., Rafael Walker-Santiago, M.D., Jacob Shapira, M.D.,
Philip J. Rosinsky, M.D., and Benjamin G. Domb, M.D.

Abstract: Despite all the advances in hip arthroscopy, microfracture is still the workhorse for treating focal and full-thickness cartilage lesions. The success of this treatment is owed to its reliability and simplicity. Given the structure of the hip joint, however, there are challenges to this procedure using a conventional microfracture pick. This note presents our current and preferred microfracture technique using a curve drill guide and flexible drill. This method offers greater range of access to different regions of the joint with ease, thus ensuring a reproducible and quicker procedure with less risk.

The goal with the microfracture is to promote migration of stem cells and growth factors from beneath the subchondral bone plate into the cartilage defect, which eventually heals to form fibrocartilage.¹⁻³ Currently, many options have been put forth for the treatment of severe chondral lesions, yet

microfracture remains as a popular choice mainly for its simplicity.^{2,4-9} The basics of performing the techniques has been developed for years in knee surgery. The anatomic complexity imparted by the “ball-and-socket” joint brings unique challenges when using the standard microfracture awl.^{10,11} The “angle

From the American Hip Institute, Des Plaines, Illinois, U.S.A.

The authors report the following potential conflict of interest or source of funding: B.G.D. reports grants and other from American Orthopedic Foundation, during the conduct of the study; personal fees from Adventist Hinsdale Hospital, personal fees and non-financial support from Amplitude, grants, personal fees and non-financial support from Arthrex, personal fees and non-financial support from DJO Global, grants from Kaufman Foundation, grants, personal fees and non-financial support from Medacta, grants, personal fees, non-financial support and other from Pacira Pharmaceuticals, grants, personal fees, non-financial support and other from Stryker, grants from Breg, personal fees from Orthomerica, grants, personal fees, non-financial support and other from Mako Surgical Corp, grants and non-financial support from Midwest Associates, grants from ATI Physical Therapy, grants, personal fees and non-financial support from St. Alexius Medical Center, grants from Ossur, outside the submitted work. In addition, Dr. Domb has a patent 8920497 - Method and instrumentation for acetabular labrum reconstruction with royalties paid to Arthrex, a patent 8708941 - Adjustable multi-component hip orthosis with royalties paid to Orthomerica and DJO Global, and a patent 9737292 - Knotless suture anchors and methods of tissue repair with royalties paid to Arthrex and Dr. Domb is the Medical Director of Hip Preservation at St. Alexius Medical Center, a board member for the American Hip Institute Research Foundation, AANA Learning Center Committee, the Journal of Hip Preservation Surgery, the Journal of Arthroscopy; has had ownership interests in the American Hip Institute, Hinsdale Orthopedic Associates, Hinsdale Orthopedic Imaging, SCD#3, North Shore Surgical Suites, and Munster Specialty Surgery Center. A.C.L. reports grants, personal fees and non-financial support from Arthrex, non-financial support from Iroko, non-financial support from Midwest, non-financial support from Smith & Nephew, grants and non-financial support from Stryker, non-financial support from Vericel, non-financial support from Zimmer Biomet, personal fees from Graymont Medical, outside the submitted work. D.R.M. reports non-

financial support from Arthrex, non-financial support from Stryker, non-financial support from Smith & Nephew, non-financial support from Ossur, outside the submitted work; and Dr. Maldonado is an editorial board member of the Journal of Arthroscopy. J.S. reports non-financial support from Arthrex, non-financial support from Stryker, non-financial support from Smith & Nephew, non-financial support from Ossur, outside the submitted work. P.J.R. reports non-financial support from Arthrex, non-financial support from Stryker, non-financial support from Smith & Nephew, non-financial support from Ossur, outside the submitted work. R.W-S. reports non-financial support from Encore Medical, non-financial support from Globus Medical, non-financial support from Acumed LLC, non-financial support from Depuy Synthes Sales, non-financial support from Medical Device Business Services, non-financial support from Johnson and Johnson International, non-financial support from Smith & Nephew, non-financial support from DJO, non-financial support from Covidien Caribbean, non-financial support from Biomechanical Pharmaceutical, non-financial support from Arthrex, non-financial support from Stryker, non-financial support from Ossur, outside the submitted work. Full ICMJE author disclosure forms are available for this article online, as [supplementary material](#).

Research conducted at the American Hip Institute, Des Plaines, IL.

Received April 11, 2019; accepted May 14, 2019.

Address correspondence to Dr. Benjamin G. Domb, M.D., American Hip Institute, 999 E Touhy Ave, Suite 450, Des Plaines, IL 60018, U.S.A. E-mail: DrDomb@americanhipinstitute.org

© 2019 by the Arthroscopy Association of North America. Published by Elsevier. This is an open access article under the CC BY-NC-ND license (<http://creativecommons.org/licenses/by-nc-nd/4.0/>).

2212-6287/19490

<https://doi.org/10.1016/j.eats.2019.05.020>

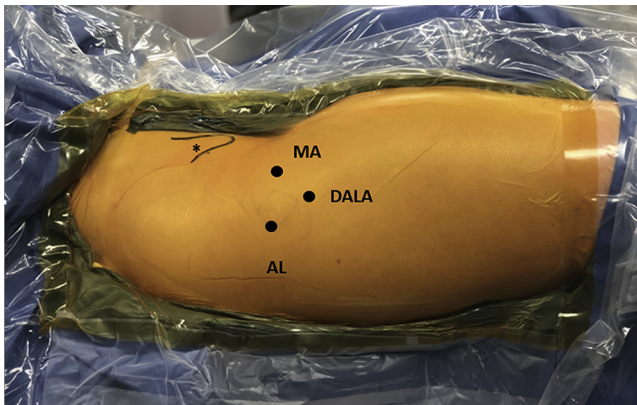


Fig 1. Patient in modified supine position. Right hip, patient's head is to the right and feet to the right, anterior superior iliac spine is marked (*). Portals are identified: anterolateral (AL), mid-anterior (MA), and distal anterolateral accessory (DALA).

of attack" with the awl is difficult to maintain, or even obtain, during the process. As a result, the surgeon risks slippage of the pick tip, which compromises the procedure. We present our arthroscopic microfracture technique using a curve drilling guide and flexible drill, which make this procedure reproducible and efficient.

Surgical Technique

Patient Preparation and Positioning

After being sedated under general anesthesia, the patient is placed in the modified supine position on the traction table (Supine Hip Positioning System; Smith & Nephew, Andover, MA) with an extra-padded post. Manual bilateral leg traction is applied to achieve full contact between the perineum and the post. The operative leg is positioned to neutral rotation and

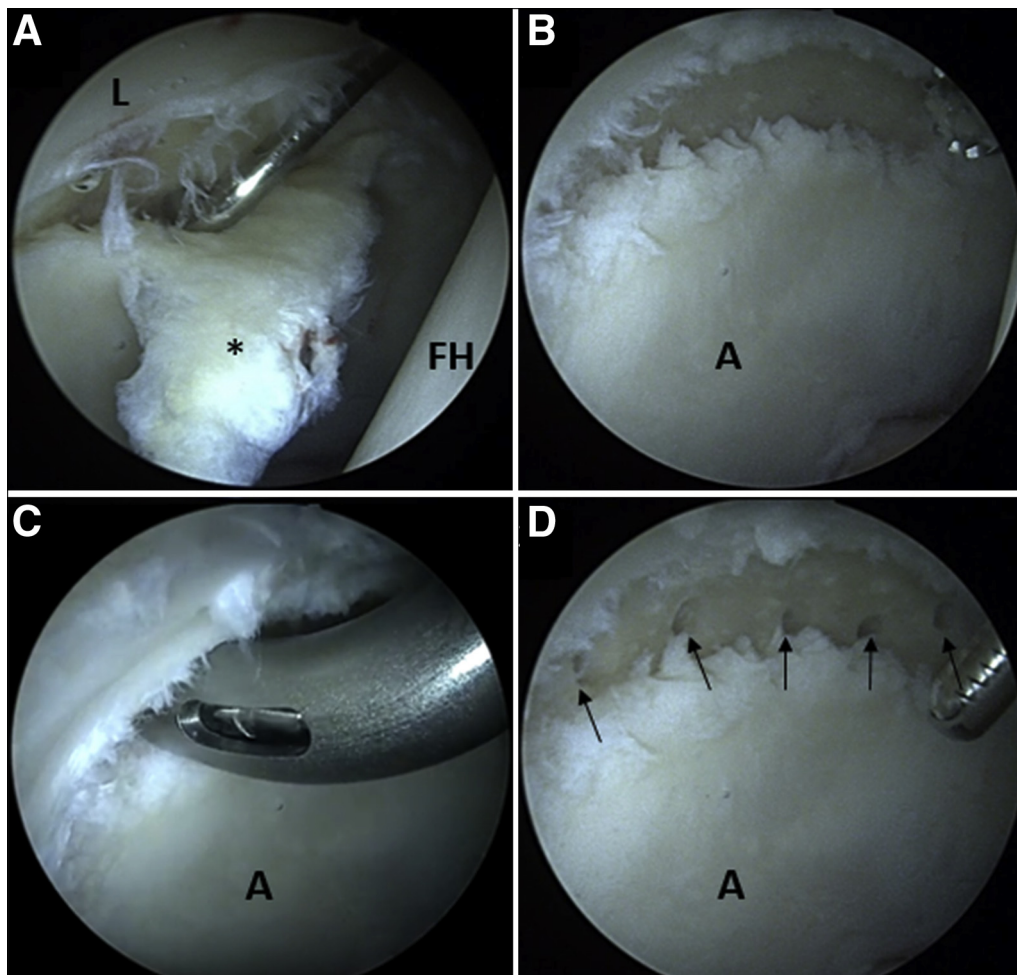


Fig 2. Intraoperative view from the anterolateral portal with the 70° arthroscope in a right hip. (A) During the diagnostic assessment, a large unviable chondral flap is found (*), and the probe from the mid-anterior portal is pointing to the cartilage defect. (B) Chondral flap has been removed. Bone-bed is prepared by stabilizing borders of the defect and removing the calcified layer. (C) While still viewing from the anterolateral portal, the 70° curve drill is inserted through the distal anterolateral accessory portal. The face of the curved guide sits perpendicular and flush to the bone-bed surface. (D) The final microfractured holes (black arrows) are shown. (A, acetabulum; FH, femoral head; L, labrum.)

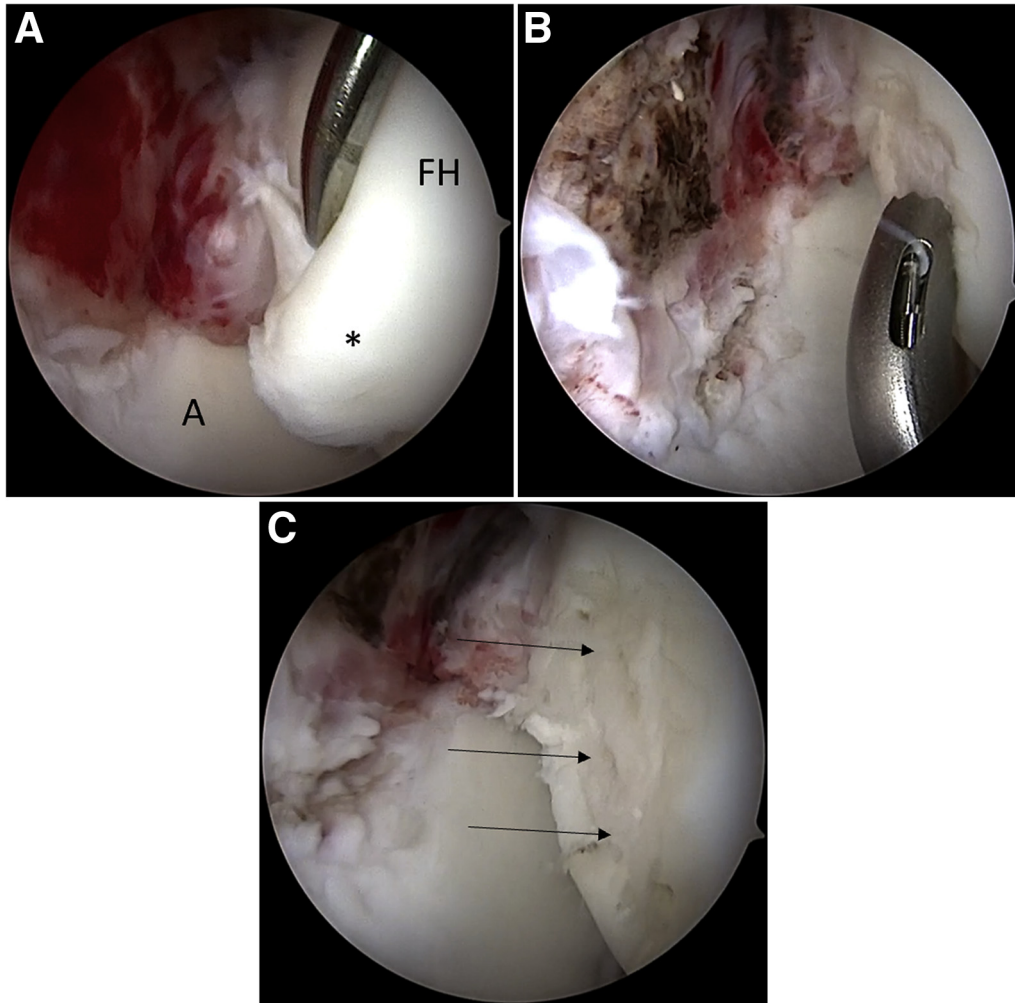


Fig 3. Intraoperative view from the anterolateral portal with the 70° arthroscope in a right hip with a chondral damage to the femoral head. (A) During the diagnostic assessment, an unstable chondral lesion on the femoral head is found (*). (B) Unstable cartilage has been removed and the borders of the defect are stabilized. The face of the 90° curved drill guide is placed flush to the subchondral bone. (C) The final holes (black arrows) are shown. (A, acetabulum; FH, femoral head.)

adduction, and the nonoperative leg is placed in 30° of abduction. The operative table is transitioned to 8° to 10° of Trendelenburg inclination.¹²

Fluoroscopy Technique

The C-arm is positioned on the nonoperative side of the patient and draped in sterile fashion. To obtain a true anteroposterior image of the pelvis, tilt the C-arm to

compensate for the Trendelenburg inclination. Under fluoroscopy, the joint seal is broken and traction applied.¹³

Portals Placement

With the anterior superior iliac spine as an anatomic reference and fluoroscopic assessment, the anterolateral portal is created. Subsequent visualization using the 70° arthroscope will be used through this portal. The mid-

Table 1. Surgical Indications and Contraindications

Indications	Contraindications
<ul style="list-style-type: none"> • Focal and full-thickness cartilage lesion 	<ul style="list-style-type: none"> • Extensive cartilage defect, over 2 cm² • Patients unwilling to commit to the required and specific postoperative management

Table 2. Advantages and Disadvantages

Advantages	Disadvantages
<ul style="list-style-type: none"> • Expedient • Cost-effective • Simple to perform • Skiving is prevented 	<ul style="list-style-type: none"> • Extended recovery time • Fibrocartilage instead of hyaline cartilage • Benefits may decrease at mid and long term

Table 3. Pearls and Pitfalls

Pearls	Pitfalls
<ul style="list-style-type: none"> • Prepare acetabular bone-bed and microfracture drilling before anchor drilling for labral treatment. • Restore labral functionality with a repair or reconstruction so to “seal” the bone marrow clot. • Before committing to drill, try different angles of approach from either the MA or DALA portals. 	<ul style="list-style-type: none"> • Inadequate bone-bed preparation, failing to remove calcified layer. • Inadequate space between drill holes may increase the risk of fractures. • Placing the drill on reverse may while retrieving the bit may increase the risk of the bit breaking in the joint.

DALA, distal anterolateral accessory; MA, mid-anterior.

anterior and distal anterolateral accessory portal are created and used for working portals (Fig 1).¹³

Diagnostic Arthroscopy and Cartilage Assessment

A methodical diagnostic arthroscopy is performed. The ligamentum teres, acetabular notch, iliopsoas impingement sign, labral/chondrolabral junction condition, and femoral and acetabular cartilage are all assessed. Microfracture is indicated if the cartilage defect exposures subchondral bone, categorized as Outerbridge lesion IV (Figs 2 and 3).^{11,14,15}

Acetabular Microfracture Technique

According to preoperative planning and intraoperative findings, perform any acetabular rim trimming before microfracture drilling. If labral repair, reconstruction, or augmentation is needed, drill holes for the anchors after the microfracture. If a chondral defect is noted and fulfills criteria for microfracture (Table 1), proceed as follows.

Bone-Bed Preparation

First, remove all unviable and unstable cartilage around the edges of the defect with a shaver. Using a ring curette, scrape away loose cartilage to create perpendicular borders around the chondral lesion site. The same should be done to the calcified layer (Video 1).

Microfracture Drilling

Once the lesion site is prepared, the MicroFX OCD Osteochondral Drill System (Stryker, Kalamazoo, MI) is used. The 70° curved drill guide is introduced into the joint from either the mid-anterior or distal anterolateral accessory portal, which ever offers a perpendicular drilling trajectory relative to the bone-bed. Before drilling, ensure that that the drill bit is (1) centered and (2) assembled to reach the desired depth.

During the procedure, the arthroscope should be held by the assistant so that the surgeon can maneuver in

one hand the curved drill guide and in the other the drill. Start from the periphery of defect and work towards the center, placing the holes 3 to 4 mm apart to avoid subchondral plate fractures (Video 1). During this process, the drill should exclusively be set on the forward speed. Keep the drill on forward while retrieving from the hole. This will reduce the risk of breaking the drill bit.

After drilling, use the shaver to remove debris that may have accumulated in the joint during drilling. Cease the fluid irrigation pump to ensure bleeding from each one of the microfractured holes (Video 1).

Postoperative Rehabilitation

The patient is placed in a brace (X-Act ROM Hip Brace; Donjoy, Vista, CA) for 8 weeks. In addition, use of crutches is encouraged for 8 weeks with weight-bearing restriction of up to 20% body weight.⁶ Gentle passive range-of-motion exercise is initiated during the first week, under the supervision of a physiotherapist.

Discussion

The purpose of this technique is to offer an alternative to accomplish the microfracture procedure in such a way that overcomes the challenges of accessing regions of a joint with high surface curvature. Our indications and contraindications are described in Table 1. To achieve a reproducible and lower-risk procedure, a curved guide with a flexible drill is used to reach angles without the creation of additional portals beyond the standard ones for hip arthroscopy. Additional advantages and disadvantages are presented in Table 2. In a recent systematic review, MacDonald et al.¹⁶ concluded that favorable outcomes can be achieved after microfracture in hip arthroscopy but noted concerns regarding the potential formation of subchondral cyst.^{1,10,16}

Domb et al.⁶ published result with minimum 5-year follow-up after hip arthroscopy with microfracture for patients with symptomatic labral tears and femoroacetabular impingement. The authors reported that sustained and significant improvement in several patient-reported outcomes. Moreover, the authors also found that the outcomes did depreciate compared with those recorded at 2 years.

Table 4. Risks

<ul style="list-style-type: none"> • Subchondral plate fracture • Subchondral cyst formation • Drill bit breaking during drilling
--

Microfracture in hip arthroscopy offers a feasible alternative for the management of certain types of severe cartilage defects.^{17,18} Nevertheless, acknowledging the demanding nature of this arthroscopic procedure, attention to details is vital (Table 3). Furthermore, risks must be recognized and considered (Table 4).

References

- Green CJ, Beck A, Wood D, Zheng MH. The biology and clinical evidence of microfracture in hip preservation surgery. *J Hip Preserv Surg* 2016;3:108-123.
- Marquez-Lara A, Mannava S, Howse EA, Stone AV, Stubbs AJ. Arthroscopic management of hip chondral defects: A systematic review of the literature. *Arthroscopy* 2016;32:1435-1443.
- O'Connor M, Minkara AA, Westermann RW, Rosneck J, Lynch TS. Outcomes of joint preservation procedures for cartilage injuries in the hip: A systematic review and meta-analysis. *Orthop J Sports Med* 2018;6:2325967118776944.
- Domb BG, Gupta A, Dunne KF, Gui C, Chandrasekaran S, Lodhia P. Microfracture in the hip: Results of a matched-cohort controlled study with 2-year follow-up. *Am J Sports Med* 2015;43:1865-1874.
- Domb BG, El Bitar YF, Lindner D, Jackson TJ, Stake CE. Arthroscopic hip surgery with a microfracture procedure of the hip: Clinical outcomes with two-year follow-up. *Hip Int* 2014;24:448-456.
- Domb BG, Rybalko D, Mu B, Litrenta J, Chen AW, Perets I. Acetabular microfracture in hip arthroscopy: Clinical outcomes with minimum 5-year follow-up. *Hip Int* 2018;28:649-656.
- Lodhia P, Gui C, Chandrasekaran S, Suarez-Ahedo C, Vemula SP, Domb BG. Microfracture in the hip: A matched-control study with average 3-year follow-up. *J Hip Preserv Surg* 2015;2:417-427.
- Becher C, Malahias MA, Ali MM, Maffulli N, Thermann H. Arthroscopic microfracture vs. arthroscopic autologous matrix-induced chondrogenesis for the treatment of articular cartilage defects of the talus. *Knee Surg Sports Traumatol Arthrosc* 2018 [Epub ahead of print].
- Fontana A, de Girolamo L. Sustained five-year benefit of autologous matrix-induced chondrogenesis for femoral acetabular impingement-induced chondral lesions compared with microfracture treatment. *Bone Joint J* 2015;97-B:628-635.
- Lubowitz JH. Editorial Commentary: Microfracture for focal cartilage defects: Is the hip like the knee? *Arthroscopy* 2016;32:201-202.
- Trask DJ, Keene JS. Analysis of the current indications for microfracture of chondral lesions in the hip joint. *Am J Sports Med* 2016;44:3070-3076.
- Maldonado DR, LaReau JM, Lall AC, Battaglia MR, Mohr MR, Domb BG. Concomitant arthroscopy with labral reconstruction and periacetabular osteotomy for hip dysplasia. *Arthrosc Tech* 2018;7:e1141-e1147.
- Domb B, Hanypsiak B, Botser I. Labral penetration rate in a consecutive series of 300 hip arthroscopies. *Am J Sports Med* 2012;40:864-869.
- Outerbridge RE. The etiology of chondromalacia patellae. *J Bone Joint Surg Br* 1961;43-B:752-757.
- Cameron ML, Briggs KK, Steadman JR. Reproducibility and reliability of the outerbridge classification for grading chondral lesions of the knee arthroscopically. *Am J Sports Med* 2003;31:83-86.
- MacDonald AE, Bedi A, Horner NS, et al. Indications and outcomes for microfracture as an adjunct to hip arthroscopy for treatment of chondral defects in patients with femoroacetabular impingement: A systematic review. *Arthroscopy* 2016;32:190-200.e2.
- Crawford K, Philippon MJ, Sekiya JK, Rodkey WG, Steadman JR. Microfracture of the hip in athletes. *Clin Sports Med* 2006;25:327-335.
- Karthikeyan S, Roberts S, Griffin D. Microfracture for acetabular chondral defects in patients with femoroacetabular impingement: Results at second-look arthroscopic surgery. *Am J Sports Med* 2012;40:2725-2730.