



Progressive Neuronal Loss in Epilepsy – A Long-Standing Conundrum Finally Resolved?

Epilepsy Currents
2021, Vol. 21(5) 366–368
© The Author(s) 2021
Article reuse guidelines:
sagepub.com/journals-permissions
DOI: 10.1177/15357597211030385
journals.sagepub.com/home/epi
 SAGE

Recurrent Limbic Seizures do not Cause Hippocampal Neuronal Loss: A Prolonged Laboratory Study

Mathern GW, and Bertram EH, 3rd. *Neurobiol Dis.* 2021;148:105183.

Purpose: It remains controversial whether neuronal damage and synaptic reorganization found in some forms of epilepsy are the result of an initial injury and potentially contributory to the epileptic condition or are the cumulative effect of repeated seizures. A number of reports of human and animal pathology suggest that at least some neuronal loss precedes the onset of seizures, but there is debate over whether there is further damage over time from intermittent seizures. In support of this latter hypothesis are MRI studies in people that show reduced hippocampal volumes and cortical thickness with longer durations of the disease. In this study we addressed the question of neuronal loss from intermittent seizures using kindled rats (no initial injury) and rats with limbic epilepsy (initial injury). **Methods:** Supragranular mossy fiber sprouting, hippocampal neuronal densities, and subfield area measurements were determined in rats with chronic limbic epilepsy (CLE) that developed following an episode of limbic status epilepticus (n = 25), in kindled rats (n = 15), and in age matched controls (n = 20). To determine whether age or seizure frequency played a role in the changes, CLE and kindled rats were further classified by seizure frequency (low/high) and the duration of the seizure disorder (young/old). **Results:** Overall there was no evidence for progressive neuronal loss from recurrent seizures. Compared with control and kindled rats, CLE animals showed increased mossy fiber sprouting, decreased neuronal numbers in multiple regions and regional atrophy. In CLE, but not kindled rats: (1) Higher seizure frequency was associated with greater mossy fiber sprouting and granule cell dispersion; and (2) greater age with seizures was associated with decreased hilar densities, and increased hilar areas. There was no evidence for progressive neuronal loss, even with more than 1000 seizures. **Conclusion:** These findings suggest that the neuronal loss associated with limbic epilepsy precedes the onset of the seizures and is not a consequence of recurrent seizures. However, intermittent seizures do cause other structural changes in the brain, the functional consequences of which are unclear.

Keywords

hippocampal sclerosis, mossy fiber sprouting, neurodegeneration, status epilepticus, animal models, synaptic reorganization, neural plasticity

Commentary

It has been known for over 100 years that neurons degenerate in specific brain regions in some patients with epilepsy.¹ Perhaps the most prominent example is that of hippocampal sclerosis, which features neuronal loss, glial proliferation, atrophy, and hardening (sclerosis) in subfields of the hippocampal formation, especially CA1, CA3, and CA4 (i.e., the hilus of the dentate gyrus).¹ Hippocampal sclerosis is commonly associated with mesial temporal lobe epilepsy, as approximately 50 to 60% of patients with medically refractory disease exhibit different phenotypes of this pathology.^{2,3} In a study of surgically resected hippocampal specimens from 151 patients with refractory mesial temporal lobe epilepsy, de Lanerolle et al³ reported that 60% of the cases exhibited hippocampal sclerosis, which the authors further divided into three subcategories based on

patterns of neuronal loss and dynorphin staining (a biomarker of axonal sprouting). In a later article, Blumcke² reviewed the hippocampal pathologies from a cohort of 4512 patients with refractory focal epilepsies of different types and found that 35% had hippocampal sclerosis. Among the patients with mesial temporal lobe epilepsy from this cohort (n = 3311), 48% exhibited hippocampal sclerosis, which the author subdivided into 5 categories based on different patterns of neuronal loss within the hippocampal formation.

What is the etiology of hippocampal sclerosis? Numerous studies using brain imaging and neuropathological assessments of tissue sections have clearly demonstrated that hippocampal sclerosis can be caused by a discrete insult to the brain, such as an episode of prolonged seizures (status epilepticus).^{4,5} For most strains of laboratory rats, it appears that at least 1-2 hours of status epilepticus are required for significant neuronal loss to



occur; however, the exact timing has been difficult to establish.⁶ While the patterns of neuronal loss caused by experimental status epilepticus vary greatly depending on the animal model, it is possible to elicit rodent pathologies that resemble human hippocampal sclerosis.⁵ Because status epilepticus can cause neurodegeneration, many have wondered whether long-term (months to years) exposure to habitual seizures (i.e., the patient's usual pattern of recurrent seizures) also leads to neuronal loss, including hippocampal sclerosis. This is an important question because continued neuronal loss may permanently impact brain function. However, current data on this topic are conflicting as some studies suggest that habitual seizures destroy neurons while others cannot establish such a link.


In an attempt to resolve this conundrum, Mathern and Bertram used laboratory rats to study the neuropathological consequences of chronic seizures in a carefully controlled and quantitative manner.⁷ Three groups of rats were analyzed: (1) animals with chronic limbic epilepsy caused by electrically induced status epilepticus ($n = 25$), (2) animals with kindling-induced seizures ($n = 15$), and (3) age-matched non-seizure controls ($n = 20$). Continuous video-intracranial electroencephalogram (EEG) recordings were used to record the number and frequency of spontaneous seizures in the rats with chronic limbic epilepsy. At the end of the study, histological sections of the hippocampal formation were assessed for the density of neurons within a subfield, the area of each subfield, and the degree of mossy fiber sprouting in the supragranular layer of the dentate gyrus (another biomarker of axonal plasticity). Because densities and areas were quantified, the authors could estimate the total number of neurons per subfield. Many earlier studies of "neuronal loss" in epilepsy and other brain conditions had relied on neuronal densities and assumed that decreased density meant fewer neurons. However, density is a measure of number per cross sectional area (or unit volume), and one cannot estimate total neuron number unless the total area (or volume) is known. This is an important distinction because brain volumes may decrease or increase in response to physiological and pathological conditions even though the absolute number of neurons remains the same.

The authors found no evidence that repeated limbic seizures caused neuronal loss in the hippocampus. This observation was based on the finding that increasing numbers of seizures did not result in progressive neuronal loss in either the kindling or the chronic epilepsy model. However, there were changes associated with higher seizure frequencies in the chronic epilepsy model, such as increased hilar area and increased mossy fiber sprouting. The kindled rats also had enhanced mossy fiber sprouting with increasing numbers of seizures. Collectively, these data suggest that while recurrent seizures do not cause progressive neuronal loss, they do cause other hippocampal pathologies.

There is ample evidence that many epilepsies continue to evolve over the lifespan. Patients may experience a change in their seizure phenotype or response to antiseizure drugs, and

some develop comorbid conditions such as cognitive decline, anxiety, and depression. If neuronal loss is not implicated in the progression of epilepsy, which pathology is important? Although we do not know the answer to this question, numerous alternative mechanisms have been proposed, including astrocyte dysfunction, neuroinflammation, microvascular alterations and blood-brain-barrier abnormalities, synaptic plasticity, aberrant neuronal activity, epigenetic changes, and metabolic perturbations. The possibilities are many and dramatically increase the complexity of the research; however, the encouraging aspect is that many more mechanisms may be targeted therapeutically, thereby increasing the likelihood of developing highly innovative antiepileptogenic and disease-modifying therapies. This is significant because no such therapy is currently approved for human use.

Mathern and Bertram present convincing evidence that recurrent seizures do not cause progressive neuronal loss in the hippocampus of laboratory rats; however, the study has limitations. First, the authors did not discriminate between different neuronal subtypes when quantifying the cell loss; thus, degeneration of small, but functionally significant neuronal populations may have been missed. Moreover, neurodegeneration in mesial temporal lobe epilepsy often extends to regions beyond the hippocampus proper, such as the entorhinal cortex and amygdala,⁸ and possible neuronal losses in these regions were not considered. Second, humans and laboratory rats are different in many respects, including neuroanatomy and brain development, metabolism, immunology, comorbid conditions, and exposure to antiseizure drugs. It is quite possible that brain neurons in humans may be more vulnerable to recurrent seizures than rat neurons because of these factors, meaning that the rat results may not translate to human patients with epilepsy. Additional studies are therefore needed to resolve these issues.

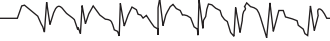By Tore Eid 

ORCID iD

Tore Eid  <https://orcid.org/0000-0001-9217-6393>

References

1. Sommer W. Erkrankung des Ammonshorns als aetiologisches Moment der Epilepsie. *Archiv f. Psychiatrie*. 1880;10:631-675.
2. Blümcke I. Neuropathology of focal epilepsies: a critical review. *Epilepsy Behav*. 2009;15:34-39.
3. de Lanerolle NC, Kim JH, Williamson A, et al. A retrospective analysis of hippocampal pathology in human temporal lobe epilepsy: evidence for distinctive patient subcategories. *Epilepsia*. 2003;44:677-687.
4. Lewis DV, Shinnar S, Hesdorffer DC, et al. Hippocampal sclerosis after febrile status epilepticus: the FEBSTAT study. *Ann Neurol*. 2014;75:178-185.
5. Norwood BA, Bumanglag AV, Osculati F, et al. Classic hippocampal sclerosis and hippocampal-onset epilepsy produced by a



- single “cryptic” episode of focal hippocampal excitation in awake rats. *J Comp Neurol.* 2010;518:3381-3407.
6. Brandt C, Töllner K, Klee R, Bröer S, Löscher W. Effective termination of status epilepticus by rational polypharmacy in the lithium-pilocarpine model in rats: window of opportunity to prevent epilepsy and prediction of epilepsy by biomarkers. *Neurobiol Dis.* 2015;75:78-90.
 7. Mathern GW, Bertram EH 3rd. Recurrent limbic seizures do not cause hippocampal neuronal loss: a prolonged laboratory study. *Neurobiol Dis.* 2021;148:105183.
 8. Du F, Whetsell WO Jr., Abou-Khalil B, Blumenkopf B, Lothman EW, Schwarcz R. Preferential neuronal loss in layer III of the entorhinal cortex in patients with temporal lobe epilepsy. *Epilepsy Res.* 1993;16:223-233.