

Rapidly formed right ventricular thrombus detected by intracardiac echocardiography before catheter ablation in a case of arrhythmogenic right ventricular cardiomyopathy



Masahiro Nakano, MD, Yoshiaki Yamaguchi, MD, PhD, Daisuke Kutsuzawa, MD, PhD, Koji Kumagai, MD, PhD

From the Division of Cardiology, Gunma Prefectural Cardiovascular Center, Gunma, Japan.

Introduction

A right ventricular thrombus with ARVC is very rare compared with left ventricular thrombus in patients with left ventricular dysfunction. Here, we reported a case of ARVC associated with a rapidly formed right ventricular thrombus.

Case study

A 40-year-old male was diagnosed with arrhythmogenic right ventricular cardiomyopathy (ARVC) 10 years ago. He received radiofrequency catheter ablation of ventricular tachycardia (VT) and an implantable cardioverter-defibrillator (ICD) 3 years ago. The patient was referred to our hospital because he experienced presyncope during light exercise. After using ICD check to confirm the use of shock therapy 7 times for VT, we scheduled a catheter ablation. As preoperative examinations, transthoracic echocardiography (TTE) and contrast-enhanced computed tomography (CT) were performed 7 and 3 days prior to the scheduled catheter ablation, respectively. The CT image was acquired at the timing optimized for opacification of right heart structures using a test bolus technique. However, no right ventricular thrombus was detected in these examinations.

At the beginning of the ablation procedure, a single bolus of 5000 U of heparin was administered. Two 5F electrode catheters were inserted into the inferior vena cava via the right femoral vein, and we tried to visualize the right ventricle using intracardiac echocardiography (ICE) merged with CT. Thereafter, the fusion image revealed a large thrombus in the right

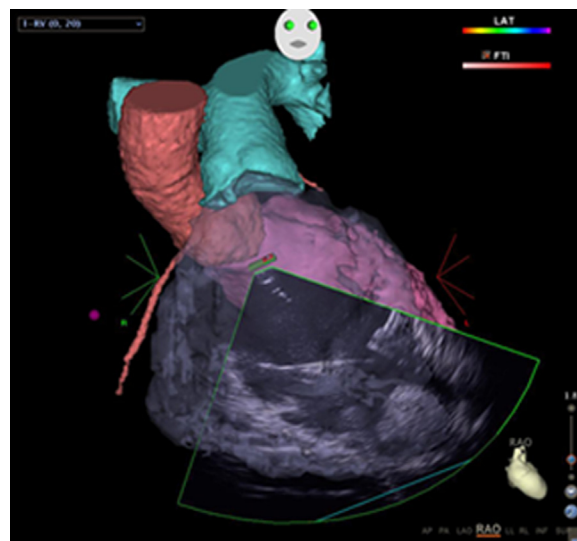


Figure 1 An image of the right ventricle created using intracardiac echocardiography merged with computed tomography. The fusion image reveals a large thrombus in the right ventricular apex.

ventricular apex (Figure 1). Further, TTE results confirmed a thrombus of a maximum diameter of 3 cm in the right ventricular apex. We withdrew the session because of the risk of thromboembolism caused by catheter manipulation in the right ventricle. Instead, we administered anticoagulation therapy using heparin and warfarin with deep sedation. As a result, the large thrombus gradually decreased and was eliminated within a week. We confirmed that there were no defects in the pulmonary blood flow by pulmonary blood flow scintigraphy 20 days after the first session. Twenty-three days after the first session, successful catheter ablation of VT was performed without incidence, with anticoagulation therapy.

Here, we reported a case of ARVC associated with a rapidly formed right ventricular thrombus. It was previously reported that a right ventricular thrombus with ARVC is very rare compared with left ventricular thrombus in patients with left ventricular dysfunction.¹ Therefore, there is no clear indication for anticoagulant therapy in ARVC patients.² However, pulmonary thromboembolism due to a large

KEYWORDS Right ventricular thrombus; Intracardiac echocardiography; Catheter ablation; Arrhythmogenic right ventricular cardiomyopathy

ABBREVIATIONS ARVC = arrhythmogenic right ventricular cardiomyopathy; CT = computed tomography; ICE = intracardiac echocardiography; ICD = implantable cardioverter-defibrillator; TTE = transthoracic echocardiography; VT = ventricular tachycardia (Heart Rhythm Case Reports 2015;1:384–385)

Conflicts of interest: The authors report no conflicts of interest. **Address reprint requests and correspondence:** Dr. Masahiro Nakano, Division of Cardiology, Gunma Prefectural Cardiovascular Center, 3-12 Kameizumimachi-kou, Maebasi 371-0004, Japan. E-mail address: masahiro.masap@yahoo.co.jp.

KEY TEACHING POINTS

- We reported a case of arrhythmogenic right ventricular cardiomyopathy (ARVC) associated with a right ventricular thrombus rapidly formed in few days after preoperative examinations.
- It has been reported that a right ventricular thrombus with ARVC is very rare. However, pulmonary thromboembolism due to a large thrombus may be fatal.
- To avoid embolism, intracardiac echocardiography or a more-focused transthoracic echocardiography to evaluate for any right ventricular thrombus just before ablation may be required, even in patients with ARVC.

thrombus may be fatal. In the present case, a large thrombus rapidly formed in a few days. Incessant VT or frequent ICD shock therapy may be responsible for the further decrease in the right ventricular function, leading to the rapid formation of the thrombus.

It has been reported that ICE can identify anatomical substrates of VT in the right ventricle, such as focal aneurysm, and can contribute to successful catheter ablation of the right ventricle.³ It is thought that CT has a higher diagnostic ability for right ventricular apical pathology compared with that of intracardiac echocardiography. However, ICE is useful in that real-time images can be obtained during the ablation procedure. If we had started the ablation without ICE, fatal pulmonary embolism may have occurred. Therefore, in order to avoid embolism, ICE or a more focused TTE to evaluate for any RV thrombus just before ablation may be required even in patients with ARVC.

References

1. Wlodarska EK, Wozniak O, Konka M, Rydleska-Sadowska W, Biederman A, Hoffman P. Thromboembolic complication in patients with arrhythmogenic right ventricular dysplasia/cardiomyopathy. *Europace* 2006;8:596–600.
2. Romeo J, Mejia-Lopez E, Manrique C, Lucariello R. Arrhythmogenic right ventricular cardiomyopathy (ARVC/D): A systemic literature review. *Cardiology* 2013;7:97–114.
3. Jongbloed MRM, Bax JJ, Borger van der Burg AE, Van der Wall EE, Schalij MJ. Radiofrequency catheter ablation of ventricular tachycardia guided by intracardiac echocardiography. *Eur J Echocardiography* 2004;5:34–40.