

Perpendicular Strut Injection of Hyaluronic Acid Filler for Deep Wrinkles

Takanobu Mashiko, MD*
 Kahori Kinoshita, MD*
 Koji Kanayama, MD*
 Jingwei Feng, MD*
 Kotaro Yoshimura, MD*†

Summary: Although various injection techniques of hyaluronic acid (HA) filler for facial rejuvenation have been developed, correction of deep wrinkles/grooves, such as the nasolabial fold (NLF), with intradermal or subdermal injections remains difficult. We tested the intradermal HA injection method to place multiple HA struts by (1) inserting a small needle perpendicularly to the wrinkle and (2) injecting HA as intradermal struts with the skin fully stretched by the practitioner's fingers. The results of both NLFs in 10 patients suggest that this technique improves NLFs and maintain the effects more consistently than conventional techniques, although the effects of both methods were almost lost after 6 months. Selective and/or combined application of this technique may enhance the current approach to facial rejuvenation with dermal fillers. (*Plast Reconstr Surg Glob Open* 2015;3:e567; doi: 10.1097/GOX.0000000000000552; Published online 20 November 2015.)

Various techniques of hyaluronic acid (HA) filler injection have been developed, such as the serial puncture, linear threading, fanning, cross-hatching, and tower technique.^{1,2} An optimal injection technique depends on the filling agent, the area and target to be corrected, and preference of the surgeon. The differential use of these techniques is a key to maximizing aesthetic results. Intradermal injection is a basic approach to treat deep wrinkles; however, occasionally, unfavorable results are encountered, such as conspicuous ridging or beading on or adjacent to the target wrinkle³ and negligible effects on wrinkles. Deep wrinkles/grooves accompanied with ptosis of the soft tissue

are often not fully corrected by a single procedure and may need to be treated by a combination of intradermal and subdermal injections. To provide more consistent intradermal structural support, we tested an intradermal injection technique to place "multiple perpendicular struts" of HA. Herein, we report the clinical benefit suggested by this study.

PATIENTS AND METHODS

Study Patients

Ten consecutive patients (9 women and 1 man), between the age of 39 and 67 years (mean, 50.2 years), were enrolled in this study with an informed consent approval by the institutional review board. In terms of inclusion criteria, healthy adult patients were required to have bilateral nasolabial fold (NLF) ratings of 2 (mild) to 4 (severe) on the 5-grade Wrinkle Severity Rating Scale (WSRS) (Table 1) and be willing to abstain from other cosmetic procedures

From the *Department of Plastic Surgery, University of Tokyo, School of Medicine, Tokyo Japan; and †Department of Plastic Surgery, Jichi Medical University, Shimotsuke, Japan.

Received for publication March 31, 2015; accepted October 6, 2015.

Copyright © 2015 The Authors. Published by Wolters Kluwer Health, Inc. on behalf of The American Society of Plastic Surgeons. All rights reserved. This is an open-access article distributed under the terms of the Creative Commons Attribution-Non Commercial-No Derivatives License 4.0 (CCBY-NC-ND), where it is permissible to download and share the work provided it is properly cited. The work cannot be changed in any way or used commercially.

DOI: 10.1097/GOX.0000000000000552

Disclosure: The authors have no financial interest to declare in relation to the content of this article. The Article Processing Charge was paid for by the authors.

Supplemental digital content is available for this article. Clickable URL citations appear in the text.

for the duration of the study. The exclusion criteria included a history of facial rejuvenation treatments in the previous 6 months.

Injection Materials and Procedure

A cross-linked HA (Restylane, Q-MED AB, Uppsala, Sweden) was injected through a sharp 30-gauge needle. Each patient received HA injections to the bilateral NLFs using either the “perpendicular strut technique” or the linear threading and fanning techniques (which are traditionally used for NFL treatment¹). The same amount of HA was used for both sides (between 0.3 and 0.5 mL for each side, depending on the severity of the NLF rating); overcorrection was not allowed.

For the “perpendicular strut” technique, HA struts (10–12 mm long) were intradermally delivered in a direction perpendicular to NLF (Fig. 1). The needle was placed almost horizontally to the skin surface and perpendicular to the nasolabial fold and then inserted (its entire length of 0.5 in.) into the mid to deep dermis (with the skin fully stretched by the practitioner’s fingers) in a direction perpendicular to the NLF. HA was introduced into the dermis during withdrawal of the needle, creating “struts” consisting of 0.01–0.03 mL HA. (See video, Supplemental Digital Content 1, which displays the injection technique. <http://links.lww.com/PRSGO/A150>.) Fifteen to 30 struts of HA were spread over the NLF area, and the spacing between each strut was approximately 1 mm. After releasing the fingers from the skin, multiple HA struts gave structural support to maintain the skin partly stretched. The same amount of HA was also injected into the other side, using conventional linear threading and fanning techniques. Patients were randomized regarding which side of the NLF would be injected using the strutting or conventional technique. No compensation was conducted even when 1 side had worse NFL and the same amount of HA gel was used on each side. Although the injector was not blinded to the injection method, the patient and the evaluators were blinded. Gentle massage of the treated area after injection was recommended on both sides. The initial treatment was followed without any touch-up treatment.

Evaluation of Results

WSRS scoring was performed to measure effectiveness by 3 blinded, certified plastic surgeons. The NLF was graded before, 4, and 24 weeks after treatment through the comparison of photographs. The paired *t* test was used to compare improvements in WSRS score on each side. The blinded

Table 1. Wrinkle Severity Rating Scale

Score	Description
5	Extreme: extremely deep and long folds, detrimental to facial appearance; 2- to 4-mm visible V-shaped folds when stretched
4	Severe: very long and deep folds; prominent facial features; less than 2 mm visible when stretched
3	Moderate: moderately deep folds; clear facial features visible at normal appearance but not when stretched
2	Mild: shallow but visible folds with a slight indentation; minor facial features
1	Absent: no visible folds; continuous skin line

Cited from the work of Narins et al.⁴

evaluators also answered the query, “which side had better improvement, judging from comparison of before and after photographs.” The query results were analyzed with χ^2 test. Safety and efficacy were measured by physician assessment and use of

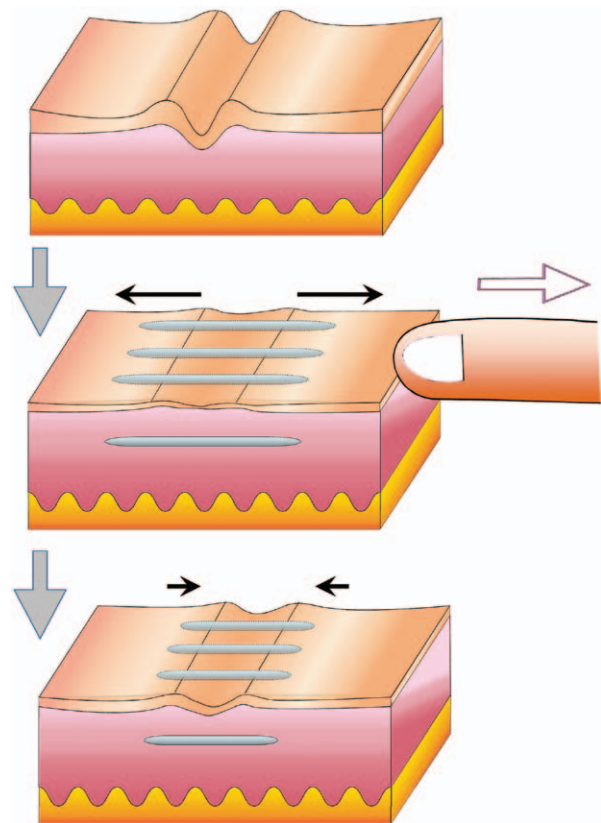
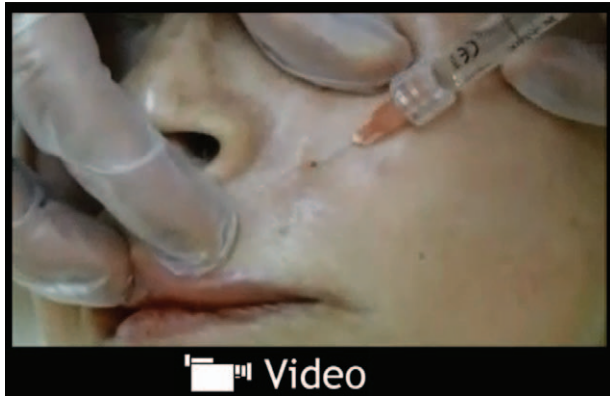

Fig. 1. Scheme of “perpendicular strut injection.” The needle is placed almost horizontally to the skin surface and perpendicularly to the nasolabial fold. It is inserted into the dermis for the entire needle length (0.5 in.) with the skin fully stretched using fingers. Hyaluronic acid (HA) is introduced into the dermis while withdrawing the needle, creating a “strut” of 0.03–0.05 mL HA. After the release of the fingers, HA struts give supportive forces to the skin to allow it to be stretched to some extent.



Video Graphic 1. See video, Supplemental Digital Content 1, which displays the injection technique. <http://links.lww.com/PRSGO/A150>.

patient diaries recording adverse events for 2 weeks after treatment.

RESULTS

All 10 patients completed the study. Mean and individual scores using the WSRS system are shown in Table 2. Four weeks after treatment, grade improvement was significantly greater in the strut method (1.7) than in the conventional side method (1.3; $P = 0.036$). Twenty-four weeks after treatment, improvement from baseline almost disappeared on the both sides. In addition, the query results answered by the 3 blinded evaluators are shown in Table 3. Significant difference was observed at 4 weeks after treatment ($P < 0.01$) but not at 24 weeks after treatment ($P > 0.05$). Temporary adverse events are shown in Table 4 and all disappeared within 2 weeks. No other serious complications occurred. Photographs of a representative patient are shown in Figures 2, 3.

Table 2. Wrinkle Severity Rating Scale Data from 10 Patients

Patient	Pre-treatment Grade		Posttreatment Grade after 4 Wk (Grade Improvement)		Posttreatment Grade after 24 Wk (Grade Improvement)	
	Strut	Control	Strut	Control	Strut	Control
1	3	3	2 (1)	2 (1)	3 (0)	3 (0)
2	2	2	1 (1)	1 (1)	2 (0)	2 (0)
3	3	3	1 (2)	1 (2)	2 (1)	3 (0)
4	3	3	1 (2)	2 (1)	3 (0)	3 (0)
5	4	3	2 (2)	2 (1)	3 (1)	3 (0)
6	4	4	2 (2)	2 (2)	4 (0)	3 (1)
7	3	3	1 (2)	2 (1)	3 (0)	3 (0)
8	2	3	1 (1)	2 (1)	2 (0)	2 (1)
9	4	4	2 (2)	2 (2)	4 (0)	4 (0)
10	3	3	1 (2)	2 (1)	3 (0)	3 (0)
Mean	3.1	3.1	1.4 (1.7)	1.8 (1.3)	2.9 (0.2)	2.9 (0.2)

Strut: perpendicular strut technique.
Control: linear threading and fanning technique.

Table 3. Evaluation of Improvement

	4 Wk	24 Wk
Strut	15	7
Control	3	1
Neither	12	22
Total	30	30

Three blinded investigators evaluated 10 patients and answered the query; which side showed better improvement by comparison of before and after photographs.

Strut: perpendicular strut technique.

Control: linear threading and fanning technique.

Table 4. Adverse Events

Adverse Event	Strut (n = 10)	Control (n = 10)
Erythema	2	1
Bruising	1	3
Swelling	2	1
Pain	0	1
Numbness	1	1
Induration	4	1

Strut: perpendicular strut technique.

Control: linear threading and fanning technique.

DISCUSSION

The NLF is composed of deep, firm fibrous tissue that receives terminal muscle fibers from the levators of the upper lip and is deepened by downward displacement of the cheek tissues.⁵ HA fillers are now the gold standard in dermal wrinkle repair; however, the result of dermal fillers for NLF remains far from perfect. HA struts placed perpendicularly to the NLFs can give a supporting and sustaining force and stretch the skin against the original wrin-

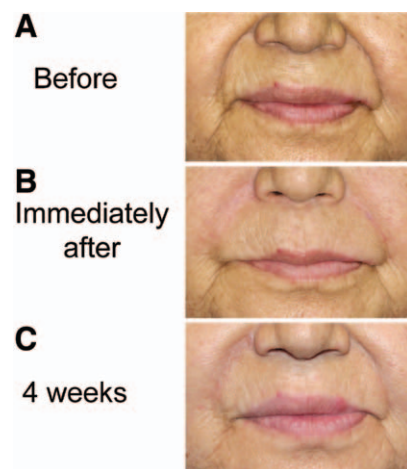


Fig. 2. A 67-year-old woman (patient 10) who underwent intradermal perpendicular strut injection to the right nasolabial fold and the conventional linear threading and fanning injection to the left nasolabial fold, using a total of 0.5 mL HA on each side: (A) before, (B) immediately after treatment, and (C) after 4 weeks; the right side showed better improvement than the left side.

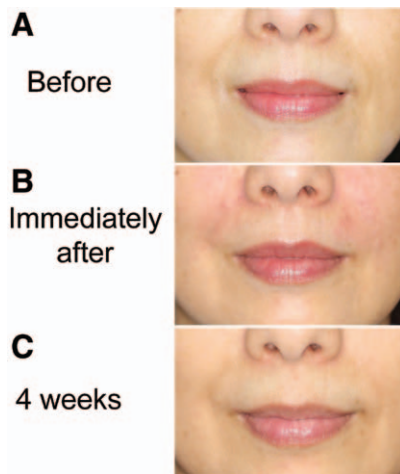


Fig. 3. A 58-year-old woman (patient 2) who underwent intradermal perpendicular strut injection to the left nasolabial fold and the conventional linear threading and fanning injection to the right nasolabial fold, using a total of 0.5 mL HA on each side: (A) before, (B) immediately after treatment and (C) after 4 weeks; the originally more severe left side maintained better improvement than the right side.

kle structure and gravitational descent, although the effect is not permanent. We need to place multiple long struts in the dermis using a hard-type cross-linked HA substance to consistently maximize its effect and stability.

The difference in the results derived from the conventional technique was generally subtle; however, the results suggested that the strut injection technique more consistently achieved sufficient improvement. Because of the degradable property of HA products, aesthetic improvement cannot be sustained for 6 months on either side, and repeated injections are required to maintain the condition. The complication rate is not very different between the 2 sides, except for temporary induration, which more frequently accompanies strut injection (which all diminished within 2 weeks and thus did not affect the outcome at 4-week follow-up). Skin necrosis, because of arterial embolization of the angular branch of the facial artery,⁶ never occurs by intradermal injection. Although the small number of patients is a limitation of this study, this is a split-face comparative study, and the obtained findings are well supported by our preliminary experience on this technique in hundreds of patients. Further studies are required

to confirm in a large number of patients and determine a good indication of this technique.

Although we treated only NLF in this study, intradermal perpendicular strut injection can be applied to other major facial lines, particularly when conventional injections only work minimally. The strut technique can complement other techniques; for example, an additional volumizing HA injection only to the maxillary bone can give sustainable structural support to elevate the entire tissue (skin and subcutaneous tissue),⁷ whereas intradermal HA struts can maintain the stretched status of the wrinkled skin.

CONCLUSIONS

Intradermal perpendicular strut injection for the treatment of NLF has proven to be a useful alternative that can give better intradermal structural support for the stretched state of wrinkles. The selective and/or combined application of this technique may enhance the current approach to facial rejuvenation with dermal fillers.

Kotaro Yoshimura, MD

Department of Plastic Surgery

Jichi Medical University

3311-1, Yakushiji, Shimotsuke, 329-0498

Tochigi, Japan

E-mail: kotaro-yoshimura@umin.ac.jp

REFERENCES

1. Rohrich RJ, Ghavami A, Crosby MA. The role of hyaluronic acid fillers (Restylane) in facial cosmetic surgery: review and technical considerations. *Plast Reconstr Surg.* 2007;120(6 Suppl):41S–54S.
2. Carruthers J, Rzany B, Sattler G, et al. Anatomic guidelines for augmentation of the cheek and infraorbital hollow. *Dermatol Surg.* 2012;38(7 Pt 2):1223–1233.
3. Duffy DM. Complications of fillers: overview. *Dermatol Surg.* 2005;31(11 Pt 2):1626–1633.
4. Narins RS, Brandt F, Leyden J, et al. A randomized, double-blind, multicenter comparison of the efficacy and tolerability of Restylane versus Zyplast for the correction of nasolabial folds. *Dermatol Surg.* 2003;29:588–595.
5. Rubin LR, Mishriki Y, Lee G. Anatomy of the nasolabial fold: the keystone of the smiling mechanism. *Plast Reconstr Surg.* 1989;83:1–10.
6. Inoue K, Sato K, Matsumoto D, et al. Arterial embolization and skin necrosis of the nasal ala following injection of dermal fillers. *Plast Reconstr Surg.* 2008;121:127e–128e.
7. Mashiko T, Mori H, Kato H, et al. Semipermanent volumization by an absorbable filler: onlay injection technique to the bone. *Plast Reconstr Surg Glob Open.* 2013;1:e4–e14.