

A rare case showing subacute thyroiditis-like symptoms with amyloid goiter after anti-tumor necrosis factor therapy

Junji Kawashima¹, Hideaki Naoe², Yutaka Sasaki² and Eiichi Araki¹

Departments of ¹Metabolic Medicine ²Gastroenterology and Hepatology, Faculty of Life Sciences, Kumamoto University, 1-1-1 Honjo, Chuo-ku, Kumamoto 860-8556, Japan

Correspondence
should be addressed
to J Kawashima

Email
jkawashima@
fc.kuh.kumamoto-u.ac.jp

Summary

Anti-tumor necrosis factor (TNF)- α therapy is established as a new standard for the treatment of various autoimmune inflammatory diseases. We report the first case showing subacute thyroiditis-like symptoms with an amyloid goiter after anti-TNF- α therapy. A 56-year-old man with Crohn's disease presented with fever and a diffuse, tender goiter. To control the diarrhea, anti-TNF therapy (infliximab) was administered 4 weeks before the thyroid symptoms emerged. The patient reported a swollen neck with tenderness on the right side and fever 4 days after the second infliximab injection. An elevated serum C-reactive protein (CRP) and serum thyroid hormone level with suppressed serum thyrotropin were observed. The thyroid-stimulating antibody was not elevated. An ultrasonograph of the thyroid revealed an enlarged goiter with posterior echogenicity attenuation and a low echoic region that was tender. The thyroid uptake value on technetium-99m scintigraphy was near the lower limit of the normal range. The patient was initially diagnosed with thyrotoxicosis resulting from subacute thyroiditis. Administration of oral prednisolone improved the fever, thyroid pain, and thyroid function, but his thyroid remained swollen. The patient developed diarrhea after prednisolone withdrawal; therefore, adalimumab, another TNF inhibitor, was administered. After three injections, his abdominal symptoms were alleviated, but the thyroid pain and fever recurred. Elevated serum CRP levels in the absence of thyroid dysfunction were observed. The patient's symptoms resolved after prednisolone retreatment, but an elastic, firm goiter persisted. A fine-needle biopsy revealed amyloid deposition in the thyroid.

Learning points:

- Many cases with thyroid dysfunction accompanied by amyloid goiter have been reported.
- There are cases that develop amyloid goiter with subacute thyroiditis-like symptoms after anti-TNF therapy.
- When the thyroid remains swollen after improvement of thyrotoxicosis following treatment with prednisolone, it should be assessed to differentiate between an amyloid goiter and common subacute thyroiditis.

Background

Thyroid dysfunction resulting from therapeutic pharmacological agents is often encountered in clinical practice. Various medicines, such as amiodarone and interferon- α , have been reported to induce thyrotoxicosis (1). Tumor

necrosis factor (TNF)- α has been implicated in the pathogenesis of numerous inflammatory conditions, and its inhibition has proven efficacious in the treatment of autoimmune diseases, such as rheumatoid arthritis and inflammatory bowel disease. Recently, several cases of

thyrotoxicosis have been reported in association with anti-TNF therapy using etanercept (2) (3) (4) (5). However, thyrotoxicosis accompanied by an amyloid goiter after anti-TNF therapy has never been reported.

In the present report, we present the first reported case showing subacute thyroiditis-like symptoms with an amyloid goiter after anti-TNF therapy for Crohn's disease.

Case presentation

A 56-year-old man who had been suffering from diarrhea since the age of 50 was diagnosed with Crohn's disease. He had no previous history of a thyroid disease or the use of other medications known to induce thyroid dysfunction. He had no history of neck pain, irradiation, or recent fever and no family history of thyroid disease. At the age of 56 years, he was treated with the TNF inhibitor infliximab (5 mg/kg) on April 26, 2012, and May 9, 2012, to improve diarrhea. He noticed neck swelling with right neck tenderness and fever 4 days after the second injection of infliximab and thus was referred to our department on May 23, 2012.

Physical examination revealed that he was undernourished, with a height of 1.67 m and a weight of 52.0 kg. His body temperature was 36.5 °C because had been taking acetaminophen since May 13, 2012. His blood pressure was 154/80 mmHg, and his pulse was 71 bpm. He did not have lid retraction, hyperhidrosis, or tremor of the fingers. An elastic, firm goiter was palpable, primarily in the right lobe of the thyroid, which was tender.

Investigation

The laboratory data revealed hypochromic anemia, hypoalbuminemia, and hypolipidemia (Table 1). His renal function was normal, with the exception of a slightly elevated urinary protein level. His serum C-reactive protein (CRP) was elevated, whereas his white blood cell count was within normal range. His serum free triiodothyronine (fT₃) and serum free thyroxine (fT₄) were both elevated, and his serum thyroid stimulating hormone (TSH) was low. His serum thyroglobulin (Tg) was elevated, and anti-Tg and anti-thyroid peroxidase antibodies were absent. Thyroid-stimulating antibodies were not elevated. Ultrasonography of his thyroid gland revealed an enlarged goiter (estimated thyroid volume: 46.8 ml), particularly in the right lobe, with irregular hypoechoic region in the right lobe and posterior attenuation of echogenicity (Fig. 1). The thyroid uptake value on technetium-99m scintigraphy was near the lower

Table 1 Laboratory results (May 23, 2012). Values presented in italics are below the normal lower limit, whereas those in bold are above the normal upper limit. Tg-antibody and TPO-antibody were measured by the electrochemiluminescence (ECLIA) method.

Laboratory tests	Patient's values	Reference range
WBC (/mm ³)	4200	(3500–8500)
Neut. (%)	70.0	(40.7–74.8)
Lymp. (%)	18.5	(19.0–49.7)
Mono. (%)	7.2	(1.0–9.0)
Eosin. (%)	4.1	(0–6.6)
RBC (×10 ⁶ /μl)	3.38	(4.31–5.65)
Hemoglobin (g/dl)	9.8	(14.0–17.7)
Hematocrit (%)	29.8	(40.4–50.8)
Platelet (/mm ³)	243	(145–325)
Total protein (g/dl)	7.3	(6.5–8.3)
Albumin (g/dl)	3.8	(3.9–4.9)
Na (mEq/l)	144	(138–146)
K (mEq/l)	3.9	(3.5–5.0)
Cl (mEq/l)	110	(99–109)
Ca (mg/dl)	9.5	(8.3–10.5)
P (mg/dl)	3.3	(2.5–4.8)
BUN (mg/dl)	20.9	(8–24)
Creatinine (mg/dl)	0.95	(0.56–1.18)
AST (U/l)	30	(13–34)
ALT (U/l)	31	(7–37)
γ-GTP (U/l)	21	(9–47)
LDH (U/l)	167	(112–213)
ALP (U/l)	239	(106–350)
CHE (U/l)	207	(218–464)
CRP (mg/dl)	3.95	(< 0.3)
Blood glucose (mg/dl)	73	(72–110)
T. cholesterol (mg/dl)	95	(128–220)
Triglyceride (mg/dl)	60	(30–150)
HDL cholesterol (mg/dl)	43	(40–108)
TSH (μIU/ml)	0.02	(0.50–5.00)
fT ₃ (pg/ml)	4.60	(2.30–4.00)
fT ₄ (ng/dl)	1.94	(0.90–1.70)
Thyroglobulin (ng/ml)	195.7	(< 32.7)
TSAb (%)	104	(< 180)
Tg-antibody (IU/ml)	0.7	(< 28)
TPO-antibody (IU/ml)	0.3	(< 16)

WBC, white blood cell; RBC, red blood cell; BUN, blood urea nitrogen; TSAb, thyroid stimulating antibody; Tg, thyroglobulin; TPO, thyroid peroxidase.

limit of the normal range (Fig. 2). Thus, his condition at that time was diagnosed as thyrotoxicosis resulting from subacute thyroiditis but not from Graves' disease.

Treatment

As the administration of acetaminophen for another 2 weeks did not ameliorate his symptoms and thyroid dysfunction, oral prednisolone (20 mg/day) was initiated on June 6, 2012. Instantly, his fever and thyroid pain were improved. Treatment with prednisolone was stopped on November 8, 2012 (Fig. 3) because his thyroid function

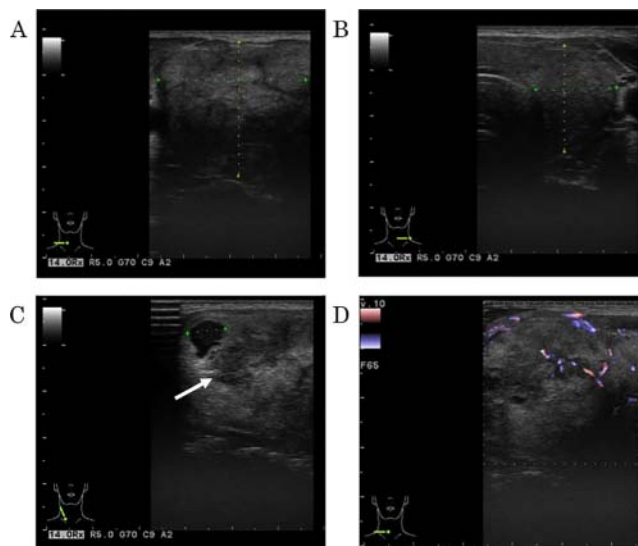


Figure 1
Ultrasonograph of the thyroid showing diffuse enlargement and posterior attenuation of echogenicity (A and B). The right lobe had a low echoic region that was tender (C, white arrow). On color Doppler imaging, the thyroid gland did not show hypervascularity (D).

had normalized and his symptoms were gone. His goiter was reduced in size after the treatment with prednisolone, but it remained swollen.

He suffered from diarrhea after the withdrawal of prednisolone; therefore, another TNF inhibitor, adalimumab, was administered starting on December 13, 2012. After three injections, his abdominal symptoms were ameliorated, but his thyroid pain and fever returned on January 10, 2013. The laboratory data on January 16 revealed elevated serum CRP (9.88 mg/dl) without thyroid dysfunction (Fig. 3). Serum Tg had increased from 200.7 ng/ml (December 5, 2012) to 753.2 ng/ml (January 16, 2013). Adalimumab was discontinued, and oral prednisolone (10 mg daily) was restarted. His symptoms vanished immediately after retreatment with prednisolone, but the elastic, firm goiter in the right lobe remained. A fine-needle biopsy of the thyroid gland was performed on November 7, 2013, and it revealed amyloid deposition in his thyroid gland (Fig. 4). Amyloid deposition was histologically confirmed in biopsied tissues from his stomach and duodenum.

Outcome and follow-up

As his serum TSH level increased, levothyroxine has been prescribed since July 2013, which has yielded a euthyroid state (Fig. 3).

Discussion

Thyrotoxicosis in our patient is suspected to have resulted from subacute thyroiditis-like destructive thyroiditis but not from hyperthyroidism, because his fever and thyroid pain disappeared immediately after the treatment with prednisolone. Relatively low uptake on technetium-99m scintigraphy also strongly suggests destructive thyroiditis.

A viral etiology has most often been implicated in subacute thyroiditis. Although serological tests for viruses suspected to be associated with subacute thyroiditis were not performed, our patient reported no episode of viral infection during anti-TNF therapy. Human leukocyte antigen typing showed that he was positive for B44 and B51 but not for B35, which confers an apparent genetic predisposition to subacute thyroiditis (6).

Early recurrence of subacute thyroiditis (within 12 months after the first episode) is rare, occurring in only 10% of patients with subacute thyroiditis (7). Our patient immediately relapsed with thyroid pain and fever after the treatment with a different anti-TNF agent. Furthermore, although goiters resulting from subacute thyroiditis usually disappear after improvement in thyroid function, in the present case, the patient's thyroid remained swollen following treatment with prednisolone. Therefore, our patient was suspected of having a thyroid disorder different from common subacute thyroiditis.

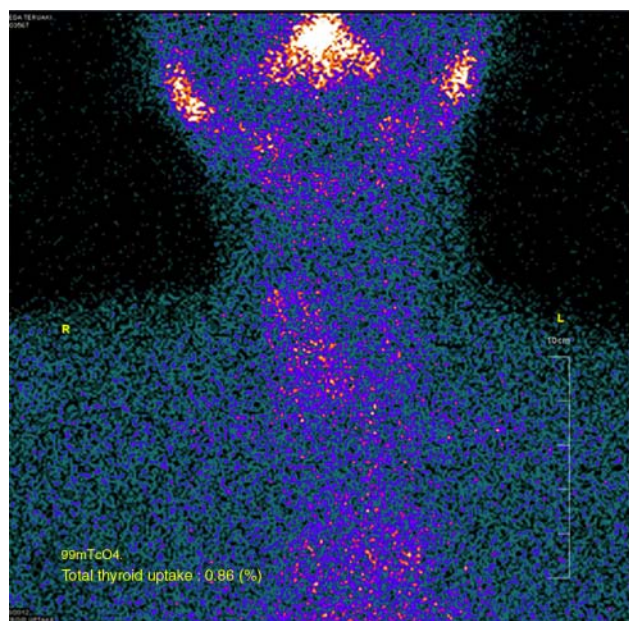


Figure 2
Technetium-99m scintigraph of the thyroid.

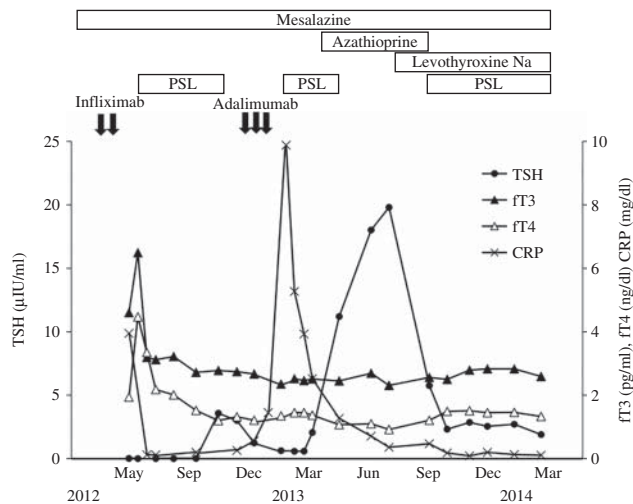


Figure 3 Changes in thyroid function and CRP. Prednisolone (PSL) was administered from June 2012 to November 2012 and from January 2013 to April 2013 for the treatment of subacute thyroiditis-like symptoms. Treatment with PSL for Crohn's disease was started in September 2013. Levothyroxine Na was prescribed for hypothyroidism in July 2013. Mesalazine and azathioprine were taken for the treatment of Crohn's disease.

He was then diagnosed with thyroid amyloidosis by fine-needle biopsy.

Amyloidosis is classified as primary and secondary. Secondary amyloidosis mostly accompanies chronic inflammatory diseases, such as tuberculosis, rheumatoid arthritis, and inflammatory bowel disease. One previous study reported that 15 (0.9%) of 1709 patients with Crohn's disease were complicated by secondary amyloidosis and only three patients had amyloid deposition in the thyroid (8).

Thyroid function in patients with an amyloid goiter is usually normal. However, several cases have been reported involving hyperthyroxinemia with an amyloid goiter that might have resulted from destructive thyroiditis, as was the case with our patient (9) (10). Although subacute thyroiditis more frequently affects women than men (7), thyroid amyloidosis with subacute thyroiditis-like symptoms has been reported mainly in men.

It is difficult to verify that the patient had thyroid amyloidosis before the administration of the first anti-TNF inhibitor, infliximab, because he did not undergo any examinations of the thyroid, including ultrasonography or needle biopsy, before the administration of the inhibitor. Serum thyroglobulin was elevated after the administration of the second anti-TNF inhibitor, adalimumab. This strongly suggests that anti-TNF inhibitors triggered the destructive thyroiditis-like subacute

thyroiditis in the patient. How TNF inhibitors could trigger subacute thyroiditis-like symptoms in our patient is unknown. Infliximab and adalimumab are monoclonal antibodies directed against TNF- α , and both have been established as a new standard for the treatment of Crohn's disease. A patient who developed Graves' disease during treatment with adalimumab has been reported (11), but no case involving destructive thyroiditis during treatment with both inhibitors was found in the literature. Etanercept is a TNF inhibitor that acts as a decoy receptor for TNF- α by competitively inhibiting the binding of TNF- α to its cell surface receptor. Several reports describe patients developing thyrotoxicosis while on etanercept (2) (3) (4) (5). All of these patients were initially suspected of having subacute thyroiditis because they showed thyroid pain without thyroid antibodies, but no thyroid amyloidosis was documented. All of these patients happened to develop subacute thyroiditis at least 6 months after the initiation of etanercept treatment. However, the subacute thyroiditis-like symptoms in our patient occurred immediately after the initiation of infliximab and adalimumab.

TNF- α and TNF- α receptors reside in human thyroid tissue (12). Anti-TNF- α antibody suppresses thyroidal fibrosis in mouse with granulomatous experimental autoimmune thyroiditis (13). Therefore, TNF signaling likely regulates the structure and function of the thyroid. Thus, modulation of the immune system by TNF inhibitors that are similar to interferon may induce thyroid dysfunction.

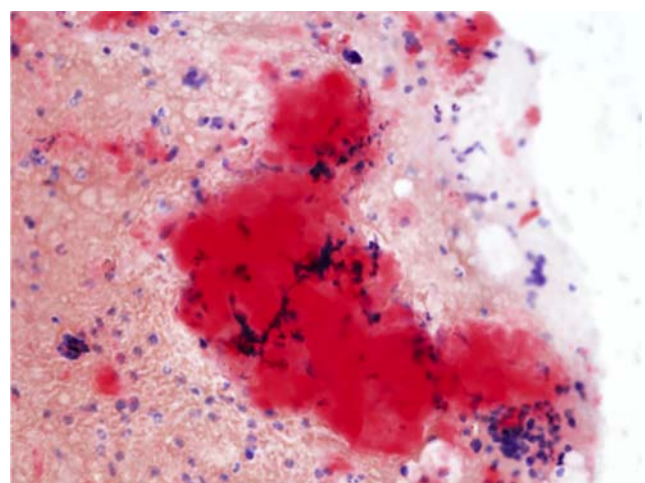


Figure 4 Cytological examination of the thyroid tissue obtained using fine-needle biopsy. Abnormal extracellular deposits showed positive staining with Congo red.

We described a case showing subacute thyroiditis-like symptoms with an amyloid goiter after anti-TNF therapy. The precise mechanism underlying the onset of this condition remains unclear. Further studies are of interest to elucidate the pathogenesis of subacute thyroiditis.

Declaration of interest

The authors declare that there is no conflict of interest that could be perceived as prejudicing the impartiality of the research reported.

Funding

This research did not receive any specific grant from any funding agency in the public, commercial or not-for-profit sector.

Patient consent

Written informed consent was obtained from the patient for publication of this case report.

Author contribution statement

J Kawashima was the lead clinician who managed the patient's thyroid disorder; H Naoe was the lead clinician who managed the patient's Crohn's disease; all authors contributed to the drafting of the report.

References

- 1 Surks MI & Sievert R 1995 Drugs and thyroid function. *New England Journal of Medicine* **333** 1688–1694. (doi:10.1056/NEJM199512213332507)
- 2 Allanore Y, Bremont C, Kahan A & Menkes CJ 2001 Transient hyperthyroidism in a patient with rheumatoid arthritis treated by etanercept. *Clinical and Experimental Rheumatology* **19** 356–357.
- 3 Vassilopoulos D, Sialevis K, Malahtari S, Deutsch M, Manolakopoulos S & Archimandritis AJ 2010 Subacute thyroiditis presenting as fever of unknown origin in a patient with rheumatoid arthritis under etanercept treatment. *Journal of Clinical Rheumatology* **16** 88–89. (doi:10.1097/RHU.0b013e3181d0bd30)
- 4 Canas CA, Tobon GJ, Arango LG & Guarin N 2009 Developing of granulomatous thyroiditis during etanercept therapy. *Clinical Rheumatology* **28** S17–S19. (doi:10.1007/s10067-008-1046-2)
- 5 Yasuji I 2013 Subacute thyroiditis in a patient with juvenile idiopathic arthritis undergoing etanercept treatment: a case report and review of the literature. *Modern Rheumatology* **23** 397–400. (doi:10.3109/s10165-012-0670-5)
- 6 Ohsako N, Tamai H, Sudo T, Mukuta T, Tanaka H, Kuma K, Kimura A & Sasazuki T 1995 Clinical characteristics of subacute thyroiditis classified according to human leukocyte antigen typing. *Journal of Clinical Endocrinology and Metabolism* **80** 3653–3656. (doi:10.1210/jcem.80.12.8530615)
- 7 Fatourechi V, Aniszewski JP, Fatourechi GZ, Atkinson EJ & Jacobsen SJ 2003 Clinical features and outcome of subacute thyroiditis in an incidence cohort: Olmsted County, Minnesota, study. *Journal of Clinical Endocrinology and Metabolism* **88** 2100–2105. (doi:10.1210/jc.2002-021799)
- 8 Greenstein AJ, Sachar DB, Panday AK, Dikman SH, Meyers S, Heimann T, Gumaste V, Werther JL & Janowitz HD 1992 Amyloidosis and inflammatory bowel disease. A 50-year experience with 25 patients. *Medicine* **71** 261–270. (doi:10.1097/00005792-199209000-00001)
- 9 Ikenoue H, Okamura K, Kuroda T, Sato K, Yoshinari M & Fujishima M 1988 Thyroid amyloidosis with recurrent subacute thyroiditis-like syndrome. *Journal of Clinical Endocrinology and Metabolism* **67** 41–45. (doi:10.1210/jcem-67-1-41)
- 10 Nagai Y, Ohta M, Yokoyama H, Takamura T & Kobayashi KI 1998 Amyloid goiter presented as a subacute thyroiditis-like symptom in a patient with hypersensitivity vasculitis. *Endocrine Journal* **45** 421–425. (doi:10.1507/endocrj.45.421)
- 11 van Lieshout AW, Creemers MC, Radstake TR, Elving LD & van Riel PL 2008 Graves' disease in a patient with rheumatoid arthritis during treatment with anti-tumor necrosis factor- α . *Journal of Rheumatology* **35** 938–939.
- 12 Zubelewicz B, Muc-Wierzgon M, Wierzgon J, Romanowski W, Mazurek U, Wilczok T & Podwinska E 2002 Genetic dysregulation of gene coding tumor necrosis factor α receptors (TNF α Rs) in follicular thyroid cancer – preliminary report. *Journal of Biological Regulators and Homeostatic Agents* **16** 98–104.
- 13 Chen K, Wei Y, Sharp GC & Braley-Mullen H 2007 Decreasing TNF- α results in less fibrosis and earlier resolution of granulomatous experimental autoimmune thyroiditis. *Journal of Leukocyte Biology* **81** 306–314. (doi:10.1189/jlb.0606402)

Received in final form 1 April 2015

Accepted 8 April 2015