



Case report

A case report of a rupture of the musculotendinous junction of the pectoralis major in an athlete

Abdullah Noufal

Pediatric Orthopedic Surgery, AUHD (Al-Assad University Hospital Damascus), Syria

ARTICLE INFO

Keywords:

Case report
Pectoralis major ruptures
Musculotendinous junction
Anchors
Suturing

ABSTRACT

Introduction: The pectoralis major muscle (PM) is a large muscle on the anterior chest wall. The rupture of the PM is a rare entity in literature and most incidences had been reported frequently in weight lifting and contact sports. Acute repair of PM rupture yielded better outcome as compared to non-operative treatment in active individuals who wish to return to their sports.

Case report: We presented a case of a champion in bodybuilding who lifted a heavy weight during his routine exercises, which caused a rupture in the musculotendinous junction of the left pectoralis major muscle.

Discussion: As it is rare to meet ruptures in this site of pectoralis major, we decided to insert anchors into the humeral bone (as in avulsions and tendon's tears), and to duplicate the suturing levels in multiple directions (as in muscular belly ruptures).

Conclusion: Our aim here is to confirm that the rupture of the musculotendinous junction of the pectoralis major muscle is rare and difficult to deal, but the acute surgical treatment by inserting anchors into the humerus, and duplicating the suturing layers in multiple directions can give good results especially in athletes.

1. Introduction

The pectoralis major muscle is a powerful adductor, internal rotator and flexor of the shoulder. It arises as a broad sheet with two heads of origin: the upper clavicular head and the lower sterno-costal head. The two parts of the muscle converge laterally and insert on the lateral lip of the bicipital groove over an area of 5 cm. The fibers of the sterno-costal head pass underneath the clavicular head fibers forming the deeper posterior lamina of the tendon, which rotates 180 degrees so that the inferior-most fibers are inserted at the highest or most proximal point of the humerus. The clavicular head fibers form the anterior lamina of the tendon, which inserts more distally. As a result of the anatomy, the fibers of the sterno-costal head are maximally stretched during activities when the arm is abducted, externally rotated and extended such as during a bench press. This predisposes the inferior portion of the tendon to fail first [1]. Although most cases are undoubtedly partial, most reported injuries have been complete ruptures [2], predominantly affecting the distal musculotendinous junction or insertion of the tendon.

In an assessment of individual fiber lengths, Wolfe et al. [3] found that through an arc of forward flexion, excursion remained consistent, averaging about 19%. However, when the same measurements were done through an arc of 30° extension from neutral, the inferior fibers

had an excursion of 40%, twice that of the more superior fibers. Hence, one can see that in the extended bench press position with an eccentrically loaded musculotendinous unit, a biomechanical explanation for the incidence of PM tendon ruptures exists. It is proposed that the tendon fails in a predictable sequence, with the inferior segments of the sternal head failing first, followed by the more superior segments of the sternal head and subsequently the clavicular head [3,5].

Pectoralis major (PM) rupture is a rare entity in literature and most incidences had been reported frequently in weight lifting and contact sports such as rugby [6]. The most common causal movement to this injury is overloaded eccentric contraction of PM with the shoulder in extension, abduction and external rotation [6,7]. Acute repair of PM rupture yielded better outcome as compared to non-operative treatment in active individuals who wish to return to their sports [7]. The technique for surgical repair varies from suturing the tendon to the periosteum [8], to the remaining tendon [9] or clavi-pectoral fascia [10]. Osseous fixation can be achieved through drill holes [11,8,12], barbed staples [13] and anchors [14].

This case report has been reported in line with the SCARE 2020 criteria [14].

E-mail address: abdullahanoufal@gmail.com.

<https://doi.org/10.1016/j.ijscr.2021.106428>

Received 19 August 2021; Received in revised form 16 September 2021; Accepted 16 September 2021

Available online 22 September 2021

2210-2612/© 2021 The Author(s). Published by Elsevier Ltd on behalf of IJS Publishing Group Ltd. This is an open access article under the CC BY-NC-ND license

(<http://creativecommons.org/licenses/by-nc-nd/4.0/>).

2. Case report

A 43 years old male patient (a champion in bodybuilding) presented in the orthopedic clinic of Al- Abasieen private hospital in Damascus. He was a right-handed dentist, and his weight was 113 kg. His main compliances were pain and ecchymosis in the left upper part of his chest wall after a heavy weight lifting (219 kg), during routine exercise 7 days ago [video No. 1]. He walked into the clinic holding his left arm on arm sling. He was nonsmoker with no familiar, personal or medication histories. The clinical examination discovered a gap at the level of musculotendinous junction of the left pectoralis major (PM), with a clear weakness in the left shoulder adduction and internal rotation. MRI imaging discovered a clear rupture with a gap and liquid collection at the level of musculotendinous junction of the sterno-costal part of the left pectoralis major [Figs. 1, 2, 3]. The patient was planned for surgical repair at the tenth day after the initial injury, as he wanted to return his sports without compromised strength.

We performed the surgery under general anesthesia. The patient was positioned in the beach chair posture with a sandbag behind the scapula. Left shoulder and chest were prepped and draped with arm adducted and internally rotated under sterile conditions. A 7 cm incision was made through a deltopectoral approach to expose the free ends of the pectoralis major tendon and lateral lip of the bicipital groove. Moreover, with blunt dissection we exposed the belly of the external part of PM. The clavicular part of PM was intact with no clear ruptures and when the sterno-costal part was clearly defined, a rupture in the musculotendinous junction was obvious [Fig. 4].

The pectoralis stump was identified and mobilized by releasing the surrounding adhesions. Three 4.5 mm anchors (with two slipable sutures for each one) were inserted about 2 mm lateral to the tendon's insertion, and then, the six sutures were passed through the tendon stump towards the sterno-costal part in three directions (upper, middle, and lower). Here, we used temporary sutures into the medial parts (of the muscular belly) to pull them laterally in last stage of suturing (when the second slipable arm is pulled medially to bring the rupture lips together)

[Fig. 5].

The arm was adducted and internally rotated to put the ruptured lips well matched, and then they were firmly sutured together in two levels and three directions by duplicating the suturing layers in the muscular belly then sliding the slipable sutures' ends through the anchors to bring the rupture's lips together and tight them firmly [Fig. 6].

Finally, we did abduction and external rotation movements to test the suturing site under stretch forces [Video No 2].

After surgery, the accelerated rehabilitation protocol involved: (1) elbow exercises from day 1. (2) Isometric rotator cuff and pectoralis major strengthening was permitted with the shoulder in neutral rotation at 2 weeks along with passive external rotation within the documented 'safe arc'. (3) Progressive physiotherapy included range of motion, strengthening and endurance exercises. Regular follow-ups were arranged to evaluate shoulder function. Gradually, progressed movements were started to get a full range of motion (ROM), and the patient returned to his favorite sport (bodybuilding) after 10 weeks [Video No 3]. The main after surgery complication was a 0.5 cm width scar formation at the exposure site.

3. Discussion

Here, we presented a rare case of musculotendinous junction rupture of the PM. As we usually meet tears or avulsions in the tendon's stump insertion into the humeral bone, many techniques were described for these cases (tendon's tears or avulsions), but we did not find a clear explanation or technique for musculotendinous junction rupture. Therefore, we decided to mix two techniques; the primer is; inserting anchors into the bone to start firmly from the force affecting point in the humerus (as the stump reinserting technique), and the last is; duplicating the suturing layers in multiple directions to distribute the forces that may separate the rupture point's lips (as in the case of the muscular belly's rupture). By doing that, we got a firm and a strong way to collect the contraction forces from the sterno-costal parts (superior, middle and inferior) and transport there effects into the anchors' sites in the humeral

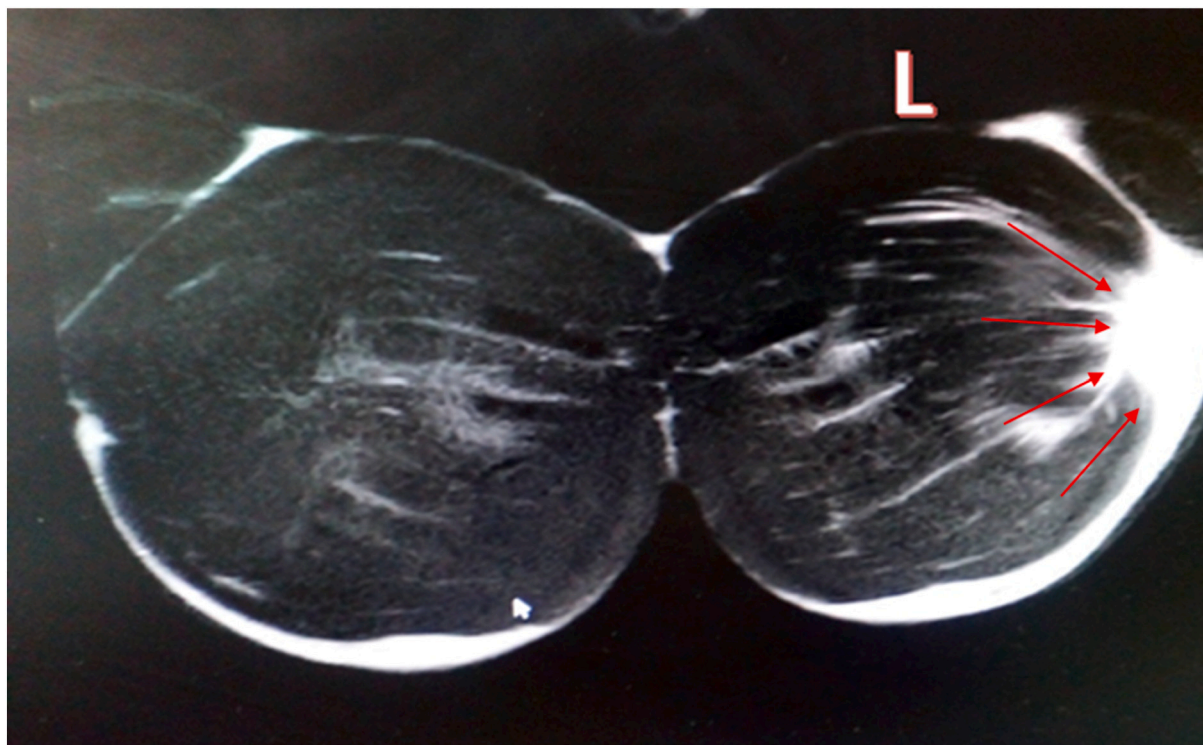


Fig. 1. Coronal MRI T2 shows the clear tear in the musculotendinous junction of the sterno-costal part of the left Pectoralis Major muscle in comparison to the right one (red arrows). (For interpretation of the references to colour in this figure legend, the reader is referred to the web version of this article.)

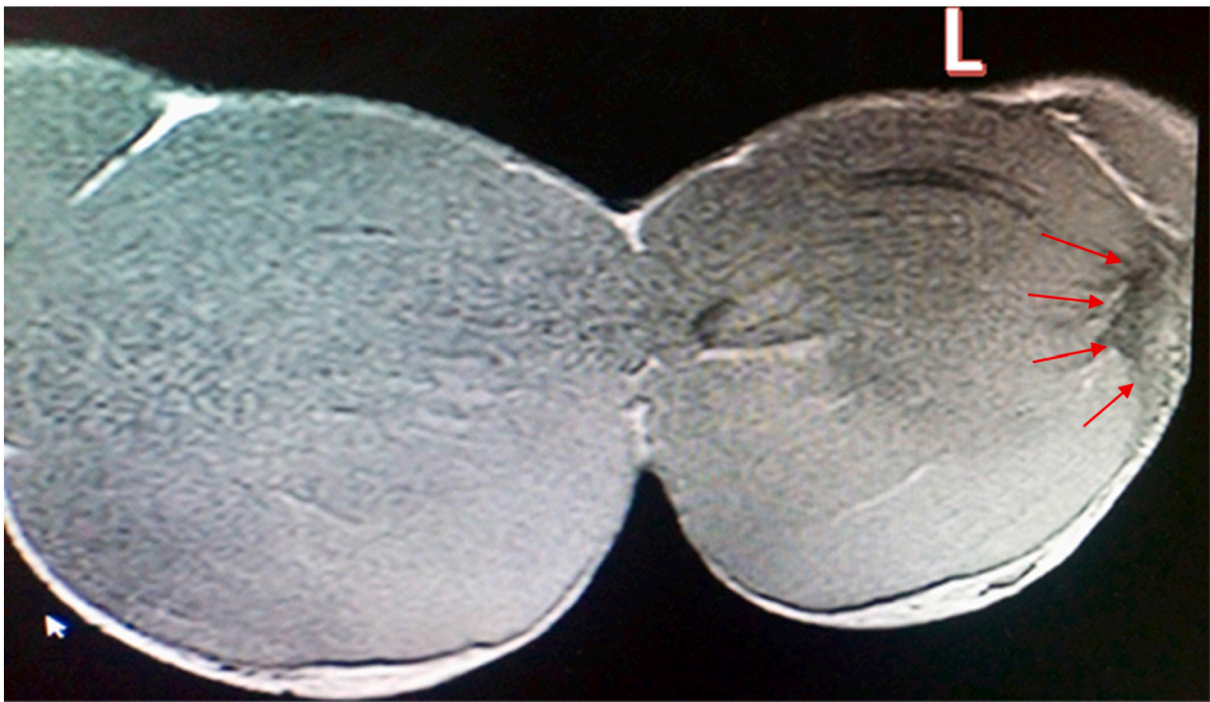


Fig. 2. Coronal MRI T1 shows the clear tear in the musculotendinous junction of the sterno-costal part of the left Pectoralis Major muscle in comparison to the right one (red arrows). (For interpretation of the references to colour in this figure legend, the reader is referred to the web version of this article.)

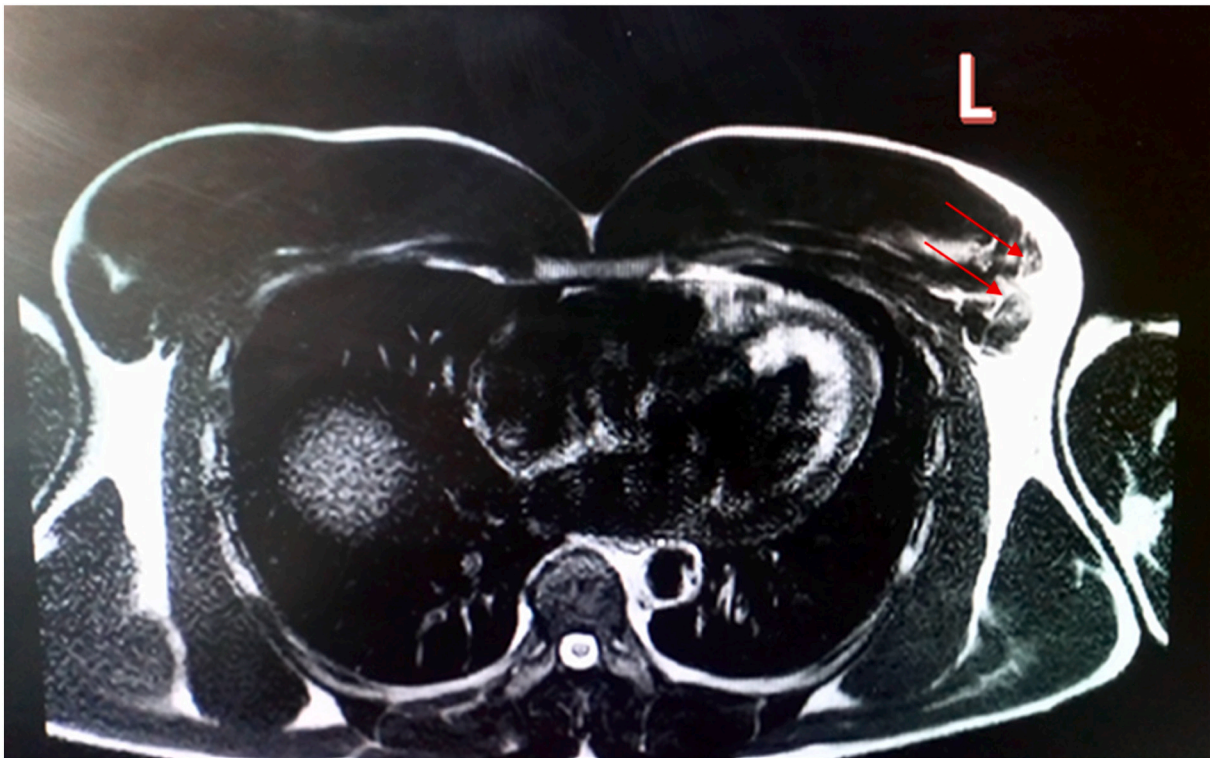

Fig. 3. Transversal MRI T2 shows the clear tear in the musculotendinous junction of the left Pectoralis Major muscle in comparison to the right one (see the rounded ruptured ends with the red arrows). (For interpretation of the references to colour in this figure legend, the reader is referred to the web version of this article.)

bone through the sutures, letting the rupture site to heal well by muscular-fibrotic integrating. (bodybuilding) and weight lifting.

The good results were clear after 10 weeks as the patient got a full ROM in the affected shoulder and started again his favorite sport

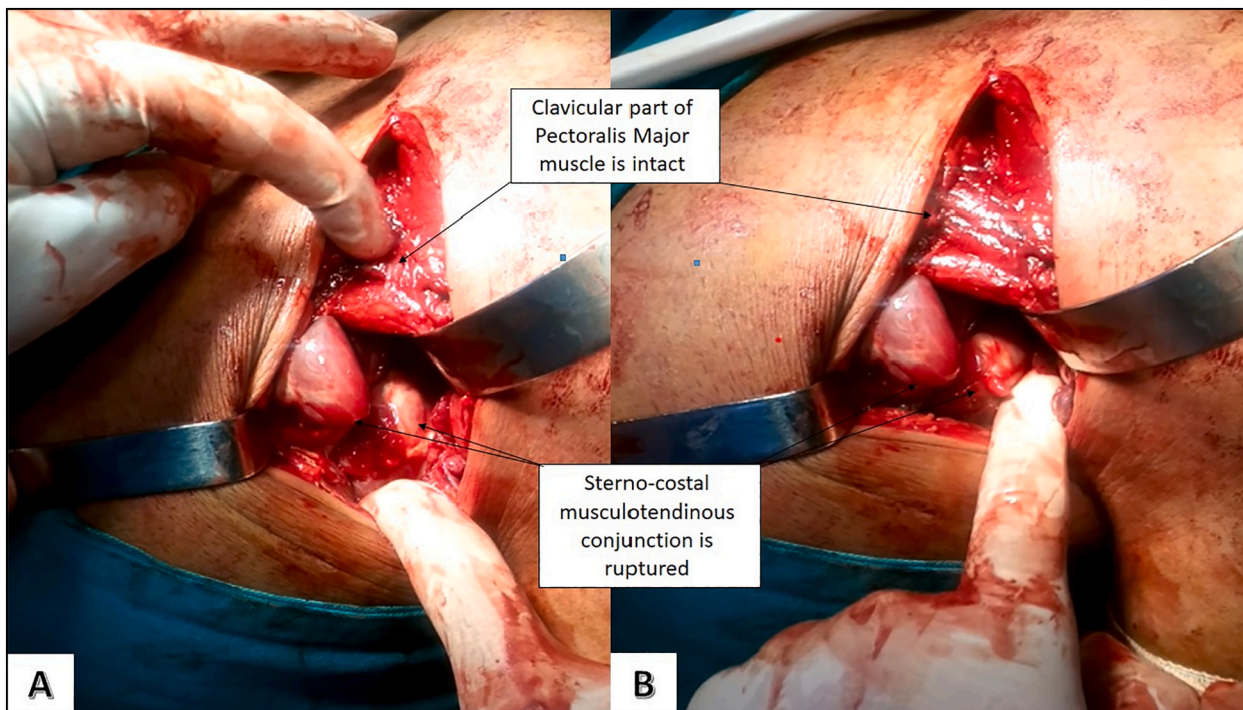


Fig. 4. (A & B) The delto-pectoral exposure and the intact clavicular part of the PM and the ruptured musculotendinous junction of the sterno-costal parts.

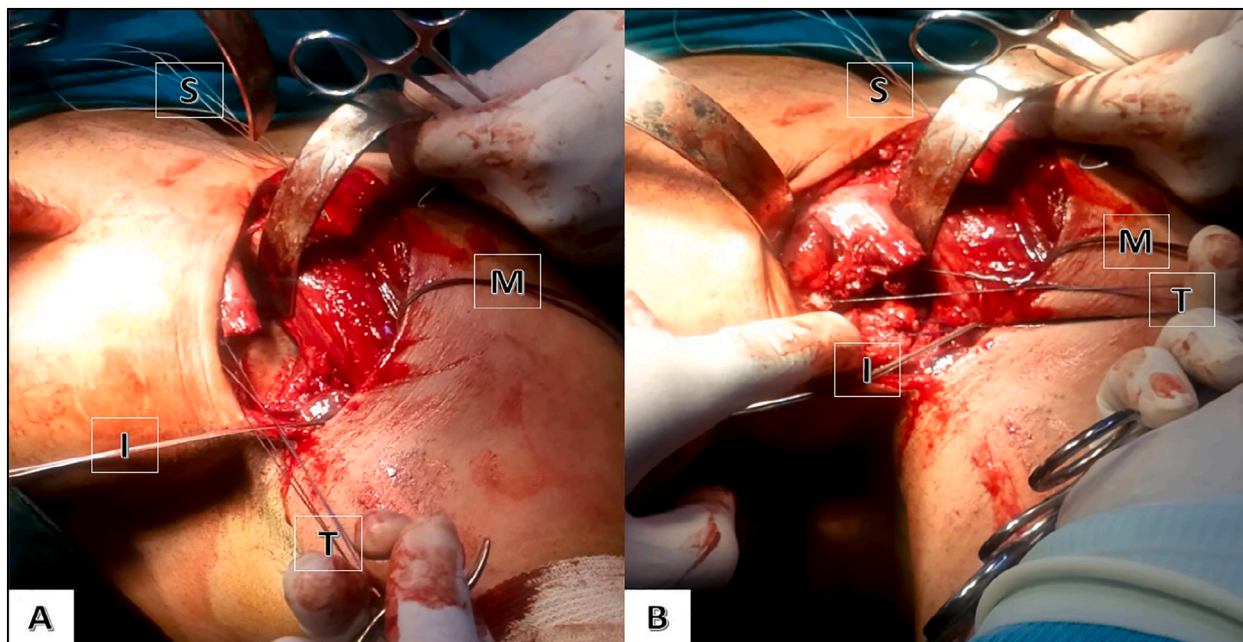


Fig. 5. In these two photos we can see the three groups of sutures according to the three anchors; Superior (S), Middle (M) & Inferior (I)-In A&B we can see the temporary sutures in the medial ruptured parts that we used to pull these parts laterally (A) before and (B) after pulling.

4. Conclusion

Rupture of the musculotendinous junction of the pectoralis major should be suspected in any case of absent adduction and internal rotation of the shoulder joint after heavy weight lifting, and careful reading of MRI especially coronal and transverse sections is cornerstone in diagnosis of these ruptures. In the medical practice, orthopedist tend to deal with ruptures of the tendon of this muscle or avulsions of its insertion into the humerus by using anchors into the bone or drilling

holes in it to reattach the tendon. In our case, we provide a practical evidence that the ruptured musculotendinous junction of the pectoralis major can be surgically reconnected by inserting anchors into the humerus and duplicating the suturing layers in three directions in the muscular belly crossing the rupture's lips. Due to the site of the rupture, surgeon may tend to make direct suturing between the belly and the tendon only, so, the rupture site will tolerate direct effect of the contraction forces directed from the belly into the humerus, which –in turn- may cause rerupture of the musculotendinous junction. Therefore,

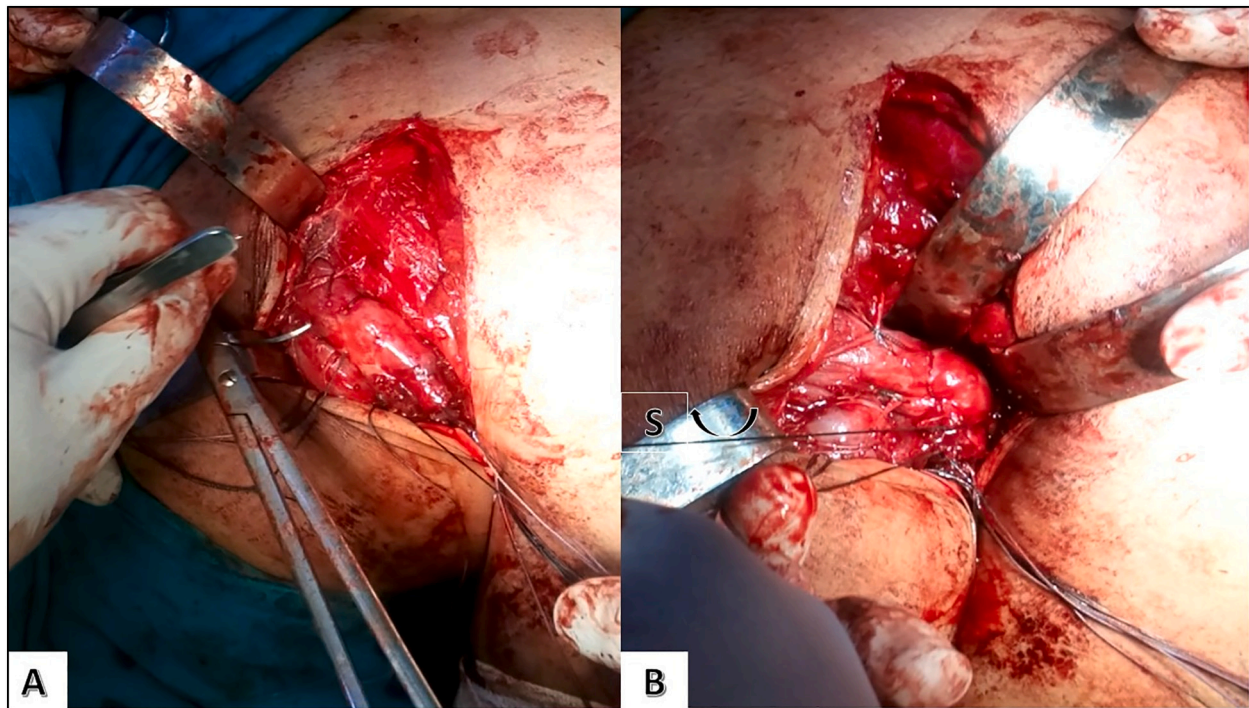


Fig. 6. A) Duplicated suturing with the primer arm of the slipable suture. B) The last arm of the slipable suture (S) bulled through the anchor and the PM tendon to match the lips together.

the successful transporting of the forces' affecting points from the contracting belly into the bone -by using anchors and slipable sutures- put the rupture lips out of the distracting effect, so it healed by fibromuscular integrating, and after few weeks, it became firm, strong and powerful enough to let our patient return gradually to his powerful sport.

Supplementary data to this article can be found online at <https://doi.org/10.1016/j.ijscr.2021.106428>.

Funding

This research did not receive any specific grant from any funding agencies in the public, commercial, or not-for-profit sectors.

Ethical approval

This study is exempt from ethical approval in our institution.

Consent

Written informed consent was obtained from the patient for publication of this case report and accompanying images. A copy of the written consent is available for review by the Editor-in-Chief of this journal on request.

Author contribution

Abdullah Noufal PhD, MD: conceptualization, investigation, data curation, writing, editing and reviewing.

Registration of research studies

Not applicable.

Guarantor

Abdullah Noufal PhD, MD.

Provenance and peer review

Not commissioned externally peer-review.

Declaration of competing interest

The author has no conflicts to disclose.

References

- [1] R.D. Travis, R. Doane, W.Z. Burkhead Jr., Tendon ruptures about the shoulder, *Orthop. Clin. N. Am.* 31 (2000) 313–330.
- [2] K. Bak, E.A. Cameron, I.J.P. Henderson, Rupture of the pectoralis major: a meta-analysis of 112 cases, *Knee Surg. Sports Traumatol. Arthrosc.* 8 (2000) 113–119.
- [3] S.W. Wolfe, T.L. Wickiewicz, J.T. Cavanaugh, Ruptures of the pectoralis major muscle: an anatomic and clinical analysis, *Am. J. Sports Med.* 20 (1992) 587–593.
- [5] A.W. ElMaraghy, M.W. Devereaux, A systematic review and comprehensive classification of pectoralis major tears, *J. Shoulder Elb. Surg.* 21 (2012) 412–422, <https://doi.org/10.1016/j.jse.2011.04.035>.
- [6] C.A. Haley, M.A. Zacchilli, Pectoralis major injuries: evaluation and treatment, *Clin. Sports Med.* 33 (4) (2014) 739–756, <https://doi.org/10.1016/j.csm.2014.06.005>.
- [7] K. Bak, E.A. Cameron, I.J. Henderson, Rupture of the pectoralis major: a meta-analysis of 112 cases, *Knee Surg. Sports Traumatol. Arthrosc.* 8 (2) (2000) 113–119, <https://doi.org/10.1007/s001670050197>.
- [8] J.E. McEntire, W.E. Hess, S.S. Coleman, Rupture of the pectoralis major muscle, *J. Bone Joint Surg. Am.* 54 (1972) 1040.
- [9] J. Manjarris, D.H. Gershuni, J. Moitza, Rupture of the pectoralis major tendon, *J. Trauma* 25 (1985) 810–811.
- [10] J. Liu, J. Wu, C. Chang, Y. Chou, W. Lo, Avulsion of the pectoralis major tendon, *Am. J. Sports Med.* 20 (1992) 366–368.
- [11] J.R. Kertzer, A.B. Richardson, Rupture of the pectoralis major muscle, *Am. J. Sports Med.* 17 (1989) 453–458.
- [12] J.Y. Park, J.L. Espinella, Rupture of the pectoralis major muscle: a case report and review of the literature, *J. Bone Joint Surg.* 52A (1970) 577–581.
- [13] T.M. Egan, H. Hall, Avulsion of the pectoralis major tendon in a weight lifter. Repair using a barbed staple, *Can. J. Surg.* 30 (1987) 434–435.
- [14] D.H. O'Donoghue, *Treatment of injuries to athletes*. 3rd edn, Saunders, Philadelphia Agha RA, Franchi T, Sohrabi C, Mathew G, for the SCARE Group. The

SCARE 2020 guideline: updating consensus Surgical CAse REport (SCARE) guidelines, *Int. J. Surg.* 2020 (84) (1976) 226–230.