

Received: 2014.07.31
Accepted: 2014.08.22
Published: 2014.11.23

Spontaneous Hemarthrosis Following Fibrinolytic Therapy for Acute Myocardial Infarction: A Case Report and Literature Review

Authors' Contribution:
Study Design A
Data Collection B
Statistical Analysis C
Data Interpretation D
Manuscript Preparation E
Literature Search F
Funds Collection G

ABDEF 1 **Mahmoud M. Ramadan**
B 2 **Iqbal S. Khan**
D 3 **Ousama Mahdi**

1 Department of Cardiology, Faculty of Medicine, Mansoura University, Egypt
2 Department of Orthopedic Surgery, Fujairah Hospital, Ministry of Health, Fujairah, United Arab Emirates
3 Department of Cardiology, Fujairah Hospital, Ministry of Health, Fujairah, United Arab Emirates





Corresponding Author: Mahmoud M. Ramadan, e-mail: amamod2020@yahoo.com
Conflict of interest: None declared

Patient: Male, 48
Final Diagnosis: Spontaneous hemarthrosis of right knee
Symptoms: A rapidly growing knee swelling was “witnessed” associated with severe tenderness, hotness and profound agony but without color change
Medication: —
Clinical Procedure: Suprapatellar arthrocentesis of the right knee joint
Specialty: Cardiology

Objective: Unusual clinical course
Background: Despite the widespread use of fibrinolytic therapy and the numerous reports on its bleeding complications, spontaneous hemarthrosis following fibrinolytic therapy is quite rare.
Case Report: We describe in this report a patient with no previous history of articular disease who developed a spontaneous right knee bloody effusion following fibrinolytic therapy using rt-PA for acute ST-elevation myocardial infarction. Furthermore, we provide a review of all cases of spontaneous hemarthrosis documented so far in the literature.
Conclusions: Several pre-existing joint diseases may predispose to hemarthrosis following fibrinolytic therapy, even in patients who deny previous or current articular disorders. Therefore, hemorrhage should be considered in the differential diagnosis of mono-arthritis following fibrinolytic therapy for STEMI.

MeSH Keywords: Hemarthrosis • Myocardial Infarction • Thrombolytic Therapy

Full-text PDF: <http://www.amjcaserep.com/abstract/index/idArt/892138>

 932  1  1  11



Background

Hemarthrosis is almost always associated with a history of previous trauma or joint instability. However, non-traumatic causes such as complications from oral anticoagulant use [1] and, less frequently, from heparin use have been reported [2].

Case Report

A 48-year-old Indian man, a previously healthy general labor worker, presented to the emergency room (ER) of Fujairah Hospital with central chest pain of 1-h duration referred to the left shoulder, associated with dyspnea and sweating. The patient was neither diabetic nor hypertensive, had never smoked,

and had normal lipid profile and negative family history of coronary artery disease. He was neither alcoholic nor a current drug user, with a lean body (57 Kg, body mass index 22 Kg/m²). There was no history of arthritis, arthralgia, joint trauma, previous joint operation, or increased tendency to bleeding, and he was taking no regular medications. He was hemodynamically stable, with blood pressure of 105/73 mmHg and pulse rate of 94/min (regular and full). The electrocardiogram showed extensive anterior wall ST-elevation myocardial infarction (STEMI). Laboratory tests showed: blood group A+ve, hemoglobin 15.7 g/dL, white blood cell count 10.4×10⁹/L, platelet count 324×10⁹/L, prothrombin time 11.9 s (INR=1.07), partial thromboplastin time 29.0 s, serum creatinine 96 µmol/L, random blood glucose 8.8 mmol/L, creatine kinase 196 U/L, lactate dehydrogenase 175 IU/L, and troponin-T 0.01 µg/L. The patient

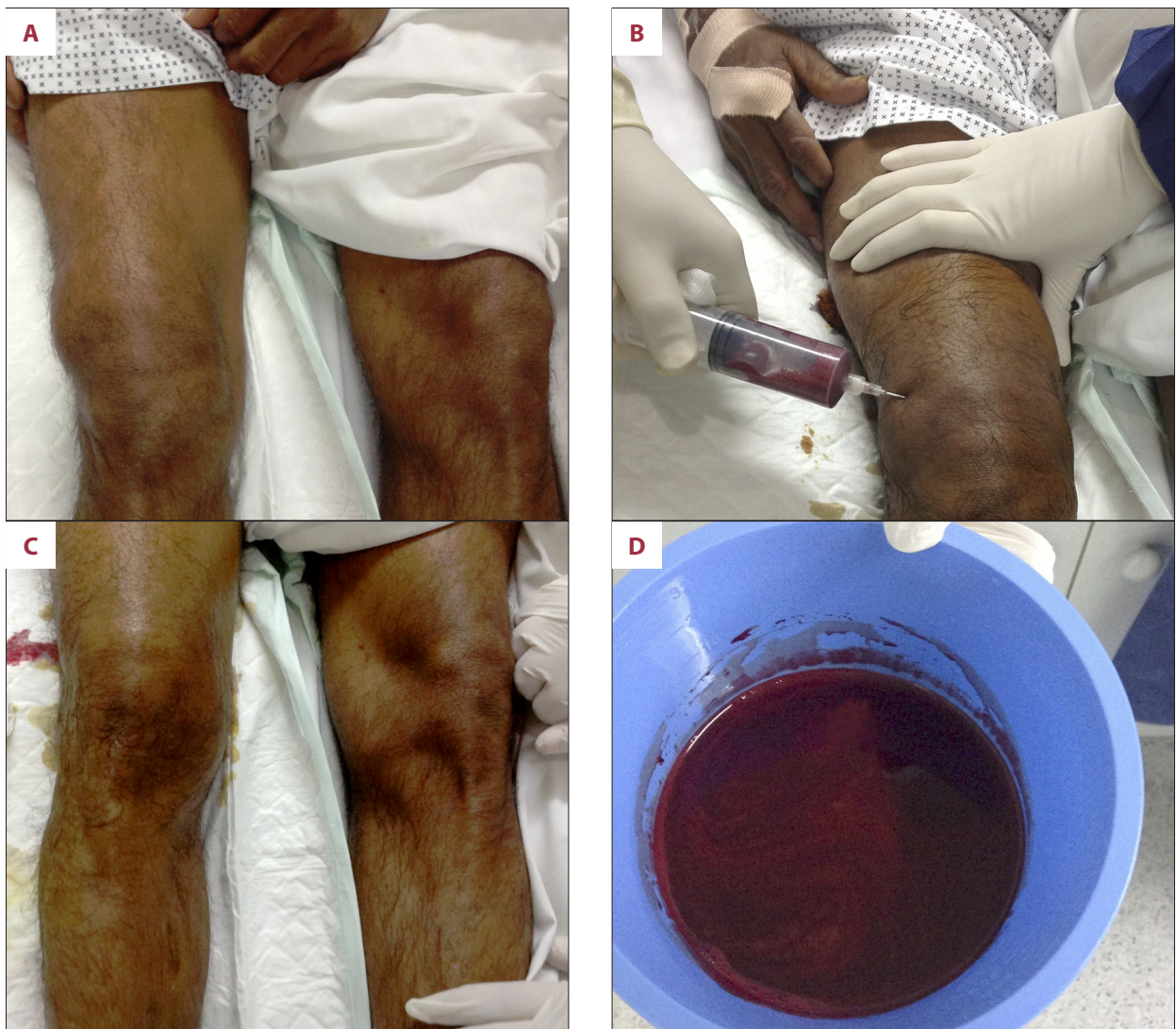

Figure 1. (A) Acute spontaneous hemarthrosis of the right knee joint. (B) Suprapatellar arthrocentesis (needle aspiration) of the right knee joint. (C) Post-aspiration, with a return to near-normal knee joint contour. (D) Frank blood (125 cc) aspirated from the right knee joint.

Table 1. Summary of all reports of spontaneous hemarthrosis, including the current report.

Serial	Source	Age (year)	Gender	Regular medications	FT	Others	Past History	Affected joint(s)	Radiographic investigations
Knee									
1.	[5]	63	Male	None	SK	ASA, UFH	Right knee meniscus removal 35 years before, and inflammation in the same joint 5 weeks before admission	Right knee	Patellofemoral osteoarthritis on X-ray
2.	[5]	68	Female	Prednisolone 10 mg every other day	SK	ASA, UFH	Pyoderma gangrenosa for 1 year associated with symmetric seronegative polyarthritis of both elbows and knees	Left knee (and right elbow)	Erosive polyarthritis of elbows and knees
3.	[6]	67	Male	None	rt-PA	UFH	No previous history of articular disease or trauma	Right knee	Osteoarthritis with chondrocalcinosis
4.	[6]	64	Male	None	SK	ASA	Osteoarthritis of both knees with bilateral patellectomy performed 4 years earlier	Left knee	Degenerative changes with chondrocalcinosis
5.	[7]	45	Male	None	SK, rt-PA	ASA, UFH	No previous history of articular disease or trauma	Right knee	Not mentioned
6.	[8]	64	Male	NSAID (irregular use for 10 years)	SK	ASA	Gout (10 years)	Both knees	Not mentioned
7.	Current report	48	Male	None	rt-PA	ASA, LMWH, Clopidogrel	No previous history of articular disease or trauma	Right knee	Moderate osteoarthritis with osteophytes
Ankle									
8	[9]	41	Male	None	rt-PA	ASA, UFH	Right ankle sprain (minor inversion injury) 4 days before the hemorrhagic event	Right ankle	Normal
9	[10]	40	Male	None	rt-PA	ASA, UFH	Right ankle tendinitis, previous surgery for flat foot.	Right ankle	Not mentioned
Shoulder									
10	[11]	50	Female	Anti-hypertensive drugs	SK	ASA	No previous history of articular disease or trauma	Right shoulder	Normal

ASA – acetyl salicylic acid; FT – fibrinolytic therapy; LMWH – low molecular-weight heparin; rt-PA – recombinant tissue-plasminogen activator; SK – streptokinase; UFH – un-fractionated heparin.

was given morphine, aspirin 300 mg, sublingual nitroglycerin 0.5 mg tablet, and oxygen, then was transferred to the care unit (CCU) of Fujairah Hospital where he was given fibrinolytic therapy (2 h after symptoms onset) in the form of Tenecteplase (Metalyse, recombinant tissue-plasminogen activator [rt-PA]) 6000 units by slow intravenous administration. Other medications included Clopidogrel 75 mg tablet daily, Atorvastatin

40 mg tablet daily, Carvedilol 3.125 mg tablets twice daily, and Enoxaparin low molecular weight heparin (LMWH) 60 mg subcutaneous injection/12 hours. Resolution of ST segment to baseline occurred 6 h after fibrinolytic therapy, with no reperfusion arrhythmias, and the patient was stable with normal hemodynamics. Diagnostic coronary angiography was done via right radial artery access 30 h after fibrinolytic intake, and revealed

proximal LAD 75% stenosis with normal other coronary vessels, but percutaneous coronary intervention was not done due to patient refusal. The radial puncture site was non-complicated, with good hand circulation on follow-up.

About 8 h after coronary angiography, the patient was hemodynamically stable (blood pressure of 110/70 mmHg and a regular pulse rate of 77/min), lying comfortably in bed, and while trying to modify his position to undergo the night-round clinical examination, he developed a sudden severe agonizing pain in his right knee. The knee was uncovered and a rapidly growing swelling was seen, associated with severe tenderness, heat, and profound agony, but without color change (Figure 1A). The orthopedist on call was immediately summoned to the CCU, and within 5 min he performed suprapatellar arthrocentesis (needle aspiration) of the right knee joint (Figure 1B). The knee swelling resolved, with a return to near-normal knee contour and marked pain relief (Figure 1C). Finally, 125 cc of frank blood were aspirated (Figure 1D). The aspirate was sterile, did not clot, and had a xanthochromic supernatant with absence of crystals. Aspirin, Clopidogrel, and Enoxaparin were temporarily withheld. The patient had no bleeding from any other site of his body, and urine analysis was normal. Three days after the first arthrocentesis, light ambulation was allowed and the previously withheld medications were resumed. Twelve hours later, final aspiration of 45 cc of frank blood was done (each joint aspiration was done under completely aseptic precautions followed by the application of pressure bandage and dressing). X-ray of the right knee joint showed moderate osteoarthritic changes with osteophytes. The patient was then discharged after a non-eventful hospital course. On follow-up, the patient showed complete resolution of the right knee hemarthrosis, with stable cardiac condition.

Discussion

Spontaneous hemarthrosis involving the knee joint after fibrinolytic therapy is very rare, and it has not been reported

References:

1. Andes WA, Edmunds JO: Hemarthrosis and warfarin: joint destruction with anticoagulation. *Thromb Haemost*, 1983; 49: 187–89
2. Salzman EW, Deykin D, Shaprio RM, Rosenberg R: Management of heparin therapy: controlled prospective trial. *N Engl J Med*, 1975; 292: 1046–50
3. ISIS-2 Collaborative Group: Randomized trial of intravenous streptokinase, oral aspirin, both, or neither among 17187 cases of suspected acute myocardial infarction: ISIS-2. *Lancet*, 1988; II: 349–60
4. The GUSTO investigators: An international randomized trial comparing four thrombolytic strategies for acute myocardial infarction. *N Engl J Med*, 1993; 329: 673–82
5. Oldroyd KG, Hornung RS, Jones AM et al: Spontaneous haemarthrosis following thrombolytic therapy for myocardial infarction. *Postgrad Med J*, 1990; 66: 387–88
6. Sanders PA: Haemarthrosis associated with thrombolytic therapy. *Br J Rheumatol*, 1991; 30: 236–37
7. Birnbaum Y, Stahl B, Rechavia E: Spontaneous hemarthrosis following thrombolytic therapy for acute myocardial infarction. *Int J Cardiol*, 1993; 40: 289–90
8. Pimenta E, Anti SM: Haemarthrosis of the knees following streptokinase therapy for acute myocardial infarction. *Arq Bras Cardiol*, 2003; 80: 641–42
9. Finlayson J, Dunsmuir RA: Haemarthrosis following thrombolytic therapy for acute myocardial infarction. *Injury*, 1997; 28: 146–47
10. Gallardo A, Gallego JC, Enero J et al: Hemarthrosis como complicación hemorrágica tras tratamiento trombolítico. *Rev Esp Cardiol*, 2001; 54: 1230–32
11. Zamani B, Talari HR: Hemarthrosis of the shoulder following streptokinase therapy for acute myocardial infarction. *Am J Case Rep*, 2008; 9: 389–91

in the studies involving a great number of patients using fibrinolytic therapy [3,4]. However, we identified 4 reports of 6 patients with spontaneous knee hemarthrosis following fibrinolytic therapy [5–8]. Notably, there are 2 other reports of 2 patients with spontaneous right ankle hemarthrosis after the use of rt-PA and un-fractionated heparin (UFH) [9,10]; and only 1 report of spontaneous right shoulder hemarthrosis after streptokinase (SK) therapy for acute STEMI [11]. Table 1 shows a summary of all reports of spontaneous hemarthrosis, including our current report. As shown in the table, the complication occurred due to the combined use of a fibrinolytic (streptokinase or rt-PA) with acetylsalicylic acid and/or heparin. Notably, LMWH (as well as Clopidogrel) was used only in our case. While it is difficult to imagine this complication occurring in a subject without any previous knee disease, it happened in 2 previously recorded similar cases [6,7] with ours as the third instance (Table 1).

Intensive care physicians and cardiologists must be aware of the possibility of rare complications like serious joint bleeding, which seems to be more frequent in previously compromised joints. Thus, caution should be observed in patients with active joint diseases or previous trauma/operations. This complication should have correct and early diagnosis with prompt aspiration of the blood and splinting to provide early relief of discomfort and prevention of further joint damage.

Conclusions

Several pre-existing joint diseases may predispose to hemarthrosis following fibrinolytic therapy, even in patients who deny previous or current history of articular disorders, as in this case. Therefore, hemorrhage should be considered in the differential diagnosis of mono-arthritis following fibrinolytic therapy for STEMI in addition to gout and pseudogout (both of which may be triggered by STEMI).