

Received: 2019.11.19

Accepted: 2020.01.21

Available online: 2020.02.24

Published: 2020.04.07

Disseminated Disease by *Mycobacterium abscessus* and *Mycobacterium celatum* in an Immunocompromised Host

Authors' Contribution:

Study Design A
Data Collection B
Statistical Analysis C
Data Interpretation D
Manuscript Preparation E
Literature Search F
Funds Collection G


ABEF **Maria Elena Locatelli**BD **Salvatore Tosto**BD **Vincenzo D'Agata**BF **Paolo Bonaventura**BD **Rosaria S. Grasso**EF **Andrea Marino**EF **Alessio Pampaloni**F **Daniele Scuderi**F **Federica Cosentino**ADEG **Bruno Cacopardo**

Division of Infectious Diseases, Department of Clinical and Experimental Medicine,
ARNAS Garibaldi Hospital, University of Catania, Catania, Italy

Corresponding Author: Maria Elena Locatelli, e-mail: mariaelena_locatelli@yahoo.it

Conflict of interest: None declared

Patient: Male, 62-year-old
Final Diagnosis: Disseminated disease by *Mycobacterium abscessus* and *Mycobacterium celatum*
Symptoms: Dyspnea • fever • pleural effusion • spleen nodules • splenomegaly
Medication: —
Clinical Procedure: —
Specialty: Infectious Diseases

Objective: Rare disease**Background:** Nontuberculous mycobacteria (NTM) are environmental pathogens that cause an increasing number of diseases, in particular in immunosuppressed patients. Diagnosing NTM infections may be difficult because clinical presentation is unspecific and resembles other conditions such as tuberculosis, lymphomas, or septicemia.**Case report:** We report the case of a 62-year-old male with a recent history of autologous bone marrow transplantation for a follicular lymphoma admitted to our department for long-lasting remittent fever and abscess-like splenic nodules. The patient was diagnosed with mixed systemic infection by *Mycobacterium abscessus* and *Mycobacterium celatum* localized in spleen, bone marrow and kidneys.**Conclusions:** In this case a rare disseminated atypical mycobacteriosis was diagnosed and treated. As far as we know this is the first case in the literature of *M. abscessus* localization either in the spleen or in the bone marrow. Our patient underwent a complex long-term therapy and had a complete resolution of the disease.**MeSH Keywords:** Immunocompromised Host • Mycobacterium Infections, Nontuberculous • Nontuberculous MycobacteriaFull-text PDF: <https://www.amjcaserep.com/abstract/index/idArt/921517>


1744



—



4



16



Background

Nontuberculous mycobacteria (NTM) represent an ubiquitous group of micro-organisms with life-threatening effects on elderly and immunocompromised patients, in particular those who underwent immunosuppressive therapy and patients in the Acquired immunodeficiency syndrome (AIDS) population [1]. The awareness on these pathogens is increasing because innovations in molecular techniques have improved the diagnosis of these previously unrecognized diseases [2]. Nevertheless, a NTM diagnosis is still very insidious: infections frequently develop with specific and variable symptoms that can deceive the clinician and can lead to misdiagnosis and delayed treatment.

Among NTM species, the most common rapidly growing mycobacterium is *Mycobacterium abscessus*, that causes 5–20% of all NTM infections [3]. It causes pulmonary infections in immunocompromised patients or inpatients with predisposing lung conditions such as bronchiectasis or cystic fibrosis [4], but it also can involve skin and soft-tissues infections.

Epidemiological data on *M. abscessus* are lacking, nevertheless, in the literature this mycobacterium is associated with significantly higher fatality rates than any other rapidly growing NTM species [5].

M. celatum is a slow-growing NTM, responsible for localized infections, mostly in the lungs or in lymph nodes as reported by Christiansen et al. in 2004. It is a rare cause of infection in humans, but it can develop into a fatal disease in immunocompromised patients and in immunocompetent patients as well [6].

Here, we report a case of simultaneous *M. abscessus* and *M. celatum* disseminated disease in a patient affected with prior B-cell lymphoma and persistent hypogammaglobulinemia.

Case Report

On February 9, 2018, a 62-year-old Caucasian male was admitted to the Unit of Infectious Diseases at the “Garibaldi” Hospital in Catania (eastern Sicily) due to long-lasting remittent fever.

In 1999, he was diagnosed with follicular B-cell non-Hodgkin lymphoma first treated with chemotherapy until 2000 and, after a relapse, with an autologous hematopoietic stem cell transplantation (HSCT) in 2003.

After the HSCT, the patient had persistent hypogammaglobulinemia and reported frequent hospital admissions due to recurrent respiratory infections.

In June 2017, gallbladder hydrops required an abdomen computed tomography (CT) scan (Figure 1) that showed a marked splenomegaly with several abscess-like splenic hypodense nodules (maximum 4 cm diameter). The patient underwent cholecystectomy, and during surgery, a spleen biopsy was performed, but unfortunately showed irrelevant results.

In November 2017, the patient was admitted to the Department of Internal Medicine for a 2-month remittent hyperpyrexia, partially susceptible to steroids and paracetamol. Under the suspicion of non-Hodgkin lymphoma relapse with splenic localization, the patient underwent a splenectomy with histological examination of his spleen. The histopathological examination of the surgical specimens showed multiple granulomatous lesions with necrotic focus and external giant pluri-nuclear cells, with extended vascularized areas, as well as the presence of many fibrotic regions and areas with polymorphic lymphoid infiltrates.

For the persistent fever, the patient was admitted to our department in January 2018. Upon hospital admission, physical examination was irrelevant except for hyperpyrexia (temperature >38°C), a post-surgery paramedian abdominal scar and a remarkable dullness at basal chest percussion on the left lung (Figure 2).

Blood examinations revealed neutrophilic leukocytosis (white blood cell 13 600 cell/mm³, absolute neutrophil count (ANC) 8300 cell/mm³), normocytic anemia with hemoglobin 11.1 g/dL, thrombocytopenia (62 000 cell/mm³), increased C-reactive protein (CRP) value of 4.04 mg/dL, hypoalbuminemia (2.57 g/dL), severe hypogammaglobulinemia (0.06 g/dL), hyponatremia (128 mEq/L, increased values of serum ferritin (642 ng/mL) and beta-2 microglobulin (4.37 mg/L). The value of procalcitonin was normal.

Repeated blood cultures and urine cultures were negative for bacteria and fungi. Lung and abdominal CT scan (Figure 3) showed left-sided pleural effusion, bilateral pulmonary ground-glass areas and mild pericardial effusion; in the abdomen, presence of multiple abscess-like hypodense nodules in the kidney, loculated effusion with perivisceral fat thickness and edematous imbibition of the muscles in the left hip.

The patient underwent thoracentesis with removal of 1200 mL of clear fluid, analyzed by Ziehl-Neelsen microscopy and GeneXpert test, both were negative for *M. tuberculosis*. Also, sputum, 24-hour collected urine and peritoneal fluid aspirate were analyzed by smear microscopy (Ziehl-Neelsen stain), mycobacteria growth indicator tube (MGIT) culture examination and nucleic acid amplification tests (NAATs) by Xpert MTB/RIF assay. All the examinations were negative for mycobacteria.

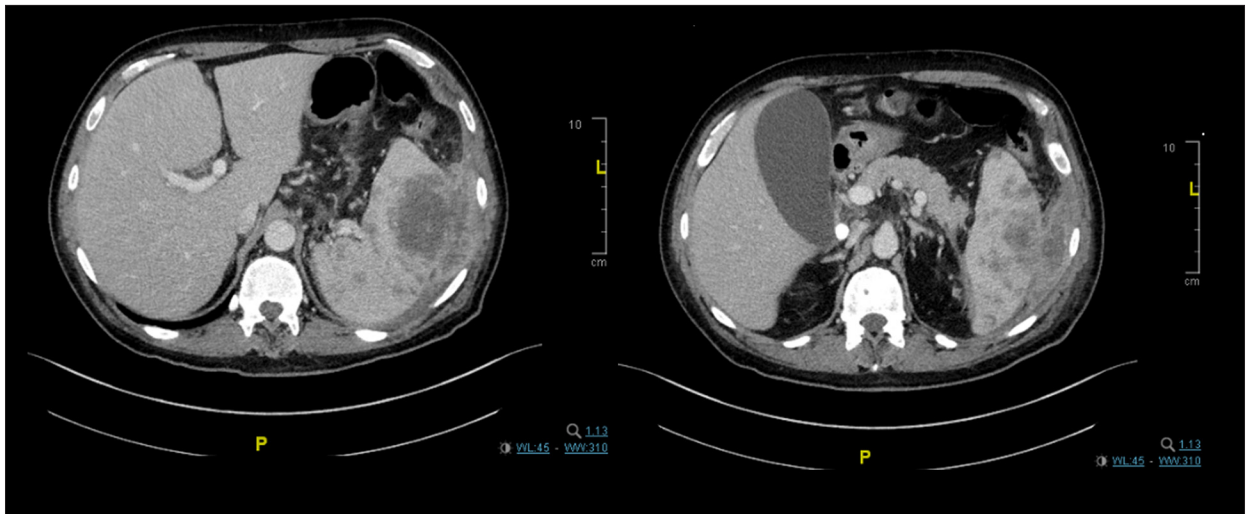


Figure 1. Accidental spleen nodules. Axial contrast-enhanced abdomen computed tomography scan (2 sections) showing gallbladder hydrops and splenomegaly (spleen bipolar diameter: 14 cm) with parenchymal alterations characterized by several abscess-like splenic hypodense nodules. Presence of peri-splenic fluid collection.

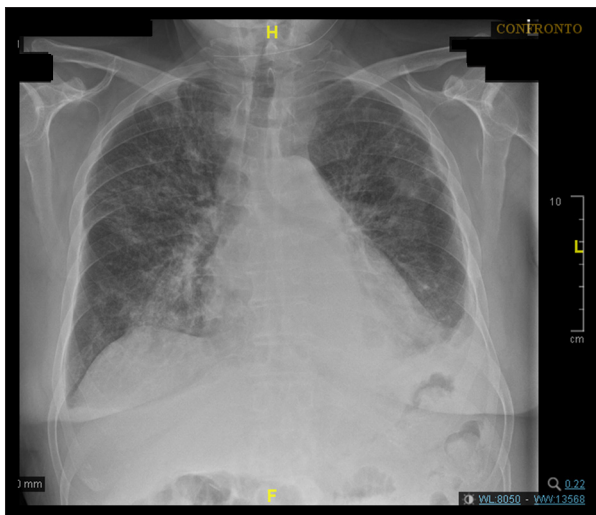


Figure 2. Lung involvement of the disease. Chest x-ray showing several bilateral parenchymal foci with ill-defined margins, localized mainly in the perihilar regions. Presence of left costophrenic angle blunting.

During hospitalization, the patient's clinical status progressively deteriorated: hyperpyrexia persisted with peaks $>39^{\circ}\text{C}$ and dyspnea occurred (oxygen saturation was 86% in room air). Thus, oxygen therapy was administered via Venturi mask (FiO_2 40%, oxygen saturation 91% with 10 L/minute). He also developed an anasarca-like edema, so both furosemide (50 mg/day) and albumin (10 mg/day) were infused intravenously.

On February 14, smears from previously removed spleen tissue aspirate were deparaffinized and together with bone marrow aspiration were screened "in situ" by multiplex real-time polymerase chain reaction (PCR) assay: both spleen tissue smears

and bone marrow aspiration resulted positive for *M. abscessus* and for *M. celatum*. Bone marrow aspirate was also cultured on Löwenstein-Jensen agar resulting positive for *M. abscessus* and *M. celatum* growth.

On the basis of such findings, starting from February 22, antibiotic treatment was administered with tigecycline 50 mg twice daily intravenously, amikacin 750 mg once daily intravenously, clarithromycin 500 mg twice daily by mouth, ciprofloxacin 500 mg twice daily by mouth, and clofazimine 100 mg once daily.

Within a week from the onset of treatment, the patient's fever decreased, and his clinical conditions improved with progressive amelioration of dyspnea. One month later, his biochemical examinations demonstrated a complete normalization of inflammatory markers. Tigecycline and amikacin were interrupted, and oral linezolid 300 mg twice daily was introduced. On March 30, the patient was discharged in good clinical status, without fever or dyspnea.

Two months after the discharge, the patient suffered from severe periumbilical abdominal pain, and underwent a pancolonoscopy that showed evidence of mucosal redness in the ileal tract. A biopsy of the ileum revealed clofazimine crystal-histiocytes in the lamina propria, thus clofazimine was interrupted. The patient continued with amikacin 750 mg intramuscularly while linezolid (300 mg twice daily), clarithromycin (500 mg twice daily) and ciprofloxacin (500 mg twice daily) orally.

Therapy was scheduled to be continued for as long as 12 months (Figure 4). On January 12, 2019, a thoracic and abdominal CT scan demonstrated the complete reabsorption of the

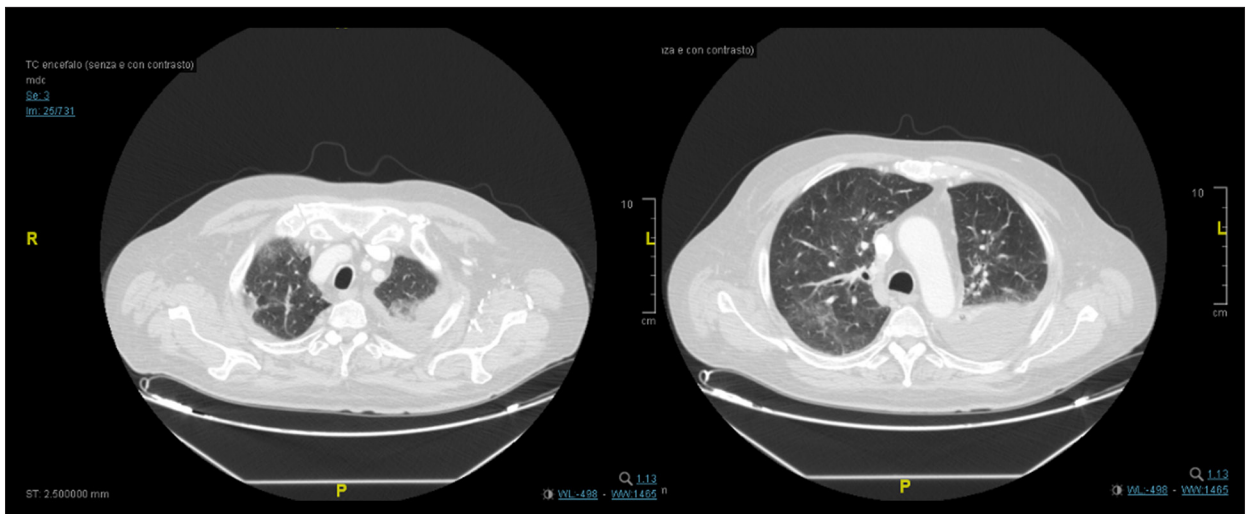


Figure 3. Progressive worsening of lung disease. Axial contrast-enhanced thorax computed tomography scan (2 sections) showing left-sided pleural effusion with parenchymal dysventilation; disseminated bilateral pulmonary “ground-glass” areas.

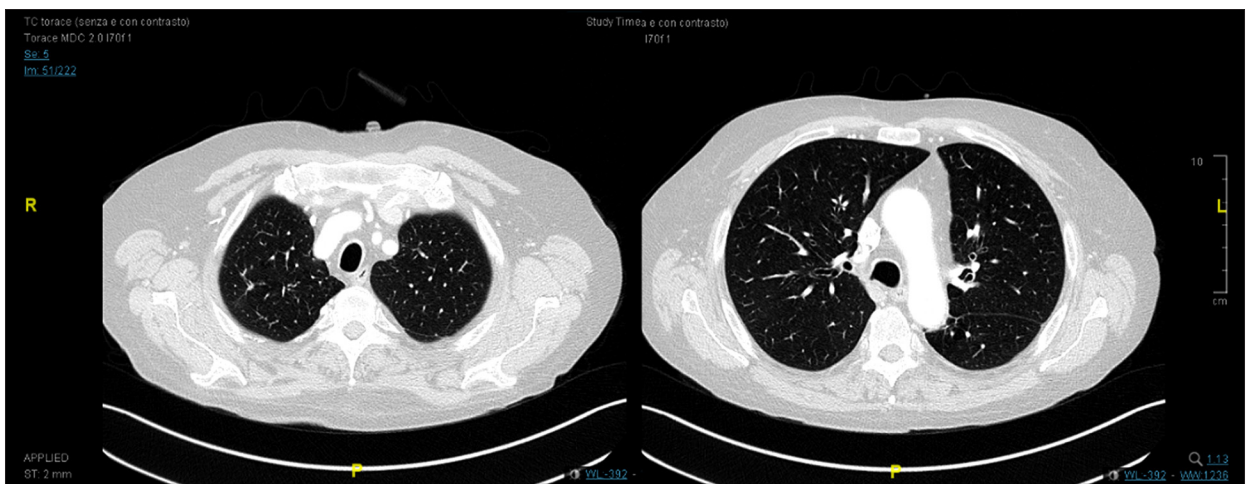


Figure 4. Improvement after 6 months of therapy. Axial contrast-enhanced thorax computed tomography scan (2 sections) showing fairly complete resolution of bilateral “ground-glass” areas, persistence of few small foci in the middle lobe. Minimum left-sided pleural effusion.

intra-abdominal abscesses. It also showed the complete recovery of pericardial and pleural effusions, and of the ground-glass lung infiltrates. On February 15, 2019, therapy was interrupted after 12 months of continuous administration. The patient had an excellent clinical status, apart from subclinical hearing loss as assessed by pure-tone audiometry, which was performed in a standard soundproof cabin. He has returned to his job and to low-intensity sports training.

Discussion

Our clinical case describes a disseminated disease by *M. abscessus/celatum* in a severely immunocompromised individual. Immune suppression was provoked either by HSCT or by a

persistent hypogammaglobulinemia, which required periodic immunoglobulin intravenous infusions.

NTM infections are 50 to 600 times more frequent in solid organ transplantation [7], HSCT recipients [8] than in the general population, and also the mortality rate is higher in the first population than in the latter one. *M. avium complex* (MAC) is the most frequent NTM species to cause disseminated infections in transplanted population. Allogeneic HSCTs are greater risk factors for NTM infections than autologous transplantations. Causes of NTM infections are mainly unrecognizable: in HSCT, there are very little possibilities that the donor bone marrow could be infected by NTM and could transmit to recipient. In 2017 a *M. abscessus* outbreak occurred in a hospital in North Carolina (USA) and caused 126 infections, 5 cases

of which in HSCT recipients [9]. Compared to *Mycobacterium tuberculosis*, in HSCT NTM are more correlated to Central venous catheter-associated infections. In HSCT population, the most common NTM infections are localized in lungs, with nodules, necrotizing pneumonia, cavitation, or pleural effusions. Other NTM infections can involve skin, gastrointestinal tract and hematopoietic system with necrotizing granulomas [10]. Complete recovery from NTM disease is seldom possible and new infections with other strains of NTM or even relapse of the original NTM is not uncommon.

M. abscessus complex might cause pulmonary, cutaneous, and disseminated infections in solid organ transplant recipients as reported by Smibert et al. 2016 [11]. In 2018, Salvator et al. [12] reported a pulmonary *M. abscessus* infection soon after allogeneic HSCT. Also, Morales in 2010 [13] described 8 clinically relevant cases of *M. abscessus* infection with both cutaneous and respiratory localizations among bone marrow transplant recipients. Nevertheless, as far as we know there are no reports of bone marrow localization by *M. abscessus* in literature.

Thus, the present case represents the first reported case of *M. abscessus* localization either in the spleen or in the bone marrow. Also, no human case of *M. celatum* splenic, bone marrow, and renal infection has been described so far. Even in our experience we could not assess the actual role of *M. celatum* whether as a co-pathogenic agent or as a mere innocent bystander.

In our clinical case, the patient was successfully treated for as long as 12 months with a complex drug combination, which started with tigecycline, amikacin, clarithromycin orally, ciprofloxacin orally, and clofazimine orally, then shifted towards oral linezolid, clarithromycin, and ciprofloxacin.

References:

1. Prevots DR, Marras TK: Epidemiology of human pulmonary infection with nontuberculous mycobacteria: A review. *Clin Chest Med*, 2015; 36(1): 13–34
2. Henkle E, Winthrop KL: Nontuberculous mycobacteria infections in immunosuppressed hosts. *Clin Chest Med*, 2015; 36(1): 91–99
3. Roux AL, Catherinot E, Ripoll F et al: Multicenter study of prevalence of nontuberculous mycobacteria in patients with cystic fibrosis in France. *J Clin Microbiol*, 2009; 47(12): 4124–28
4. Kwon YS, Koh WJ: Diagnosis and treatment of nontuberculous mycobacterial lung disease. *J Korean Med Sci*, 2016; 31(5): 649–59
5. Moore M, Frerichs JB: An unusual acid-fast infection of the knee with subcutaneous, abscess-like lesions of the gluteal region; Report of a case with a study of the organism, *Mycobacterium abscessus*, n. sp. *J Invest Dermatol*, 1953; 20(2): 133–69
6. Christiansen DC, Roberts GD, Patel R: *Mycobacterium celatum*, an emerging pathogen and cause of false positive amplified *Mycobacterium tuberculosis* direct test. *Diagn Microbiol Infect Dis*; 2004; 49(1): 19–24
7. Anjan S, Morris MI: How can we improve the outcome for transplant patients with nontuberculous mycobacterial infections? *Future Microbiol*, 2018; 13: 903–914.
8. Hou R, Nayak R, Pincus SM et al: Esophageal *Mycobacterium avium*-intracellular infection in a bone marrow transplant patient: Case report and literature review. *Transpl Infect Dis*, 2019; 21(1): e13019
9. Baker AW, Lewis SS, Alexander BD et al: Two-phase hospital-associated outbreak of *Mycobacterium abscessus*: investigation and mitigation. *Clin Infect Dis*, 2017; 64(7): 902–11
10. Al-Anazi KA, Al-Jasser AM, Al-Anazi WK: Infections caused by non-tuberculous mycobacteria in recipients of hematopoietic stem cell transplantation. *Front Oncol*, 2014; 4: 311
11. Smibert O, Snell GI, Bills H et al: *Mycobacterium abscessus complex* – a particular challenge in the setting of lung transplantation. *Expert Rev Anti Infect Ther*, 2016; 14(3): 325–33
12. Salvator H, Berti E, Catherinot E et al: Pulmonary alveolar proteinosis and *Mycobacterium abscessus* lung infection related to ruxolitinib after allogeneic stem cell transplantation. *Eur Respir J*, 2018; 51(5): pii: 1701960
13. Morales P, Gil A, Santos M: *Mycobacterium abscessus* infection in transplant recipients. *Transplant Proc*, 2010; 42(8): 3058–60
14. Griffith DE, Aksamit T, Brown-Elliott BA et al: An official ATS/IDSA statement: Diagnosis, treatment, and prevention of nontuberculous mycobacterial diseases. *Am J Respir Crit Care Med*, 2007; 175(4): 367–416
15. Ryu YJ, Koh WJ, Daley CL: Diagnosis and treatment of nontuberculous mycobacterial lung disease: Clinicians' perspectives. *Tuberc Respir Dis (Seoul)*, 2016; 79(2): 74–84
16. Singh H, Azad K, Kaur K: Clofazimine-induced enteropathy in a patient of leprosy. *Indian J Pharmacol*, 2013; 45(2): 197–98

As reported by Griffith et al. in 2007 [14], macrolides are the only oral agents reliably active *in vitro* against *M. abscessus*. These authors declared that this mycobacterial infection generally has low or intermediate minimum inhibitory concentrations (MICs) to amikacin, cefoxitin, linezolid, and clofazimine. More recently, Ryu et al. [15] suggested the efficacy of macrolide therapy in addition to fluoroquinolone, linezolid, clofazimine, or amikacin for long-term treatments, but never shorter than 12 months comprehensively.

It should be remarked that our patient suffered a severe abdominal distress due to intestinal deposition of crystallized clofazimine. Crystallization of clofazimine in high dosage over prolonged periods is a rare but well-recognized condition known to occur in various tissues [16]. The prompt withdrawal of clofazimine administration is required in order to avoid a life-threatening evolution. In the present case, this unusual side effect forced us to return towards intramuscular amikacin in order to maintain an effective and synergic drug combination. Unfortunately, yet expectedly, a mild hearing loss was ascertained after the 12-month treatment course.

Conclusions

This article has discussed the protracted management of both *M. abscessus* and *M. celatum* infections in an immunosuppressed patient. Infections caused by these mycobacteria localized either in the spleen or in the bone marrow represent a clinical challenge because of the poor prognosis of the condition and the small number of cases described in the literature. Our case report may be considered a model for the management of other similar conditions.