



Case report

Vesicovaginal fistula with bladder and vaginal stone

Ahmad Agil^{*}, Aninditho Dimas Kurniawana

Department of Urology, Hasan Sadikin Academic Medical Center/Faculty of Medicine, Universitas Padjadjaran, Bandung, Indonesia



ARTICLE INFO

Keywords:

Vesicolithiasis
Suture
Hanging calculus
Vesico-vaginal fistula

ABSTRACT

Introduction: In developing countries, Vesico-vaginal fistula (VVF) results following obstetric trauma or iatrogenic during hysterectomy. Large calculus associated with VVF is relatively rare, with the risk factor are presence of foreign body, urinary tract infection, and prolonged duration of disease. Most bladder stones can be found among patients who are bedridden, indwelling urethral catheter, bladder outlet obstruction, infection, and other similar characteristic. We report a case of VVF with bladder and vaginal stone in 37 years old woman and reviews the evaluation and treatment and highlights the role of the healthcare team in managing patients with this condition. **Presentation of case:** A 37-year-old, P2A0, woman with a history of hysterectomy three years ago. Intermittent small amounts of watery vaginal discharge developed 1,5 years after the operation. A physical examination revealed mild tenderness over the suprapubic area and no evidence of uterine prolapse. Cystography computed tomography scan with contrast confirmed a fistula vesicovagina with a connection between posterosuperior wall of vesica urinaria and anterosuperior wall of vagina with vesicolithiasis, size $15 \times 26 \times 14$ mm and two vaginal stone with size of $7 \times 12 \times 17$ mm and $4 \times 4 \times 5$ mm. Cystoscopy revealed a grayish stone identified in supratrigone with size of 30×12 mm.

Discussion: A hanging intravesical stone on the dome of urinary bladder is scarce, possibly caused by any synthetic and non-absorbable suture material inside of the bladder were encrusted forming a bladder stone. Important risk factors known, which is specific in developing countries, are poor socioeconomic status, mal-nourishment, low literacy rate, early marriage and childbearing, and inadequate obstetrical care.

Conclusion: Although the incidence of VVF accompanied by hanging vaginal stone and a large bladder stone is scarce, reports of any case regarding this study can be beneficial to other studies. Due to its harmful effect, the usage of non-absorbable sutures material during surgery isn't suggested. Hence, the absorbable suture material usage with careful dissection is suggested for any gynecological or pelvic surgery.

1. Introduction

Vesico-vaginal fistula (VVF) is an anomalous communication between the bladder and vagina, resulting in continuous urine leakage through the vagina, this condition is the most common type of urogenital fistula [1]. VVF is mostly caused by trauma during childbirth, obstetric and gynecological operations. In 85 % of patients, VVF occurs after gynecological surgery, in 11 % after childbirth, and in 4 % after radiation exposure [2]. In developing countries, VVF may occur following obstetric trauma especially obstructed labor with resulting pressure necrosis or iatrogenic during hysterectomy [1,3]. However, VVF formation also possible to be triggered by acquired variables—obstetric surgical, malignant, radiation, and miscellaneous categories—and congenital variables, mostly are urogenital malformations and rarely happens [4,5].

Bladder stones are the most common manifestation of lower urinary tract stones, accounting for 5 % of urinary stones and nearly 1.5 % of all patients in the urology hospitalizations [6]. Most bladder stones can be found among patients who are bedridden, indwelling urethral catheter, bladder outlet obstruction, infection, and other similar characteristic [7]. Several studies have reported that intrauterine contraceptive device (IUD) migrated through the wall of urinary bladder and the serve as a nidus of intravesical stone formation [8,9]. Stone formation can also be found due to precipitation of suture material within the bladder cavity and inadvertent intravesical suture during hysterectomy [10,11]. Large calculus is associated with VVF is relatively rare, the risk factor are presence of foreign body, urinary tract infection, and prolonged duration of disease [2]. Stone can be identified radiologically in 7 % of VVF using excretory urogram [3].

A hanging intravesical stone on the dome of urinary bladder is rare.

^{*} Corresponding author.

E-mail address: ahmadagil@gmail.com (A. Agil).

<https://doi.org/10.1016/j.ijscr.2022.107311>

Received 23 February 2022; Received in revised form 12 June 2022; Accepted 12 June 2022

Available online 14 June 2022

2210-2612/© 2022 Published by Elsevier Ltd on behalf of IJS Publishing Group Ltd. This is an open access article under the CC BY-NC-ND license (<http://creativecommons.org/licenses/by-nc-nd/4.0/>).

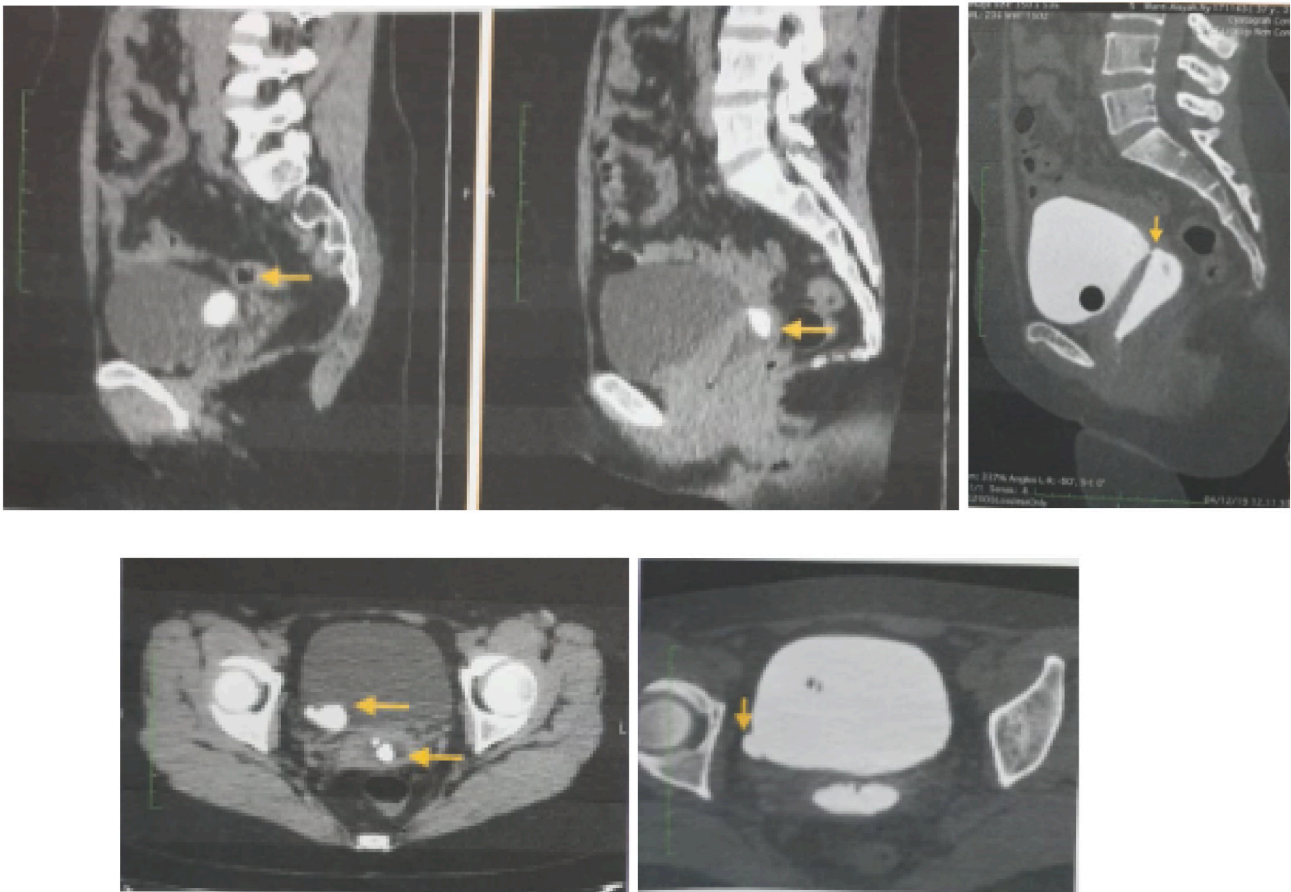


Fig. 1. Cystography CT Scan with contrast, Cahya Kawaluyan Hospital, 04-12-2019.

The incidence of IUD migrating to adjacent organ is between 1 and 3 %. Any synthetic and non-absorbable suture material inside of the bladder was encrusted to become a bladder stone. The underlying mechanism would be that the suture penetrated through the dome of urinary and then caused the deposition of calcium salts [5]. Some urological and non-urological surgeries with proximity to bladder have been reported to have such a complication [10]. The exact relationship between stone formation and VVF is still not known. However, it is possibly caused by the ulceration and erosion of stone caused VVF while others suggest that formation of stones is mainly due to urinary stasis and frequent infection caused by abnormalities of urogenital tract, such as vaginal fistulas and vaginal obstruction [12].

The diagnostic workup should be comprehensive as the majority of VVF require definitive surgical management. Timing, approach, graft usage, postoperative management, and surgical expertise must be optimized when exercised for successful management. The primary complication of VVF surgery is recurrent fistula formation [3].

We report a case of a probable iatrogenic VVF sutured with non-absorbable material progressing to nidus for bladder and vaginal stone in 37 years old woman. We would like to review and evaluate the treatment, and highlights the role of the healthcare team in managing patients with this condition.

2. Case presentation

A 37-year-old, P2A0 woman was referred to our urology clinic because of persistent dysuria, urinary frequency and urgency for a year, despite of antibiotic treatment. She had a history of abdominal hysterectomy 3 years ago due to atonia uteri during her 2nd child delivery. Intermittent small amounts of watery vaginal discharge developed 1.5

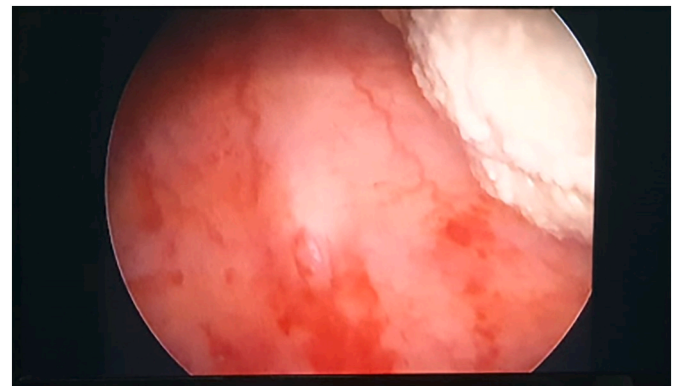


Fig. 2. Vesicovaginal fistula during cystoscopy.

years after the operation. She sought medical aid for these symptoms at the gynecological department, but without improvement.

Laboratory test shows Hb 14.2 g/dl, white blood counts of 6600/ μ L, with blood urea nitrogen of 23,9 mg/dL, and blood creatinine of 0,73 mg/dL. Urinalysis showed 15–18 white blood cells per high power field, and positive *Trichomonas* in the urine.

Cystography computed tomography scan with contrast confirmed a VVF with a connection between posterosuperior wall of vesicaurinary and anterosuperior wall of vagina with vesicolithiasis, size 15 \times 26 \times 14 mm and two vaginal stone with size of 7 \times 12 \times 17 mm and 4 \times 4 \times 5 mm (Fig. 1).

After careful discussion about further planning, we performed cystoscopy which revealed VVF and bladder stone (Fig. 2).

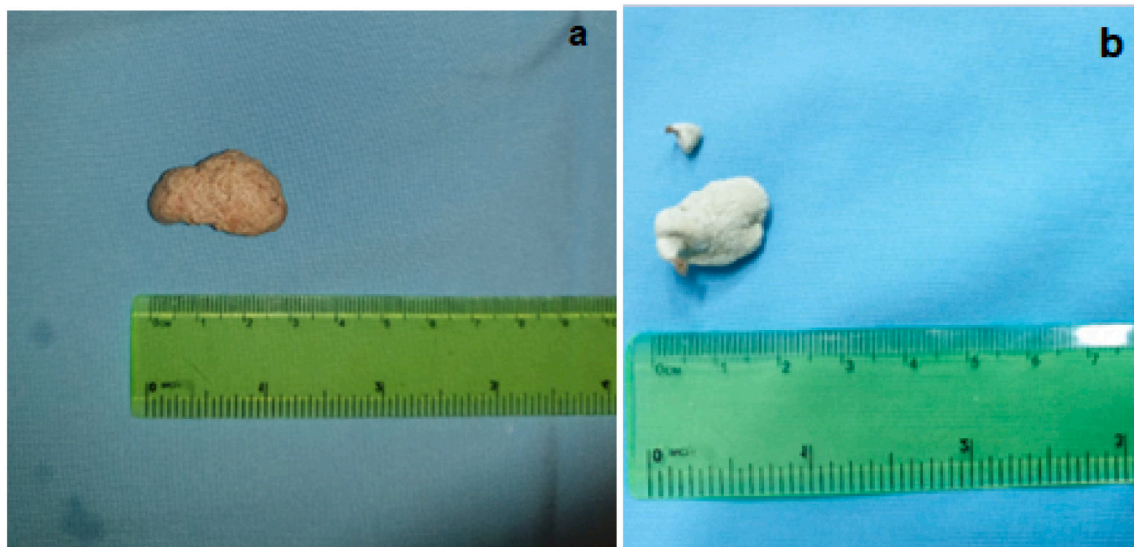


Fig. 3. a. Bladder stone. b. Sutures materials and vaginal stone.

The patient opted for open vaginal identification. In this operation, the intravaginal stone adherence with the fistula site was extracted but the location of the fistula was too high to be repaired trans-vaginally, so we decided to do trans-vesically.

A grayish stone was identified high above the trigone with the size of 30×12 mm (Fig. 3a) while two grayish vaginal stone with the size of 20×8 mm and 4×4 mm were also identified with remnants of suture materials attached to them (Fig. 3b). After the stone and non-absorbable suture material remnant was already taken, we repaired the fistula with two layers closure using absorbable suture material. At the end of the procedure, the patient shows satisfactory results at the postoperative follow-up, with no further complications.

3. Discussion

Most common cause of VVF are caused by obstetrical and gynecological injury. Hysterectomy is the most common gynecological surgery resulting in VVF formation, accounting for 80 % of the annual incidence in developed countries. The rate of VVF formation varies with the surgical approach, which the highest is laparoscopic procedures, followed by transabdominal and transvaginal approach [4,13].

In the developed countries, the most common cause of VVF is gynecological surgery, such as obstructed labor and the resulting pressure necrosis. Other risk factors that contributed to VVF formations are poor socioeconomic status, malnourishment, low literacy rate, early marriage and childbearing, and inadequate obstetrical care [1,5]. Iatrogenic suture within the bladder is also important in VVF formation, specifically the non-absorbable, leading to aggregation of crystal and form stone around it, which correlated with our patient who had a history of abdominal hysterectomy 3 years ago [5,10,14–16]. Hence, the classic clinical presentation of a patient with VVF is continuous urinary incontinence after recent pelvic surgery. However, the severity of symptomatology and timing of presentation is variable [1,6,7,13]. Also, urine leaking through the vagina 7–12 days after gynecological or pelvic surgery caused by tissue necrosis can be found [5,17,18]. The diagnosis can be confirmed by completing a tampon dye test, which confirmed by blue dye on the gauze near the apex. Otherwise, if the dye is only noted on the distal tampon, this may represent spillage of the dye during filling or other forms of urinary incontinence [14].

Clinical symptoms of bladder stones with VVF can include recurrent urinary tract infections, pyuria, suprapubic pain, severe swelling of the perineum, hematuria, and usually also presents with lower urinary tract symptoms (LUTS), such as pain, urgency, and intermittency on voiding.

The severity of leakage can be reduced due to the “ball valve” effect caused by vesicle stones [19].

Important imaging tools for bladder stone evaluation and diagnosis used in VVF are abdominal plain x-ray, ultrasonography (USG), intravenous urography (IVU) and Multi-slice computed tomography (MSCT). Most clinicians use KUB (plain kidney, ureter, and bladder) X-ray and ultrasound for initial examination. Abdominal radiography may reveal intravesical stone, along with ultrasound evaluation [10]. Vesical stone usually accumulate in the bottom of the urinary bladder because of gravitation. Meanwhile, a hanging intravesical stone supra trigone is rare. However, it implies that the patient has undergone procedure in the neighborhood region such as hysterectomy or placement of IUD [5]. Transvaginal ultrasonography may clearly visualize the exact size, site, and course of the fistula. Transvaginal sonographic evaluation is well-tolerated with a low side-effect profile and more instructive than some other conventional investigations [11].

Cystoscopy is of particular help and can be used to identify the exact location of the fistula tract in the bladder [6]. Vaginoscopy can be easily performed in the office, which is also well-tolerated by patients, used to localize the fistula opening on the vaginal side [18]. Contrast studies, such as a multiphasic CT urogram, is recommended for pre-operative, to identify concomitant ureteral fistulas or abnormalities. More invasive and advanced techniques are generally not required but may include endoanal ultrasound or subtraction magnetic resonance (MR) fistulography [16,20]. Preoperative MR imaging may be required to assess patients with complex fistulas, to prevent complications in operations [21].

The management of VVF operations is usually transvaginal or abdominal through a transvesical approach, depending on the size and location of the fistula, the surgeon's experience, and the need for concurrent action [4,14,20,22]. Stone management depends on the size. It can be treated through cystolitholapaxy when it is <3 cm, whereas open cystolithotomy is recommended when it is >3 cm. For small, early-detected, and non-malignant VVF, conservative management can be pursued to help in spontaneous closure of the defect. Hence, conservative management couldn't be done in our patient [4,13,17,19].

The two-stage operation (delayed repair), consisting the removal of the stone with an endoscopic technique or open cystolithotomy, followed by VVF management for three months postoperative, usually are required in handling bladder stones with VVF to assess inhibition in fistula healing due to infection or inflammation [2]. However, in our patient, a one-stage operation (immediate repair) was performed because no signs of infection nor edema are detected. The transvesical

Table 1

Examination results in our patient.

Clinical examination	Normal vital signs
Physical examination	- Mild tenderness over the suprapubic area - No evidence of uterine prolapse - Vulva was within normal limit - There are stones palpated during vaginal touchers
Laboratory test	- Hb 14.2 g/dl - White blood counts of 6600/ μ L - Blood urea nitrogen of 23,9 mg/dL - Blood creatinine of 0,73 mg/dL - Urinalysis: - 15–18 white blood cells per high power field - positive Trichomonas in the urine

repair is used due to the large bladder stone and the high level of the fistula's location. After the procedure, the patient shows satisfactory results at the postoperative follow-up, with no further complications.

4. Conclusion

Although the incidence of VVF accompanied by hanging vaginal stone and a large bladder stone is scarce, reports of any case regarding this study can be beneficial to other studies. Due to its harmful effect, the usage of non-absorbable sutures material during surgery isn't suggested. Hence, the absorbable suture material usage with careful dissection is suggested for any gynecological or pelvic surgery (Table 1).

Declaration of competing interest

Authors have no conflicts of interest.

Acknowledgements

Authors would like to thank Department of Urology of Universitas Padjadjaran for all the support in the making of this manuscript.

Funding

No source of support contributing to this manuscript.

Ethical approval

This study has been approved by Hasan Sadikin ethical committee.

Consent

Written informed consent was obtained from the patient for publication of this case report and accompanying images. A copy of the written consent is available for review by the Editor-in-Chief of this journal on request.

Author contribution

Ahmad Agil: Analysis and interpretation of data, drafting the article.
Aninditho Dimas Kurniawan: Analysis and interpretation of data, drafting the article.

Registration of research studies

Not applicable.

Guarantor

Ahmad Agil.

References

- [1] S. Patankar, S. Dobhada, M. Bhansali, Vesicovaginal fistula with secondary vaginal stones, *J. Laparoendosc. Adv. Surg. Tech.* 16 (4) (2006) 386–389.
- [2] A. Sawant, A.S. Tamhankar, P. Pawar, G.V. Kasat, L. Kapadnis, Large dumbbell shaped vesicovaginal calculus managed with holmium laser cystolithotripsy followed by staged repair of vesicovaginal fistula, *J. Clin. Diagn. Res.* 10 (9) (2016), PD23–5.
- [3] A.I. Akamaguna, J.C. Odita, L.N. Ajabor, E.E. Okpere, Radiology of obstetric vesicovaginal fistula, *Urol. Radiol.* 5 (1) (1983) 247–250.
- [4] S.N. Shephard, S.J. Lengmang, C.V. Kirschner, Bladder stones in vesicovaginal fistula: is concurrent repair an option? Experience with 87 patients, *Int. Urogynecol. J.* 28 (4) (2017) 569–574, <https://doi.org/10.1007/s00192-016-3142-1>. Available from: .
- [5] C.M. Lu, Intravesical stone formation several years after hysterectomy: A case report, *J. Med. Case Rep.* 7 (Figure 2) (2013) 2–4.
- [6] A. Cardoso, A. Paes, T. Teixeira, Giant bladder stone in a patient with Vesicovaginal fistula caused by bladder wall ischemia due to unassisted prolonged labor in the Amazon jungle, *Int. J. Med. Rev. Case Rep.* 2 (Reports in Surgery and Dermatolo) (2018) 82.
- [7] B.F. Schwartz, M.L. Stoller, The vesical calculus, *Urol. Clin. North Am.* 27 (2) (2000) 333–346.
- [8] D. Demirci, O. Ekmekçioglu, A. Demirtaş, I. Gülmez, Big bladder stones around an intravesical migrated intrauterine device, *Int. Urol. Nephrol.* 35 (4) (2003) 495–496.
- [9] H. Atakan Rfan, M. Kaplan, E. Ertrk, Intravesical migration of intrauterine device resulting in stone formation, *Urology* 60 (5) (2002) 911.
- [10] H. Köseoğlu, R.Y. Akman, Suture related iatrogenic bladder stone, *J. Urol. Surg.* 1 (1) (2014) 44–45.
- [11] W.H. Chien, C.C. Liang, Iatrogenic bladder stone and associated vesicovaginal fistula after hysterectomy, *Gynecol. Surg.* 3 (2) (2006) 134–135.
- [12] T.A. Kurmanov, G.U. Kulkayeva, A.F. Shakirova, S.B. Shalekenov, S. B. Mugalbekov, D.D. Mustafinov, Primary vaginal stone associated with vesicovaginal fistula: a case report, *Urol Case Reports [Internet]* 40 (2022), 101917, <https://doi.org/10.1016/j.eur.2021.101917>.
- [13] Kholis K. Francisca, M.A. Palinrungi, S. Syahrir, Faruk M. Syarif, Bladder stones associated with vesicovaginal fistula: A case report, *Surgical Associates Ltd, Int J Surg Case Rep [Internet]* 75 (2020) 122–125, <https://doi.org/10.1016/j.ijscr.2020.09.028>. Available from: .
- [14] D. Dalela, A. Goel, S.N. Shakhwar, K.M. Singh, Vesical calculi with unrepaired vesicovaginal fistula: a clinical appraisal of an uncommon association, *J. Urol.* 170 (6) (2003) 2206–2208.
- [15] J.M. Kaminski, A.R. Katz, S.C. Woodward, Urinary bladder calculus formation on sutures in rabbits, cats and dogs, Available from, *Surg. Gynecol. Obstet.* [Internet] 146 (3) (1978 Mar) 353–357, <http://www.ncbi.nlm.nih.gov/pubmed/625671>.
- [16] J.W.H. Evans, C.R. Chapple, D.J. Ralph, E.J.G. Milroy, Bladder calculus formation as a complication of the stamey procedure, *Br. J. Urol.* 65 (6) (1990) 580–582.
- [17] R.A. Agha, M.R. Borrelli, R. Farwana, K. Koshy, A.J. Fowler, D.P. Orgill, et al., The SCARE 2020 statement: updating consensus surgical CAse REport (SCARE) guidelines, *Int. J. Surg. [Internet]*. 60 (October) (2020) 132–136, <https://doi.org/10.1016/j.ijso.2020.10.028>. Elsevier Available from: .
- [18] S. Rajaian, N.S. Kekre, Vesicovaginal fistula with large bladder calculus, *ANZ J. Surg.* 82 (4) (2012) 278–279.
- [19] M.S. Litschgi, J.J. Benz, E. Glatthaar, Bladder stones as a complication of gynecologic surgery, Available from, *Fortschr. Med.* [Internet] 93 (32) (1975 Nov 13) 1627–1628, <http://www.ncbi.nlm.nih.gov/pubmed/1221001>.
- [20] M.A. Malik, M. Sohail, M.T.B. Malik, N. Khalid, A. Akram, Changing trends in the etiology and management of vesicovaginal fistula, *Int. J. Urol.* 25 (1) (2018) 25–29.
- [21] S. Dwarkasing, S.M. Hussain, W.C.J. Hop, G.P. Krestin, Anovaginal fistulas: evaluation with endoanal MR imaging, *Radiology* 231 (1) (2004) 123–128.
- [22] M.H. Cheng, H.T. Chao, H.C. Horng, M.J. Hung, B.S. Huang, P.H. Wang, Vesical calculus associated with vesicovaginal fistula, Elsevier Taiwan LLC, *Gynecol Minim Invasive Ther [Internet]* 3 (1) (2014) 23–25, <https://doi.org/10.1016/j.gmit.2013.07.009>. Available from: .