




# Management of Bone Failure in Fracture of the Distal Region of the Femur Using the Masquelet Technique with Fibula Graft Associated with Iliac-Crest Graft: Report of Two Cases\*

## *Manejo de falha óssea em fratura da região distal do fêmur pela técnica de Masquelet com enxerto de fibula associado a enxerto de crista ilíaca: Relato de dois casos*

Frederico Silva Pimenta<sup>1</sup>  Tardelli Lapaz da Silva Prudêncio<sup>1</sup> Gustavo Pacheco Martins Ferreira<sup>1</sup>  
Alessandro Cordoval de Barros<sup>1</sup> Marco Túlio Lopes Caldas<sup>1</sup> Heitor Maia Rodrigues<sup>1</sup>

<sup>1</sup>Orthopedics and Traumatology Service, Hospital Maria Amélia Lins, Belo Horizonte, Minas Gerais, Brazil

Address for correspondence Frederico Silva Pimenta, MSc, Rua do Campo 130, apt. 802, Vila da Serra, Nova Lima, Minas Gerais, 34006-062, Brazil (e-mail: fredericopimenta86@hotmail.com).

Rev Bras Ortop 2022;57:1074–1078.

### Abstract

Two cases of bone failure after fracture of the distal region of the femur treated with the Masquelet technique are presented. The first case involves acute bone loss, and the second, pseudarthrosis. The proper management of these lesions led to consolidation and a good functional result.

### Keywords

- ▶ bone graft
- ▶ pseudarthrosis
- ▶ femur fractures

### Resumo

Dois casos de falha óssea após fratura da região distal do fêmur tratados pela técnica de Masquelet são apresentados. O primeiro caso envolve uma perda óssea aguda, e o segundo, uma pseudoartrose. O manejo adequado dessas lesões levou à consolidação e a um bom resultado funcional.

### Palavras-chave

- ▶ enxerto ósseo
- ▶ pseudoartrose
- ▶ fraturas do fêmur

## Introduction

The treatment of large bone losses after the fracture of long bones is challenging for the orthopedist. Bone transport

using the Ilizarov method is associated with complications and great morbidity.<sup>1</sup> A treatment option is the Masquelet technique, in which a richly-vascularized membrane is formed. The procedure takes place in two stages: in the first stage, a bone cement spacer is used to fill the defect, and, in the second, the spacer is removed and the defect is filled with bone graft.<sup>2-5</sup>

\* Work developed at the Orthopedics and Traumatology Service, Hospital Maria Amélia Lins, Belo Horizonte, Minas Gerais, Brazil.

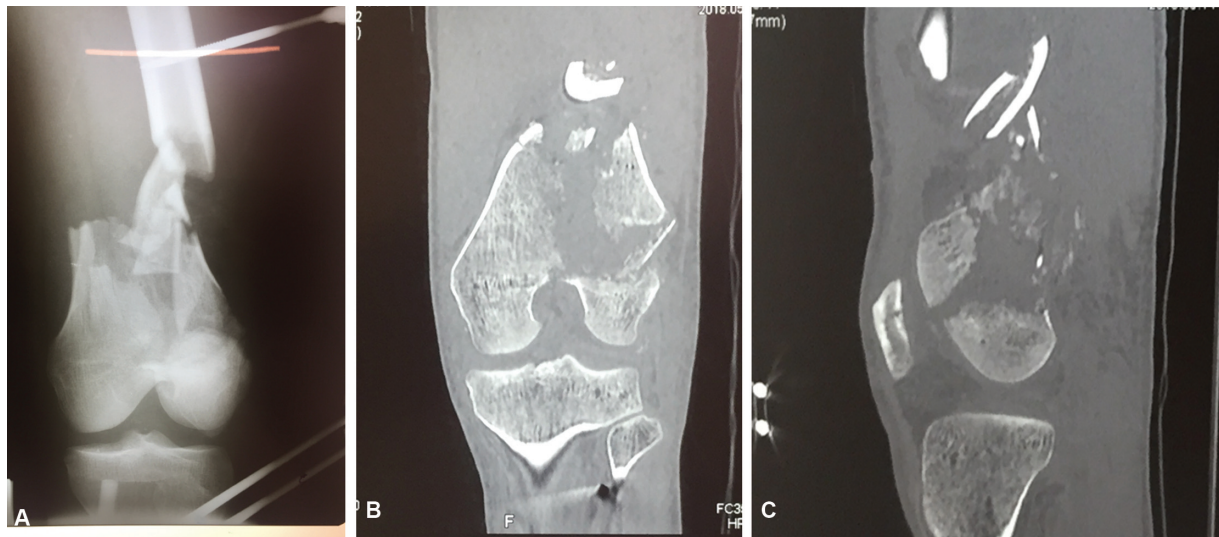
received  
September 6, 2019  
accepted  
March 2, 2020  
published online  
June 10, 2020

DOI <https://doi.org/10.1055/s-0040-1710336>.  
ISSN 0102-3616.

© 2020. Sociedade Brasileira de Ortopedia e Traumatologia. All rights reserved.

This is an open access article published by Thieme under the terms of the Creative Commons Attribution-NonDerivative-NonCommercial-License, permitting copying and reproduction so long as the original work is given appropriate credit. Contents may not be used for commercial purposes, or adapted, remixed, transformed or built upon. (<https://creativecommons.org/licenses/by-nc-nd/4.0/>)

Thieme Revinter Publicações Ltda., Rua do Matoso 170, Rio de Janeiro, RJ, CEP 20270-135, Brazil



**Fig. 1** (A) Anteroposterior (AP) radiograph of the knee demonstrating bone failure. (B) Computed tomography (CT) coronal section demonstrating bone loss and a small joint fragment of the lateral femoral condyle and (C) a sagittal cut of an associated Hoffa fracture.

Two cases of large bone failure of the distal femur are reported. The first case involved acute bone loss after an open fracture of the femur. In the second case, the patient was initially treated acutely due to a distal fracture of the femur, and evolved with pseudarthrosis in this region.

### Case Report

#### Case 1

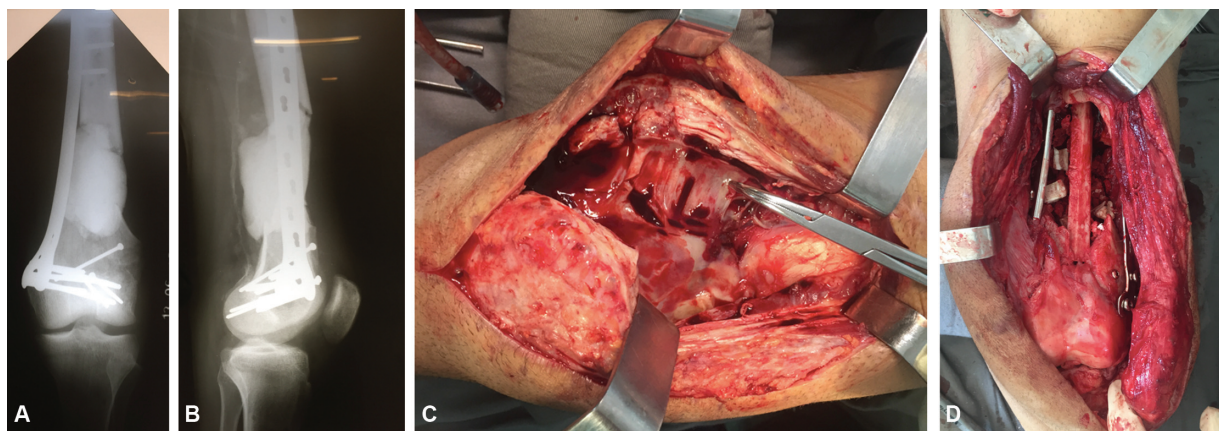
A male patient, 24 years old, victim of a collision between a motorcycle and an automobile, presented an exposed AO 33C3 fracture of the distal region of the femur, of grade 3B according to the classification by Gustilo et al<sup>6</sup>, and bone loss (► Fig. 1). The initial approach involved extensive debridement and transarticular external knee fixation. Seven days after the trauma, fracture fixation was performed with a medial blocked plate through an anterior access and medial parapatellar arthrotomy, as well as a new debridement with collection of culture material. The 9-cm bone defect was

filled with 40 g of orthopedic cement with 2 g of vancomycin (► Fig. 2 A and B).

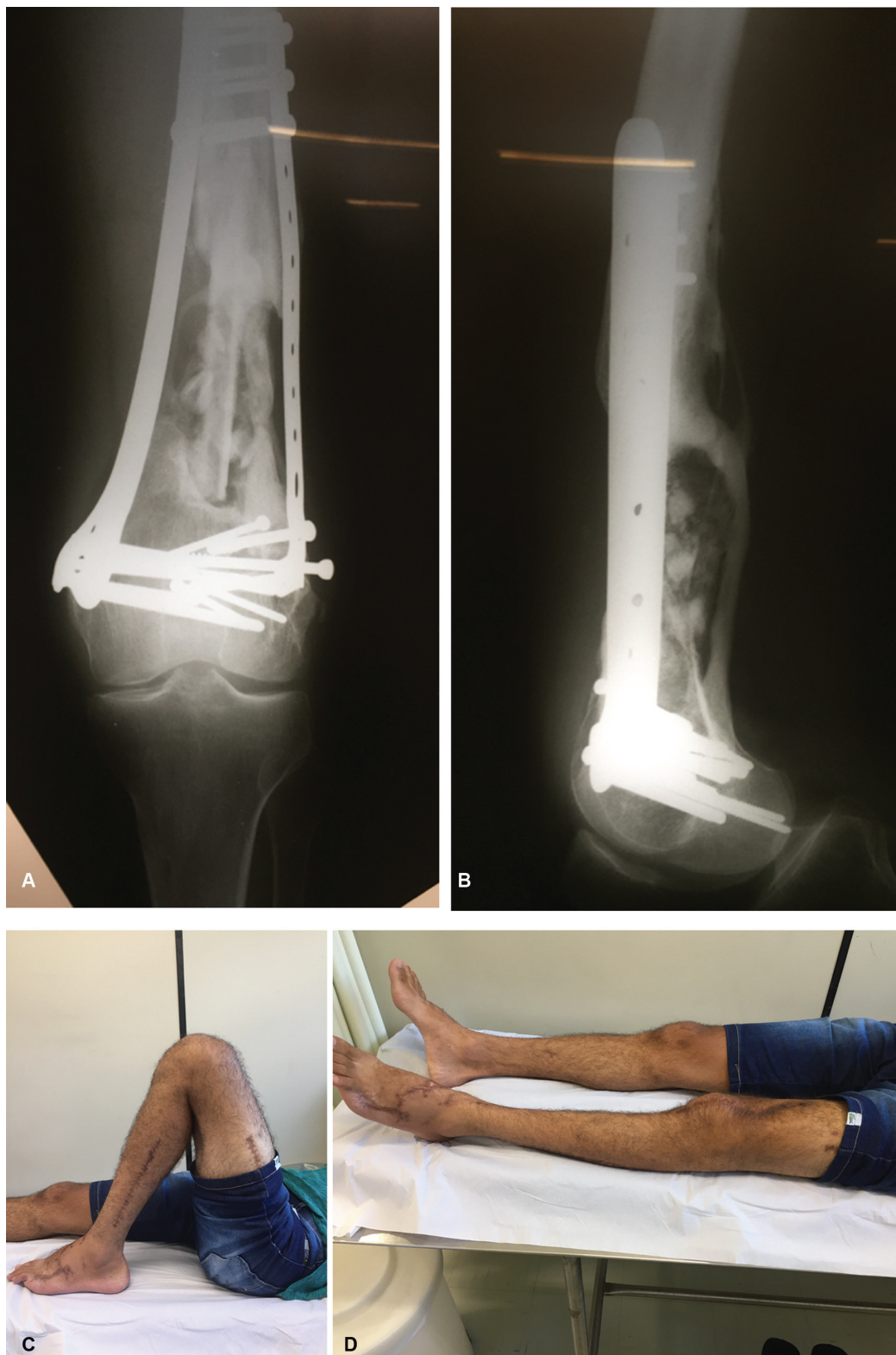The cultures were negative, and after six weeks the patient underwent the second surgical time. The cement was removed, and the bone failure was filled with ipsilateral nonvascularized fibula graft and iliac-crest bone graft. A new side plate was added to provide greater stiffness to the construction (► Fig. 2 C and D). Partial load support was started at four months, and after one year the fracture consolidated. The range of motion of the knee went from 0° to 130°, and the discrepancy of the limbs was shorter than 1.0 cm (► Fig. 3).

#### Case 2

A 22-year-old male victim of a collision between a motorcycle and a lamp post presented an exposed O 33C3 fracture of the distal region of the femur, of grade 3B according to the classification by Gustilo et al<sup>6</sup>, with bone loss of 4 cm. The initial approach involved debridement and a transarticular external



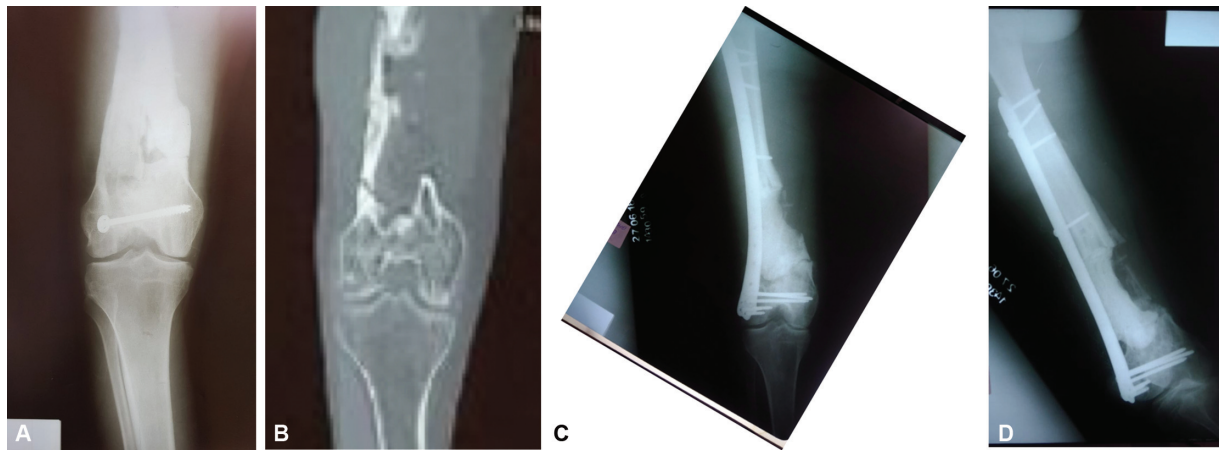
**Fig. 2** (A and B) Anteroposterior (AP) and profile radiographs demonstrating bone failure filled with orthopedic cement and fixation of joint fragments and medial blocked plate. (C) Vascularized membrane after cement removal – tip of the clamp. (D) Bone failure filled with fibula graft and iliac-crest graft.



**Fig. 3** (A and B) Anteroposterior (AP) and profile radiographs demonstrating bone consolidation. (C and D) Final range of motion.

fixator. After ten days, the definitive fixation was performed, and the defect was filled with iliac-crest graft. The patient evolved with acute osteosynthesis infection, and two debridements and intravenous antibiotic therapy were performed. The infection was controlled, and after one year of the procedure,

the plaque was removed. Two months after the removal of the plaque, the patient complained of pain in the knee region, and new images were made. Distal pseudarthrosis of the femur was observed, with an unviable bone segment (► **Fig. 4A and B**). The operative scar showed no signs of infection, and the level of C-

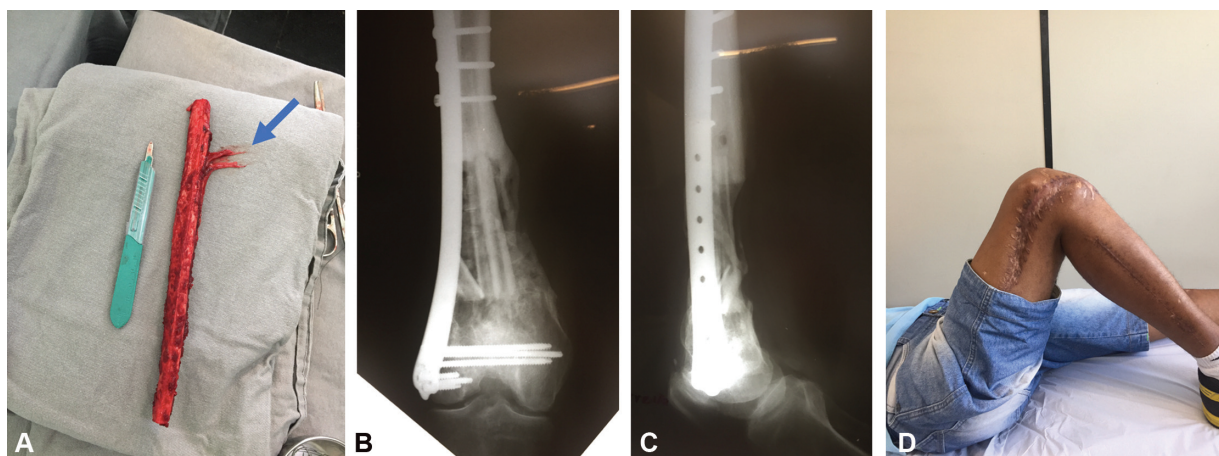


**Fig. 4** (A and B) Anteroposterior (AP) radiographs and computed tomography (CT) scans demonstrating unfeasible bone segment and pseudarthrosis of the distal region of the femur. (C and D) Devitalized bone tissue removed and defect filled with orthopedic cement with antibiotics and fixation with lateral blocked plate (X-ray).

reactive protein (CRP) was 18 mg/L. Upon physical examination, the patient presented a shortening of 5 cm and a varus alignment of 6°.

The patient underwent resection of the entire devitalized bone through an anterolateral access, as well as fixation with a lateral blocked plate, and the material was sent for culture. The bone defect measured 11 cm, and it was filled with orthopedic cement and 8 g of vancomycin; the renal function was monitored every 48 hours due to the risk of systemic toxicity from the antibiotic (►Fig. 4C and D). The final length of the limb was obtained by slight manual traction according to soft-tissue compliance, with special concern for the neurovascular bundle, which was inspected by direct vision in the distal region of the femur during surgery, after the dissection of the tissues, through an extensive exposure, so that there was no excessive traction in such structures. In the culture, there was growth of *Staphylococcus epidermidis* and *Bacillus sp.*, which were treated with 2 g of cefepime every 8 hours, and 600 mg of clindamycin every 6 hours intravenously during 6 weeks.

After 6 weeks, the level of CRP was lower than 10 mg/L, and the second surgery was performed. The cement was removed, and the defect was filled with vascularized-fibula graft and iliac-crest graft (►Fig. 5A). At the time of the removal of the iliac-crest graft, bone marrow aspirate from the crest was obtained, which was infiltrated into the bone defect of the distal region of the femur after closure. This iliac crest aspirate was obtained with puncture with a bone-biopsy needle, and the material was not processed. New cultures including bone and soft tissue were harvested after the removal of the cement spacer, totaling six samples, and there was no bacterial growth. The patient was discharged from the hospital with a treatment with oral Amoxicillin + Clavulanic Acid 500/125 mg every 8 hours for 6 months, and control of the infectious process was performed through the blood count, the levels of CRP, and the rate of erythrocyte sedimentation. Partial load support was started at 4 months, and after 1 year the fracture consolidated, the range of motion of the knee went from 0° to 120°, the discrepancy of the limbs was of 2 cm, and the alignment of the limb was neutral (►Fig. 5B and D).



**Fig. 5** (A) Vascularized-fibula autologous graft (arrow – blood vessel ). (B and C) Postoperative radiograph demonstrating consolidation. (D) Range of motion.

## Discussion

The present article reports the treatment of two complex knee lesions with the Masquelet technique, demonstrating that large bone losses can be managed without the use of bone transport devices.

The Masquelet technique involves the formation of a vascularized membrane and the filling of the defect with autologous bone graft. The technique involves the use of a polymethylmethacrylate cement spacer that leads to membrane formation that prevents bone-graft resorption and creates an ideal environment for consolidation.<sup>7-10</sup> Although the description of the Masquelet technique involves the treatment of bone failures up to 25cm, the literature presents studies in which failures generally do not exceed 7 cm due to the limited source of autologous iliac-crest bone graft.<sup>11</sup>

Dugan et al<sup>12</sup> obtained bone consolidation in 15 open fractures of the distal region of the femur treated acutely with the 2-stage technique, such as the one presented in the first case report. The size of the bone failures ranged from 2 cm to 11 cm, and they were filled with iliac-crest graft and allograft supplementation in the case of major defects. In the aforementioned cases, we opted for the use of fibula graft and supplementation with iliac-crest graft, in order to fill the bone defect and add greater stability to the fracture with the use of the fibula. In addition, we demonstrated that large bone defects can be successfully managed without the use of allografts.<sup>12</sup>

Donegan et al<sup>12</sup> used a similar technique involving the use of spacers with antibiotics and subsequent bone grafting. The study involved acute fractures with bone loss and infected and uninfected pesudarthrosis of the femur and tibia, and fracture consolidation was achieved in 10 of the 11 cases treated.<sup>13</sup>

The present study 2 reports cases of bone failures of 9 cm and 11 cm, in which the limited capacity of the autologous iliac crest graft was overcome through the association of a fibula graft; the use of allograft is not necessary.<sup>14</sup> In the first case presented, the non-vascularized fibula was used, and, in the second case, the vascularized fibula was used due to the larger bone defect. The removal of the fibula graft in both cases was performed by the microsurgery team. This may represent a limitation for the use of the technique in orthopedic services without a team with training in microsurgery in the case of obtaining the vascularized fibula. We consider that the non-vascularized-fibula graft can be obtained by an orthopedist without microvascular training, but we opted for the joint approach with the microsurgery team. Allsopp et al,<sup>15</sup> in a systematic review, demonstrated that there is no evidence that bone defects larger than 6 cm should be treated with vascularized grafts, and that there was no difference in time and consolidation rates comparing vascularized and non-vascularized grafts. This enables the obtainment of grafts in orthopedic services without a microvascular surgery team.

The Masquelet technique associated with iliac-crest graft and vascularized-fibula graft demonstrated good functional results and bone consolidation in the two cases herein presented by the authors.

### Conflict of Interests

The authors have no conflict of interests to declare.

### References

- 1 DeCoster TA, Gehlert RJ, Mikola EA, Pirela-Cruz MA. Management of posttraumatic segmental bone defects. *J Am Acad Orthop Surg* 2004;12(01):28-38
- 2 Rezzouk J, Leclerc J, Leger O, Boireau P, Fabre T, Durandeau A. Bone reconstruction with induced membranes and cancellous autograft: results in 18 cases of osteitis. *J Bone Joint Surg Br* 2005;87(Suppl 2):98
- 3 Masquelet AC, Begue T. The concept of induced membrane for reconstruction of long bone defects. *Orthop Clin North Am* 2010;41(01):27-37
- 4 Chong KW, Woon CY, Wong MK. Induced membranes—a staged technique of bone-grafting for segmental bone loss: surgical technique. *J Bone Joint Surg Am* 2011;93(Suppl 1):85-91
- 5 Ahmad S, Kalra M, Selvamari M. Induced membrane formation in a case of infected gap nonunion of radius: Case report. *J Clin Orthop Trauma* 2013;4(03):147-150
- 6 Gustilo RB, Mendoza RM, Williams DN. Problems in the management of type III (severe) open fractures: a new classification of type III open fractures. *J Trauma* 1984;24:742-746
- 7 Giannoudis PV. Treatment of bone defects: Bone transport or the induced membrane technique? *Injury* 2016;47(02):291-292
- 8 Pelissier P, Martin D, Baudet J, Lepreux S, Masquelet AC. Behaviour of cancellous bone graft placed in induced membranes. *Br J Plast Surg* 2002;55(07):596-598
- 9 Pelissier P, Masquelet AC, Bareille R, Pelissier SM, Amedee J. Induced membranes secrete growth factors including vascular and osteoinductive factors and could stimulate bone regeneration. *J Orthop Res* 2004;22(01):73-79
- 10 Pelletier MH, Malisano L, Smitham PJ, Okamoto K, Walsh WR. The compressive properties of bone cements containing large doses of antibiotics. *J Arthroplasty* 2009;24(03):454-460
- 11 Chmell MJ, McAndrew MP, Thomas R, Schwartz HS. Structural allografts for reconstruction of lower extremity open fractures with 10 centimeters or more of acute segmental defects. *J Orthop Trauma* 1995;9(03):222-226
- 12 Dugan TR, Hubert MG, Siska PA, Pape HC, Tarkin IS. Open supracondylar femur fractures with bone loss in the polytraumatized patient - Timing is everything!. *Injury* 2013;44(12):1826-1831
- 13 Donegan DJ, Scolaro J, Matuszewski PE, Mehta S. Staged bone grafting following placement of an antibiotic spacer block for the management of segmental long bone defects. *Orthopedics* 2011;34(11):e730-e735
- 14 Levin LS. Vascularized fibula graft for the traumatically induced long-bone defect. *J Am Acad Orthop Surg* 2006;14(10 Spec No.):S175-S176
- 15 Allsopp BJ, Hunter-Smith DJ, Rozen WM. Vascularized versus Nonvascularized Bone Grafts: What Is the Evidence? *Clin Orthop Relat Res* 2016;474(05):1319-1327