

—Original—

## Slc:Hartley guinea pigs frequently possess duplication of the caudal vena cava

Tepei NAKAMURA<sup>1,2</sup>), Miyuki NORIMURA<sup>3</sup>), Kanako SUMI<sup>3</sup>), Osamu ICHII<sup>2</sup>),  
Yaser Hosny Ali ELEWA<sup>2,4</sup>), Yasuhiro KON<sup>2</sup>), Osamu TATSUMI<sup>1</sup>),  
Hideki HATTORI<sup>3</sup>), Tomoji YOSHIYASU<sup>3</sup>) and Ken-ichi NAGASAKI<sup>5</sup>)

<sup>1</sup>Section of Biological Science, Chitose Laboratory, Japan Food Research Laboratories, 2-3 Bunkyo, Chitose, Hokkaido 066-0052, Japan

<sup>2</sup>Laboratory of Anatomy, Department of Basic Veterinary Sciences, Division of Veterinary Medicine, Faculty of Veterinary Medicine, Hokkaido University, Kita 18-Nishi 9, Kita-ku, Sapporo, Hokkaido 060-0818, Japan

<sup>3</sup>Section of Biological Safety Research, Chitose Laboratory, Japan Food Research Laboratories, 2-3 Bunkyo, Chitose, Hokkaido 066-0052, Japan

<sup>4</sup>Department of Histology and Cytology, Faculty of Veterinary Medicine, Zagazig University, Qesm Awal Az Zagazig, Ash Sharqia Governorate 44519, Egypt

<sup>5</sup>Section of Biological Safety Research, Tama Laboratory, Japan Food Research Laboratories, 6-11-10 Nagayama, Tama, Tokyo 206-0025, Japan

**Abstract:** The formation of the caudal vena cava is a complex process involving development, regression, and anastomosis. In mammals, the normal caudal vena cava runs to the right side of the abdominal aorta, while duplication of the caudal vena cava has been identified as a congenital abnormality in both companion animals and humans. The present study demonstrates that Slc:Hartley guinea pigs frequently possess asymptomatic duplicated caudal vena cava. The prevalence was 30% and 24% for males and females, respectively, with no sex-related differences. In accordance with Saad *et al.* (2012)'s criteria, duplicated caudal vena cava were classified into two distinct variations. The dominant variation was a complete duplication without iliac anastomosis where the left caudal vena cava continued from the left common iliac vein and joined the left renal vein; the left renal vein ran to the right to join the right caudal vena cava. The alternative variation was an incomplete duplication where the left caudal vena cava joined the right infrarenal caudal vena cava at a more cranial point than in normal cases; the renal segment was unchanged. Iliac anastomosis was not found in any cases. Duplicated caudal vena cava neither affected the body weight nor the kidney weight. In conclusion, Slc:Hartley guinea pigs frequently possess asymptomatic duplicated caudal vena cava in the absence of iliac anastomosis and appear to be a novel and useful animal model for duplicated caudal vena cava in animals and humans.

**Key words:** congenital anomaly, duplicated caudal vena cava, guinea pigs, Hartley, iliac anastomosis

---

### Introduction

---

During embryogenesis, vertebrates generally develop symmetrical organs, but a number of organs break this

symmetry, such as the heart, liver, spleen, and caudal vena cava (inferior vena cava in humans) [7]. In mammals, the caudal vena cava receives blood from the caudal trunk, abdomen, pelvis, and caudal limbs, and deliv-

---

(Received 3 December 2018 / Accepted 17 April 2019 / Published online in J-STAGE 28 May 2019)

Corresponding author: T. Nakamura. e-mail: nakamura@jfrl.or.jp



This is an open-access article distributed under the terms of the Creative Commons Attribution Non-Commercial No Derivatives (by-nc-nd) License <<http://creativecommons.org/licenses/by-nc-nd/4.0/>>.

ers it to the right atrium of the heart. The caudal vena cava arises from three pairs of symmetrical veins but the right vein only remains through a complex process including development, regression and anastomosis [4, 5]. Firstly, the postcardinal veins appear and drain the caudal trunk. Secondly, the subcardinal veins develop cranio-medially to the postcardinal veins, while the postcardinal veins gradually regress, except for their caudal ends which remain as the common iliac veins. Thirdly, the supracardinal veins then start to develop and contribute to the venous drainage, while the left subcardinal vein completely regresses, yet the right subcardinal vein remains. After these complex processes, the caudal vena cava is composed of four segments: infrarenal, renal, suprarenal and hepatic segments [3, 4]. The infrarenal segment is derived from the right supracardinal vein, while the anastomosis between supracardinal and subcardinal veins forms the renal segment. The suprarenal segment is derived from the cranial end of the right subcardinal vein and the hepatic segment develops from the right hepatic vein [3–5].

Duplication of the infrarenal caudal vena cava is normally found in whales and dolphins [10]; however, it is recognized as a rare congenital anomaly in both companion animals and humans [1–3]. Recently, computed tomography has revealed that the identified anomalies are more common than initially expected [1–3, 9, 11]. For example, in dogs, the prevalence of duplicated caudal vena cava is 0.46% by ultrasound imaging but 2.08% by computed tomography [2]. Although the duplicated caudal vena cava appears asymptomatic, double caudal vena cava is linked with higher risks of thromboembolic events in humans [4], and has significant association with extrahepatic portosystemic shunts in dogs [2]. Although experimental animal models are useful for the evaluation of pathogenesis and complications of duplicated caudal vena cava, no experimental animal models possessing double caudal vena cava currently exist.

Guinea pigs (*Cavia porcellus*) are experimental animals belonging to the family Caviidae, unlike mice and rats which are classified in the family Muridae [8]. Like humans, guinea pigs are susceptible to tuberculosis bacterium and cannot produce vitamin C by themselves; guinea pigs have therefore been used as animal models for human medical conditions such as scurvy and tuberculosis [8]. Although guinea pigs have commonly been replaced by mice and rats, they are still used for the study of allergic reactions to pharmaceuticals and medical

devices [6]. In the present study, we introduce asymptomatic duplicated caudal vena cava found in Slc:Hartley guinea pigs, available from Japan SLC, Inc. (Shizuoka, Japan).

---

## Materials and Methods

---

Animal experimentation was performed in accordance with the guidelines of Chitose Laboratory, Japan Food Research Laboratories (approval No. HK180110-01). A hundred Slc:Hartley guinea pigs (male: 50, female: 50) purchased from Japan SLC, Inc. were used in this study. The animals, aged between six to ten weeks, were euthanized by excess inhalation of isoflurane, and the abdominal cavity was observed macroscopically. Subsequently, some guinea pigs were fixed with 10% neutral buffered formalin. The fixed abdomen was dehydrated and defatted with graded alcohol followed by pure acetone, then embedded with polyester resin (Maruto, Tokyo, Japan). Abdominal sections were sliced transversally using a circular diamond cutter (Microcutter, Maruto) at approximately 2-mm intervals, and were ground by hand. The sections were observed using an all-in-one fluorescence microscope (BZ-X800, Keyence, Osaka, Japan). Some animals were euthanized by cutting the abdominal aorta under deep anesthesia with isoflurane, and the kidneys were weighed.

Duplicated vena cava was categorized into three types; i.e., complete, complete with iliac anastomosis, and incomplete, as previously reported [11]. A complete duplication was defined by the presence of both the right and left caudal vena cava. A complete duplication with iliac anastomosis was identified by the presence of the two caudal vena cavae and iliac anastomosis. An incomplete duplication was identified when the two caudal vena cavae were present but joined each other more cranially than the end of the abdominal aorta.

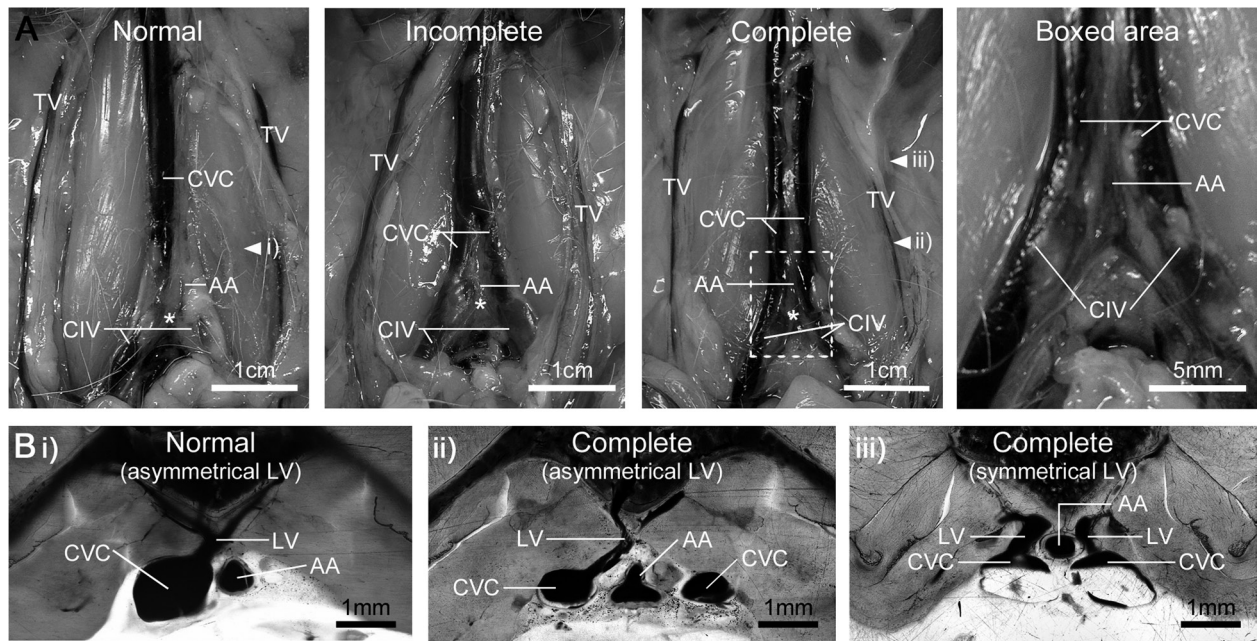
The results are expressed as mean  $\pm$  SE. The Mann-Whitney *U* test was used to compare data between two groups. The Kruskal-Wallis test was used to compare data among three groups or more. The categorical data were analyzed using Fisher's exact test.

---

## Results

---

In all Slc:Hartley guinea pigs, the abdominal aorta ran at the midline and branched to the ambilateral common iliac arteries (Fig. 1A). In normal Slc:Hartley guinea



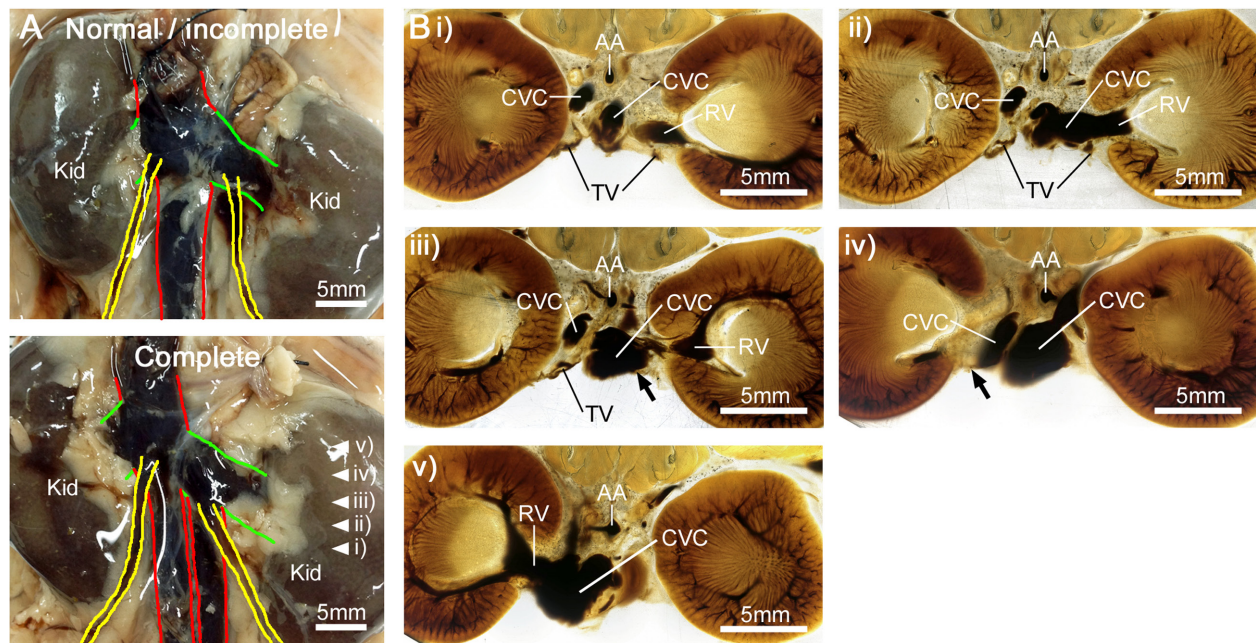
**Fig. 1.** Gross anatomy of the infrarenal segment of caudal vena cava in Slc:Hartley guinea pigs. Representative image of male guinea pigs is shown. (A) Macroscopical features of the infrarenal segment of caudal vena cava. (B) Transverse sections of the infrarenal segment of caudal vena cava in caudal view. The sections were prepared from tissues harvested from the positions indicated by the arrowheads (i, ii, iii) in panel A. In Slc:Hartley guinea pigs with duplicated caudal vena cava, the lumbar veins either reach the right caudal vena cava (ii) or separately joined the left and right caudal venae (iii). AA, abdominal aorta; CIV, common iliac vein; CVC, caudal vena cava; LV, lumbar vein; TV, testicular vein. The asterisks indicate the caudal end of the abdominal aorta.

**Table 1.** Prevalence of duplicated vena cava in Slc:Hartley guinea pigs

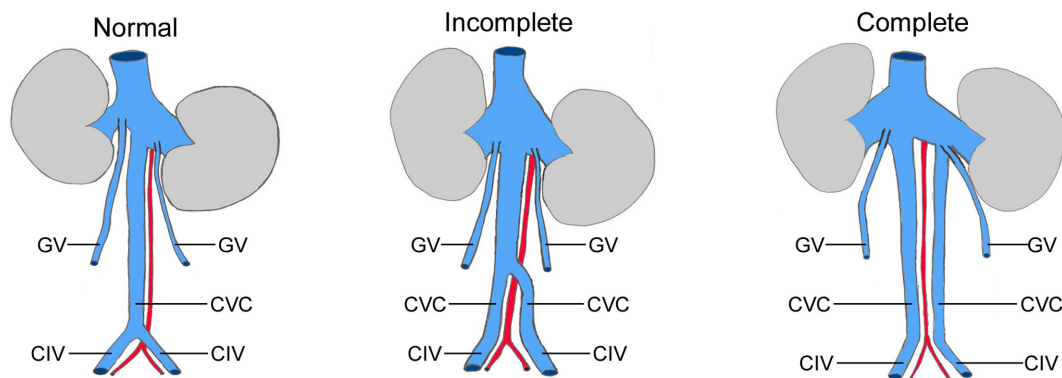
Sex	Sample size	Complete	Complete with iliac anastomosis	Incomplete	Normal
Total	100	23 (23%)	0	4 (4%)	73 (73%)
Male	50	14 (28%)	0	1 (2%)	35 (70%)
Female	50	9 (18%)	0	3 (6%)	38 (76%)
P-value		P=0.342	P=1.000	P=0.617	P=0.510

pigs, the infrarenal caudal vena cava continued from the ambilateral common iliac veins at the caudal end of the abdominal aorta, and ran along the right side of the abdominal aorta (Fig. 1A). Slc:Hartley guinea pigs presented with duplication of the caudal vena cava at the infrarenal segment in 15 out of 50 males (30%) and 12 out of 50 females (24%) without sex-related differences (Fig. 1A and Table 1). The duplicated caudal vena cava was classified into two distinct variations, in accordance with the criteria outlined by Saad *et al.* [11]. The dominant variation was a complete duplication where the left caudal vena cava continued from the left common iliac vein (Fig. 1A). The two infrarenal segments of the caudal vena cava ran symmetrically along the lateral border

of the abdominal aorta and had approximately same caliber (Figs. 1A and B). The iliac anastomosis was not found in all cases with complete duplication. Complete duplication was observed in 28% of males and 18% of females with no sex-related differences (Table 1). Another variation was an incomplete duplication, where the left caudal vena cava continued from the left common iliac vein, but ran ventrally to the abdominal aorta and joined with the right caudal vena cava more cranially than the caudal end of the abdominal aorta (Fig. 1A). The renal segment and the gonadal vein had the same structures as those found in normal cases (Fig. 1A). Iliac anastomosis was not identified in any cases. Incomplete duplication was found in 2% and 6% of male and



**Fig. 2.** Gross anatomy of the renal segment of caudal vena cava in Slc:Hartley guinea pigs. Representative image of male guinea pigs is shown. (A) Macroscopical features of the renal segment of caudal vena cava. Red, caudal vena cava; green, renal vein; yellow, testicular vein. (B) Transverse sections of the renal segment of caudal vena cava in Slc:Hartley guinea pigs with complete duplicated caudal vena cava, caudal view. The sections were prepared from tissues harvested from the positions indicated by arrowheads (i, ii, iii, iv, v) in panel A. The images are numbered from the caudal end. AA, abdominal aorta; CVC, caudal vena cava; RV, renal vein; TV, testicular vein. Arrows indicate junction of the caudal vena cava and the testicular vein.



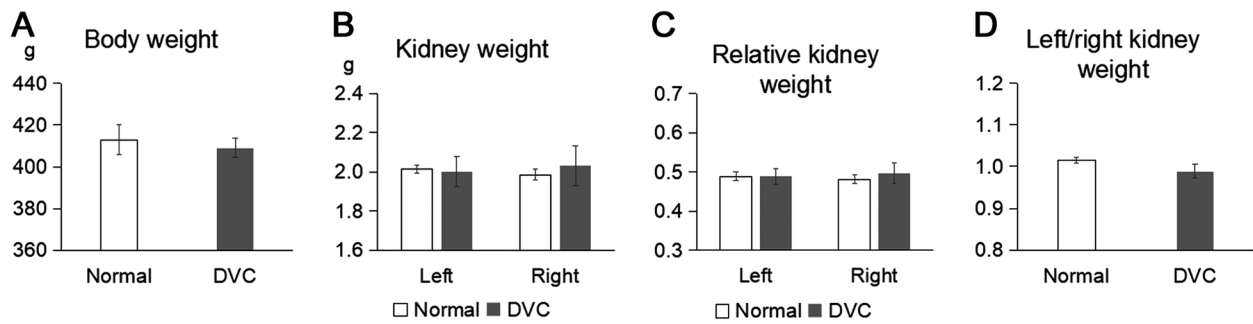
**Fig. 3.** The running route of the duplicated caudal vena cava in Slc:Hartley guinea pigs. Blue, red, and gray indicate vein, artery, and kidney, respectively. CIV, common iliac vein; CVC, caudal vena cava; GV, gonadal vein.

females, respectively (Table 1).

In all normal cases, the left and right lumbar vein crossed at the midline and reached the right caudal vena cava (Fig. 1B). Slc:Hartley guinea pigs with duplicated caudal vena cava had two variations in the angioplasty of lumbar vein although the prevalence was not examined in this study. One variation showed the same structures as those found in normal cases (Fig. 1B). In another variation, the left and right lumbar vein separately

joined the left and right caudal vena cavae, respectively (Fig. 1B).

At the renal segment of caudal vena cava in normal guinea pigs, the left gonadal vein drained the left renal vein (Fig. 2A). The left renal vein ran ventrally of the abdominal aorta and joined the right caudal vena cava (Fig. 2A). The right gonadal vein joined the caudal vena cava at a position slightly caudal to the right renal vein (Fig. 2A). In guinea pigs with complete duplication of



**Fig. 4.** Effect of duplicated caudal vena cava on body weight and kidney weight in male Slc:Hartley guinea pigs. (A) Body weight, (B) Kidney weight, (C) Kidney weight per body weight, and (D) Ratio of left per right kidney weight. DVC, duplicated vena cava.

the caudal vena cava, the left gonadal vein drained the border between the left caudal vena cava and left renal vein (Figs. 2A and B). The left renal vein collected the left caudal vena cava at the midline, and ran ventrally of the abdominal aorta to joined with the right caudal vena cava (Figs. 2A and B). The right gonadal vein ran similarly as that observed in case of normal guinea pigs (Fig. 2A). The running route of the infrarenal and renal segments of the caudal vena cava in SLC:Hartley guinea pigs are shown in Fig. 3.

In male guinea pigs at six weeks of age, when they are most commonly used for the biological safety test, body weight and kidney weight were unaffected by the duplicated caudal vena cava (Figs. 4A–C). Although the ratio of left to right kidney weight was slightly lower in the guinea pigs with duplicated caudal vena cava than in normal cases, the difference was not found to be significant (Fig. 4D).

### Discussion

This study identified that Slc:Hartley guinea pigs frequently possess duplicated caudal vena cava, with no sex-related differences. Duplicated caudal/inferior vena cava have been reported in both companion animals and humans at 2.08% in dogs with breed-related differences (0.52–10.71%) [2], 7.0% in cats [1], and 0.2–3.0% in humans [4]. In the present study, we found 27% of Slc:Hartley guinea pigs to possess duplicated caudal vena cava at the infrarenal segment. The prevalence was much higher than has been reported for other animal species, with the exception of whales and dolphins which have paired caudal vena cavae [10]. To our knowledge, the duplication of the caudal vena cava has not been reported in other strains of guinea pigs, indicating a

strain-specific phenotype in Slc:Hartley guinea pigs. Although the bilateral lumbar veins reach the right caudal vena cava in dogs with duplicated caudal vena cava [1], the Slc:Hartley guinea pigs with duplicated caudal vena cava presented with both the asymmetrical and symmetrical lumbar veins, indicating that the development of the caudal vena cava is associated with that of the lumbar vein. Since Slc:Hartley guinea pigs had higher prevalence of duplicated caudal vena cava, and the examination of the fetal development is easier than in companion animals, Slc:Hartley guinea pigs are novel and useful models for the study of duplicated vena cava.

In humans, duplicated inferior vena cava has been categorized by several researchers according to the caliber and angioplasty of the infrarenal inferior vena cava, and presence and angle of the iliac anastomosis [3, 11]. Saad *et al.* (2012) categorized these anomalies based on the caliber and angioplasty of the infrarenal inferior vena cava and the presence of the iliac anastomosis [11]. This classification was applied to categorize variations of duplicated caudal vena cava in guinea pigs in addition to dogs [2], indicating that this criterion is useful for inter-species comparison of duplicated caudal vena cava. According to this classification, the dominant variation was different among mammalian species. Most cases of duplicated caudal vena cava in Slc:Hartley guinea pigs, were classified as complete duplication without iliac anastomosis, as was the case in dogs [2]. In humans, a complete duplication with iliac anastomosis has been reported to be more common, and shows variable patterns in the angle of the iliac anastomosis, while prevalence of complete duplication without iliac anastomosis has been reported to be between 20.2% [9] and 33% [3]. The male to female ratio additionally appears to differ

among species. In Slc:Hartley guinea pigs, dogs, and cats, no sex-related differences have been reported [1, 2]. On the other hand, duplicated inferior vena cava is predominantly found in human males, although that remains under debate [3]. The present study could not address the origin of the duplicated vena cava, whether it is the regression of the iliac anastomosis, or the persistence of the left supracardinal veins. However, the origin of double infrarenal caudal vena cavae may be due to the persistence of both the supracardinal veins, since the iliac anastomosis is often present in humans with duplicated inferior vena cava [3, 4, 9].

In multiple breeds of dogs, body weight has not been associated with the caudal vena cava when analyzed by multivariable logistic regression model [2]. Our study revealed that neither the body weight nor the kidney weight are associated with the duplication of caudal vena cava using a single strain of guinea pigs, indicating that such duplications are asymptomatic under physiological conditions. Slc:Hartley guinea pigs have been used in the biological safety tests [6]; therefore, it should be acknowledged that the congenital anomalies may influence these results. This study indicates that the presence of duplicated caudal vena cava does not limit the applicability of these guinea pigs in toxicity test, since they were asymptomatic under physiological conditions. However, careful attention must be paid if some toxicities are found when using this strain.

In conclusion, Slc:Hartley guinea pigs are novel and useful animal models for duplicated caudal vena cava in both companion animals and humans. The prevalence and anatomical variations in the development and duplication of caudal vena cava among species may be the manifestation of the underlying genetic factors rather than sporadic factors. Further studies need to be undertaken to establish inbred guinea pigs possessing the duplicated caudal vena cava to elucidate the genetic mechanism and identify the responsible genes. Although knowledge on the genetic information of guinea pigs is limited, a whole-genome sequencing approach can be utilized to elucidate the molecular pathogenesis responsible for duplication of the caudal vena cava in Slc:Hartley guinea pigs.

---

## Acknowledgments

---

We would like to acknowledge Chizuko Kodama for her assistance with specimen preparation. This work was supported by JSPS KAKENHI, Grant Number: JP18K0703708.

---

## References

---

1. Bélanger, R., Shmon, C.L., Gilbert, P.J. and Linn, K.A. 2014. Prevalence of circumcaval ureters and double caudal vena cava in cats. *Am. J. Vet. Res.* 75: 91–95. [[Medline](#)] [[CrossRef](#)]
2. Bertolini, G., Diana, A., Cipone, M., Drigo, M. and Caldin, M. 2014. Multidetector row computed tomography and ultrasound characteristics of caudal vena cava duplication in dogs. *Vet. Radiol. Ultrasound* 55: 521–530. [[Medline](#)] [[CrossRef](#)]
3. Chen, H., Emura, S., Nagasaki, S. and Kubo, K.Y. 2012. Double inferior vena cava with interiliac vein: a case report and literature review. *Okajimas Folia Anat. Jpn.* 88: 147–151. [[Medline](#)] [[CrossRef](#)]
4. Eldefrawy, A., Arianayagam, M., Kanagarajah, P., Acosta, K. and Manoharan, M. 2011. Anomalies of the inferior vena cava and renal veins and implications for renal surgery. *Cent. European J. Urol.* 64: 4–8. [[Medline](#)] [[CrossRef](#)]
5. Ghandour, A., Partovi, S., Karuppasamy, K. and Rajiah, P. 2016. Congenital anomalies of the IVC-embryological perspective and clinical relevance. *Cardiovasc. Diagn. Ther.* 6: 482–492. [[Medline](#)] [[CrossRef](#)]
6. International Organization for Standardization. 2010. ISO 10993–10:2010. Biological evaluation of medical devices—Part 10: Tests for irritation and skin sensitization.
7. Levin, M. 2005. Left-right asymmetry in embryonic development: a comprehensive review. *Mech. Dev.* 122: 3–25. [[Medline](#)] [[CrossRef](#)]
8. Maejima, K., and Kasai, N. 1989. Comparative laboratory animal science. pp. 88–123. *In: Latest laboratory animal science 1st ed.* Asakura Publishing, Tokyo (in Japanese).
9. Natsis, K., Apostolidis, S., Noussios, G., Papatheasiou, E., Kyriazidou, A. and Vyzas, V. 2010. Duplication of the inferior vena cava: anatomy, embryology and classification proposal. *Anat. Sci. Int.* 85: 56–60. [[Medline](#)] [[CrossRef](#)]
10. Rommel, S.A., Costidis, A.M., Fernández, A., Jepson, P.D., Pabst, D.A., McLellan, W.A., Houser, D.S., Cranford, T.W., Van Helden, A.L., Allen, D.M. and Barros, N.B. 2006. Elements of beaked whale anatomy and diving physiology and some hypothetical causes of sonar-related stranding. *J. Cetacean Res. Manag.* 7: 189–209.
11. Saad, K.R., Saad, P.F., Amorim, C.A., Armstrong, D., Soares, B.L.F., Neves, P.C.F. and Razuk Filho, A. 2012. Duplication of the inferior vena cava: case report and a literature review of anatomical variation. *J. Morphol. Sci.* 29: 60–64.