

## Case Report

# An unusual manifestation of Hand-Foot-Genital Syndrome: Embryonal Rhabdomyosarcoma - A case report

Amr Hamza<sup>a</sup>, Ghina Ghannam<sup>a</sup>, Yaman Koudra Danial<sup>a</sup>, Abdualh Fattal<sup>a,\*</sup>, Lina Ghabreau<sup>b</sup>, Ghefar Omar<sup>b</sup>, Manar Abdullah<sup>c</sup>

<sup>a</sup> Faculty of Medicine, University of Aleppo, Aleppo, Syria

<sup>b</sup> Pathology Department, Aleppo University Hospital, Aleppo, Syria

<sup>c</sup> Pediatric Department, Aleppo University Hospital, Aleppo, Syria

## ARTICLE INFO

## Keywords:

Hand-foot-genital syndrome  
Embryonal rhabdomyosarcoma  
Novel case  
Hand-foot-uterus syndrome

## ABSTRACT

Hand-Foot-Genital Syndrome (HFGS) is a dominantly inherited condition and one of the rarest cases encountered in clinical practice. It might be presented with a wide variety of limb malformations and urogenital defects manifestations. In this report, a unique and novel case of HFGS accompanied with Embryonal Rhabdomyosarcoma of the urinary bladder is described in a two-year-old male. The patient was admitted to the hospital in order to investigate a progressively enlarging mass in the lower abdomen. During hospitalization, oliguria was noted by resident physicians. However, hypospadias and dysmorphic abnormalities, demonstrated upon physical examination, were the cornerstone in the diagnosis of HFGS. An accurate visual examination of the abdomen showed dilated superficial veins, and abdominal rigidity appeared through palpation. Furthermore, the radiologic evaluation showed delayed ossification of carpal bones, and abdominal CT scan revealed a necrotic mass in the hypogastric region measuring 12 × 10 cm. A biopsy was performed through which the mass was confirmed as Embryonal Rhabdomyosarcoma of the urinary bladder. The kidney function follow-up showed normal results. Neoadjuvant chemotherapy was started to diminish the tumor size. However, the patient eventually passed away during the treatment phase. This report emphasizes the need for a high index of suspicion to establish early detection of Embryonal Rhabdomyosarcoma in each newborn diagnosed with Hand-Foot-Genital Syndrome (HFGS) to avoid potential fatal consequences.

## 1. Introduction

Hand-Foot-Genital Syndrome (HFGS) is a rare autosomal dominant condition caused by a mutation of the HOXA13 gene on chromosome 7p15 [1].

The HOX genes are organized into four distinct clusters HOXA, HOXB, HOXC, and HOXD which are located in the 7p15.2, 17q21.32, 12q13.13, and 2q31.1, respectively. These genes are transcription factors classified within a large family called Homeobox. The HOXA 13 gene regulates the development of upper limb, lower limb, urinary tract, and reproductive system during the early stage of embryonic development [2].

The structure of the HOXA 13 gene includes polyalanine tracts, and most of the mutations in the HOXA 13 gene affect one of poly (A) tract. These mutations make poly (A) tracts long and unstable by adding extra alanine leading to an altered protein. HFGS may be manifested with

more severe symptoms and signs when the mutation results in an altered and functional HOXA13 protein [3].

The HFGS is described as congenital malformation affects genitourinary with variable skeletal anomalies, mainly affecting hands and feet, such as fusion of distal and middle phalanges of the toes, shortening of the fifth finger, thumbs, and middle phalanges. About half of affected individuals have urogenital anomalies, such as hypospadias of variable severity with or without gryposis penis in males. Otherwise, females may have incomplete Mullerian fusion or bicornuate uterus. Females may also have increased risks of spontaneous abortion, preterm delivery, or stillbirth [1]. Vesicoureteral reflux, recurrent urinary tract infections, and chronic pyelonephritis may also occur [4].

Herein; we investigate a life-threatening manifestation of HFGS in a patient with urine interruption due to compressive tumor in the urinary bladder called Embryonal Rhabdomyosarcoma, which accompanies with this syndrome for the first time.

\* Corresponding author.

E-mail address: [Fattal2661764@gmail.com](mailto:Fattal2661764@gmail.com) (A. Fattal).

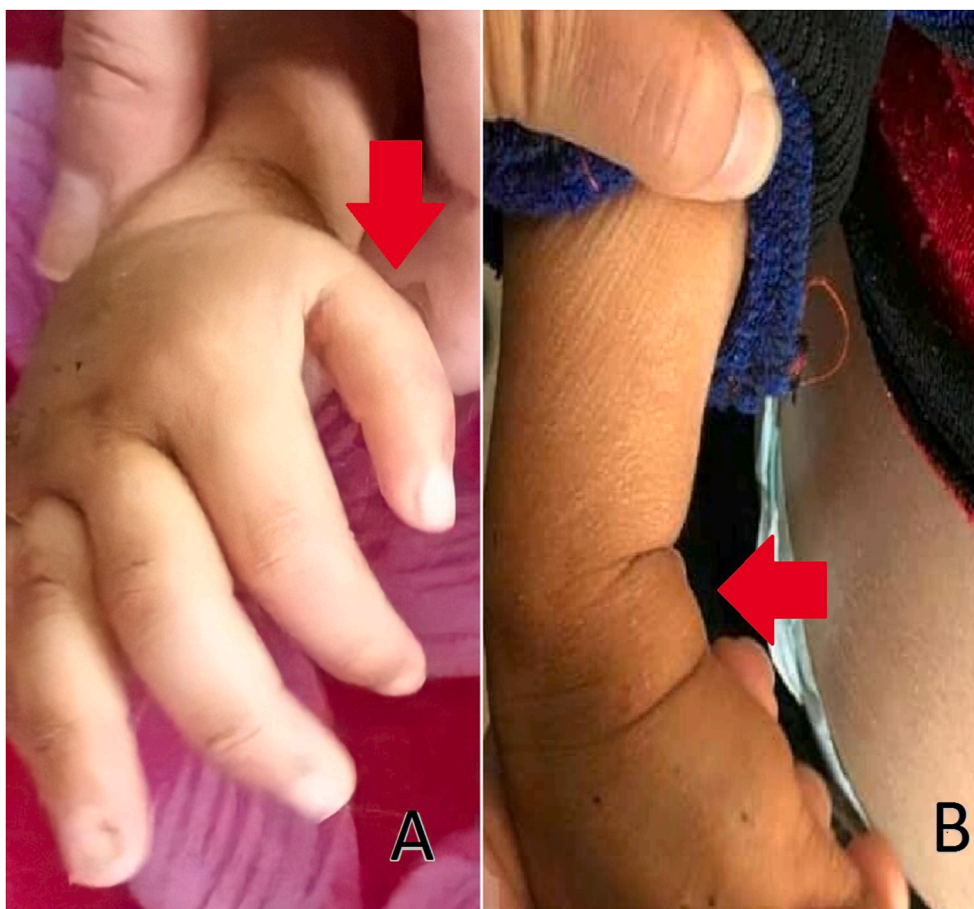<https://doi.org/10.1016/j.amsu.2021.01.032>

Received 1 January 2021; Received in revised form 12 January 2021; Accepted 12 January 2021

Available online 19 January 2021

2049-0801/© 2021 The Authors. Published by Elsevier Ltd on behalf of IJS Publishing Group Ltd. This is an open access article under the CC BY-NC-ND license

(<http://creativecommons.org/licenses/by-nc-nd/4.0/>).



**Fig. 1.** (A) Distortion on the thumb of the right upper (Arrow). (B) Distortion on the left wrist (Arrow).

## 2. Case presentation

A 2-year-old Syrian boy presented to the hospital due to an observed mass in the lower abdomen. His parents were healthy with a fourth-degree of consanguinity, and their whole eight children were normal except our patient. The pregnancy period had unremarkable antenatal or perinatal history and ended via spontaneous vaginal delivery.

A neonatal primary evaluation was performed after birth, and the absence of screaming delay, cyanosis, and inhalation was detected. The patient showed no need for respiratory support or incubation. His vaccine program was received completely. The psychomotor development was appropriate to his age in general. His tall was 85 cm, and his weight was 8 kg including the mass weight (less than his peers), with a walking onset at the age of 14 months. The patient's medical and surgical history was unremarkable, and his family history was also negative.

The swelling in the lower abdomen was observed 20 days before the attendance. Oliguria and constipation were noted by resident physicians in the emergency department. They managed by inserting a catheter in order to improve urinary excretion, without changing in its colour.

The physical examination showed an acceptable general state with a mild pallor, forward slanted pavilion, edema in eyelids and scrotum, and non-impressive edema in the lower extremities. Dysmorphic features included distortion on the left wrist and the thumb of the right upper limb, with a limited extension of the thumb. Shortness of proximal phalanx of the thumb with deviation was also noted (Fig. 1). The urogenital abnormalities included hypospadias.

The following results were obtained by measuring vital signs: Temperature was 38 °C, respiratory rate was 34/min, pulse rate was 150/min, and blood pressure was 105/56 mm Hg. The respiratory and cardiac system functions were within normal. There was no hemorrhage or

dehydration, neither vomiting nor diarrhea, and without any palpated visceral enormousness.

The abdominal examination showed dilated superficial veins, and abdominal rigidity appeared through palpation.

Laboratory tests demonstrated a negative urine test. The follow-up of the kidney and liver functions yielded normal results during hospitalization.

Radiologic evaluation with an X-ray image of the upper limbs showed delayed ossification of the carpal bones (Capitate and Hamate) (Fig. 2). In addition, abdominal CT revealed a large necrotic mass in the hypogastric region measuring (10–12) cm pushed the bladder to the left (Fig. 2). The ultrasound showed a necrotic liquid cystoid mass measuring (12.5–9 - 8) cm with abundant bloody perfusion. A bilateral 1st-grade dilation of the urinary tract was also seen.

A biopsy from the mass was performed and sent to the pathology department, and one section measuring 4 μm in thickness was studied. Haematoxylin and eosin (H&E) stain showed proliferation of small rounded and large elongated tumor cells with scattered rhabdomyoblasts, with eosinophilic cytoplasmic processes containing cross striations in a loose myxoid or dense collagenous stroma (Fig. 3).

The specimen was also stained with (MyoD1) which is more sensitive to Embryonal Rhabdomyosarcoma because it dyes the nuclei of the striated muscle cells and distinguishes them from other cells, and as a result, scattered tumor cells showed positivity for MyoD1 (Fig. 3). This result explained the cause of losing weight of the patient.

The patient received only one course of neoadjuvant chemotherapy consisted of a combination of Vincristine 1 mg/m<sup>2</sup> (Adults dosage is 1.5 mg/m<sup>2</sup>) and Adriamycin 16 mg/m<sup>2</sup> (Adults dosage is 25 mg/m<sup>2</sup>). However, he eventually passed away.

Germinal tumors were suspected during diagnosis, therefore, alpha-

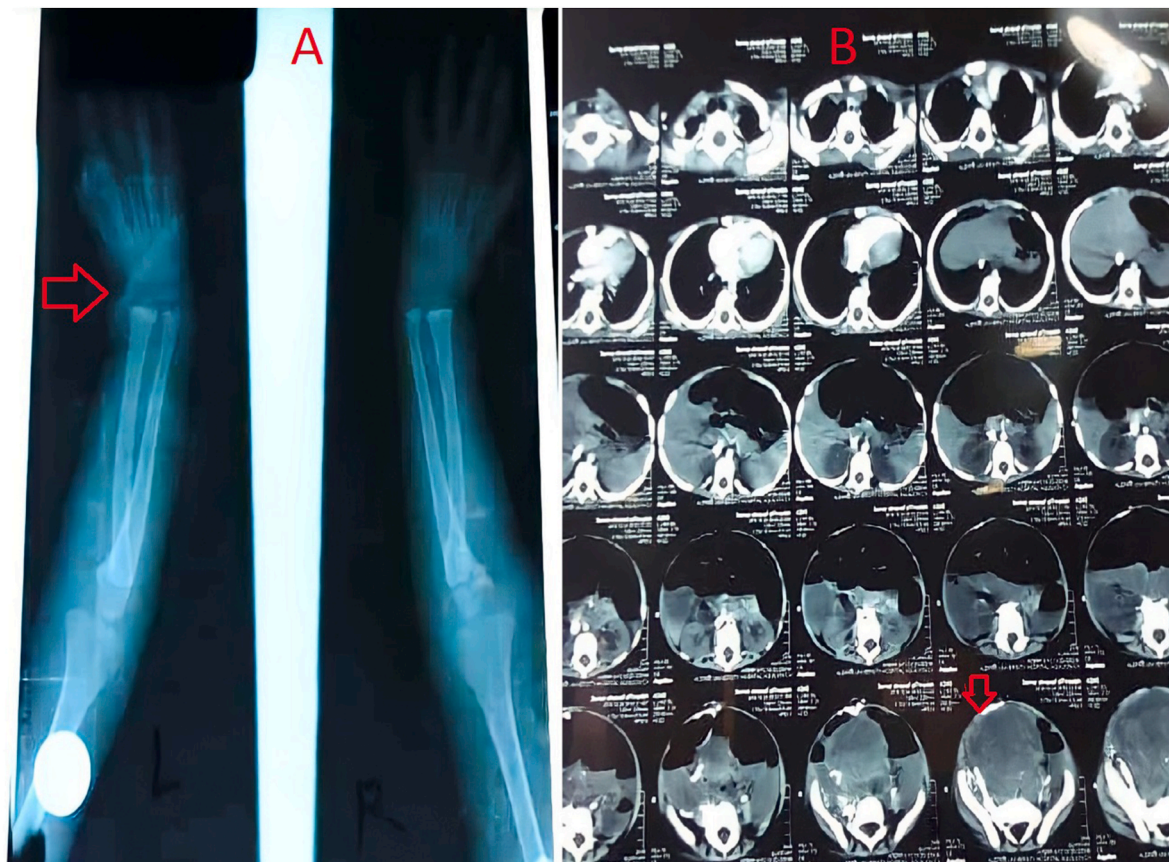


Fig. 2. (A) X-ray image reveals delayed ossification of the carpal bones (Arrow). (B) Axial CT image reveals a necrotic mass in the hypogastric region measuring (10–12) cm (Arrow).

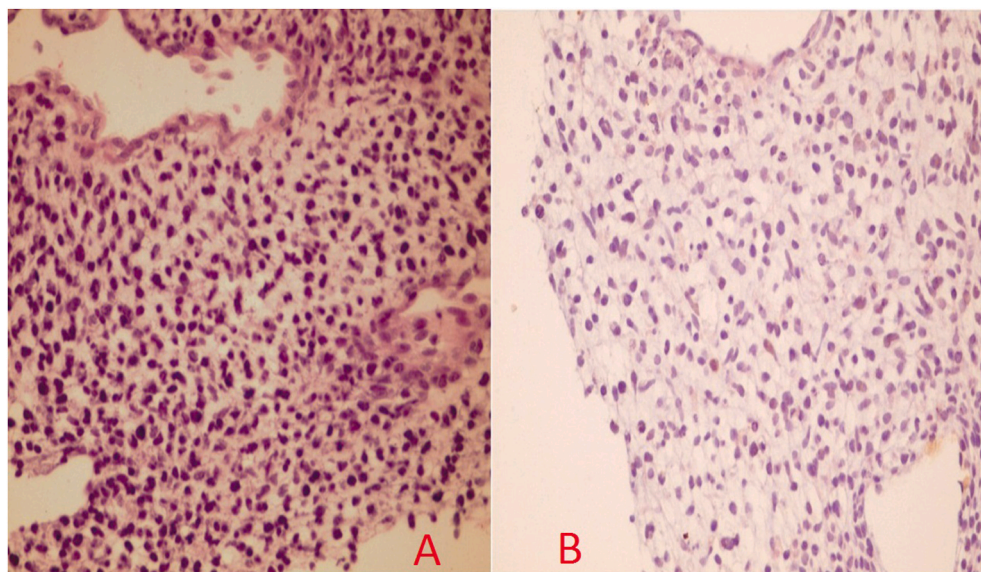


Fig. 3. (A) Haematoxylin and eosin (H&E) stain showed proliferation of small rounded and large elongated tumor cells. (B) MyoD1 stain.

fetoprotein (AFP) and human chorionic gonadotropin (HCG) levels were assayed and the results were normal.

### 3. Discussion

Hand-Foot-Genital Syndrome (HFGS) is a rare, autosomal dominant condition occurring due to mutation or deletion of the HOXA13 gene on

the chromosome 7p15 [1].

The Hand-Foot-Uterus Syndrome (HFUS) was first described by Stern et al., in 1970 and later revised to the HFG syndrome after documentation of extensive genitourinary abnormalities in addition to uterine abnormalities in affected females as well as the identification of several affected males with hypospadias who had the typical musculoskeletal and genitourinary findings of the disorder [5].

The HFGS is characterized by congenital genitourinary anomalies and variable skeletal anomalies, mainly affecting hands and feet, such as short thumbs and halluces, shortening of the middle phalanges, and the fusion of middle and distal phalanges of the toes.

About half of affected individuals have urogenital anomalies but have normal fertility. Males may have hypospadias or cryptorchidism, while females may have incomplete Mullerian fusion or bicornuate uterus. Females may have increased risks for spontaneous abortion, preterm delivery, or stillbirth [1].

In patients with HOXA13 mutations, skeletal anomalies are typically fully penetrant. However, these anomalies may be clinically subtle and only identifiable by imaging. The genitourinary abnormalities show variable penetrance and include hypospadias in males and incomplete Mullerian duct fusion in females, vesicoureteral reflux and ureteral-pelvic junction obstruction can be detected in both sexes [5].

Nevertheless, all patients with urogenital anomalies warrant careful examination for distal limb anomalies. Importantly, a family history positive for urogenital anomalies or recurrent pregnancy losses/preterm deliveries should prompt clinicians to carefully assess for distal limb anomalies and consider genetic testing which may lead to the identification of HFGS.[5].

In comparison with Giedion & Prader (1976) who reported a family with three affected brothers and apparently unaffected parents, we had not recognized any affected individual in the family in our case [6].

Diagnosis is made typically by G-T-L banding<sup>1</sup> chromosome analysis which is not available in our hospital or at any hospital in our country as a result of the lack of resources in the health sector.

In our case, the patient had additional malformation that had not been reported in HFGS previously: Embryonal Rhabdomyosarcoma tumor.

We depend on the radiography study in the diagnosis of the syndrome and the pathology in the diagnosis of the tumor.

Herein, we report the first case in Syria of the rare syndrome HFG with a rare associated tumor of Embryonal Rhabdomyosarcoma. So that, more studies are needed to reconsider about all malformations that may occur due to the HFGS, and we recommend doctors to do regular follow-ups with their patients in hospitals or local clinics regardless whether other risk factors exist or not.

### Ethical approval

Not required for case reports at our hospital. Single case reports are exempt from ethical approval in our institution.

### Sources of funding

There are no sources of funding.

### Author contribution

Conception and design: Amr Hamza, Ghina Ghannam, Yaman Koudra Danial, and Abdualh Fattal.

Analysis and interpretation of the data: Amr Hamza and Yaman Koudra Danial.

Drafting of the article: Amr Hamza, Ghina Ghannam, Yaman Koudra Danial, and.

Abdualh Fattal.

Critical revision of the article for important intellectual content: Lina

Ghabreau, Ghefar Omar, and Manar Abdullah.

### Informed consent

Written informed consent was obtained from the patient's family for publication of this case report and accompanying images. A copy of the written consent is available for review by the Editor-in-Chief of this journal on request.

### Registration of research studies

None.

### Guarantor

Dr. Manar Abdullah.

### Patient perspective

The patient's family participated in the treatment decision. Their perspective on this treatment was to remove uncomfortable mass.

### Provenance and peer review

Not commissioned, externally peer-reviewed.

### Declaration of competing interest

The authors declare that they have no conflict of interest.

### Acknowledgement

The authors would like to thank: Mr. Muhamad Zakaria Brimo Alsaman and Mr. Fadi Ward for giving suggestions to the work.

### Appendix A. Supplementary data

Supplementary data related to this article can be found at <https://doi.org/10.1016/j.amsu.2021.01.032>.

### References

- [1] F. Halal, The hand-foot-genital (hand-foot-uterus) syndrome: family report and update, *Am. J. Med. Genet.* 30 (1988) 793–803.
- [2] F.R. Goodman, P.J. Scambler, Human HOX gene mutations, *Clin. Genet.* 59 (2001) 1–11.
- [3] B. Utsch, K. Becker, D. Brock, M.J. Lentze, F. Bidlingmaier, M. Ludwig, A novel stable polyalanine [poly(A)] expansion in the HOXA13 gene associated with hand-foot-genital syndrome: proper function of poly(A)-harbouring transcription factors depends on a critical repeat length? *Hum. Genet.* 110 (5) (2002 May) 488–494. Epub 2002 Apr 4. Review.
- [4] E. Imagawa, H. Kayserili, G. Nishimura, M. Nakashima, Y. Tsurusaki, H. Saito, S. Ikegawa, N. Matsumoto, N. Miyake, Severe manifestations of hand-foot-genital syndrome associated with a novel HOXA13 mutation, *Am. J. Med. Genet.* 164A (2014) 2398–2402.
- [5] A.K. Poznanski, L.R. Kuhns, J. Lapidus, A.M. Stern, A new family with the hand-foot-uterus syndrome-A wider spectrum of the hand-foot-uterus syndrome, in: D. Bergsma (Ed.), "Genetic Forms of Hypogonadism." *New York Stratton*, vol. XI, BD: OAS, 1975, pp. 127–135, 4.
- [6] A. Giedion, A. Prader, Hand-foot-uterus (HFU) syndrome with hypospadias: the hand-foot-genital (HFG) syndrome, *Pediatr Radio* 4 (1976) 96–104.

<sup>1</sup> G-T-L banding refers to the chromosome banding technique in which G-bands are acquired through treatment with Trypsin followed by staining with Leishman's stain to produce differential staining of metaphase chromosomes.