

A surprising diagnosis in a young patient with intermittent claudication: Symptomatic isolated external iliac artery aneurysm associated with cystic media necrosis

Georgios Chatzantonis, MD,^a Lillian Schmoll, MD,^a Felix Strübing, MD,^b Grigorios Chatzantonis, MD,^c and Clemens Kühner, MD,^a *Ludwigshafen by Rhine, Ludwigshafen, and Münster, Germany*

ABSTRACT

Aneurysms of the external iliac artery are extremely rare. We present a case of a middle-aged male patient with calf claudication owing to peripheral arterial embolism on the basis of a thrombosed true aneurysm of the external iliac artery caused by cystic media necrosis. Vascular imaging established the diagnosis and we proceeded to removal of the aneurysm via open repair, with excellent surgical and clinical results. (*J Vasc Surg Cases and Innovative Techniques* 2020;6:352-6.)

Keywords: Aneurysm; Isolated Iliac artery aneurysm; External iliac artery; Intermittent claudication; Cystic medial necrosis

Isolated iliac artery aneurysms (IAA) are reported in up to 7% of all aortoiliac aneurysms and 12% to 48% of all isolated iliac aneurysms (IAA) are bilateral.¹⁻³ True aneurysms of the external iliac artery (EIA) are especially rare.⁴⁻⁶ In the present case, we discuss how we diagnosed and successfully treated a male patient with a symptomatic isolated external IAA caused by cystic medial necrosis (CMN) and review the presentation of this rare entity in the literature.

Written informed consent was obtained from the patient for publication of this case report and accompanying images.

CASE REPORT

A 51-year-old male patient was referred to our department of vascular surgery with a 5-month history of persistent calf and foot claudication of his right lower extremity. No rest pain was reported. The patient was an active smoker (25 pack-years), with no other known cardiovascular risk factors and he was not under any medication. Fourteen years before the acute incident, the patient had suffered a left sided pyelonephritis without sepsis. On physical examination the peripheral pulses of the right lower extremity were absent and the ankle-brachial index was 0. On the standardized treadmill exercise test, the right calf claudication began at 67 m.

We proceeded with magnetic resonance angiography, which showed an obstructed right EIA and a collateralized thromboembolic obstruction of the infrapopliteal arteries (*Fig 1, A and B*). Owing to presence of slightly dilated external iliac arteries of the contralateral side, we opted to perform computed tomography (CT) angiography, which visualized an thrombosed isolated 2-cm large fusiform right external IAA and a 2-cm saccular aneurysm of the left EIA, without involving the abdominal aorta, the common iliac artery (CIA) or the internal iliac artery (IIA) (*Fig 2, A-D*).

We managed the aneurysm by open repair using a right retroperitoneal approach (*Fig 3, A*). Preoperatively, the patient was informed of all operative risks, including erectile dysfunction. We chose a retroperitoneal approach, which is associated with a lower risk of nerve injury and subsequent erectile dysfunction. We implanted an 8-mm Dacron interposition graft and ligated the aneurysm. Both anastomoses were placed approximately 1 cm proximal and distal to the aneurysm (*Fig 3, B*). The flow in the IIA was preserved by constructing a proximal side-to-end anastomosis.

Histopathologic examination of the excised right iliac artery segment showed a mucoid degeneration of the tunica media, confirming that the true aneurysm was caused by CMN.

From the Department of Vascular and Endovascular Surgery, Municipal Hospital Ludwigshafen, Teaching Hospital of the University of Johannes Gutenberg University of Mainz and Medical Faculty of Mannheim of the University of Heidelberg, Ludwigshafen by Rhine^a; the Department of Hand-, Plastic and Reconstructive Surgery, Burn Trauma Center, BG Trauma Center Ludwigshafen, University of Heidelberg, Ludwigshafen^b; and the Division of Cardiovascular Imaging, Department of Cardiology I, University Hospital Münster, Münster.^c

G.C. and L.S. contributed equally to this work.

Author conflict of interest: none.

Correspondence: Georgios Chatzantonis, MD, Department of Vascular and Endovascular Surgery, Municipal Hospital Ludwigshafen, Teaching Hospital of the University of Johannes Gutenberg University of Mainz and Medical Faculty of Mannheim of the University of Heidelberg, Ludwigshafen by Rhine, Germany (e-mail: chatzang@klllu.de).

The editors and reviewers of this article have no relevant financial relationships to disclose per the Journal policy that requires reviewers to decline review of any manuscript for which they may have a conflict of interest.

2468-4287

© 2020 The Author(s). Published by Elsevier Inc. on behalf of Society for Vascular Surgery. This is an open access article under the CC BY-NC-ND license (<http://creativecommons.org/licenses/by-nc-nd/4.0/>).

<https://doi.org/10.1016/j.jvscit.2020.05.010>

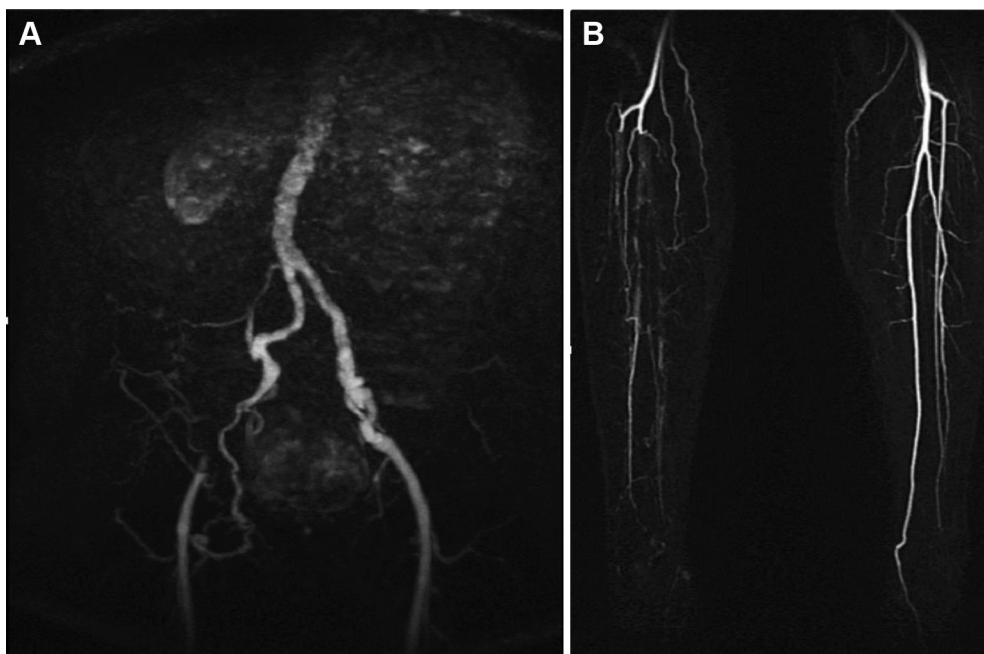


Fig 1. A and B, Magnetic resonance angiography shows the obstructed right external iliac artery (EIA) and the collateralized embolic occlusion of the infragenaal arteries.

A mycotic pathology was ruled out. Fig 4, A-C, illustrates the histopathologic findings.

The operative procedure was uneventful. After a short period of observation in a recovery room, we were able to transfer the patient to our regular vascular surgical ward and there was no need for further intensive care or monitoring. Postoperatively, the pain-free walking distance on the treadmill exercise test increased to more than 500 m and the right ankle-brachial index was 0.7. The patient was discharged on postoperative day 6. On discharge, we recommended strict management of cardiovascular risk factors as well as smoking cessation, antiplatelet therapy, with low-dose aspirin and statin therapy.

Additionally, owing the saccular morphology of the left iliac external artery aneurysm, we planned an elective second procedure of open repair in the same manner 1 month after discharge. Here as well, the postoperative course was uneventful and the patient was discharged on postoperative day 5. At 50 days after repair of the right-sided symptomatic EIA aneurysm, the patient was satisfied and regained much of his everyday mobility with a pain-free walking distance of 4000 m. We were also able to show a preserved flow in both IIA in the postoperative magnetic resonance angiography (Fig 5).

DISCUSSION

An IAA is defined as dilatation of the vessel to more than 1.5 times its normal or expected diameter.^{1,7} Isolated IAA include aneurysms of the CIA, the IIA, the EIA and combinations of those, excluding those of the infrarenal abdominal aorta. They frequently involve the CIA, IIA, or both.^{8,9} Aneurysms of the EIA are

extremely rare, possibly owing to the different embryological development between the iliac artery segments.¹⁰

The majority of patients with isolated IAA aneurysms are male and diagnosed in the seventh and eighth decades.⁷ Their overall prevalence is reported as less than 2% of the general population and the underlying pathology and type of isolated IAA includes degenerative aneurysm, pseudoaneurysm, penetrating ulcer, postdissection aneurysm, mycotic aneurysm, and traumatic aneurysm.¹¹

CMN was first described by Babes and Mironescu in 1910 and since 1928 was established by Gsell and Erdheim as pathologic finding in the media wall related to aortic aneurysm, dissection, and rupture.¹² CMN is a disorder of the large arteries, especially the aorta, and commonly seem to be an essential feature of several hereditary conditions, such as Ehlers-Danlos and Marfan syndrome. It is characterized by cyst-like lesions within the media, causing degenerative disruptions of connective tissue proteins and smooth muscles of the tunica media, which may lead to deterioration of the arterial wall.¹³

Isolated IAAs, except for their high risk of rupture of up to 40% with high mortality (31%), rarely can cause thromboembolic peripheral events followed by arterial insufficiency and were recognized only after onset of ipsilateral limb ischemic symptoms, which need further angiographic evaluation.¹⁴ Elective repair is generally recommended if the aneurysm diameter reaches the

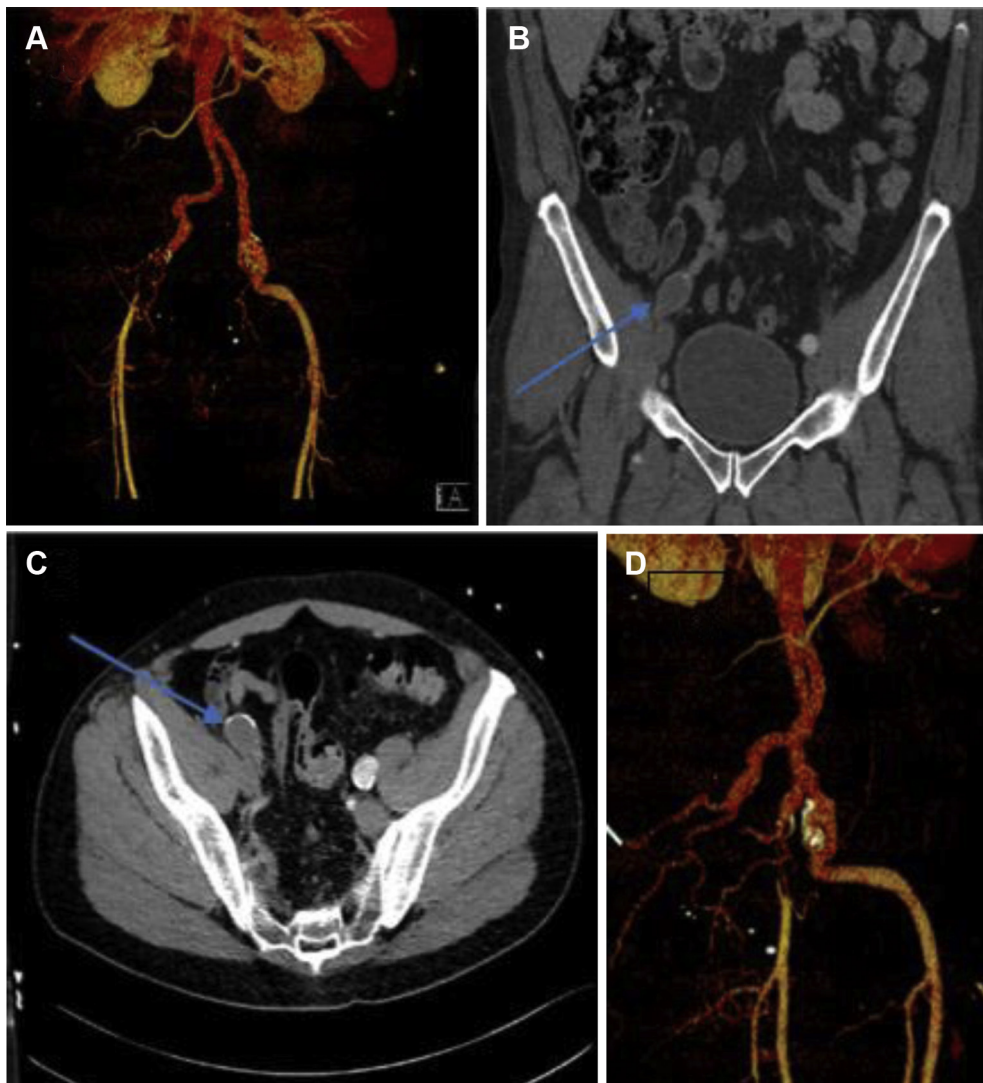


Fig 2. A-D, Computed tomography (CT) angiography in axial (C) and coronal (B) view with three-dimensional reconstruction (A and D) shows the isolated 2-cm large thrombosed aneurysm of the right external iliac artery (EIA) (blue arrow) and the 2-cm large sacciform aneurysm of the left EIA (white arrow).

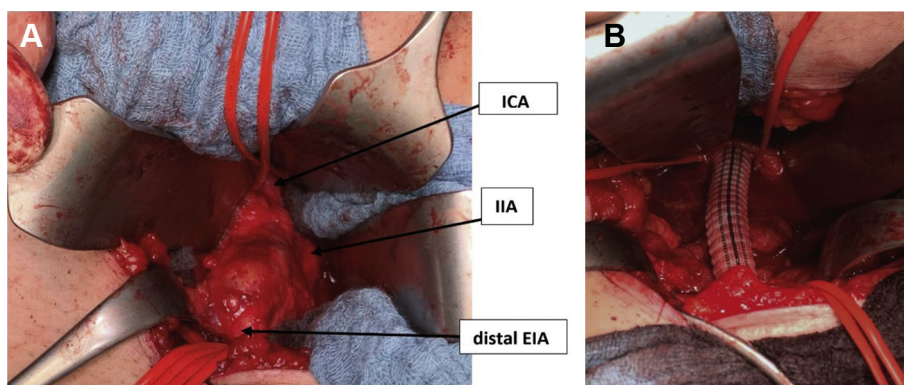


Fig 3. A and B, Intraoperative photo after exposure of the external iliac artery (EIA) aneurysm. The common iliac and the distal iliac artery are encircled with vessel loops to obtain vascular control. A, Intraoperative photo after aneurysm exclusion and reconstruction with an 8-mm Dacron interposition graft (B). ICA, Iliac common artery; IIA, internal iliac artery.

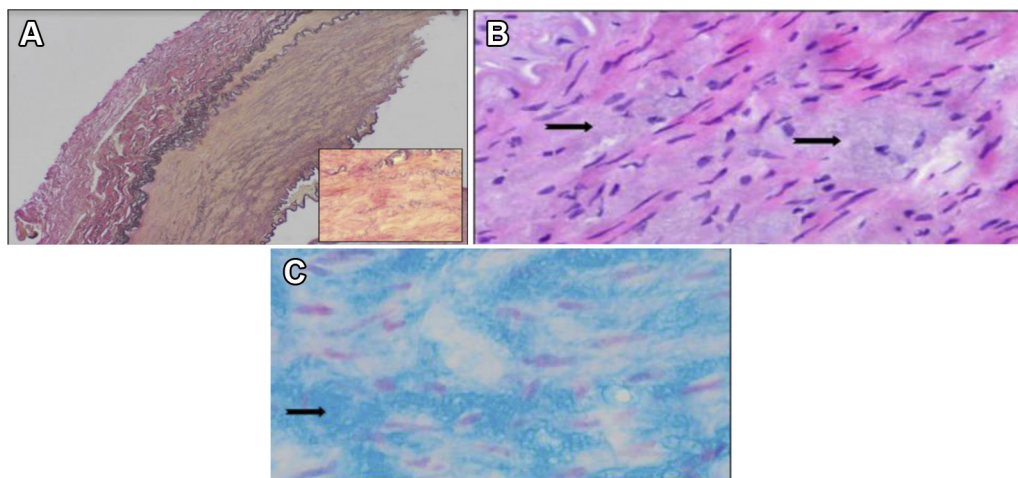


Fig 4. A-C, Cystic medial necrosis (CMN). **A,** Photomicrograph of the wall of the external iliac artery (EIA). On low power, the impaired layered arrangement of medial smooth muscle is readily apparent showing fragment and loss of elastic fibers (stain: Elastica van Gieson; original magnification $\times 40$). (*Inset*) Loss and fragmentation of elastic fibers (original magnification $\times 200$). **B** and **C,** On high power, accumulated proteoglycans (*arrows*) between smooth muscle cells often seems to be myxoid (stain: hematoxylin and eosin; original magnification $\times 100$; and stain: Astra Blue; original magnification $\times 200$).

threshold of 3.0 to 3.5 cm and the type of operative repair depends on patient anatomy, clinical status, and the presence of concomitant abdominal aortic aneurysm.⁷

We searched under the keyword “external IAA” in the English-language medical literature and we found 65 EIA aneurysms. We only found three cases of true isolated aneurysms of the EIA caused by CMN until January 2020. Each of them was histologically confirmed and the aneurysms were treated with different types of open repair. The [Table](#) presents the cases reviewed.

Crivello et al,¹⁵ who first described the case of the isolated EIA aneurysm in association with CMN, reported a higher operative risk owing to the friability of the artery wall caused by the media degeneration. In 2009, Kato et al¹⁶ reported their experiences in the treatment of an EIA aneurysm, but they could not conform the findings of Crivello et al. Similar to the experience of Kato et al, we also did not find fragile vessel walls in our bilateral open aneurysm repair.

In summary, we present another case of an isolated aneurysm of the EIA with the particularity of bilateral occurrence. We managed the symptomatic right EIA aneurysm via open repair and chose to repair the left sided asymptomatic aneurysm 4 weeks postoperatively, despite the absence of current elective repair threshold of 3.0 to 3.5 cm because of the sacciform morphology. We chose an open approach for two main reasons. First, the patient was young, and we did not want to expose him to followed-up CT radiation. Second, the anatomic features of the arteries were not appropriate for endovascular treatment. Our histopathologic findings conform at large with those of the preceding reports of CMN as underlying

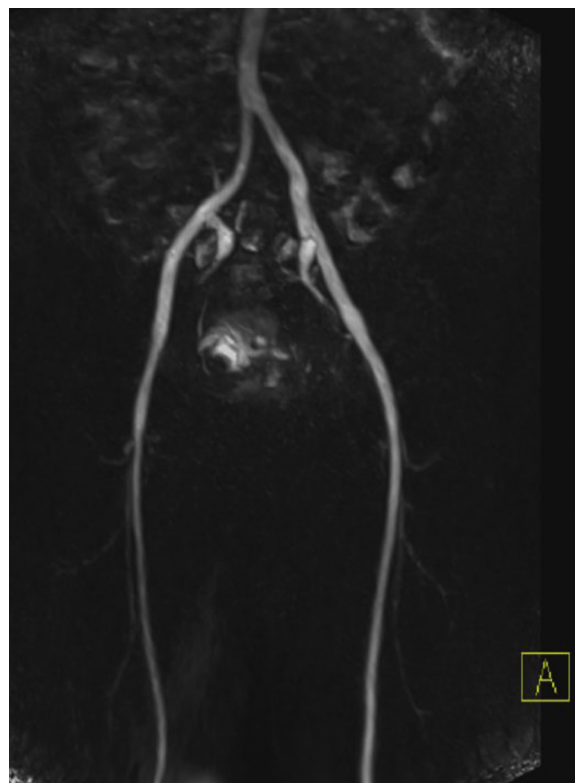


Fig 5. Postoperative magnetic resonance angiogram after aneurysm repair of both external iliac artery (EIA) showing the preserved flow both internal iliac arteries.

pathomechanism of development of isolate iliac aneurysms of the EIA. On reviewing the current literature, we must assert to the fact that there remains

Table. Reported cases of isolated external iliac aneurysm with an underlying histopathology of cystic media necrosis (CMN)

Author	Age	Sex	Symptomatic	Size (cm)	Year
Crivello et al ¹⁵	27	Male	Yes	NA	1986
Mohan et al ¹⁷	66	Male	No	11	1997
Kato et al ¹⁶	78	Female	Yes	4	2009
Current case	51	Male	Yes	2	2019

limited information of the rare entity and call on vascular clinicians for more publishing so as to establish the characteristics that may be still unknown.

We thank Helena Elert, MD, and Prof Dr Mindaugas Andrulis of our pathology department for providing the pathology slides and the respective descriptions.

REFERENCES

- Boules TN, Selzer F, Stanziale SF, Chomic A, Marone LK, Dillavou ED, et al. Endovascular management of isolated iliac artery aneurysms. *J Vasc Surg* 2006;44:29-37.
- Krupski WC, Selzman CH, Florida R, Strecker PK, Nehler MR, Whitehill TA. Contemporary management of isolated iliac aneurysms. *J Vasc Surg* 1998;28:1-11; discussion: 11-3.
- Patel NV, Long GW, Cheema ZF, Rimar K, Brown OW, Shanley CJ. Open vs. endovascular repair of isolated iliac artery aneurysms: a 12-year experience. *J Vasc Surg* 2009;49:1147-53.
- McCready RA, Pairolero PC, Gilmore JC, Kazmier FJ, Cherry KJ, Hollier LH. Isolated iliac artery aneurysms. *Surgery* 1983;93:688-93.
- Lowry SF, Kraft RO. Isolated aneurysms of the iliac artery. *Arch Surg* 1978;113:1289-93.
- Hu H, Takano T, Guntani A, Onohara T, Furuyama T, Inoguchi H, et al. Treatment of solitary iliac aneurysms: clinical review of 28 cases. *Surg Today* 2008;38:232-6.
- Wanhainen A, Verzini F, Van Herzele I, Allaire E, Bown M, Cohnert T, et al. Editor's choice - European Society for Vascular Surgery (ESVS) 2019 Clinical Practice Guidelines on the Management of Abdominal Aorto-iliac Artery Aneurysms. *Eur J Vasc Endovasc Surg* 2019;57:8-93.
- Levi N, Schroeder TV. Isolated iliac artery aneurysms. *Eur J Vasc Endovasc Surg* 1998;16:342-4.
- Kasulke RJ, Clifford A, Nichols WK, Silver D. Isolated atherosclerotic aneurysms of the internal iliac arteries: report of two cases and review of literature. *Arch Surg* 1982;117:73-7.
- Norman PE, Powell JT. Site specificity of aneurysmal disease. *Circulation* 2010;121:560-8.
- Bacharach JM, Slovut DP. State of the art: management of iliac artery aneurysmal disease. *Catheter Cardiovasc Interv* 2008;71:708-14.
- Bahnson HT, Nelson AR. Cystic medial necrosis as a cause of localized aortic aneurysms amenable to surgical treatment. *Ann Surg* 1956;144:519-29.
- Yuan SM, Jing H. Cystic medial necrosis: pathological findings and clinical implications. *Rev Bras Cir Cardiovasc* ;26: 107-115.
- Dix FP, Titi M, Al-Khaffaf H. The isolated internal iliac artery aneurysm—a review. *Eur J Vasc Endovasc Surg* 2005;30: 119-29.
- Crivello MS, Porter DH, Kim D, Critchlow JF, Scoutt L. Isolated external iliac artery aneurysm secondary to cystic medial necrosis. *Cardiovasc Intervent Radiol* 1986;9:139-41.
- Kato T, Takagi H, Kawai N, Sekido Y, Umemoto T. Ruptured isolated external iliac artery true aneurysm associated with cystic medial necrosis: report of a case. *Surg Today* 2009;39: 705-9.
- Mohan I, Adam D, Kurian K, Ruckley C. Isolated external iliac aneurysm associated with hyperhomocysteinaemia. *Eur J Vasc Endovasc Sur* 1997;14:506-8.

Submitted Feb 18, 2020; accepted May 14, 2020.